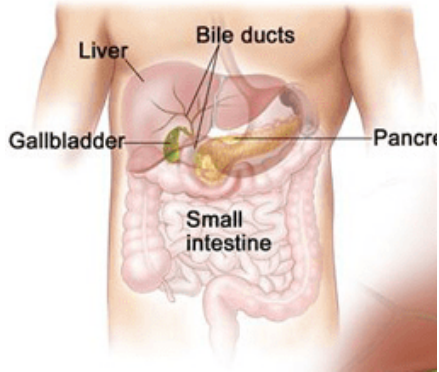

Anatomy of Hepatopancreatobiliary System

A RO's Perspective

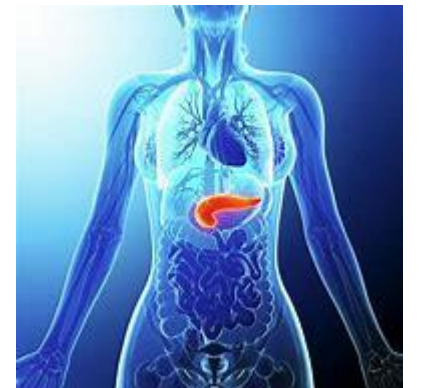
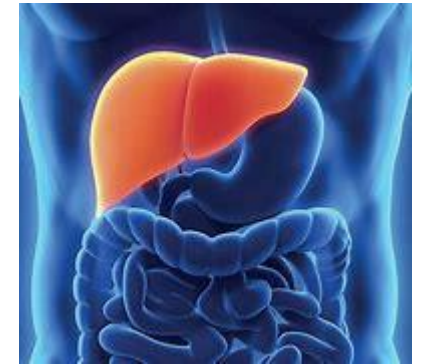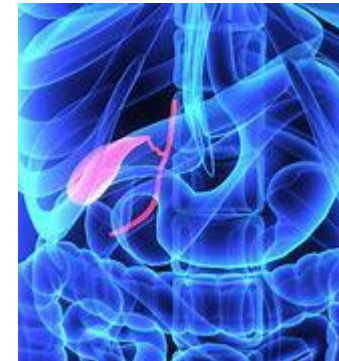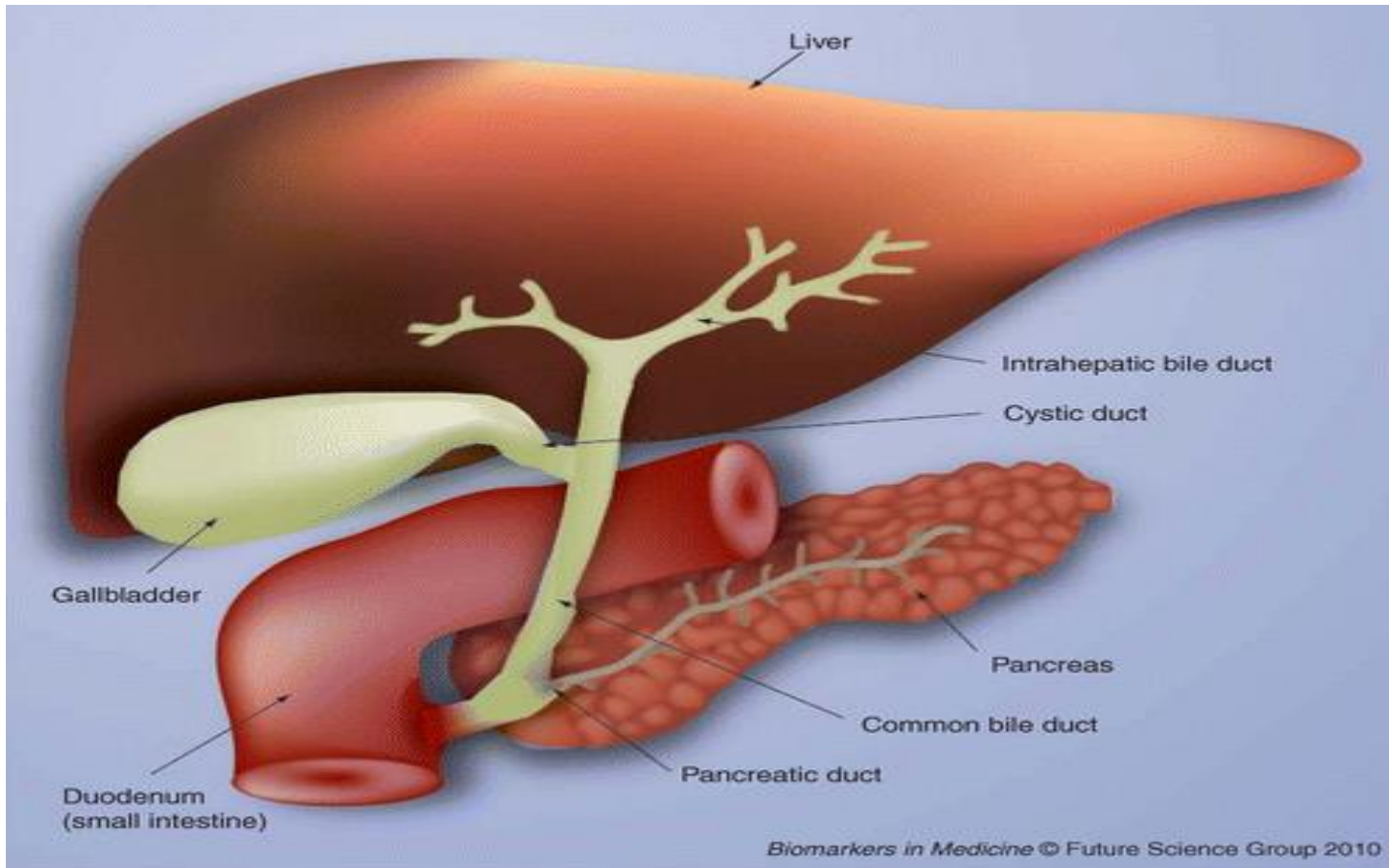


Dr Chandani Hotwani

Consultant Radiation Oncologist

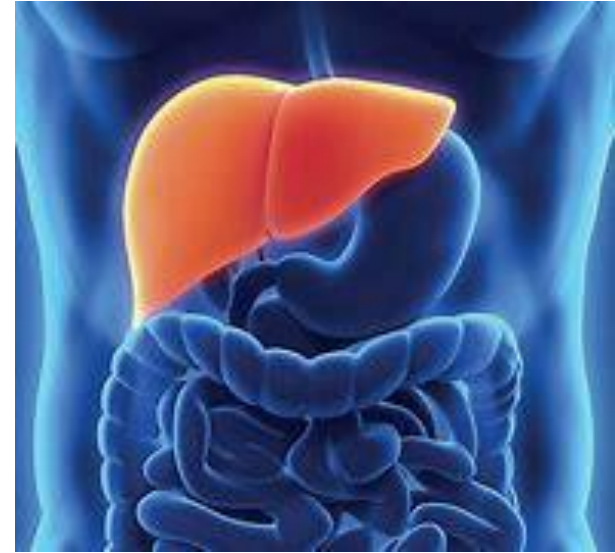Alexis Multispeciality Hospital, Nagpur

Hepatopancreatobiliary System



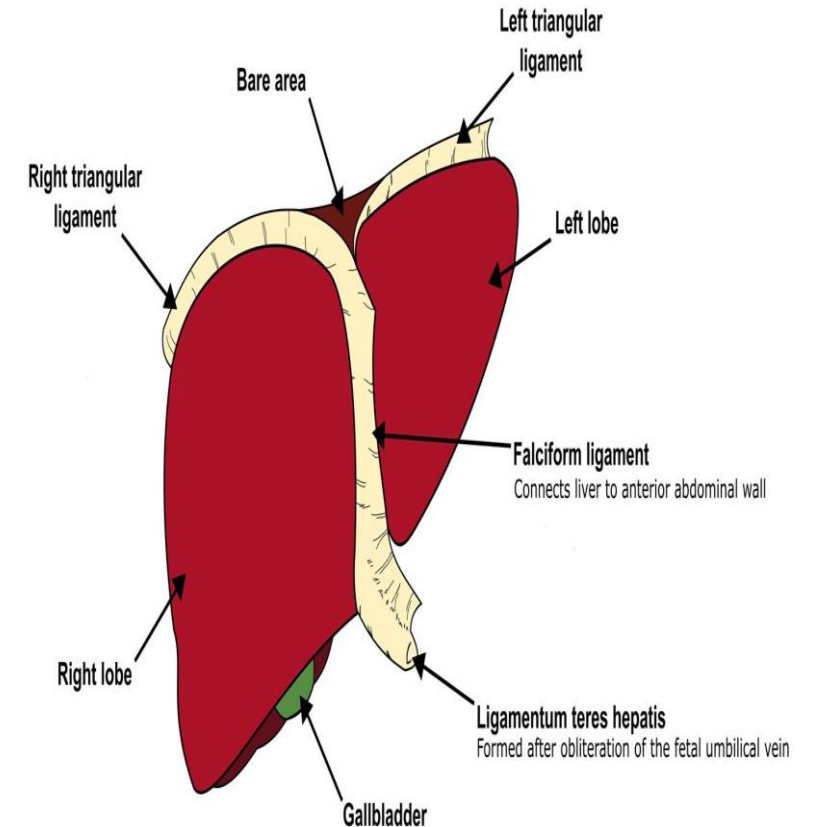
Liver

- Liver: second largest organ
 - Weighs around 1.5kg
- 25% of CO is supplied to liver
- Located just below diaphragm
 - extends from the right 5th intercostal space superiorly to the edge of the costal margin inferiorly
- Covered by Glisson's capsule

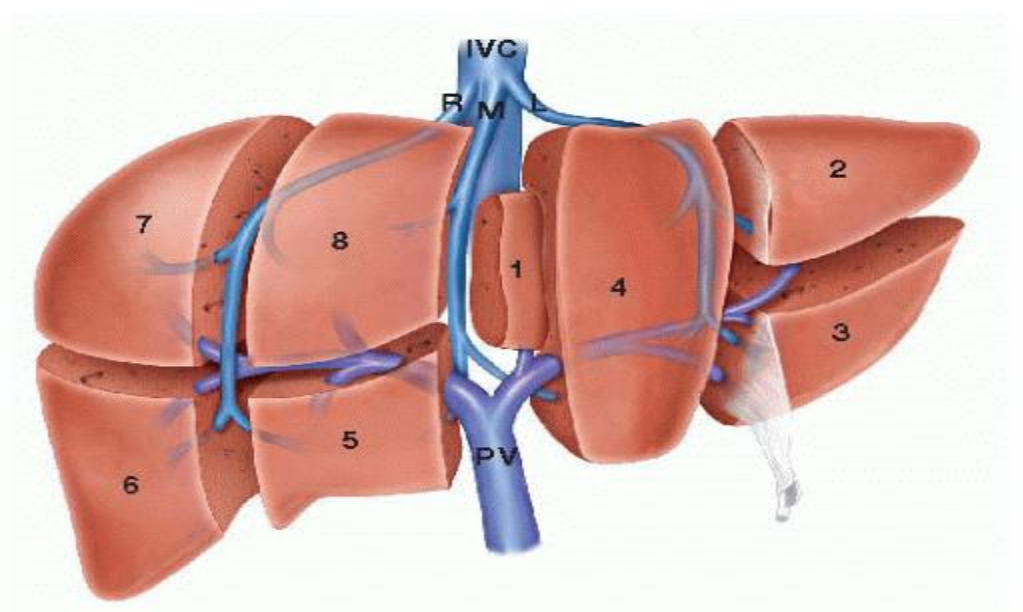


Ligaments of liver

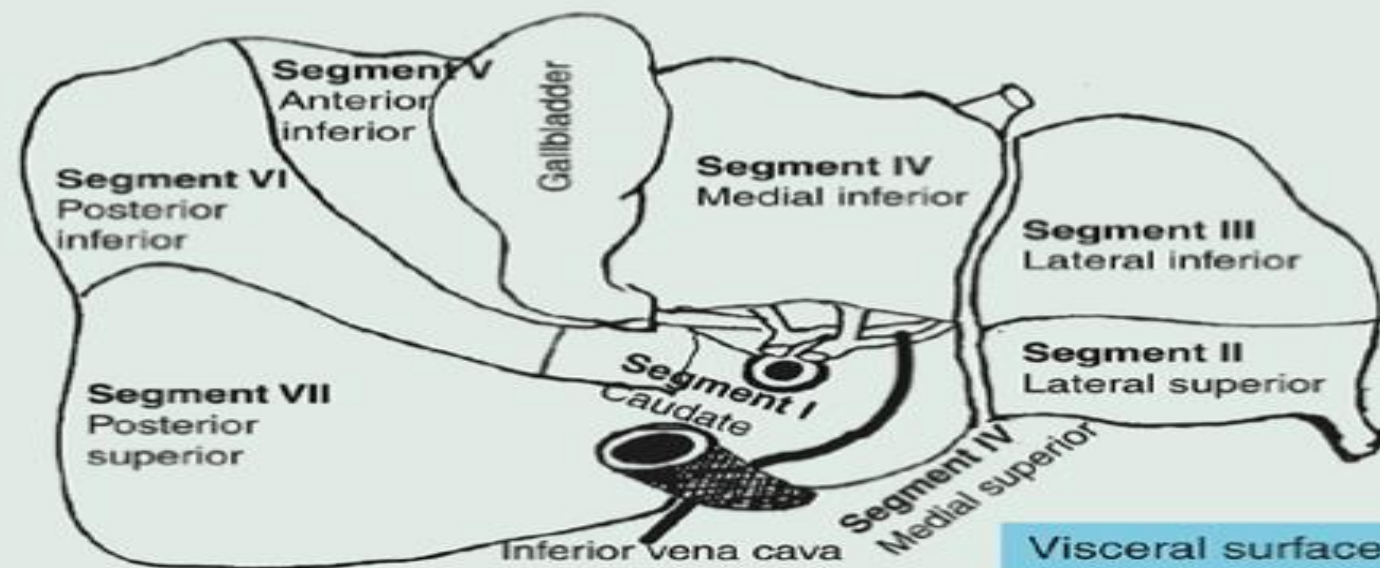
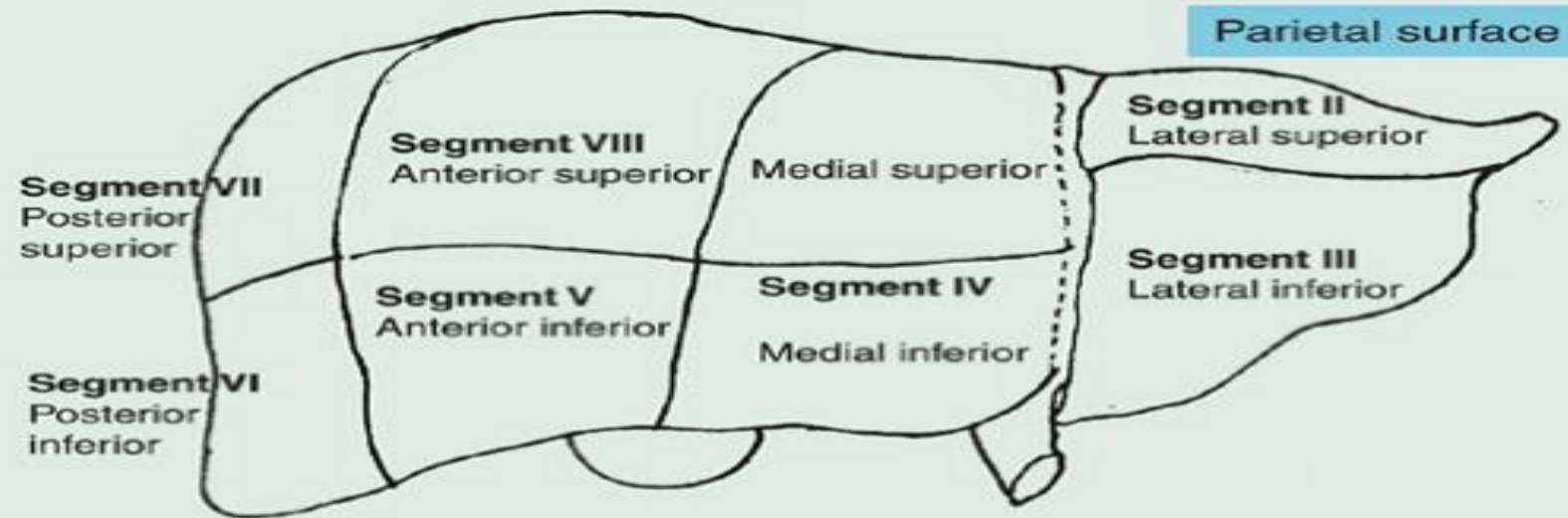
Coronary ligament	Coronal ligament Attaches the liver to the <u>diaphragm</u> , and the right <u>kidney</u> and <u>adrenal gland</u>
Triangular ligament	Asymmetrical Right and left components Covers left lobe of the liver
Falciform ligament	Sickle-shaped Anchors the liver the anterior abdominal wall and the diaphragm
Ligamentum teres (hepatis)	Round ligament of the liver A remnant of the left umbilical vein
Ligamentum venosum	A remnant of the ductus venosum Occupies the fissure of the ligamentum venosum
Lesser omentum	L-shaped Two parts: hepatogastric ligament, hepatoduodenal ligament



Segments of liver



- Evolved over time
 - Various classifications used
 - Hjortsjö, Healey and Schroy, Couinaud, Goldsmith and Woodburne, and H. Bismuth
 - Couinaud eight segment classification in 1954 favoured
 - Eight independent segments
 - Spatially divided by Cantlie's line, which runs from the fundus of the gallbladder to the suprahepatic inferior vena cava (IVC). Within the substance of the liver, the middle hepatic vein courses along this same path and is the true division of the right and left hemilivers
 - Own function, biliary drainage and vascular outflow and inflow (separate portal, hepatic artery and biliary flow, but venous drainage is shared with adjacent segments)



The Brisbane 2000 Terminology of liver anatomy and resections

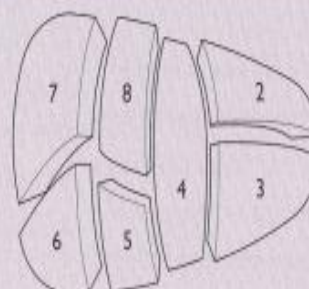
- Uses four planes to separate the segments:
 - Three longitudinal planes joining the **inferior vena cava** to respectively the **right hepatic vein**, the **median hepatic vein**, and the umbilical portion of the **left hepatic vein**.
 - One imaginary transverse plane passing by the **portal vein** bifurcation is also used.
 - Three segments to the left liver (segments II, III, and IV) fed by the left portal vein and four segments to the right liver fed by the right portal vein (segments V, VI, VII, and VIII).
 - **Segment I** is located posteriorly between the portal vein and the inferior vena cava and is fed by multiple branches coming from both the left and right portal veins and does not belong either to the right or left liver.

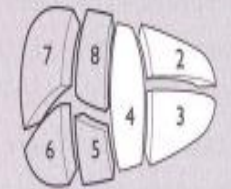
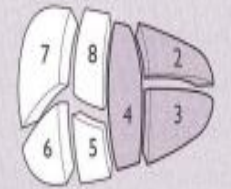
- First order division

- Left and right hemiliver (falciform ligament)
- Left hepatectomy or left hemihepatectomy (segments 2 to 4)
- Right hepatectomy or right hemihepatectomy (segments 5-8).

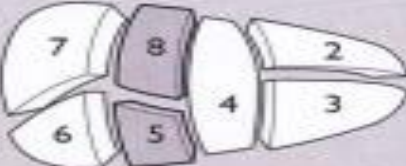
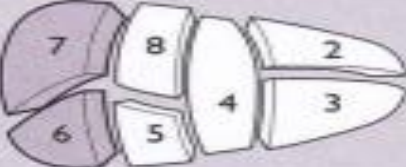
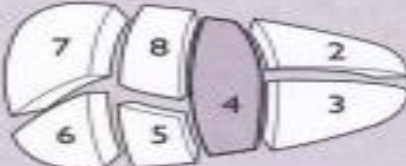
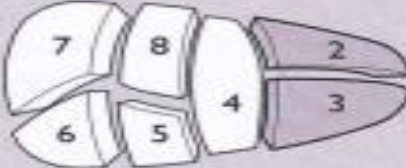
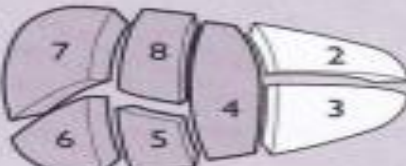

Table 1. First-order division

Schematic diagram of the segments for reference in the table (for purposes of clarity Sg1 is not shown)



Anatomical term	Couinaud segments referred to	Term for surgical resection	Diagram (pertinent area is in heavy black outline)
Right hemiliver OR Right liver	Sg5-8(+/-Sg1)	Right hepatectomy OR Right hemihepatectomy (stipulate +/- segment 1)	
Left hemiliver OR Left liver	Sg2-4 (+/-Sg1)	Left hepatectomy OR Left hemihepatectomy (stipulate +/- segment 1)	

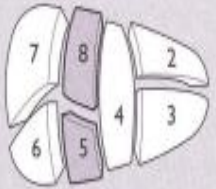

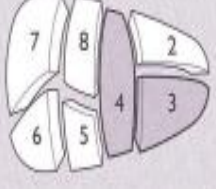
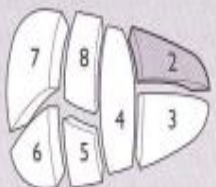
- Second order division
 - Right anterior section (segment 5&8), the right posterior section (segments 6&7),
 - the left medial section (segment 4) and the left lateral section (segment 2&3).
 - The resection of these sections is termed as the corresponding sectionectomy.

Anatomical term	Couinaud segments referred to	Term for surgical resection	Diagram
Right anterior section	Sg5,8	Add '-ectomy' to any of the anatomical terms as in <i>Right anterior sectionectomy</i>	
Right posterior section	Sg6,7	<i>Right posterior sectionectomy</i>	
Left medial section	Sg4	<i>Left medial sectionectomy</i> OR <i>Resection segment 4</i> (also see under third order) OR <i>Segmentectomy 4</i> (also see under third order)	
Left lateral section	Sg2,3	<i>Left lateral sectionectomy</i> OR <i>Bisegmentectomy 2,3</i> (also see under third order)	
Right hemiliver plus left medial section	Sg4-8 (+/- Sg1)	<i>Right trisectionectomy</i> or <i>Extended right hepatectomy</i> or <i>Extended right hemihepatectomy</i>	
Left hemiliver plus right anterior section	Sg2,2-5,5,8 (+/- Sg1)	<i>Left trisectionectomy</i> or <i>Extended left hepatectomy</i> or <i>Extended left hemihepatectomy</i>	

Borders or watersheds:

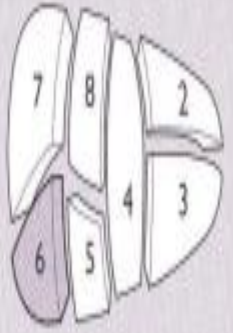
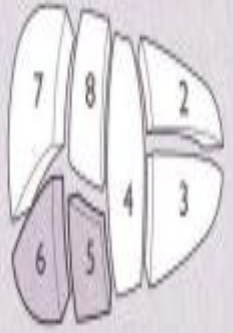
An additional alternative second-order division based on **portal vein** recommended in this terminology which used the term **sector** instead of section and the resection of these sectors is known as **sectorectomy**

Addendum. Alternative second-order division (second-order division based on portal vein)

Anatomical term	Couinaud segments referred to	Term for surgical resection	Diagram
Right anterior sector OR Right paramedian sector	Sg5,8	Add '-ectomy' to any of the anatomical terms, as in Right anterior sectorectomy OR Right paramedian sectorectomy	
Right posterior sector OR Right lateral sector	Sg6,7	Right posterior sectorectomy OR Right lateral sectorectomy	
Left medial sector OR Left paramedian sector	Sg3,4	Left medial sectorectomy OR Left paramedian sectorectomy OR Bisegmentectomy 3,4	
Left lateral sector OR Left posterior sector	Sg2	Left lateral sectorectomy OR Left posterior sectorectomy OR Segmentectomy 2	

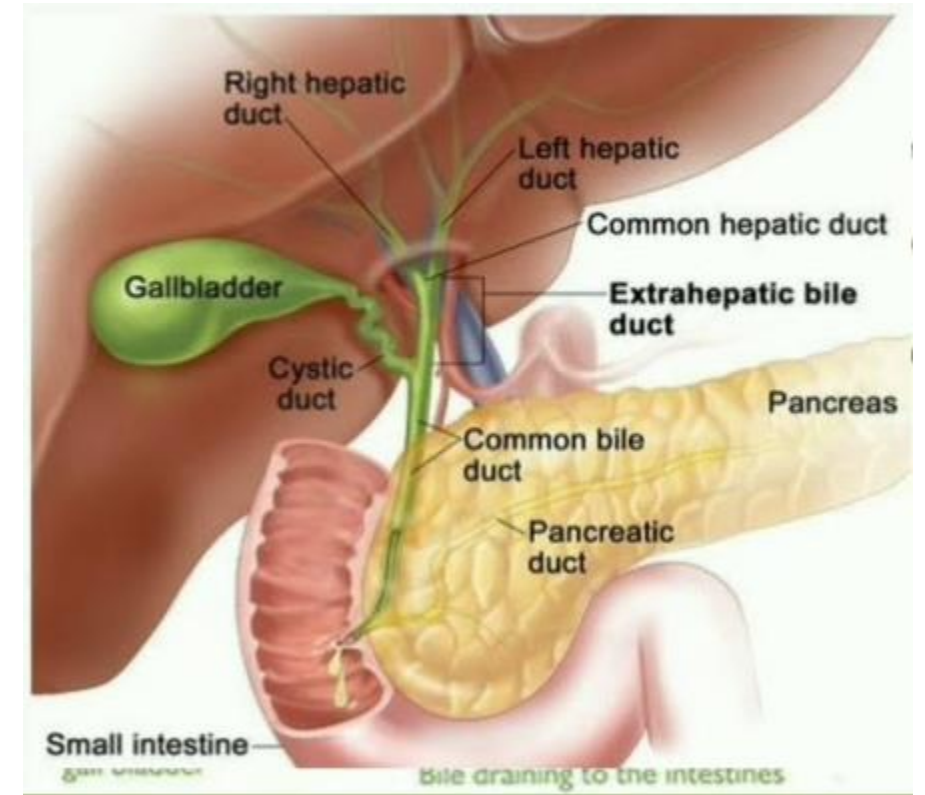
- Third-order division,
 - these sections are divided into segments and the resection of these segments is termed as ***segmentectomy***.

Table 3. Third-order division

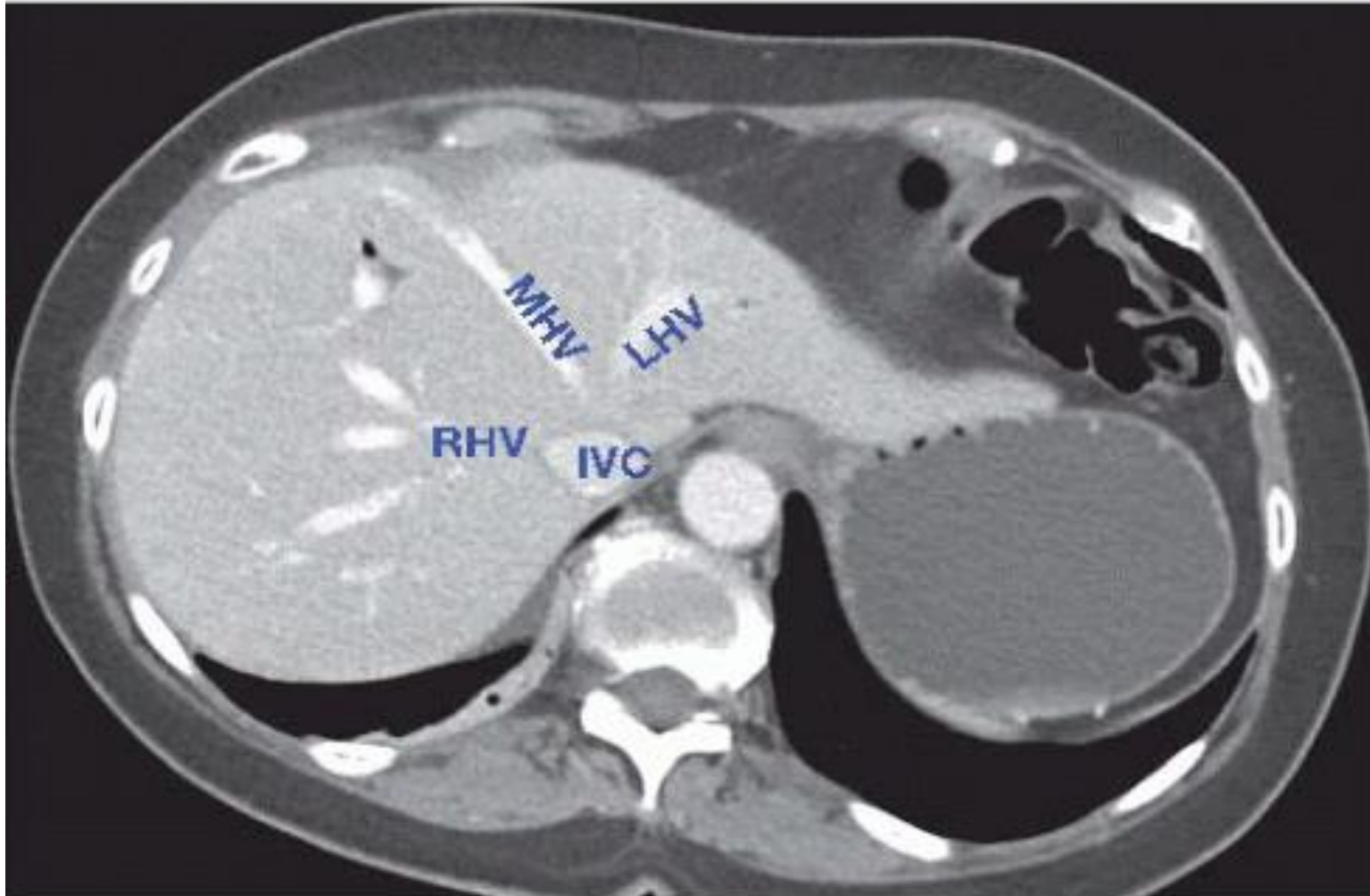
Anatomical term	Couinaud segments referred to	Term for surgical resection	Diagram
Segments 1–9	Any one of Sg1 to Sg9	Segmentectomy	 <p>(Segmentectomy 6)</p>
2 contiguous segments	Any two of Sg1 to Sg9 in continuity	Bisegmentectomy	 <p>(Bisegmentectomy 5,6)</p>

Porta Hepatis

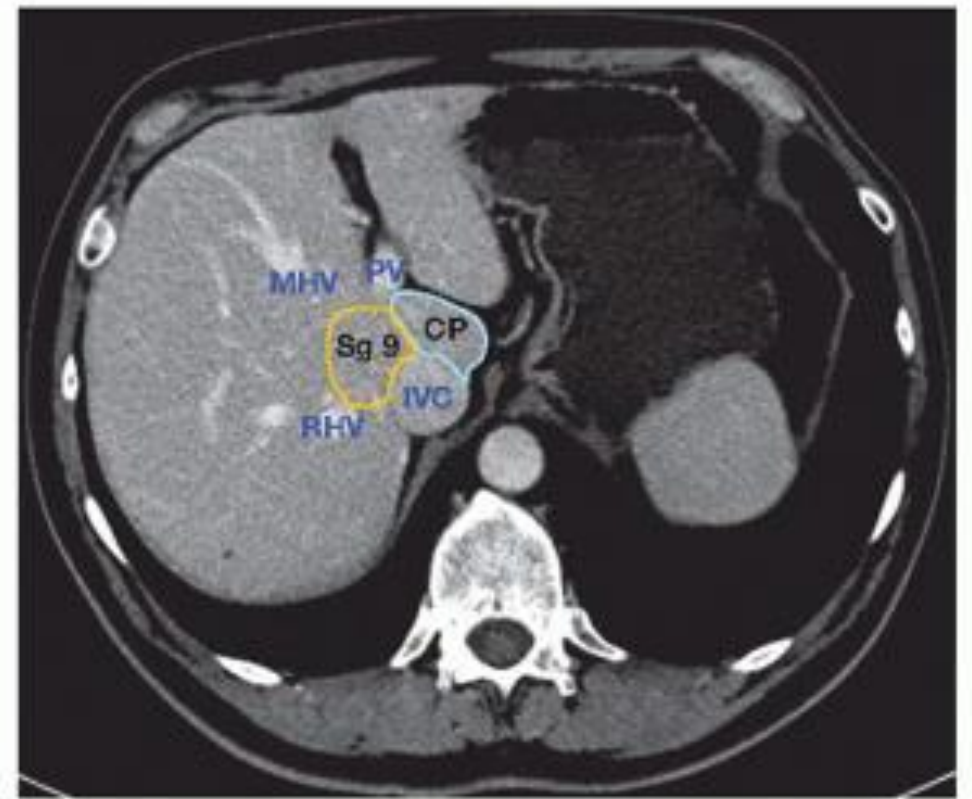
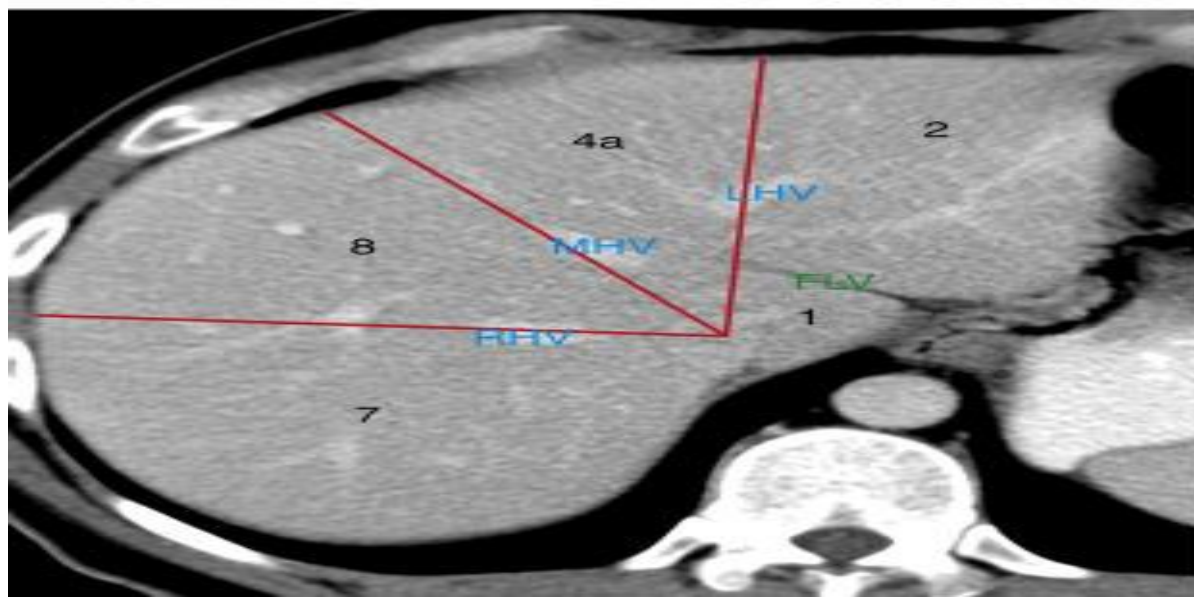
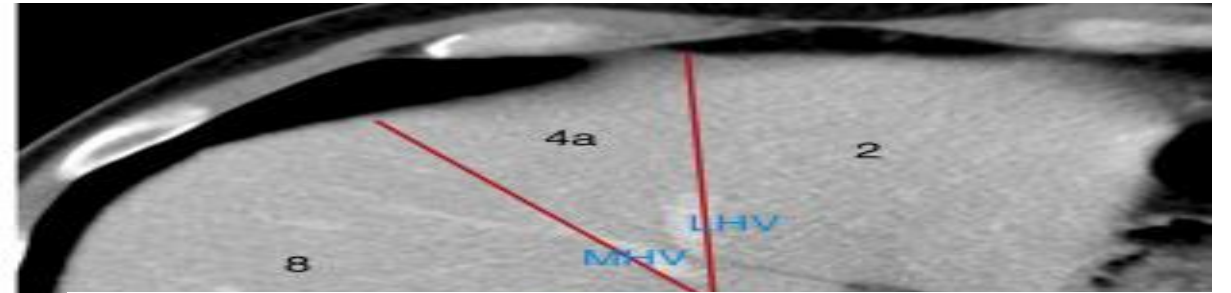
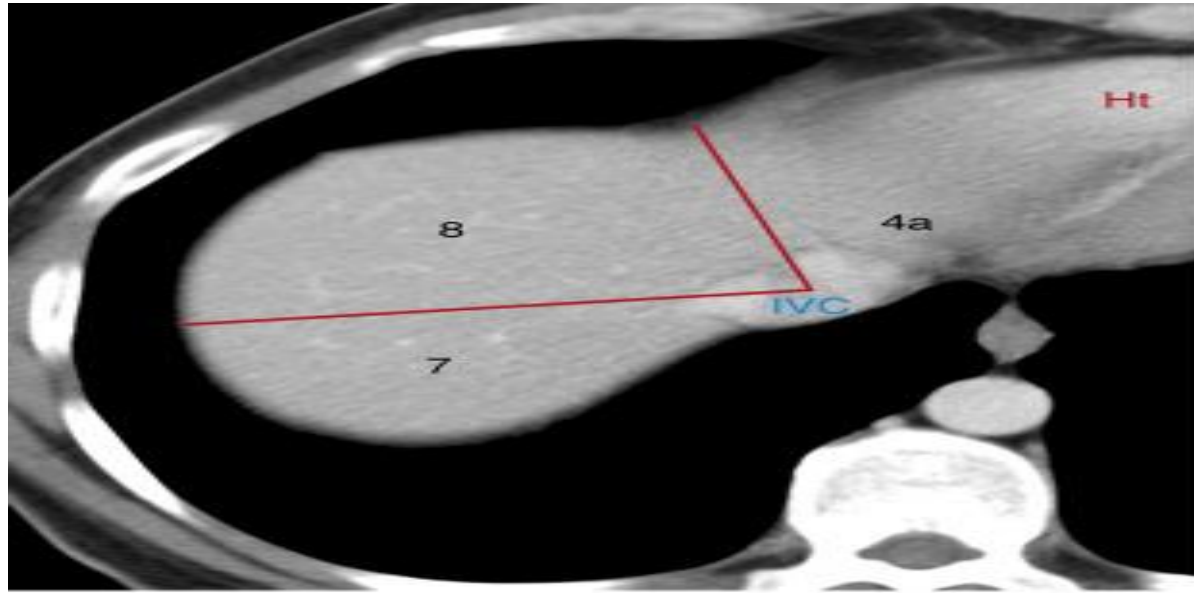
- Short but deep fissure 5cm long extending transversely beneath the left portion of the right lobe of the liver, nearer its posterior surface than its anterior border.
- Separates the quadrate lobe in front from the caudate lobe and process behind.
- It transmits
 - Hepatic duct(ant)
 - Hepatic artery
 - Hepatic portal vein(post)
 - Nerves and lymphatics
- Lies in transduodenal ligament



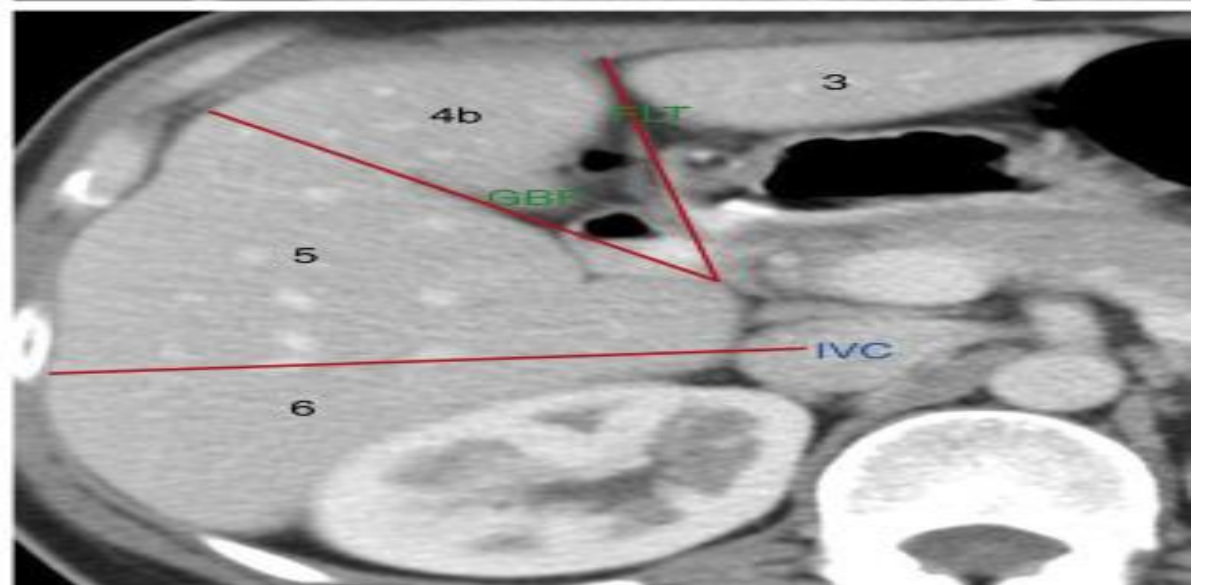
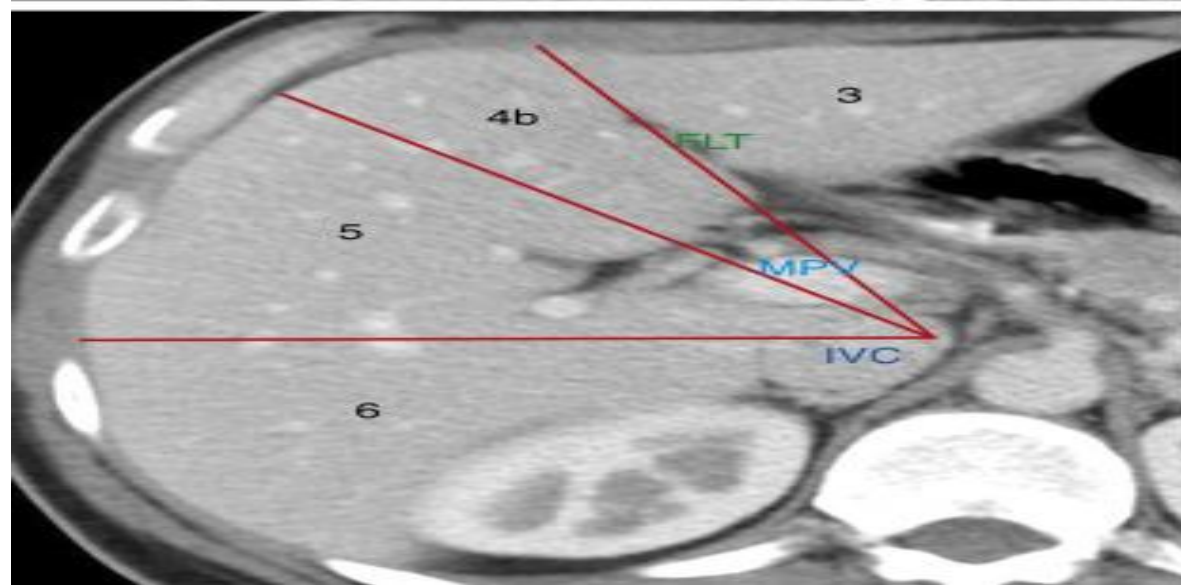
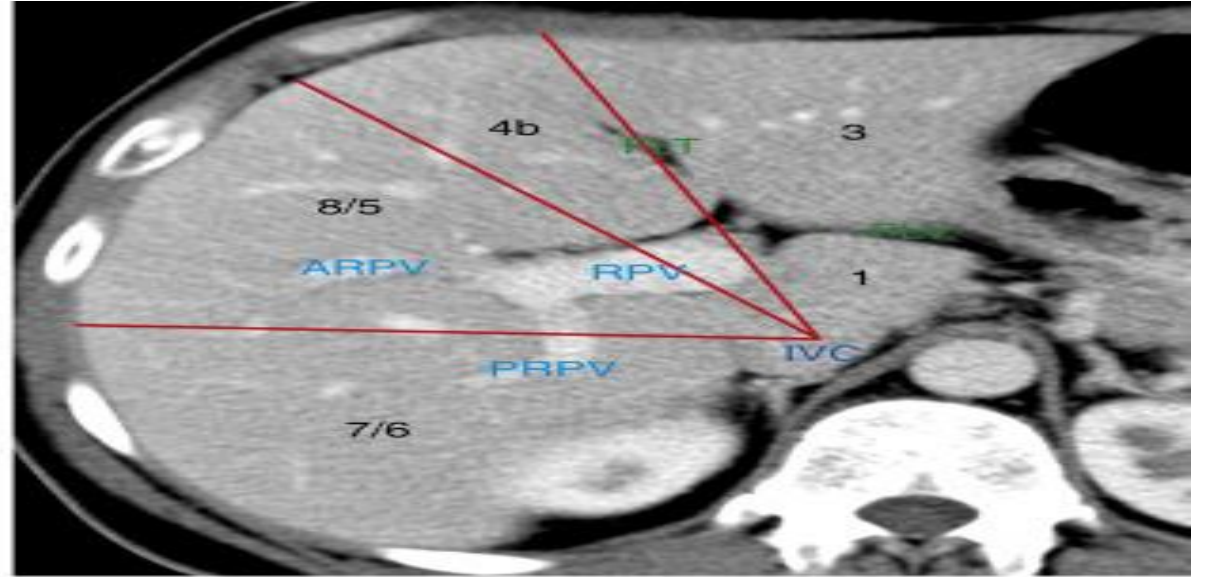
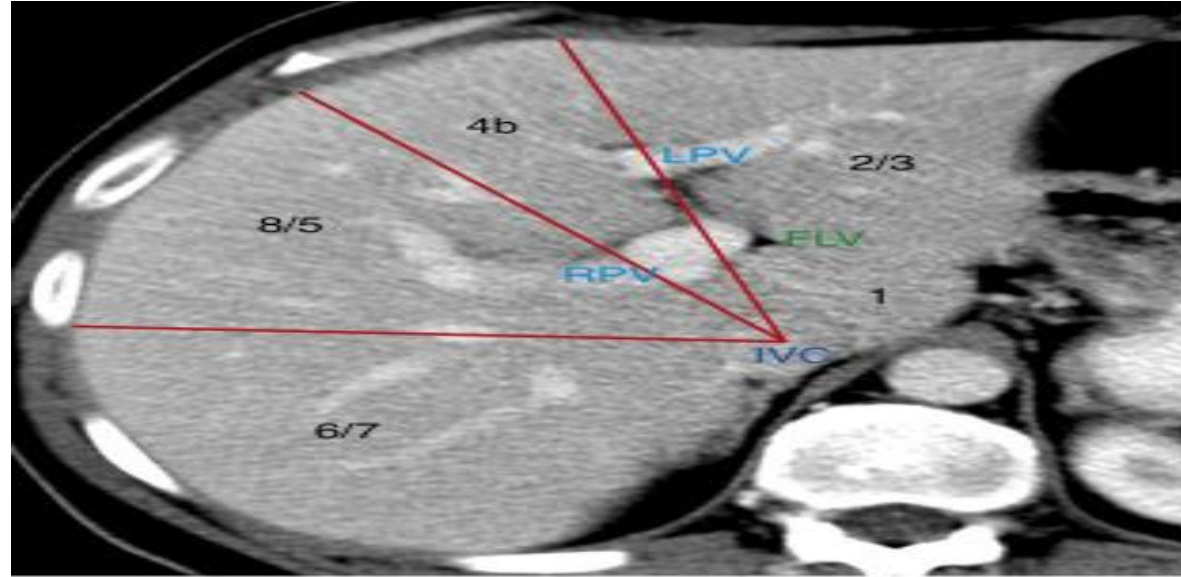
CT Anatomy

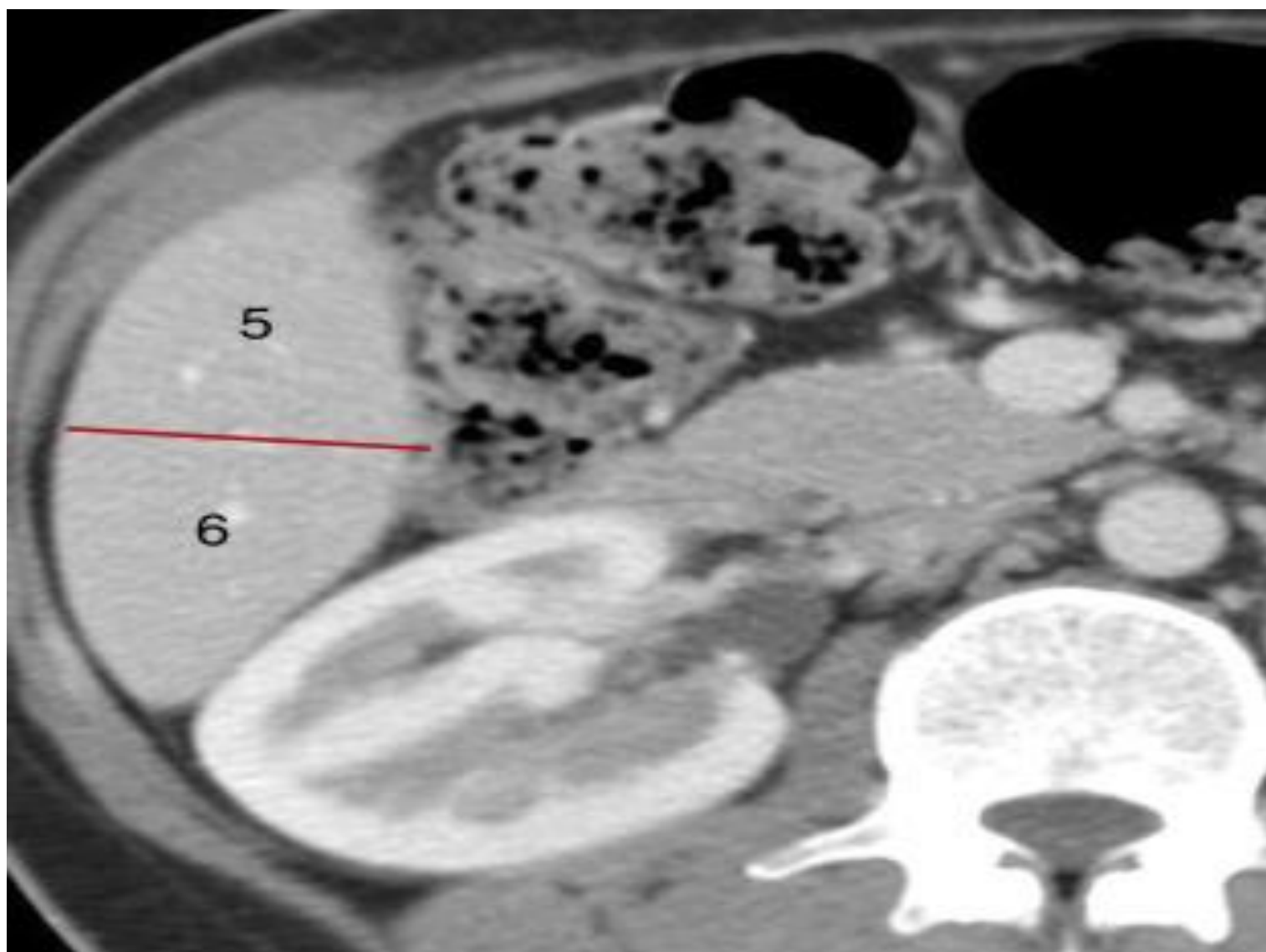


CT Anatomy



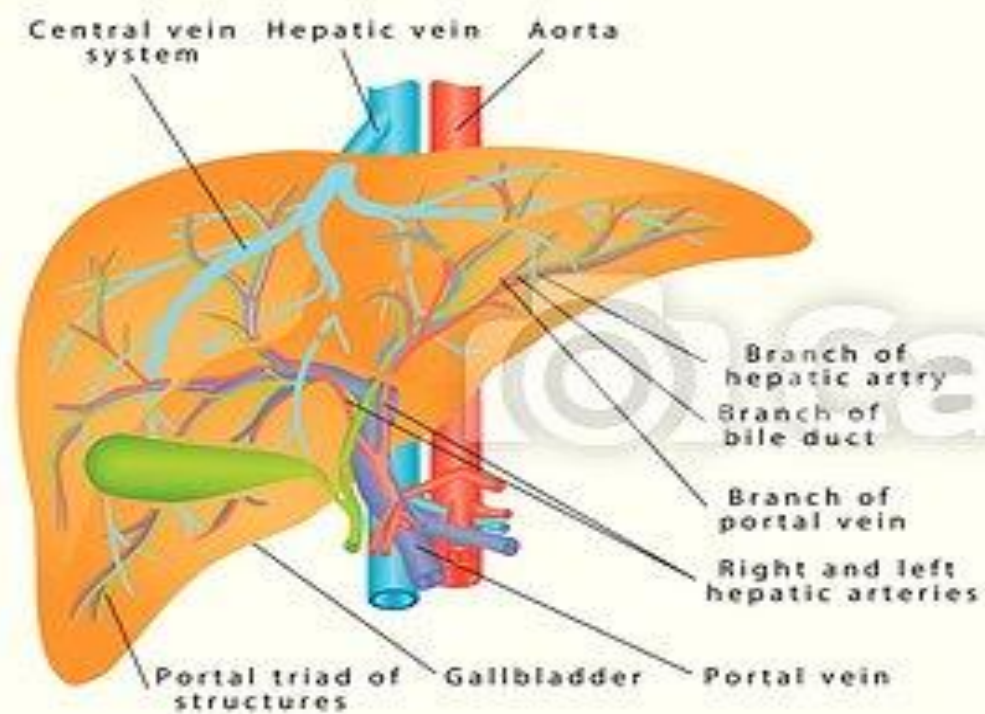
A



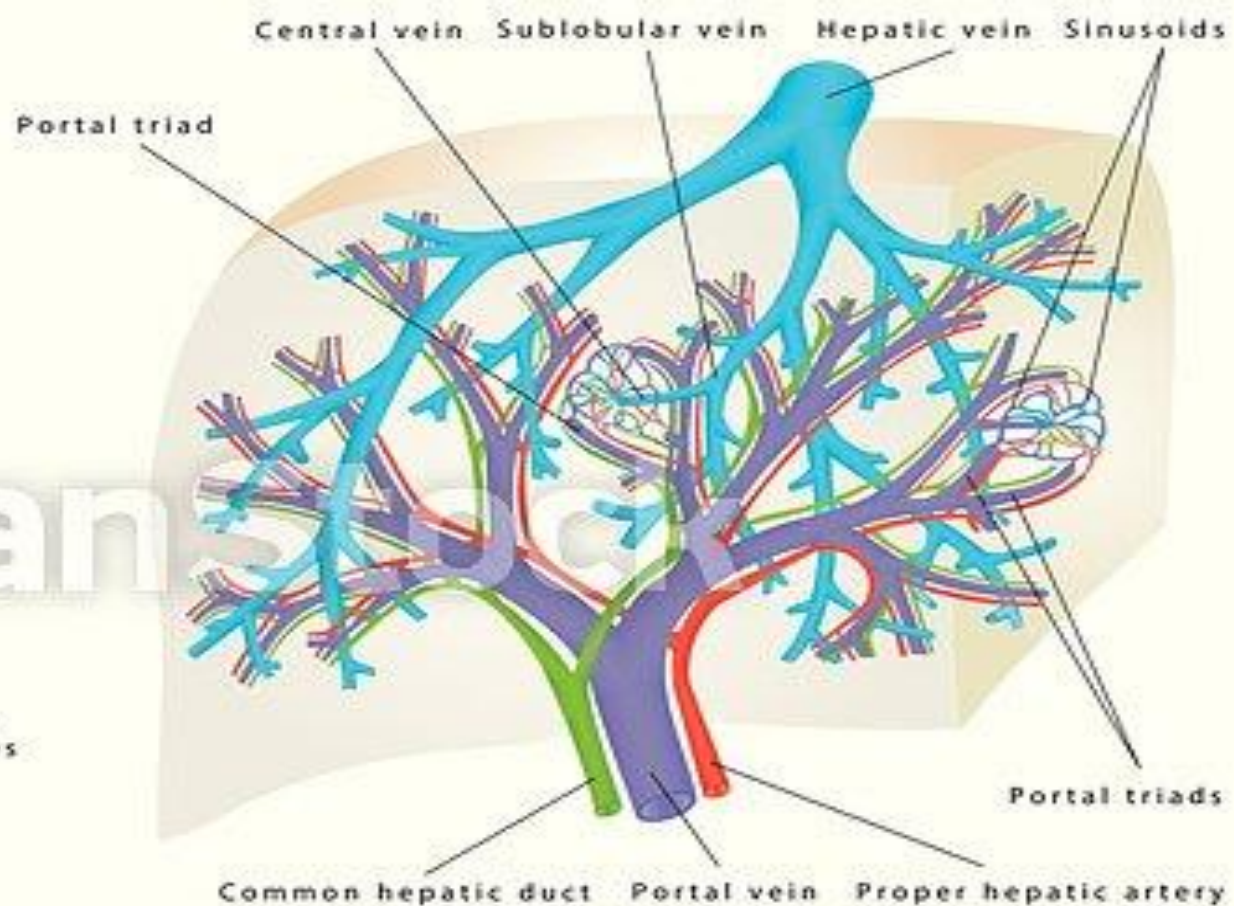


Blood Supply

- Hepatic artery arises from celiac artery at T12 level
 - 20-30% % of hepatic blood flow
- Left gastric and Left hepatic artery (LHA)
- Portal trunk separates in liver hilum into left and right
 - 70-80% of blood flow
- Left vein supplies seg II, III and IV
- Right portal vein branch divides further into two branches: the right anterior portal vein supplying segments V and VIII and the right posterior vein supplying segments VI and VII.

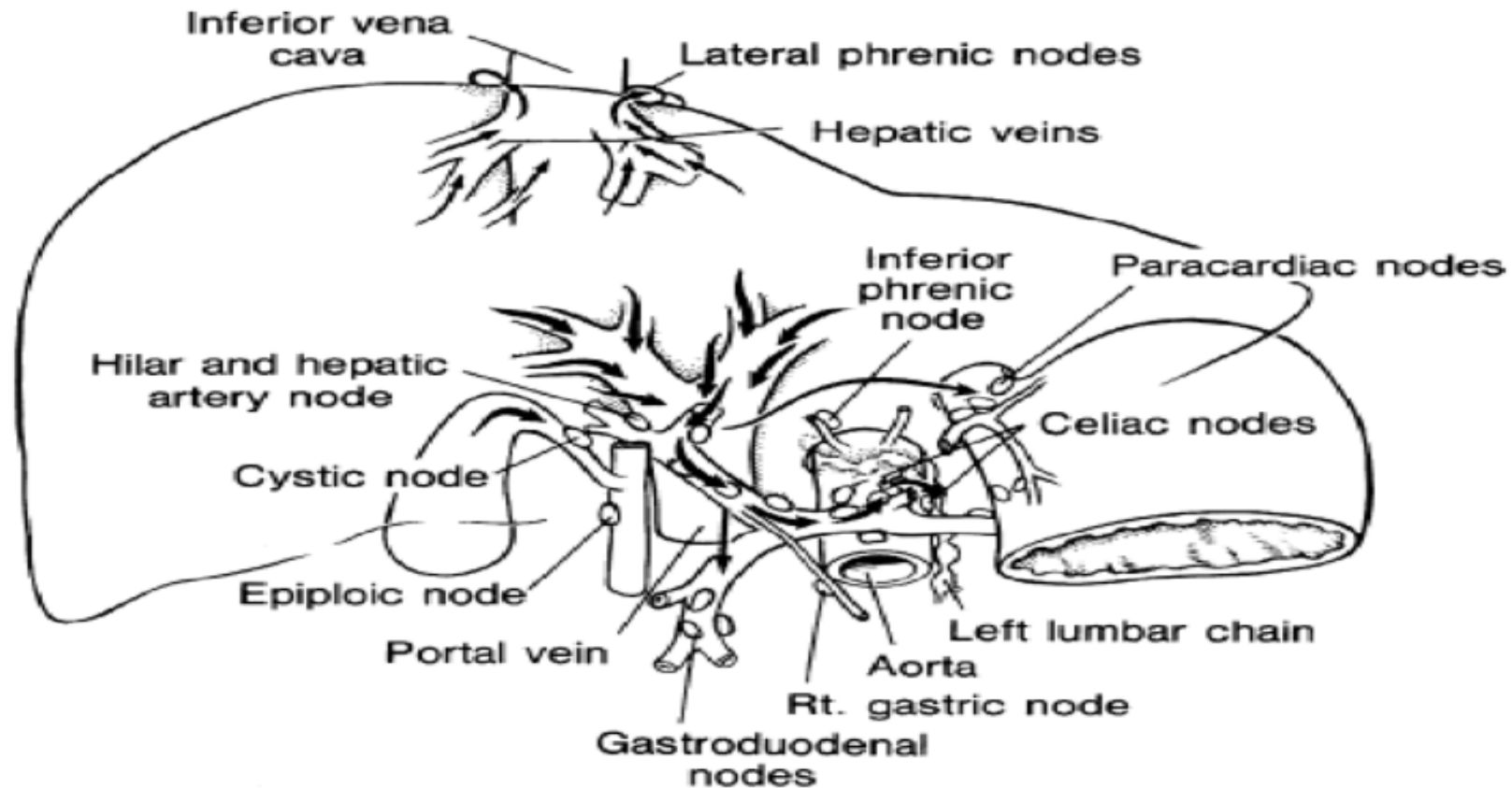


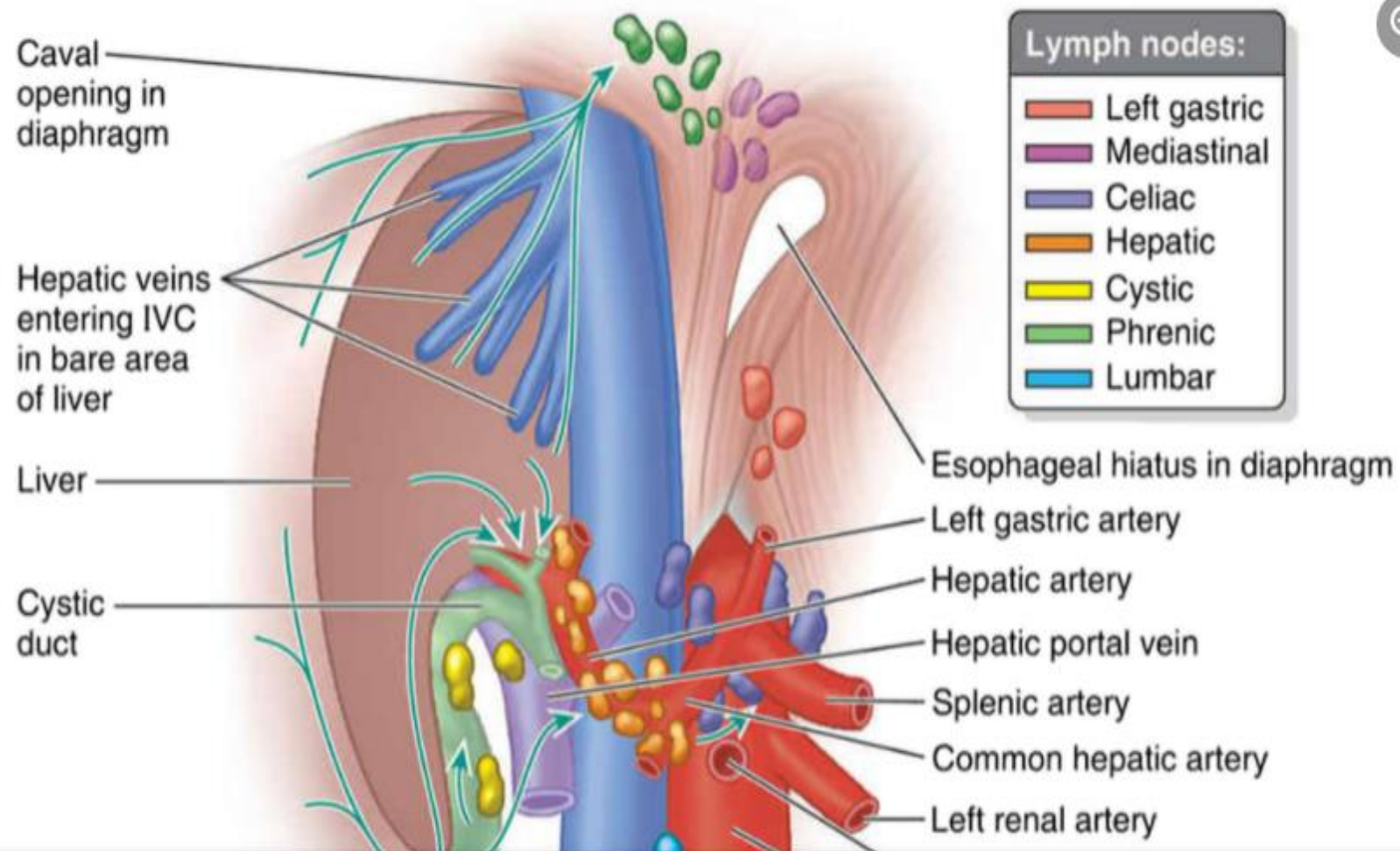
INTERNAL ANATOMY OF LIVER



ANATOMY OF VEINS AND ARTERIES OF THE LIVER

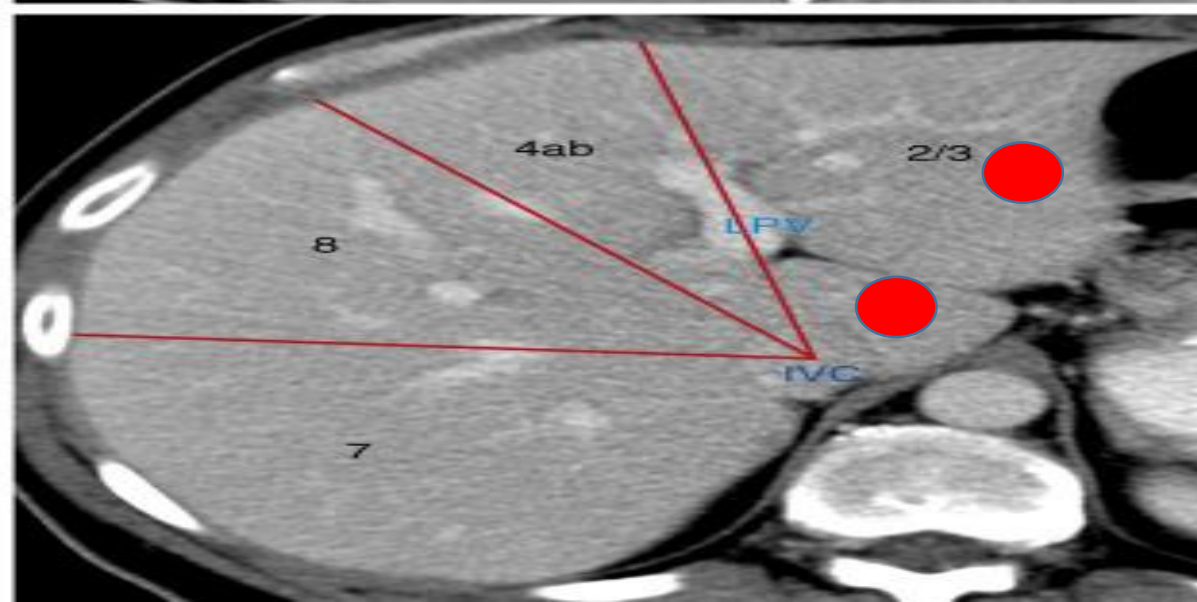
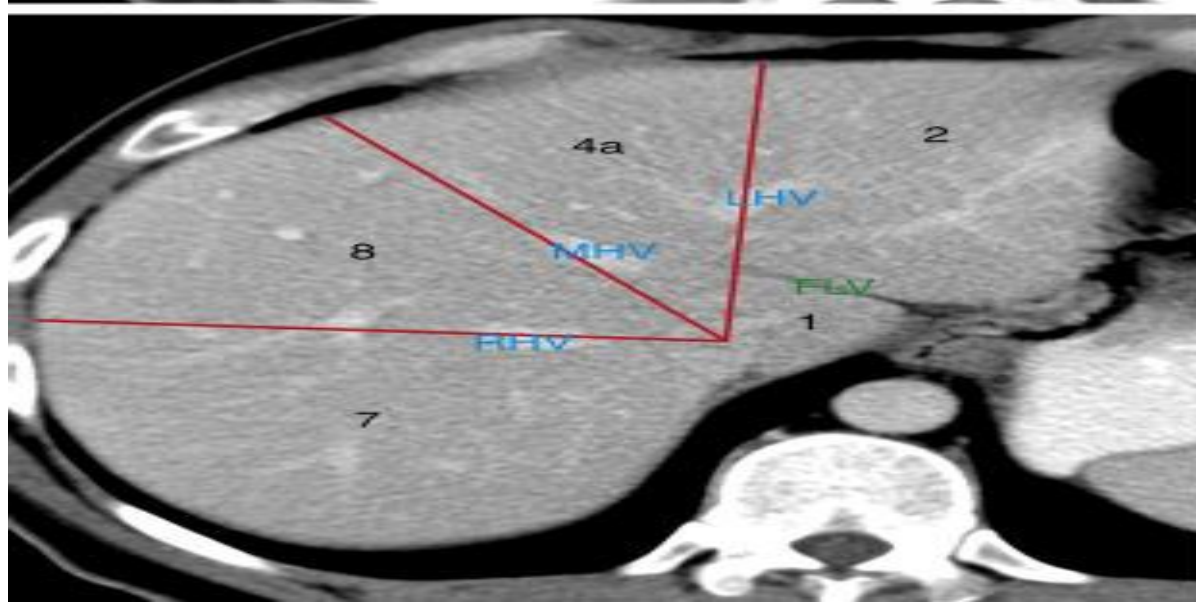
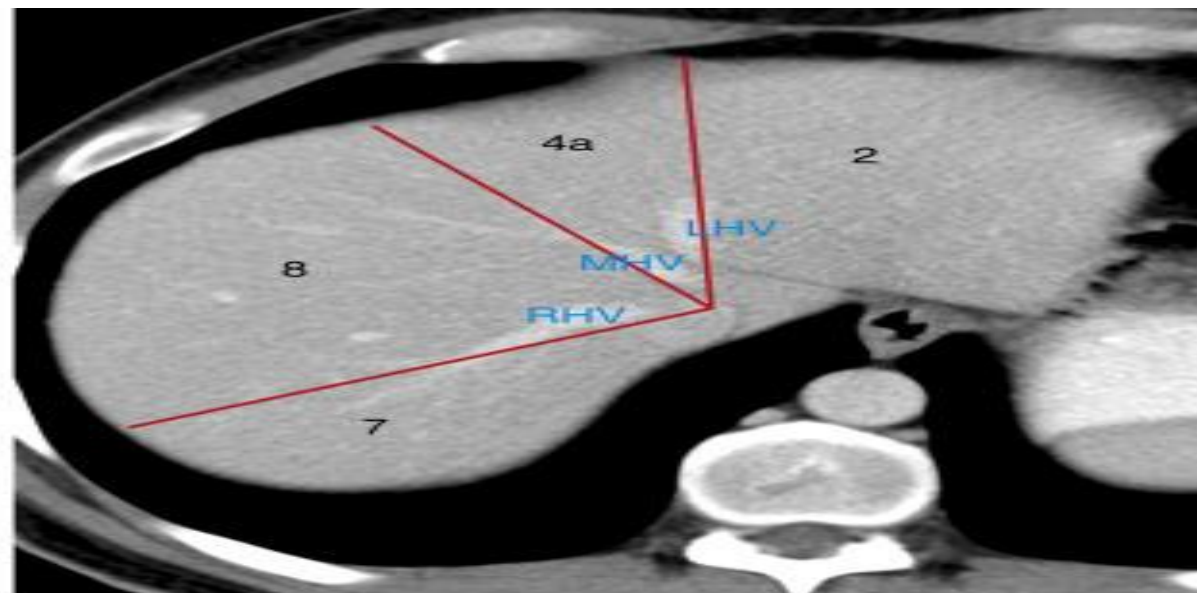
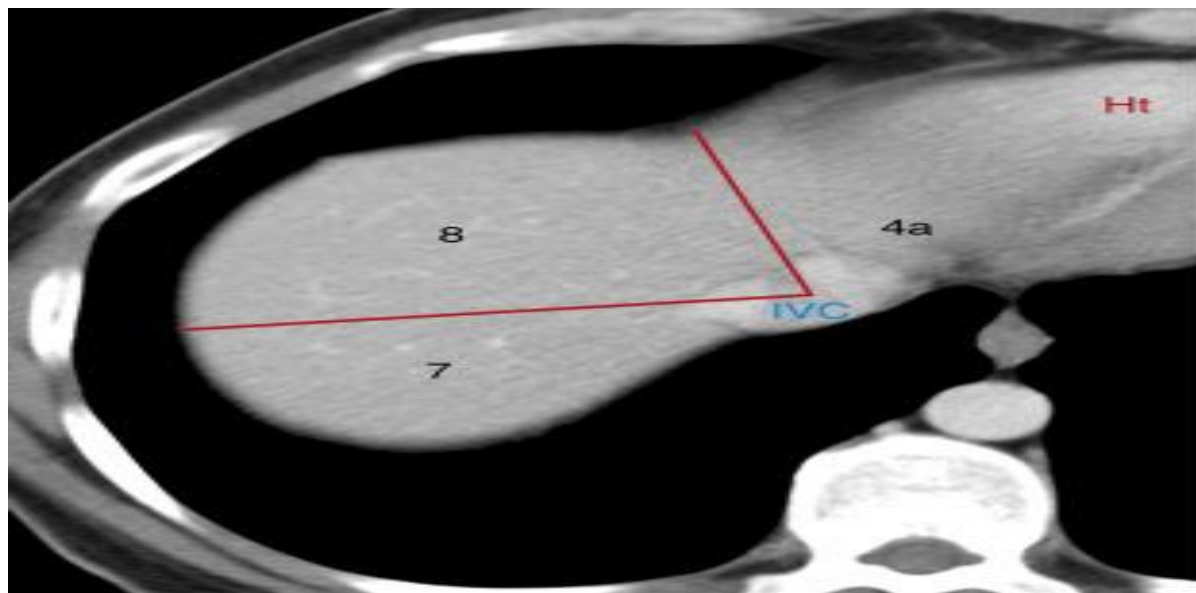
Lymphatic Drainage of Liver

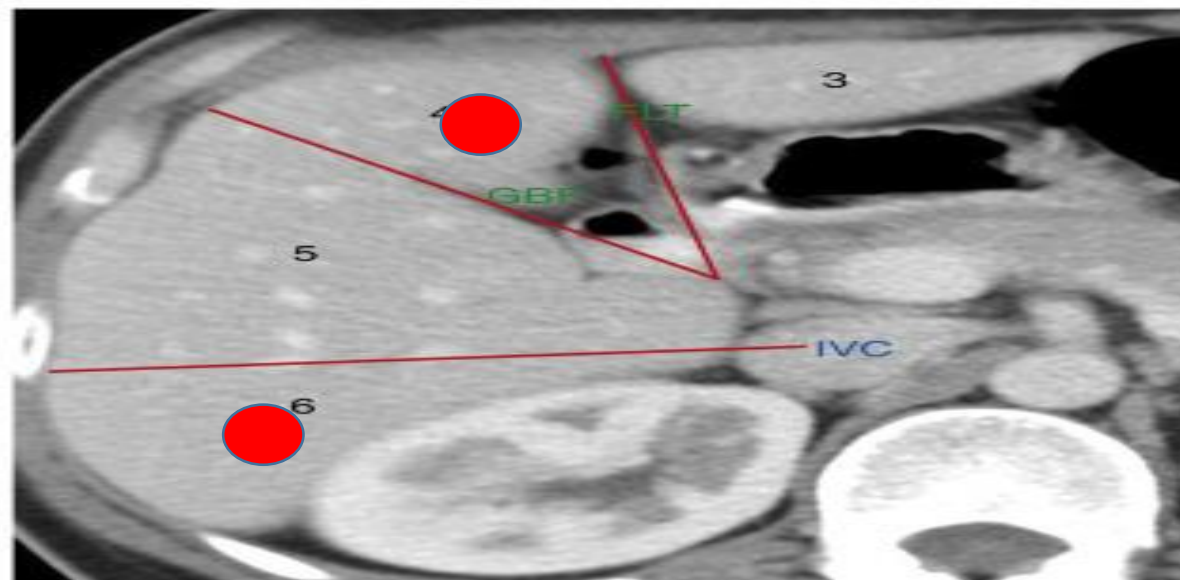
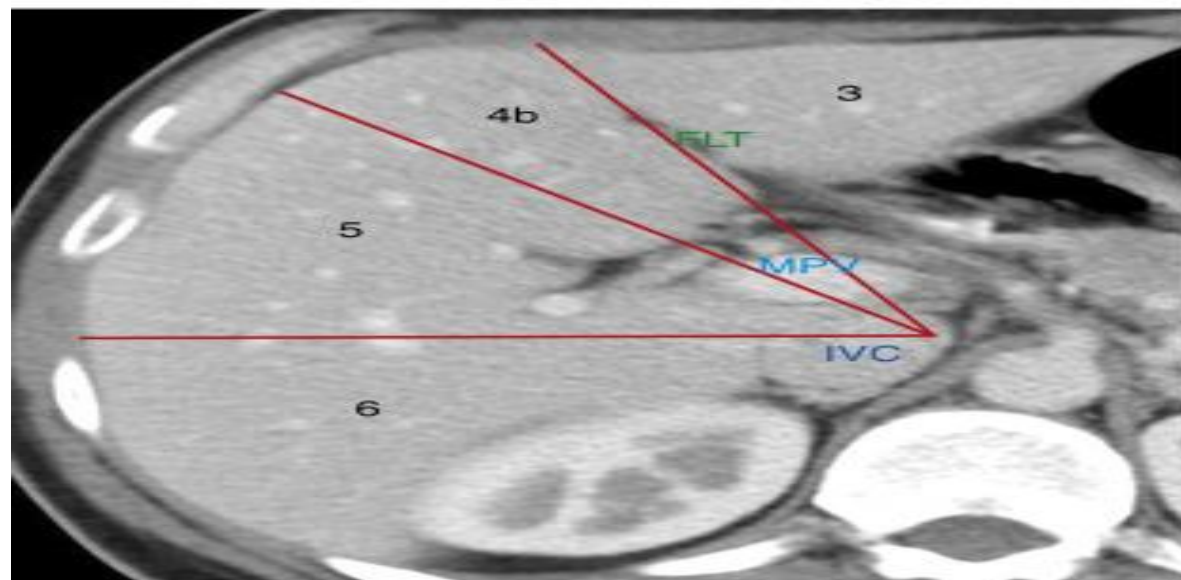
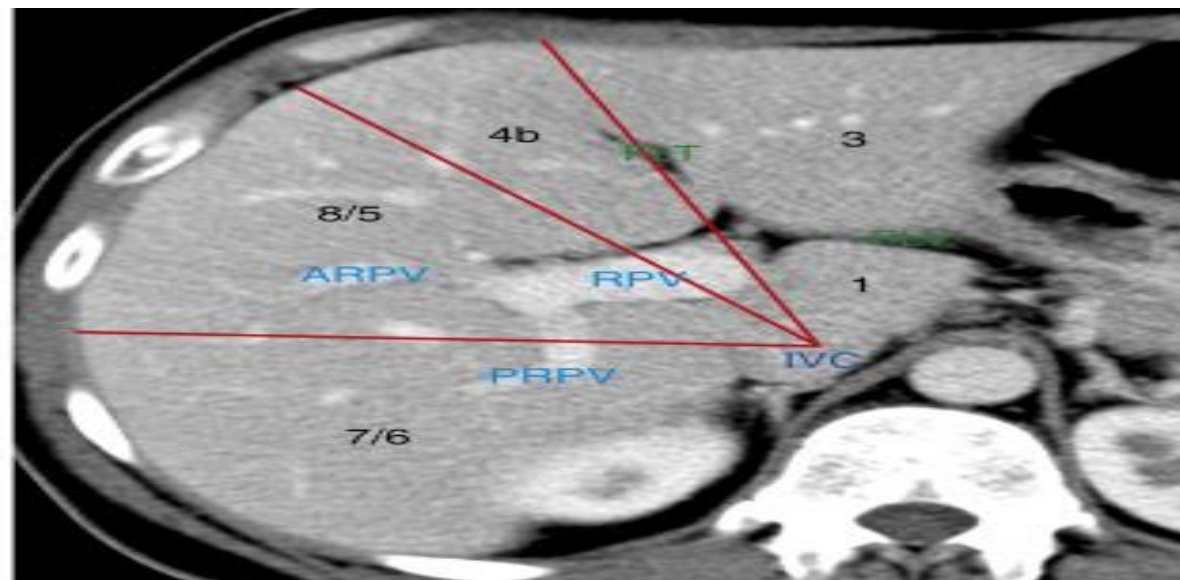
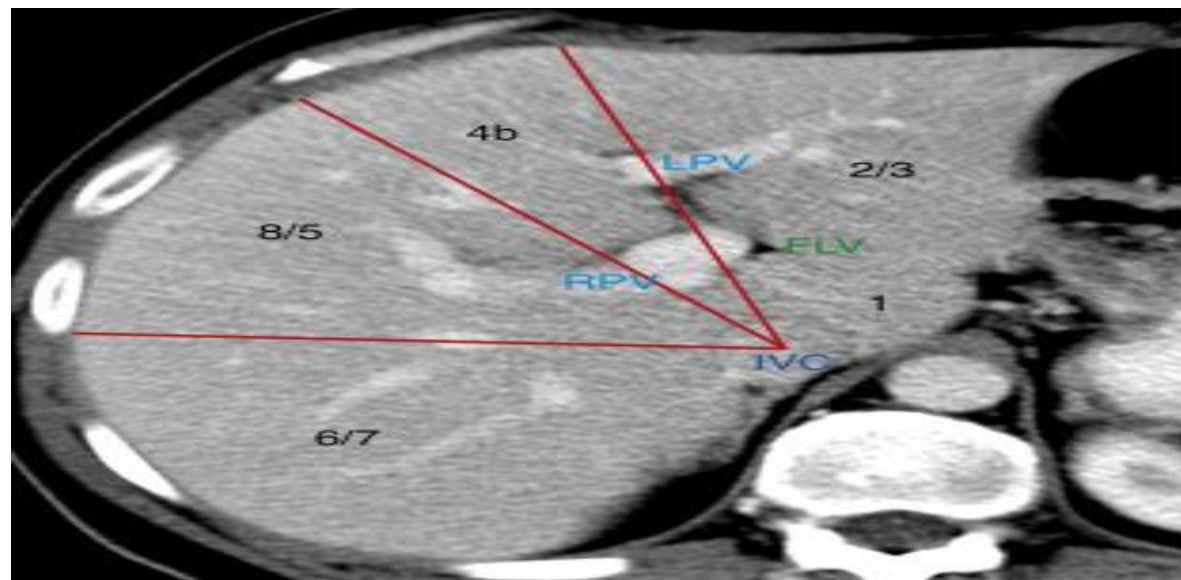


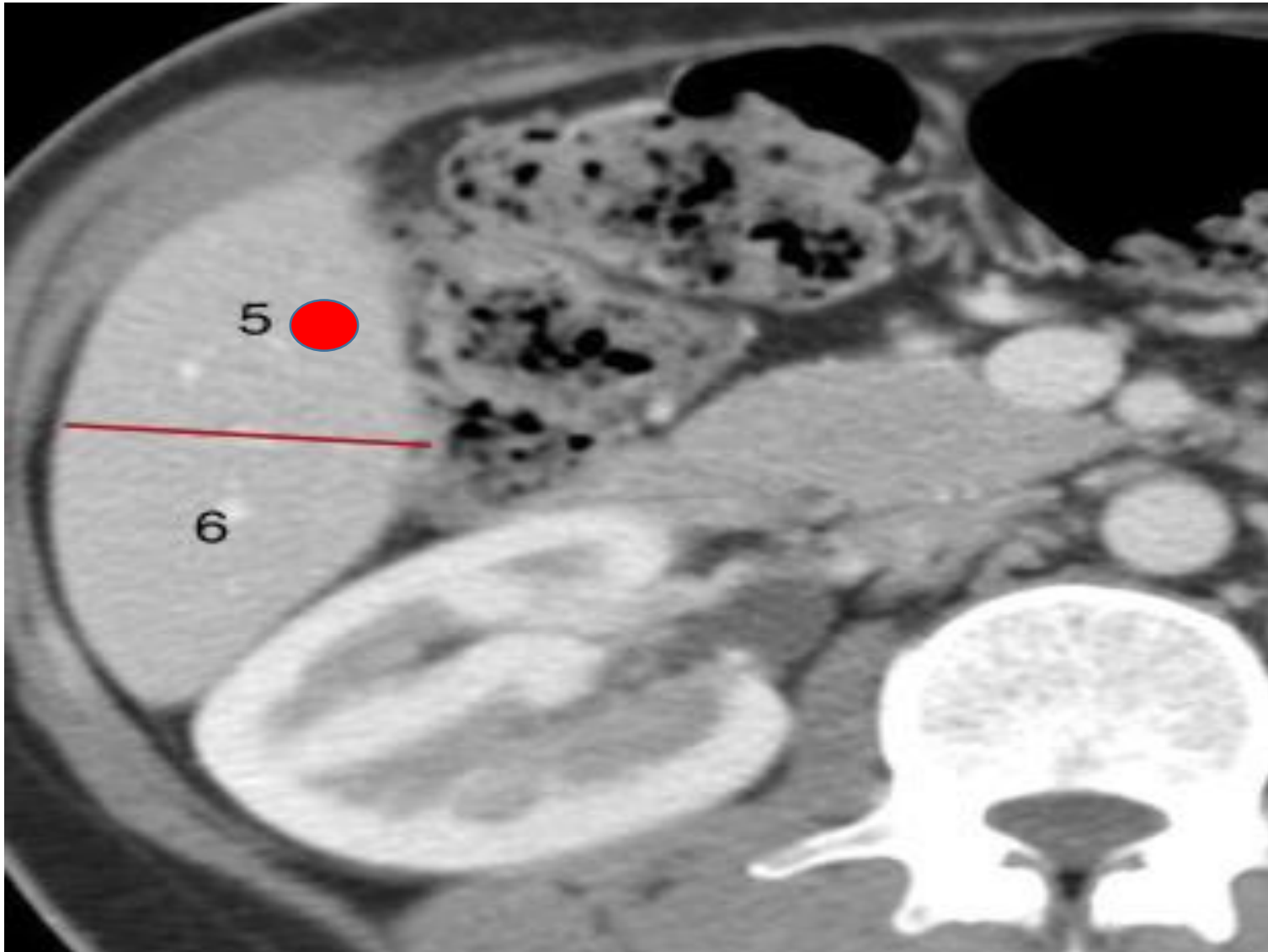


Applied Anatomy

- For SBRT for liver lesions, proximity to porta hepatis has to be assessed
 - MECC defines varying doses accordingly
 - <2cm from porta hepatis: 10Gy*5#
 - >2cm from porta hepatis: 20Gy*3#
- Minimum 5mm distance between liver lesion and any hollow GI organ
- RFA vs SBRT for liver lesions
 - Heat sink effect with RFA if lesion in close proximity to GB or portal vein







Gall Bladder (biliary vesicle)

- Small organ where bile is stored
- Hollow organ, sits just beneath right lobe of liver
- Extends from end of porta hepatis to inf border of liver
- 7-10cm long, 3cm wide, 30 ml capacity

Biliary Tree

Intrahepatic bile ducts

Bile canaliculi

segmental bile ducts (individual liver segment)

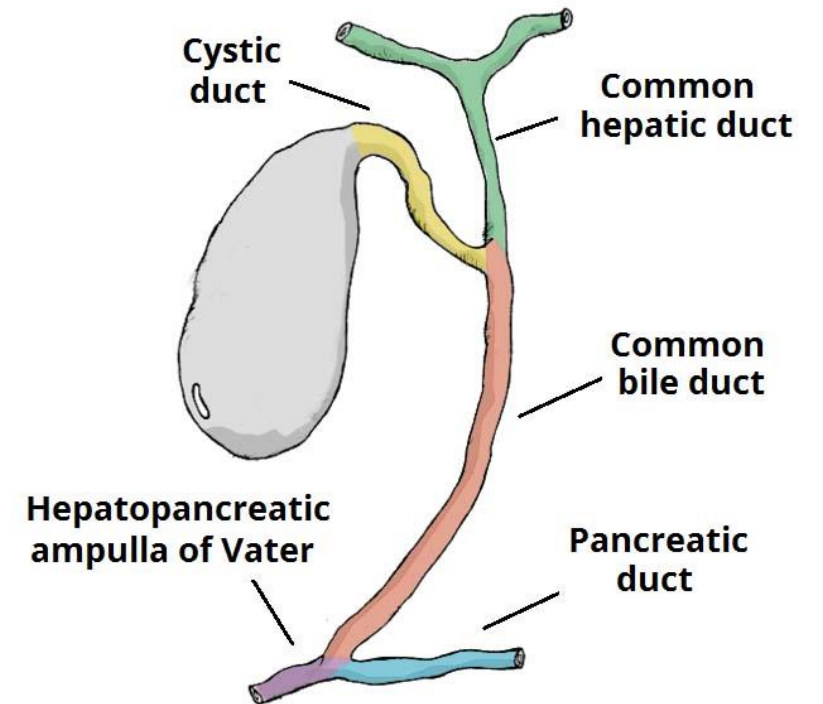
Sectional bile ducts

RPD

RAD

LHD

RHD



Biliary Tree

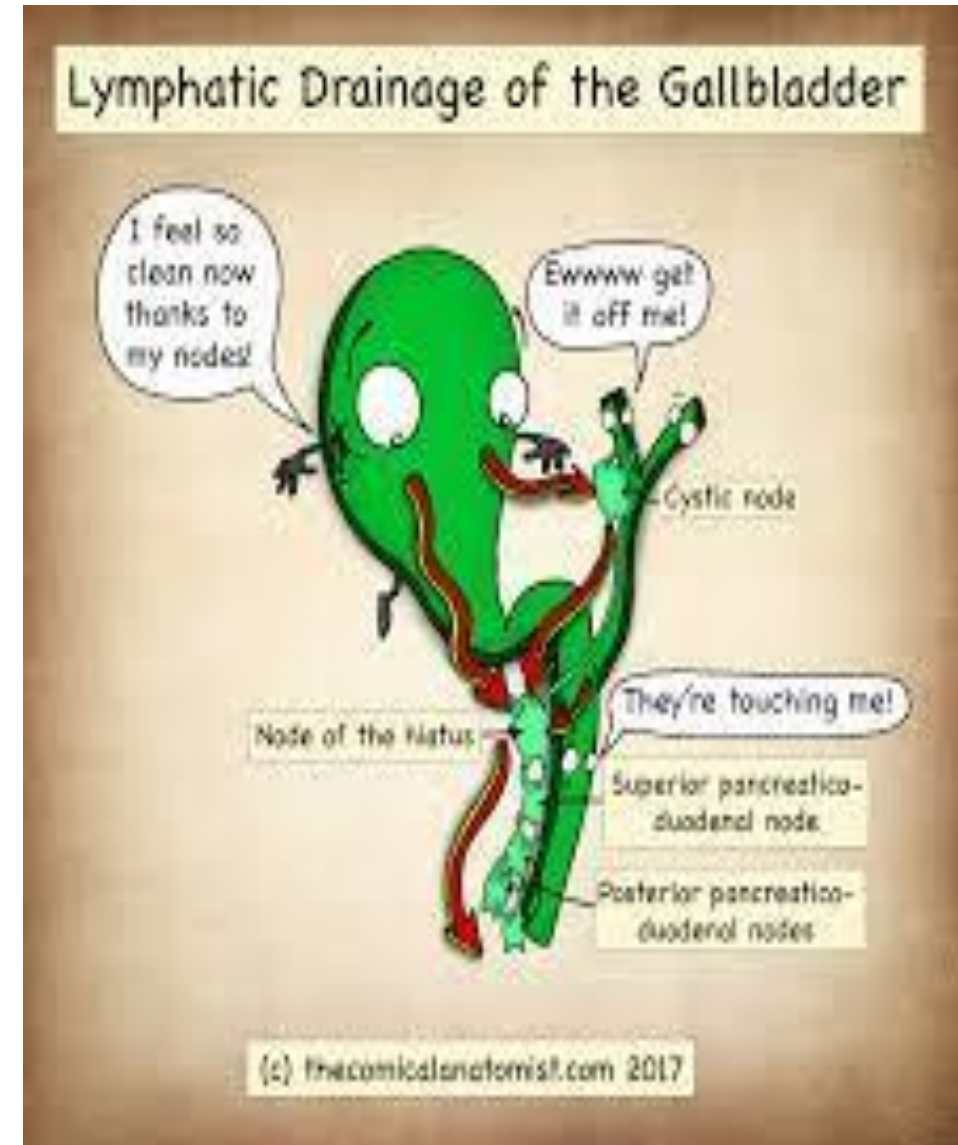
- Bile ducts from segment I drain into the merging point of the RHD and LHD.
- Extra-hepatic bile ducts include the CHD and the cystic duct which combine to form the common bile duct.
- The neck of the gallbladder is attached to the CHD by the cystic duct, draining bile from the biliary tree

Blood Supply and Venous Drainage of GB

- Cystic artery
 - GB
 - Hepatic ducts
 - Cystic duct, upper part of bile duct
- Post sup pancreaticoduodenal a.
 - Lower part of bile duct
- Right hepatic artery
 - Minor part of middle bile duct
- Hepatic vein
 - Sup part of GB
- Right br of Portal vein
 - Rest of GB drained by cystic veins
- Lower part of bile duct drains into portal vein

Lymphatic Drainage of GB

- Lymphatic metastasis is initially to cystic and pericholedochal nodes and then to the pancreaticoduodenal system, with later potential spread to the rest of the celiac axis or the superior mesenteric or aortic nodes




Cholangiocarcinoma

- Intrahepatic (10%)
- Extrahepatic
 - Perihilar (70%) :between secondary biliary radicles and proximal to cystic duct insertion
 - Klatskin tumour : confluence of RHD and LHD
 - Distal (20%) : distal to cystic duct insertion
 - Ampulla of Vater

Bismuth Corlette Classification (Perihilar)

- Type I
- Type IIa
- Type IIIa
- Type IIIb
- Type IV
- Type V

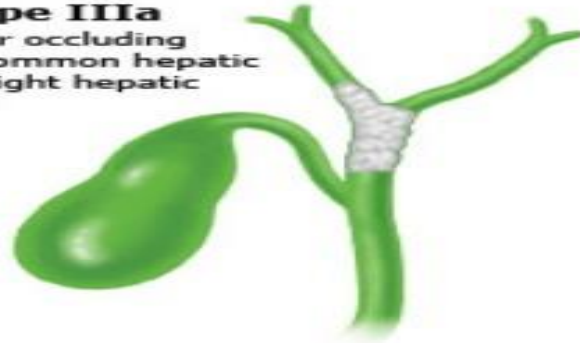Type I
Tumor below the
confluence of the
left and right
hepatic ducts



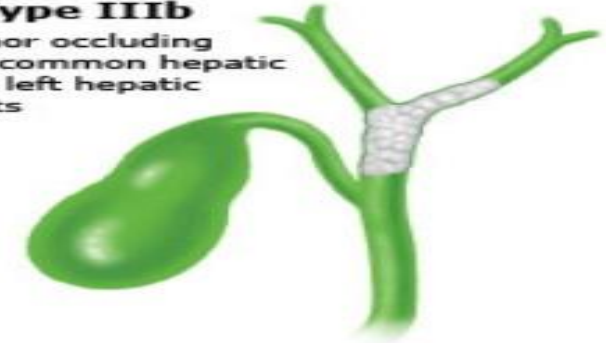Type II
Tumor reaching
the confluence



Type IIIa
Tumor occluding
the common hepatic
and right hepatic
ducts




Type IIIb
Tumor occluding
the common hepatic
and left hepatic
ducts



Type IV
Tumor that involves
the confluence and
both the right or
left hepatic
duct

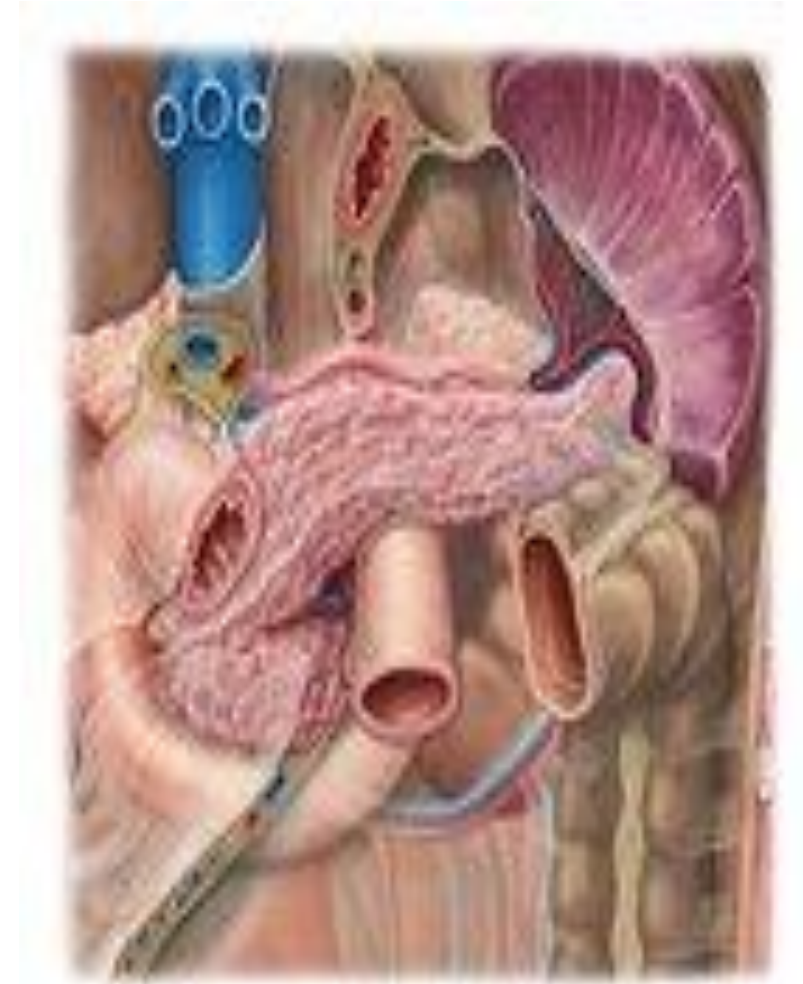

Type IV
Tumors that are
multicentric



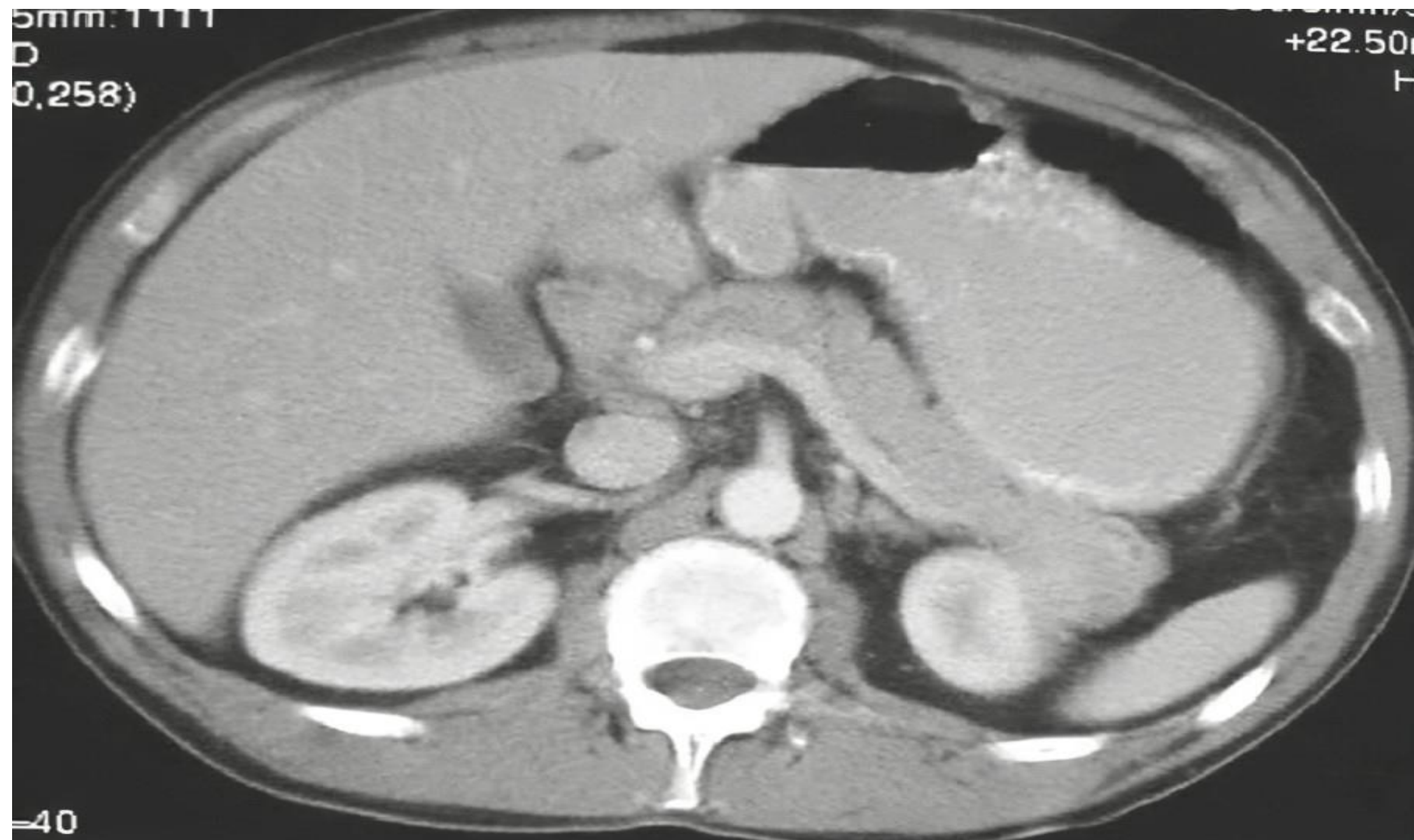Pancreas

- Retroperitoneal organ at L1-L2 level.
- Accessory organ, exocrine and endocrine gland
- 5 parts: head (including the part called uncinate process), neck, body, and tail
- Intimate contact with surrounding organs, including stomach, duodenum, jejunum, kidneys, and spleen as well as major vessels, which can be involved by direct tumor extension.
- Tumors in the head of the pancreas often invade or compress the common bile duct, causing jaundice and dilatation of the bile ducts and gallbladder.

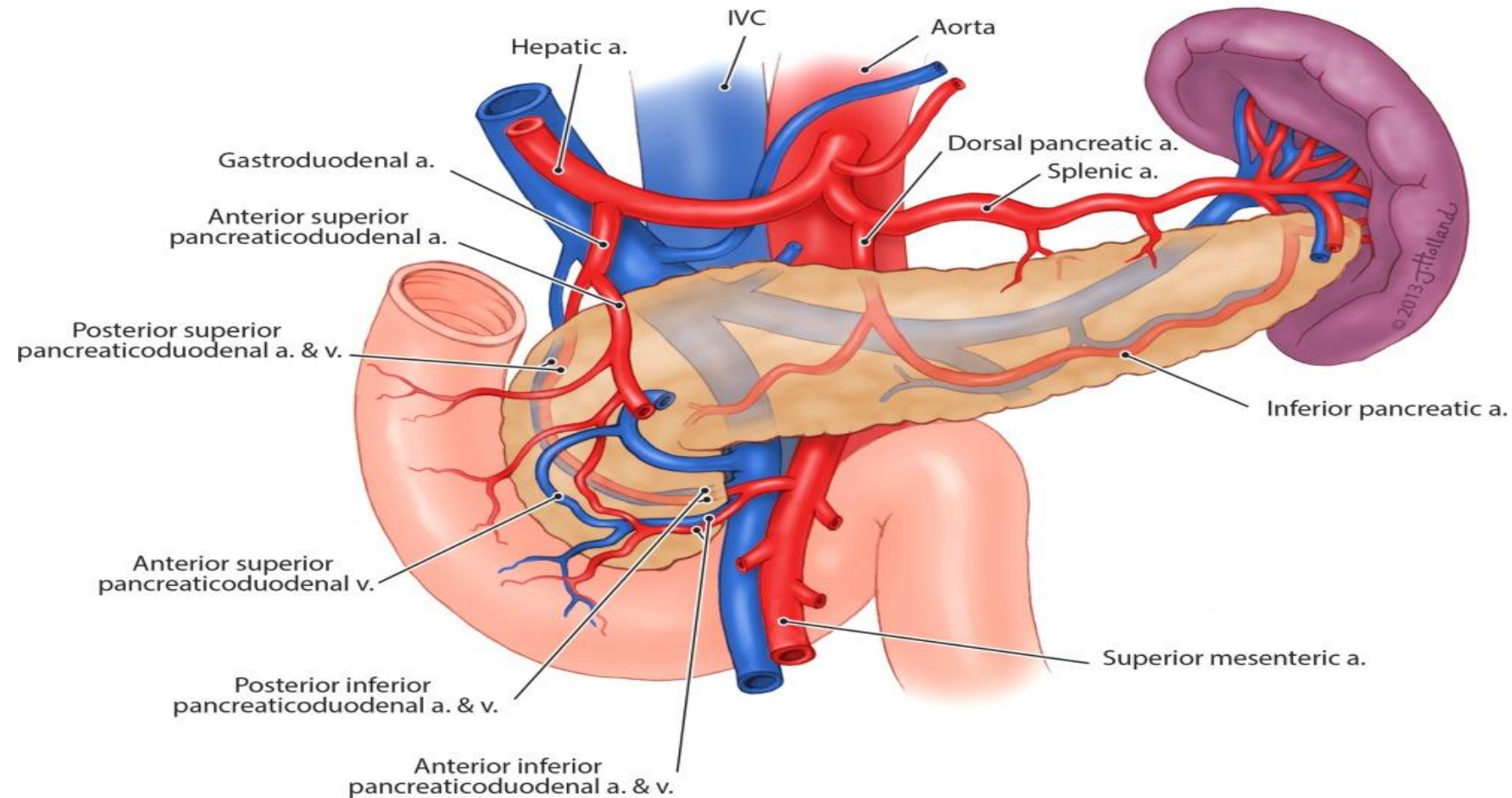


5mm:1111
D
0.258)

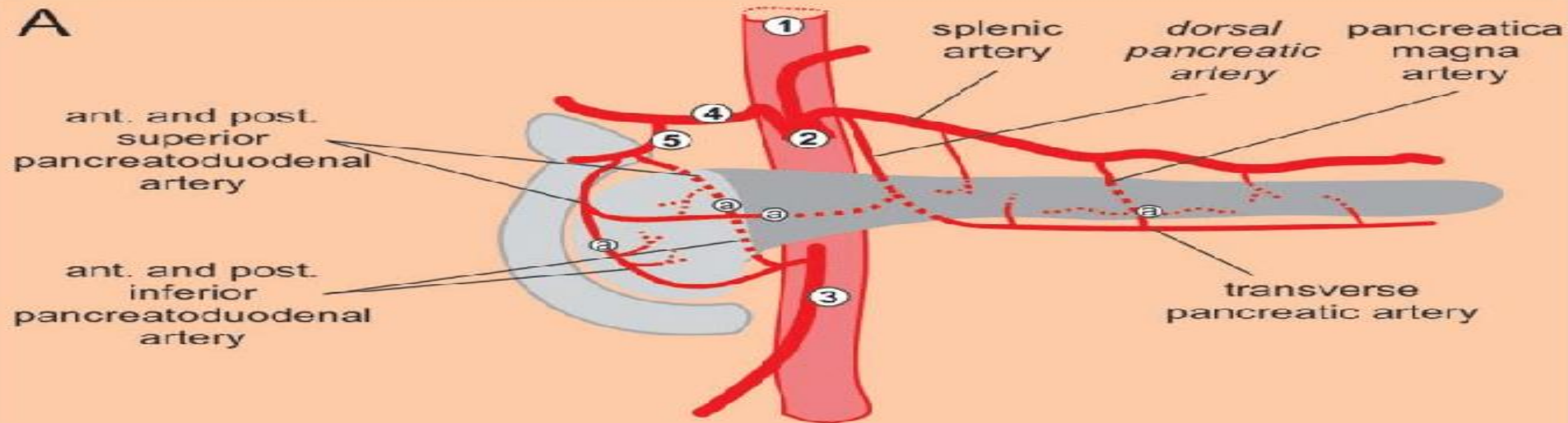
+22.50
H



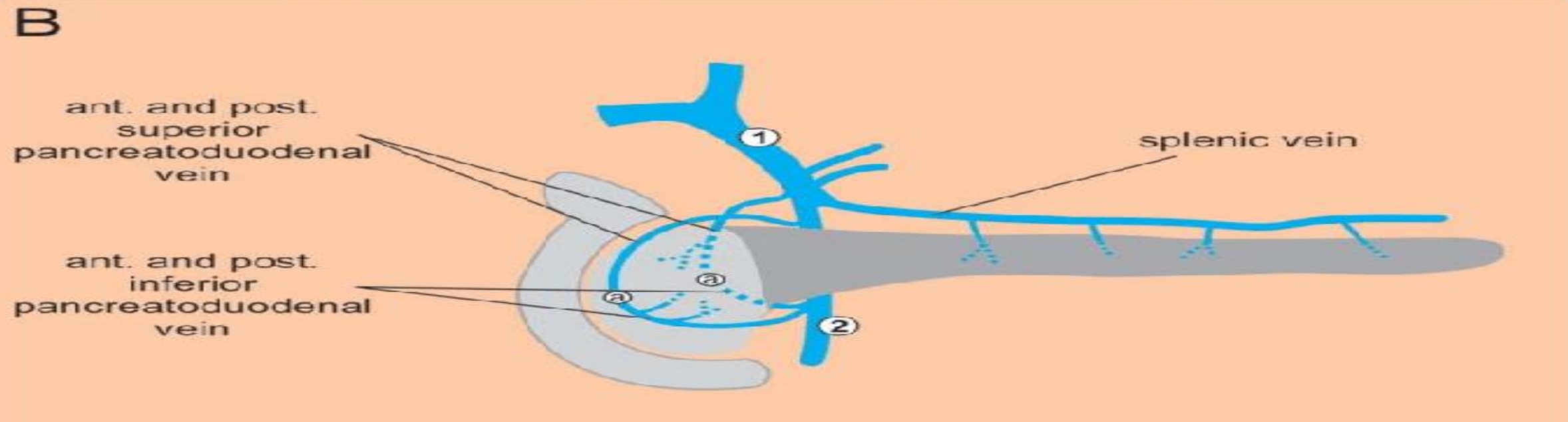
Blood Supply



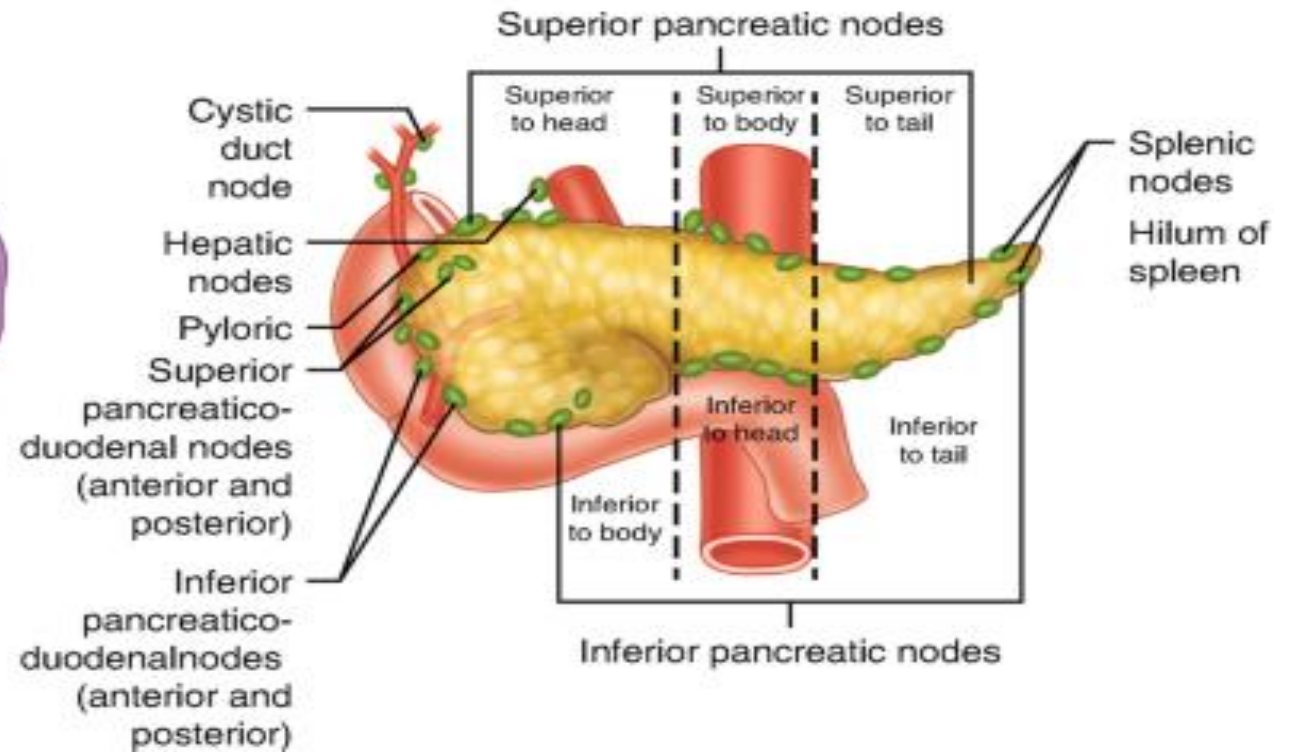
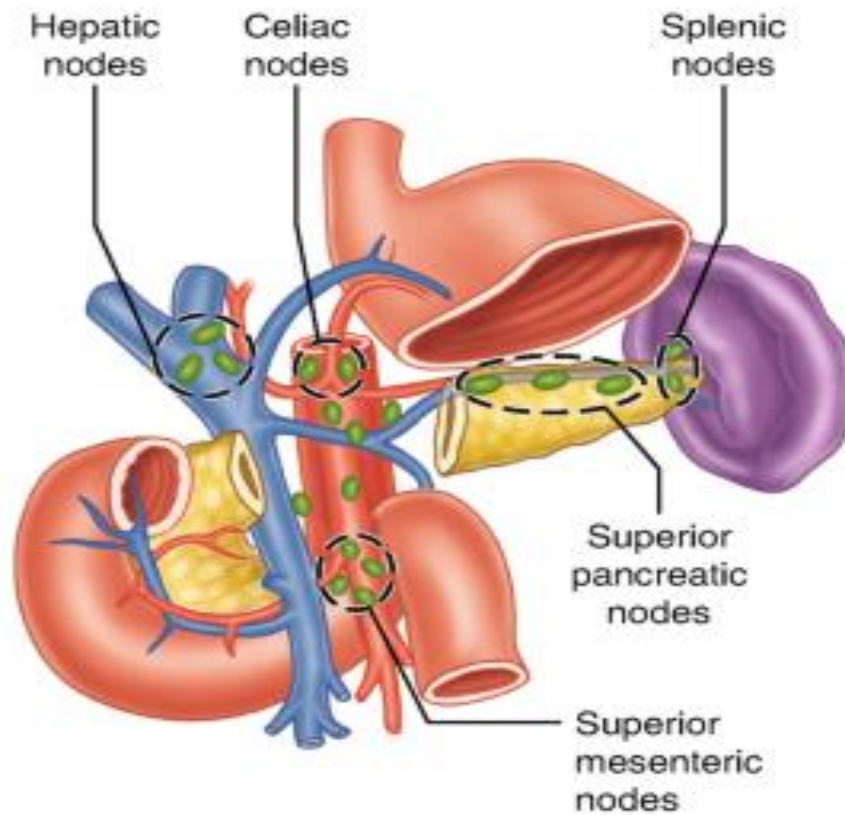
A



B

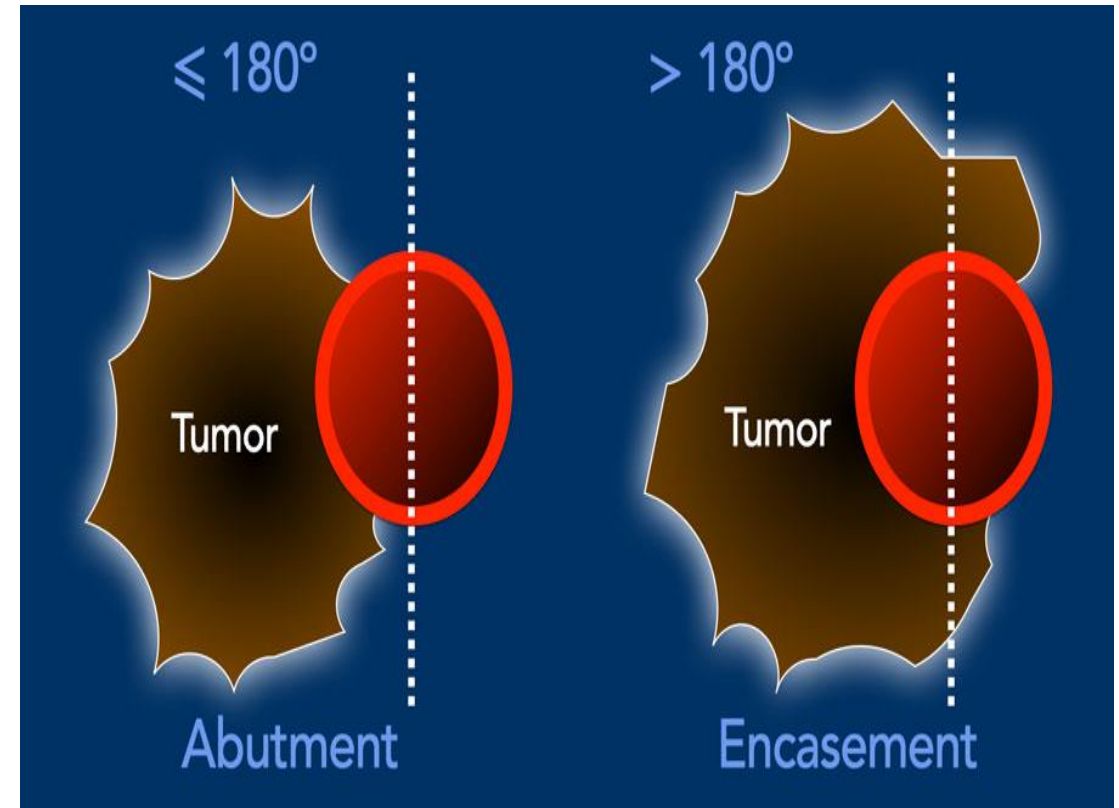


Lymphatic Drainage



NCCN resectability criteria

Resectable	Borderline	Irresectable
Arterial	<i>Head/uncinate process:</i>	<i>H/U process:</i>
No contact	- Solid tumor contact with CHA without extension to CA or hepatic artery bifurcation or abutment and no extension to the SMA or variant artery*	> 180° SMA or CA
	<i>Body/tail:</i>	<i>Body/tail:</i>
	- Abutment ($\leq 180^\circ$) to the celiac axis or encasement of the celiac axis without involvement of the aorta or gastroduodenal a.	> 180° SMA or CA or $\leq 180^\circ$ CA and aortic involvement
Venous	> 180° or with contour irregularity / thrombosis	> 180° or with contour irregularity or thrombosis
$\leq 180^\circ$ without contour irregularity	<i>resection & reconstruction possible</i>	<i>r & r <u>not</u> possible</i>



Applied Anatomy

- For adjuvant RT in ca pancreas, high risk of recurrence around CA and SMA,
 - CTV should include these regions along with preop tumour volume
- For tumour involving tail of pancreas, splenic nodes should be included in the CTV.

To summarise....

- Liver, GB , biliary tree and pancreas.. closely associated organs
 - Complimentary physiological association
- Good anatomical understanding helps in appropriate management of malignancies
- Blood supply and lymphatic drainage are important considerations while considering radiotherapy planning

Thank you!