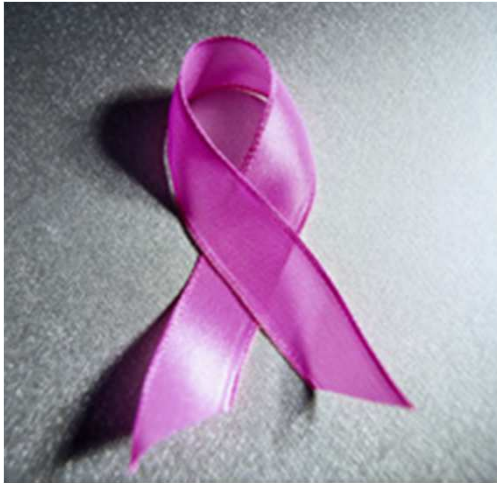

IGRT in breast cancer: need or fashion?



Dr. Devang Bhavsar

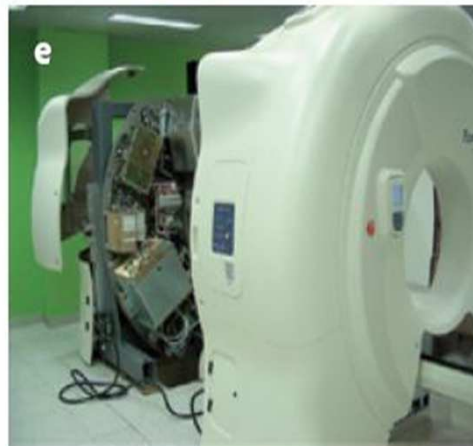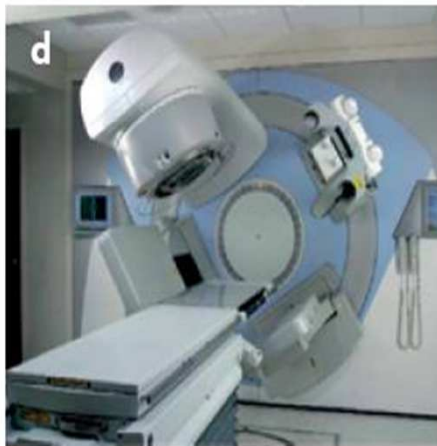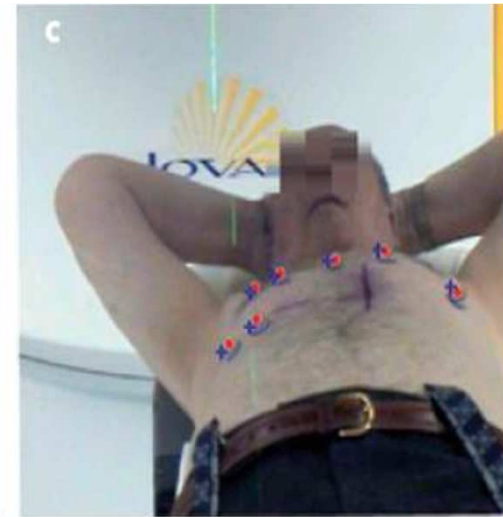
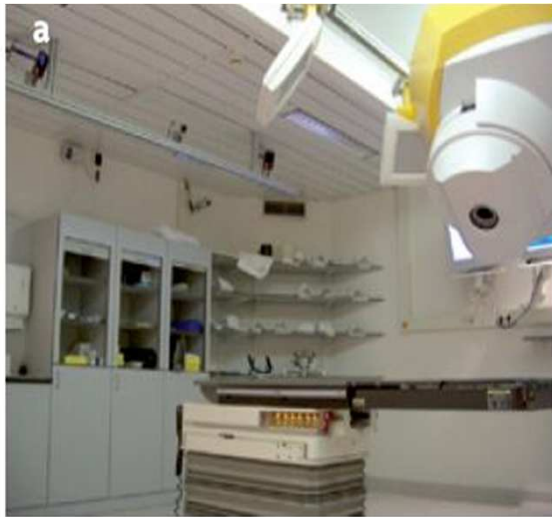Asso. Proff.

Dept of radiation oncology

The Gujarat cancer and research institute

1. What is IGRT? History.
2. Need of IGRT in breast cancer?
3. IGRT preliminary work done.

What is IGRT:



Definition :

- **Image-guided radiation therapy (IGRT)** is the process of frequent or daily two and three-dimensional imaging, during a course of radiation treatment, used to direct radiation therapy utilizing the imaging coordinates of the actual radiation treatment plan. The patient is localized in the treatment room in the same position as planned from the reference imaging dataset.

IGRT:

- Three-dimensional (3D) IGRT would include localization of a cone-beam computed tomography (CBCT) dataset with the planning computed tomography (CT) dataset from planning.
- Similarly Two-dimensional (2D) IGRT would include matching planar kilovoltage (kV) radiographs fluoroscopy or megavoltage (MV) images with digital reconstructed radiographs (DRRs) from the planning CT.

Goal and clinical benefits:

- The goal of the IGRT process is to improve the accuracy of the radiation field placement, and to reduce the exposure of healthy tissue during radiation treatments.
- In years past, larger planning target volume (PTV) margins were used to compensate for localization errors during treatment.

Tumor control

- TCP and NTCP.
- Close relation between tumor/target and critical organ (OAR) like spine, heart, lung.)
- Dose escalation and increase chances of TCP and also at same fair chances to produce irreversible damage to normal surrounding tissue.

History:

- Radiation therapy is a local treatment that is designed to treat the defined tumor and spare the surrounding normal tissue from receiving doses above specified dose tolerances.
- There are many factors that may contribute to differences between the planned dose distribution and the delivered dose distribution.

History:

- Early days without technology support.
- First study on positioning and immobilization, by Haus, showed reduction in error from 36 to 15 %.
- X-ray tube in linac or cobalt room.
- Image registration and automation.
- Conformal radiotherapy set up is imp.

Recent :

- Portal imaging fluorescent screen and camera combination.
- EPID.
- Matrix ionization .
- Amorphus sillicon.
- Online as well off line verification.

Newer techniques

- 2-D images .
- Surrogate marker.
- Bone match v/s marker.
- So need of 3-D imaging on board.
- Cone beam CT scan and MV CT scan.
- US guided.

Still ?? Precision.. Not achieved

- Breathing.
- Heart movement.
- Abdominal structure movement, bowel gas and bladder position.
- Need 4-D CT scan.
- Breath holding, respiratory gating, real time tracking.

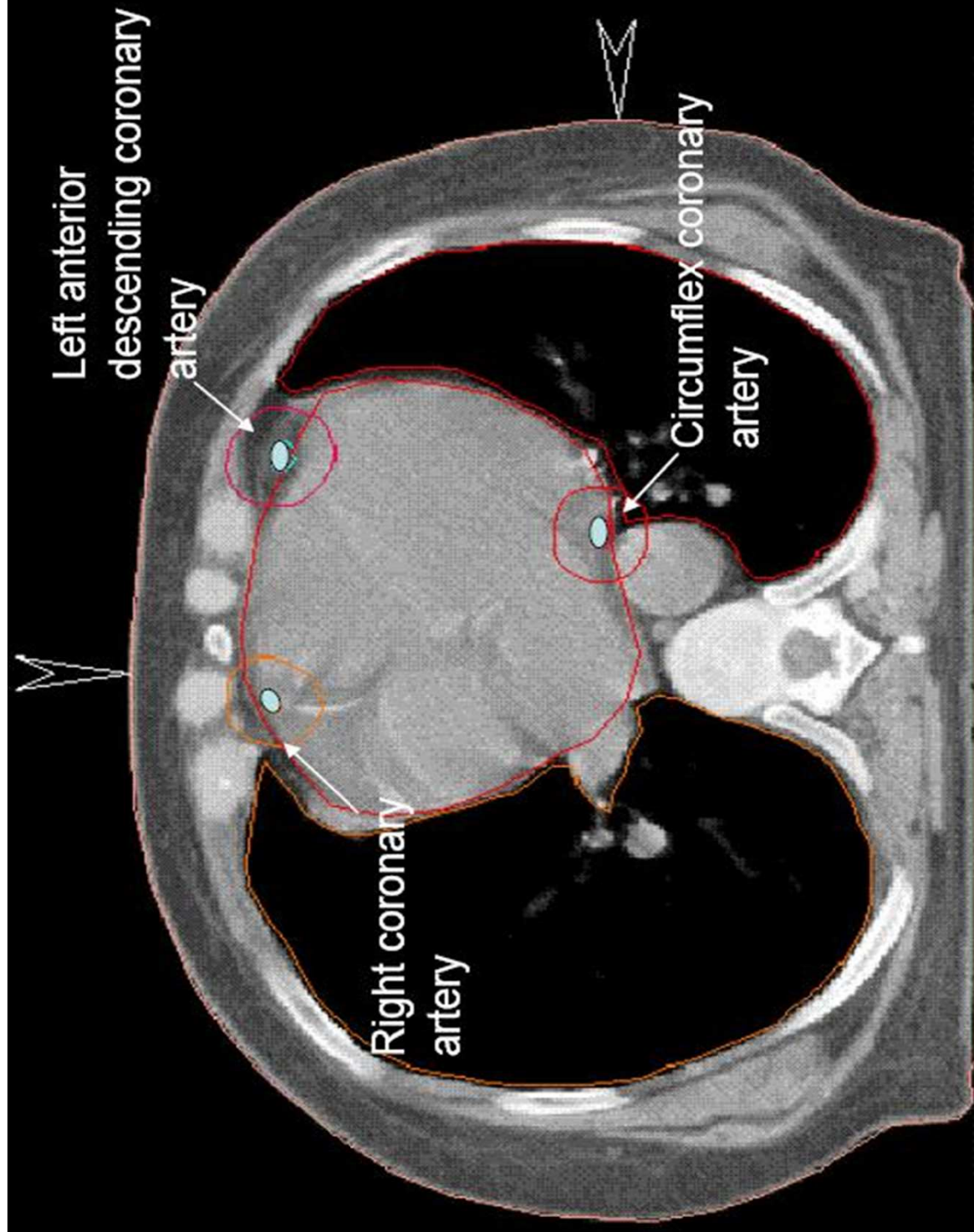
Why you need IGRT in breast
cancer:

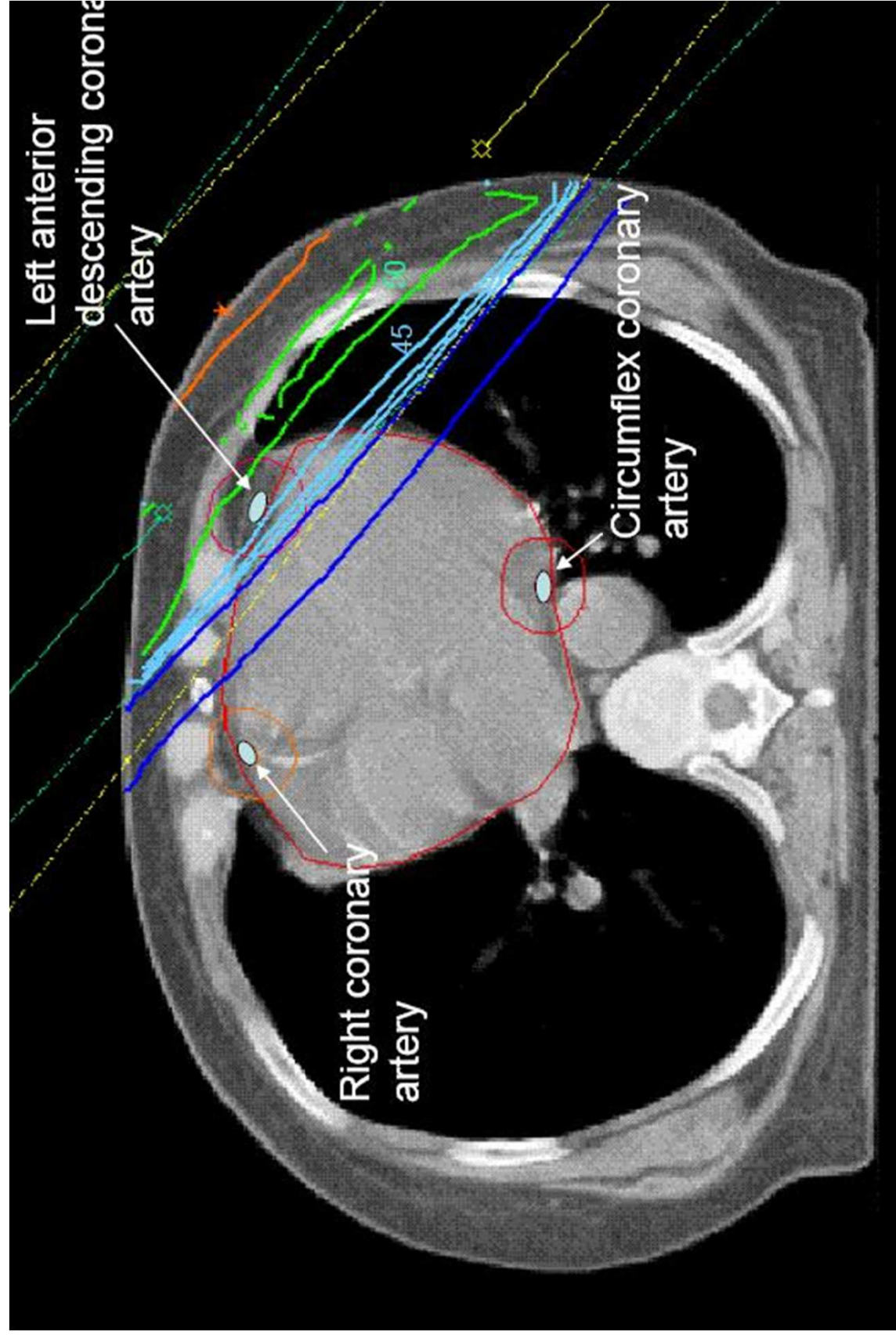
We have enough proof...

- Danish trial: Reduce loco-regional recurrence 18 % in high risk group and survival benefits of 9 %.
- Level –I evidence is lacking in 1-3 node positive but recommended in NCCN.
- Old series with superficial therapy and unplanned radiation may harm?

What make RT unwanted:

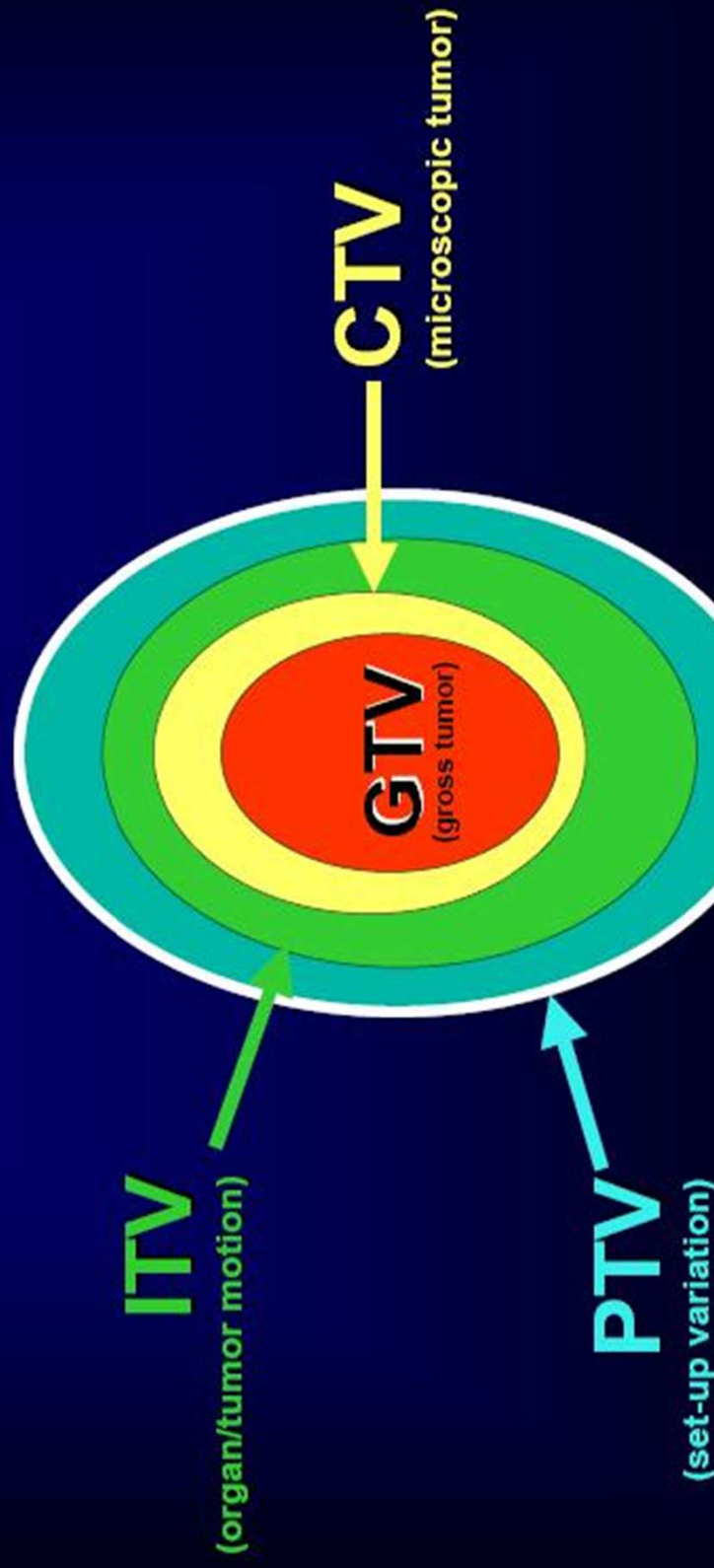
- Danish trial results are not reproducible.
- Local : breast pain, skin fibrosis, reconstruction, dose to opposite breast.
- RIHD: radiation induced heart disease.
- Death due to cardiac complication.
- Damage to lung.
- Brachial plexus damage.
- Thyroid.





Challenge 1

Guidance on Target Determination and Delineation




ICRU 62

International Commission on Radiation Units and Measurements

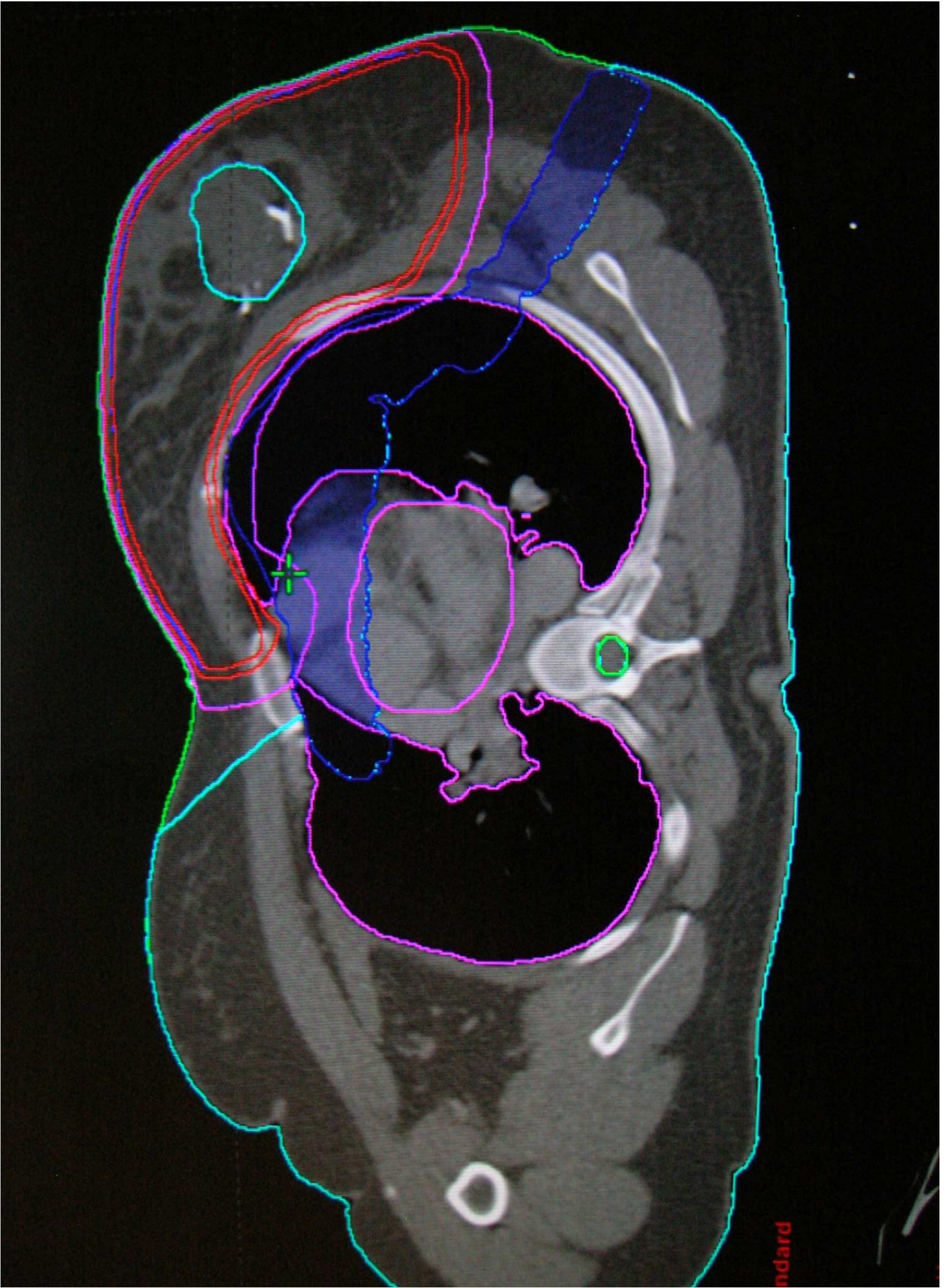Irradiated volume:

- CTV : 5 cm³ area.
- Now add margin of 2 cm and make it 7 cm³.
- Difference ??
- 125 cc volume for 5 cubic and 343 cc for 7cm³ difference of 218 cc.
- IGRT can reduce it..??

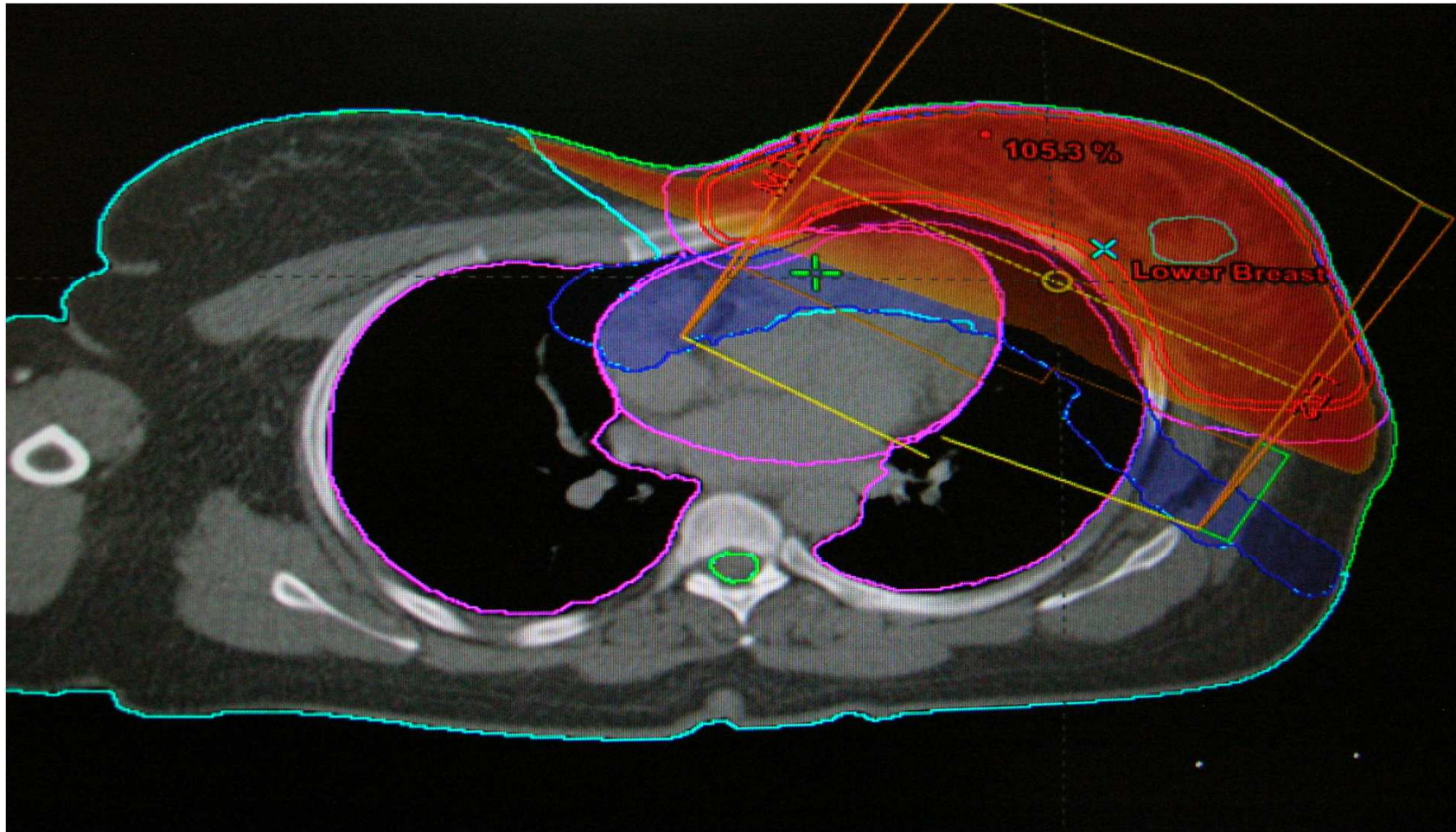
Target: Challenge 2



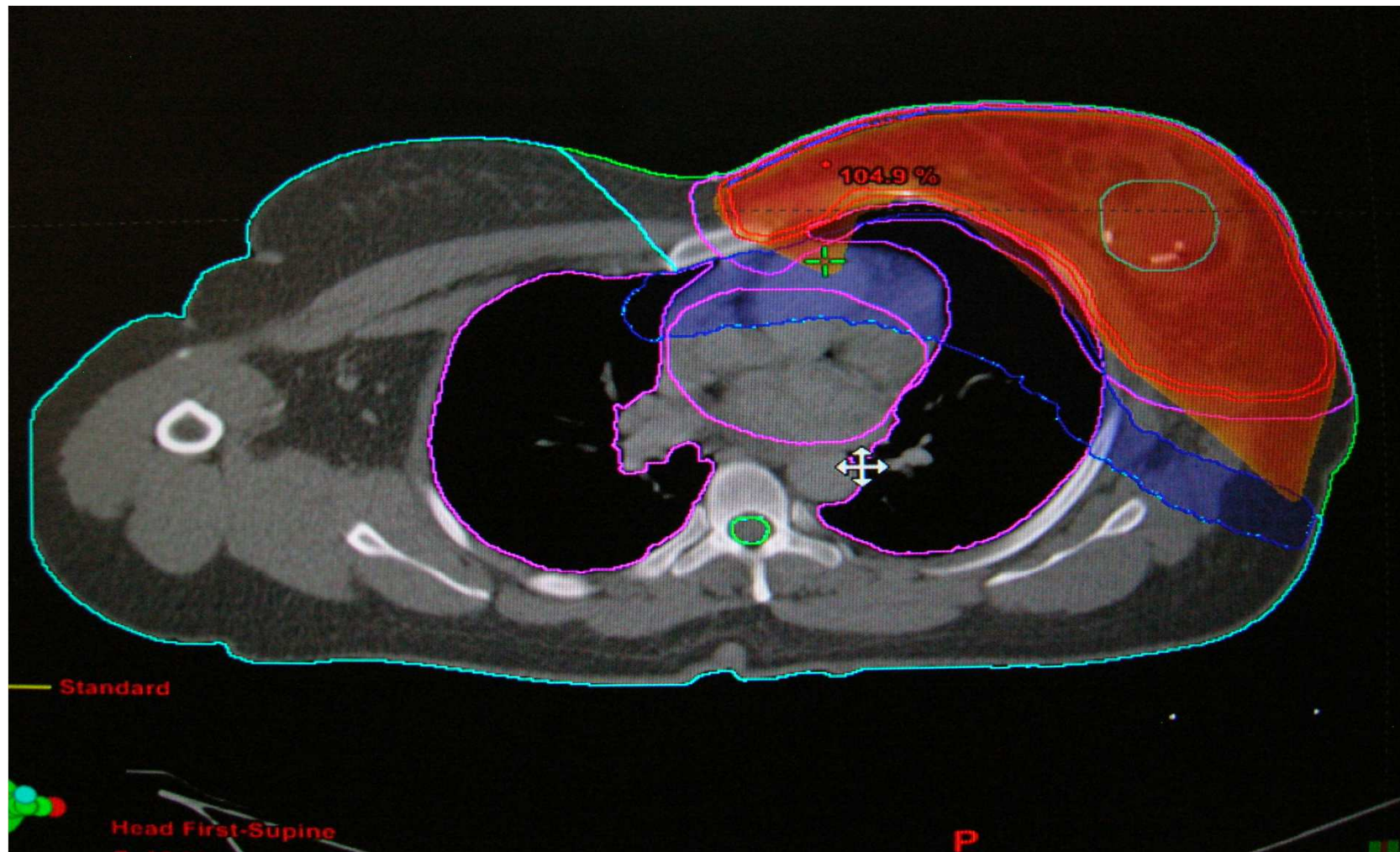
Good Aiming Means Everything



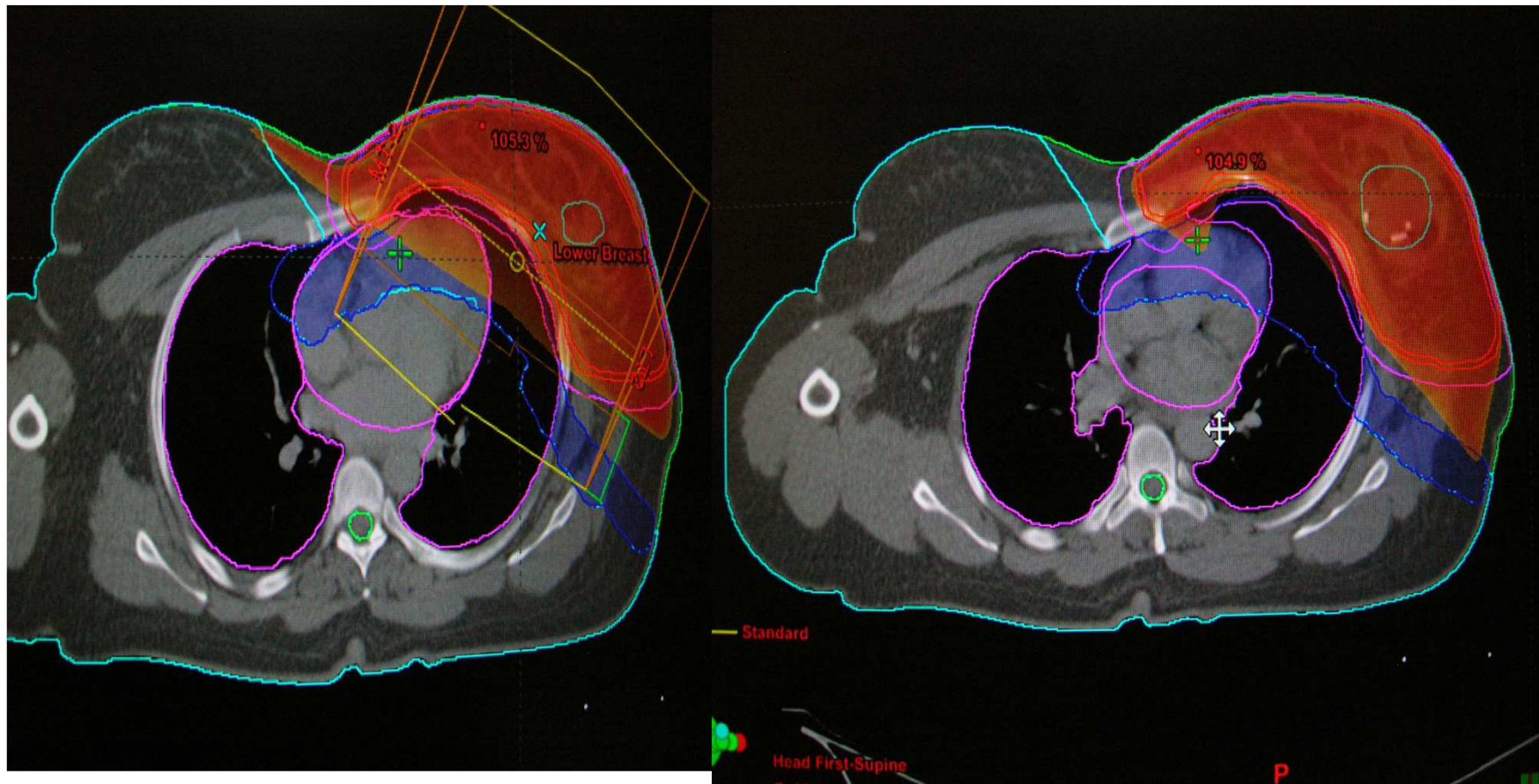
3-DRT v/s IMRT:



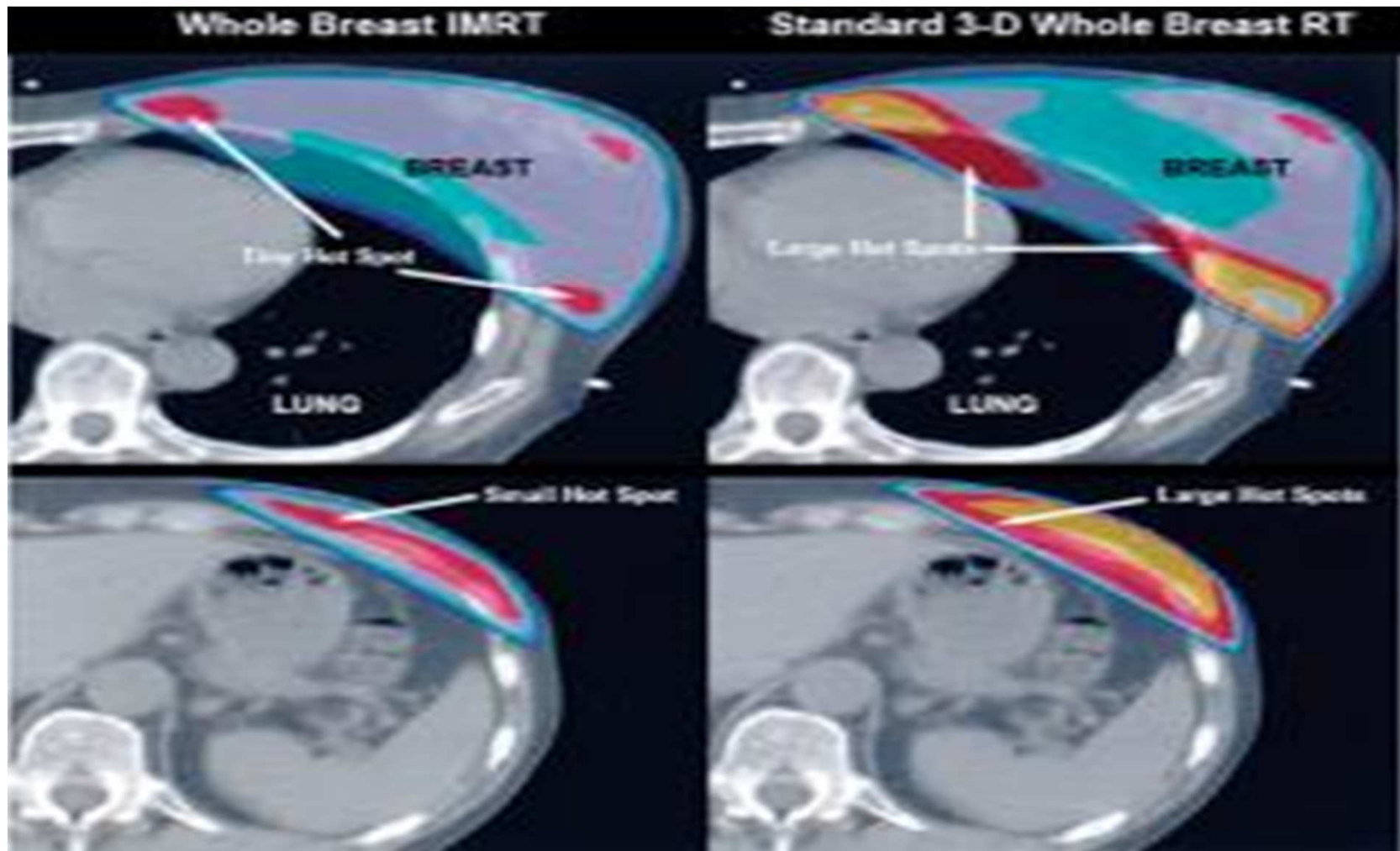
3-DCRT v/s IMRT



3-D v/s IMRT



3-D v/s IMRT



Challenge 3



Provided the bull's eye is not moving...

Types of movement:

- Interfraction
- Intrafraction .

Offline Review - DAVE, PRAFULLABEN ID:07-0303

File Edit View Insert Measure Matching Review Tools Help

Blended: AP KV -DRR - AP KV SETUP - 8/4/2007 10:08

Blended: RL KV -DRR - RL KV SETUP - 8/4/2007 10:07

S2 - AP KV SETUP - AP KV -DRR - 8/3/2007... S2 - AP KV SETUP - AP KV SETUP - 8/4/2007... S2 - RL KV SETUP - RL KV -DRR - 8/3/2007 1... S2 - RL KV SETUP - RL KV SETUP - 8/4/2007...

Summary: Images (2 New) / Couch Corrections (VAR_IEC scale)

AP KV SETUP - RL KV SETUP	
Status	
Lat [cm]	
Lng [cm]	
Vrt [cm]	
Rtn [deg]	

Paired/IGRT FinIS #

Patient Alerts

- no alerts available -

New Alert...

Session 2, Sat 8/4/2007, Image 1,2 of 2

start Offline Review - DAV... 1 - Paint Norton 4:55 PM

Offline Review - DAVE, PRAFULLABEN ID:07-0303

File Edit View Insert Measure Matching Review Tools Help

Blended: AP KV -DRR - AP KV SETUP - 9/3/2007 12:34

Blended: RL KV -DRR - RL KV SETUP - 9/3/2007 12:33

S21 - AP KV SETUP - AP KV -DRR - 8/3/2007...

S21 - AP KV SETUP - AP KV SETUP - 9/3/200...

S21 - RL KV SETUP - RL KV -DRR - 8/3/2007...

S21 - RL KV SETUP - RL KV SETUP - 9/3/200...

Summary: Images (2 New) / Couch Corrections (VAR_IEC scale)

	AP KV SETUP - RL KV SETUP
Status	
Lat [cm]	
Lng [cm]	
Vrt [cm]	
Rtn [deg]	

Paired/IGRT Finl5 #

Patient Alerts

- no alerts available -

New Alert...

Session 21, Mon 9/3/2007, Image 1,2 of 2

start

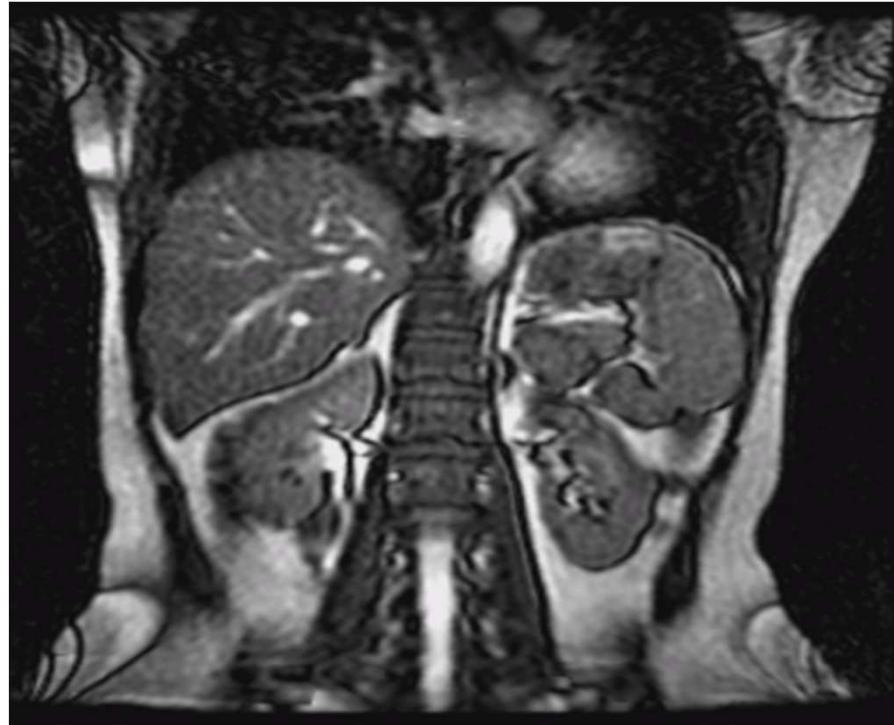Offline Review - DAV...

untitled - Paint

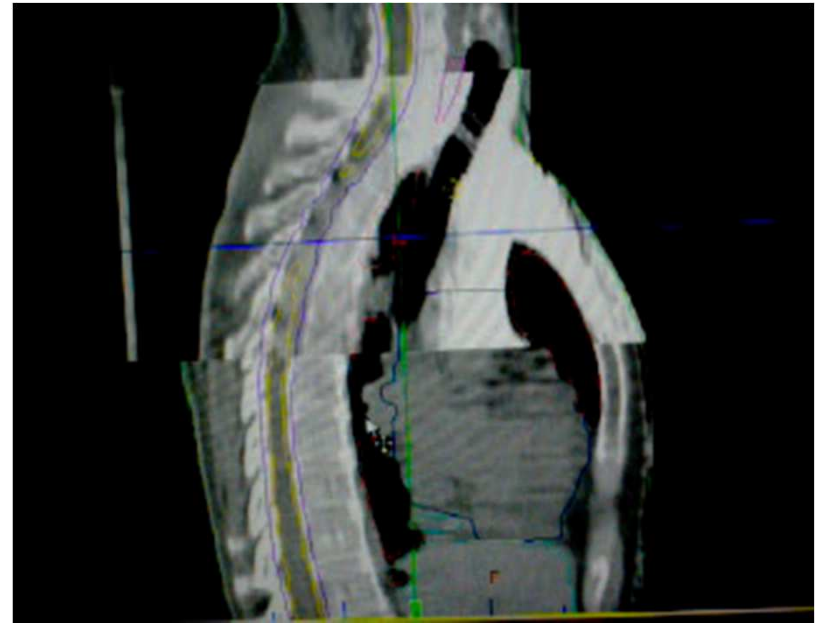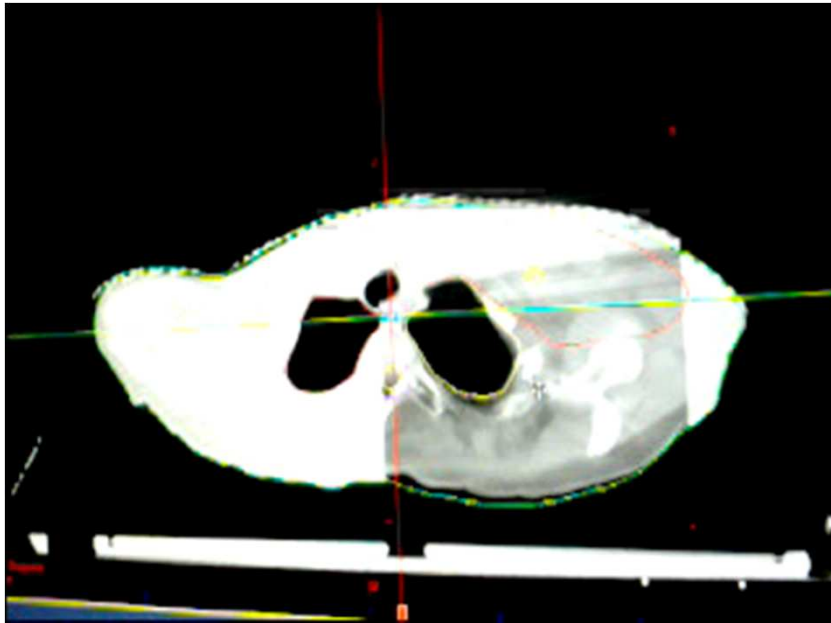
Norton

5:07 PM

Intrafraction:



Movement and motion:

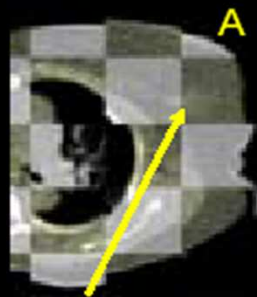


Precision therapy:

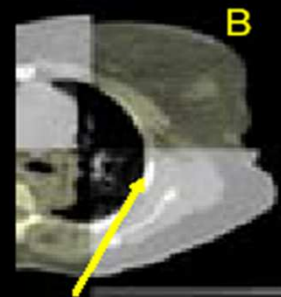
IGRT FOR BREAST CA

Langen et al., IJROBP, 63S, p. S179, 2005

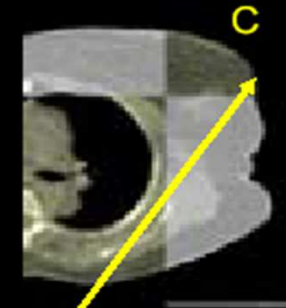
7 patients
5 CTs per patient
35 scans



Seroma



Rib cage



Skin

Bone and skin alignments, relative to seroma

Dir.	Ribs	Skin
	Mean \pm 1SD (Margin*)	
Lat.	-1.5 \pm 2.7 (5)	1.7 \pm 3.4 (6)
Long.	0.8 \pm 3.1 (4)	1.2 \pm 2.8 (4)
Vert	-2.4 \pm 2.0 (6)	-0.5 \pm 3.2 (3)

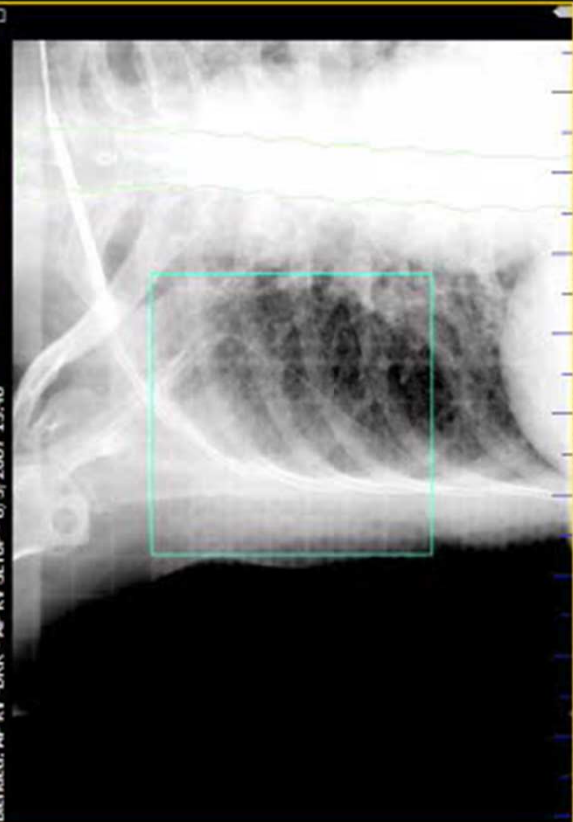
Our experience:

- Since Aug 2006: 24 patients treated with IGRT.
- 11 were CBS and 13 post mastectomy.
- 09 patients were right sided breast and 15 were left sided breast disease.
- Mean age was 51 years.

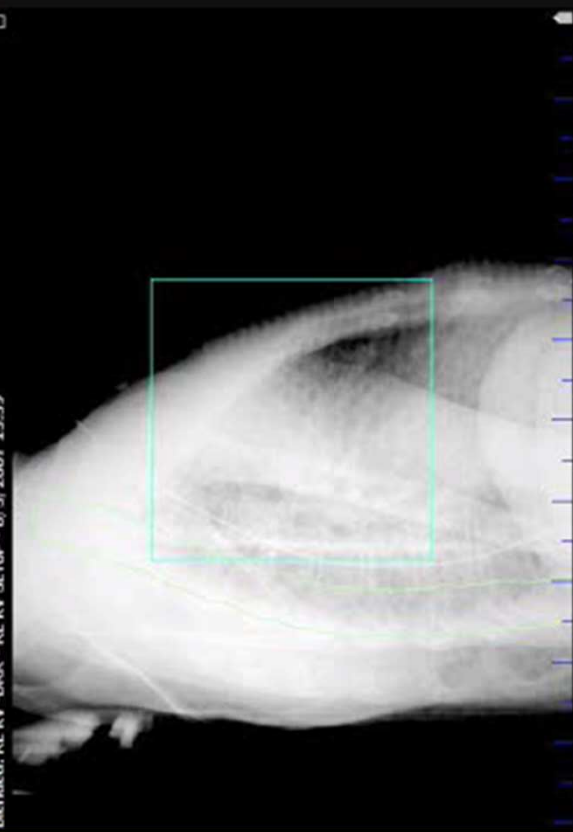
Steps:

- Immobilization.
- CT-scan free breathing.
- Contouring.
- Planning.
- Verification.
- Treatment delivery online and off line correction.

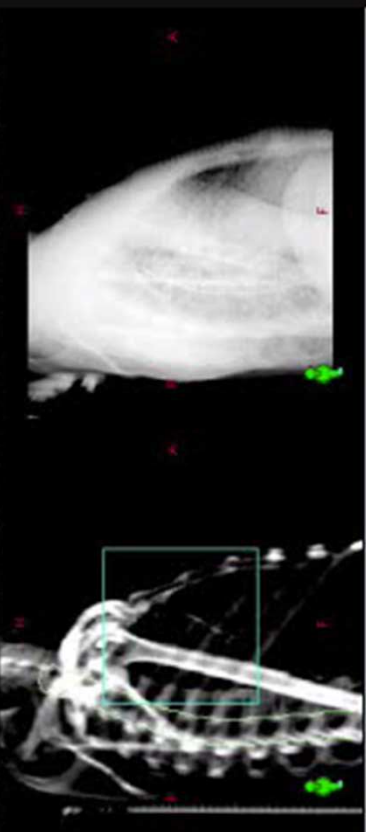
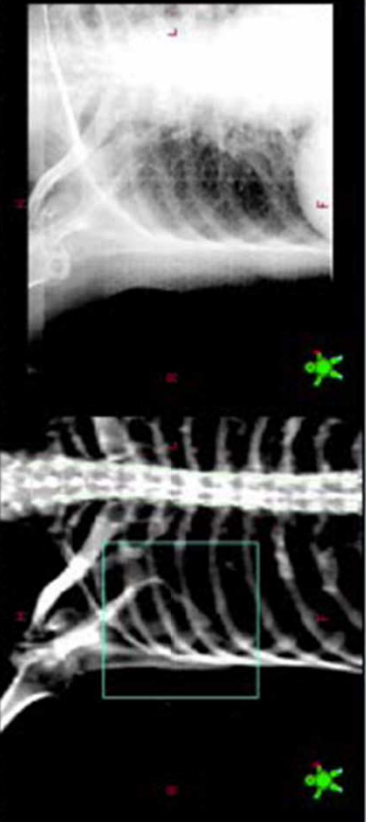
Blended: AP KV - DRR - AP KV SETUP - 8/3/2007 13:40



Blended: RL KV - DRR - RL KV SETUP - 8/3/2007 13:39



S1 - AP KV SETUP - AP KV - DRR - AP KV SETUP - 8/3/2007... S1 - AP KV SETUP - AP KV - DRR - AP KV SETUP - 8/3/2007... S1 - RL KV SETUP - RL KV - DRR - RL KV SETUP - 8/3/2007...



Summary: Images (9 New) / Couch Corrections (VAR, REC scale)

Status	AP KV SETUP - RL KV SETUP
Lat [cm]	
Long [cm]	
Vrt [cm]	
Rtn [deg]	

Patient Alerts

- No alerts available -

New Alert...

Session 1, Fri 8/3/2007, Image 8,9 of 9

Norton

start

Results:

- All patients off line record were reviewed.
- Daily set up error were corrected.
- Daily movement noted.
- Cone beam CT was also taken in selected cases.

Conclusion:

- Radiotherapy play important role in management of breast cancer.
- Side effect after 10-15 years are well understood so we can reduce side effect with available present technology.
- Image guided radiotherapy is not standard of care at present but will definitely going to useful radiation techniques to treat breast cancer, more on left side.

- Thank you.