



# Radiological Anatomy and Imaging in Lung Cancer

**Dr Poonam Sherwani**

**Associate Professor**

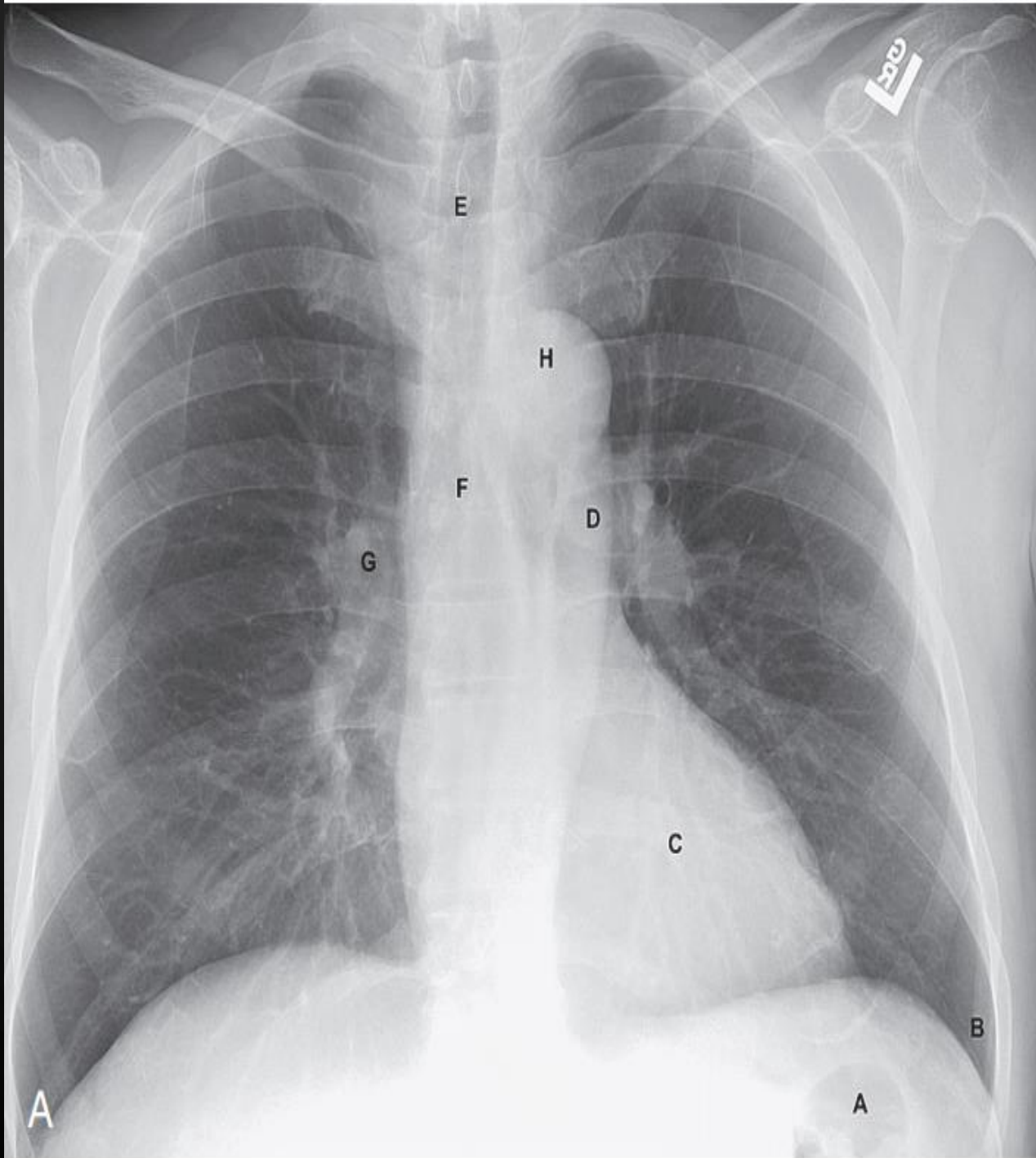
**DNB,MNAMS,FELLOW PEDIATRIC RADIOLOGY(AIIMS,Delhi)**

**EDIR,DICRI**

**AIIMS Rishikesh**

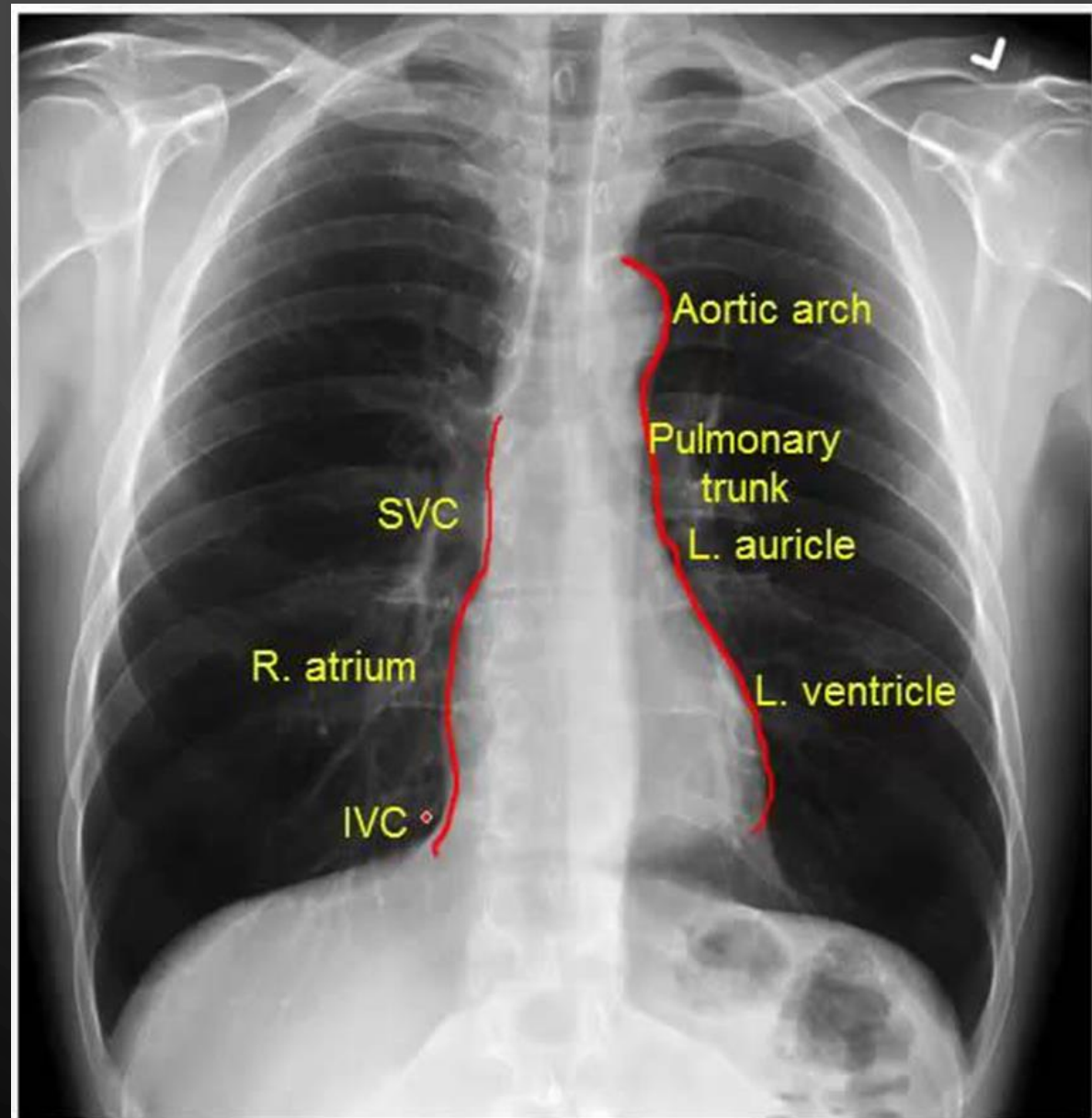
# Overview

- Normal Chest Radiograph Anatomy
- Signs on Chest Radiograph
- Bronchopulmonary Segments
- Normal mediastinal anatomy on CT chest
- Classification of Lung Cancer
- Imaging pattern of Lung Cancer
- Imaging of Various subtypes of Lung cancer



- A. gas in fundus
- B. costophrenic sulcus (angle)
- C. heart
- D. descending aorta
- E. trachea
- F. carina
- G. hilum
- H. aortic knob
- J. ascending aorta

# Cardiac borders

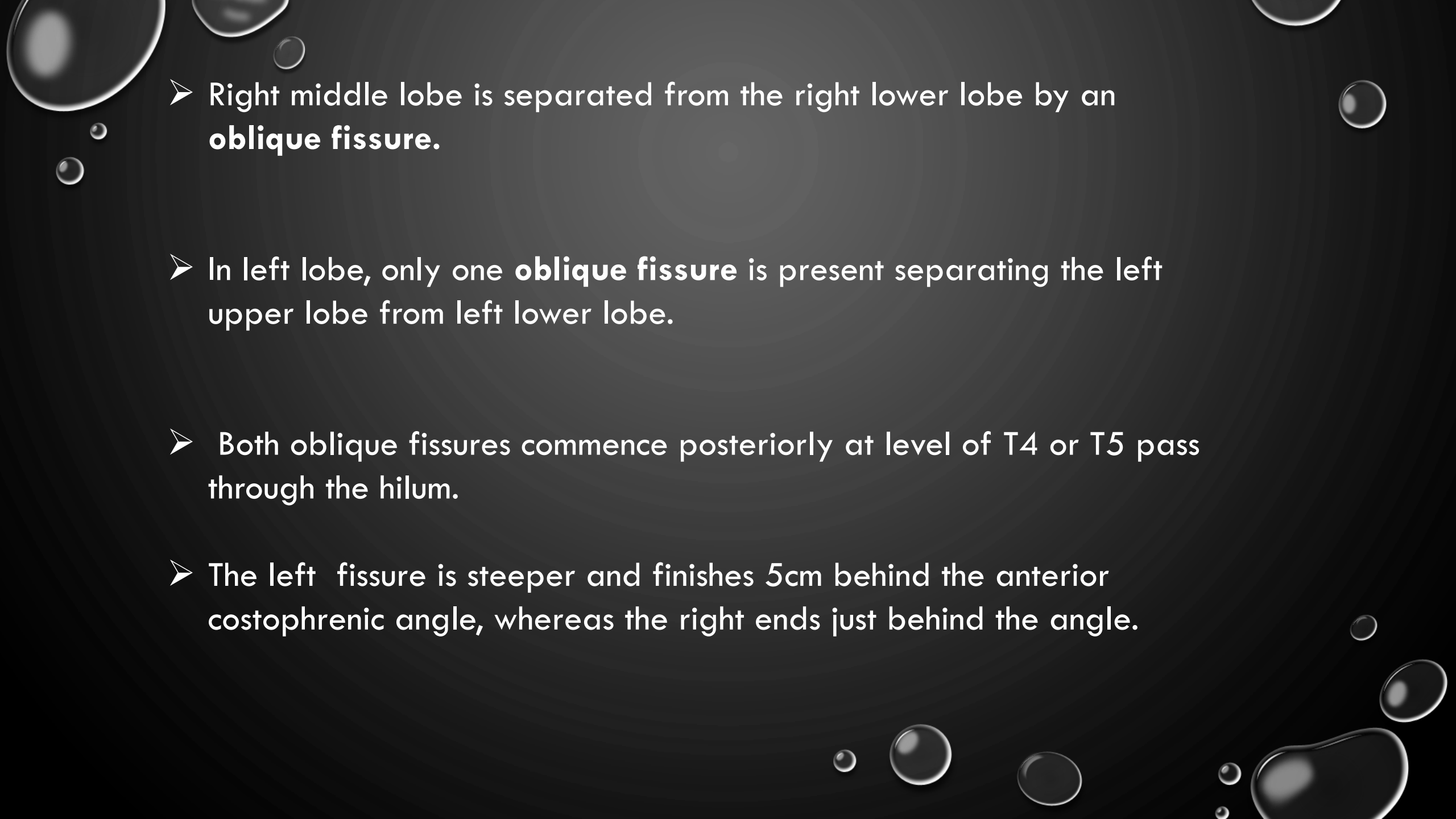


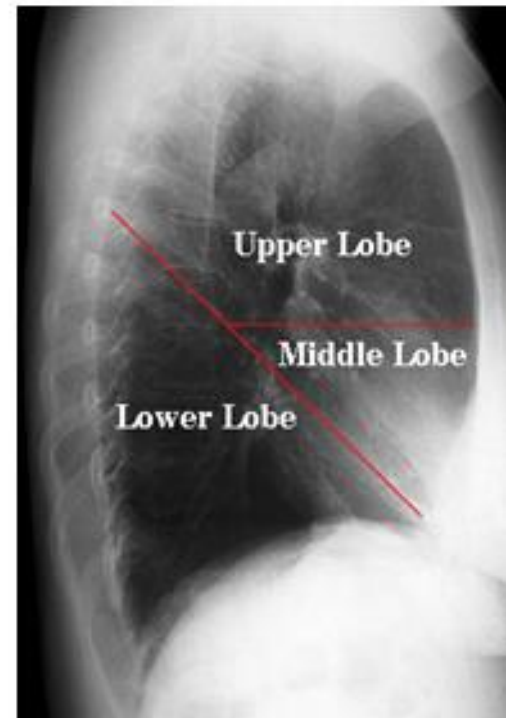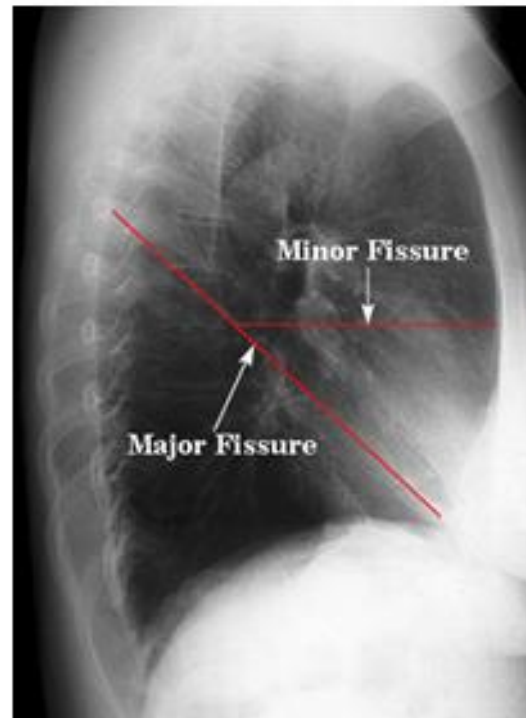
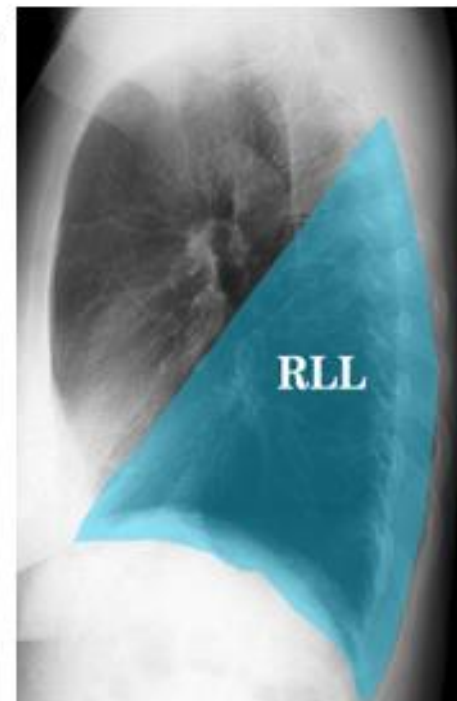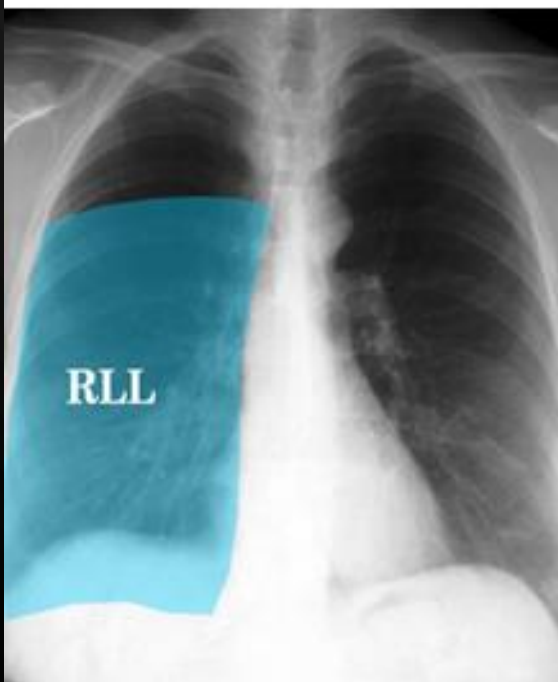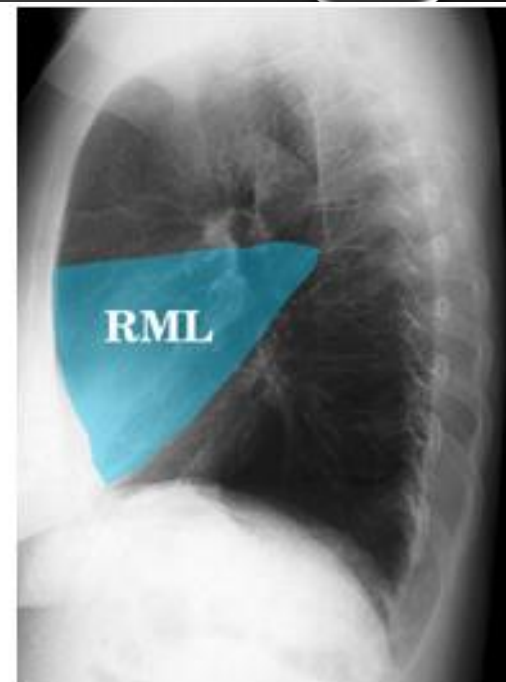
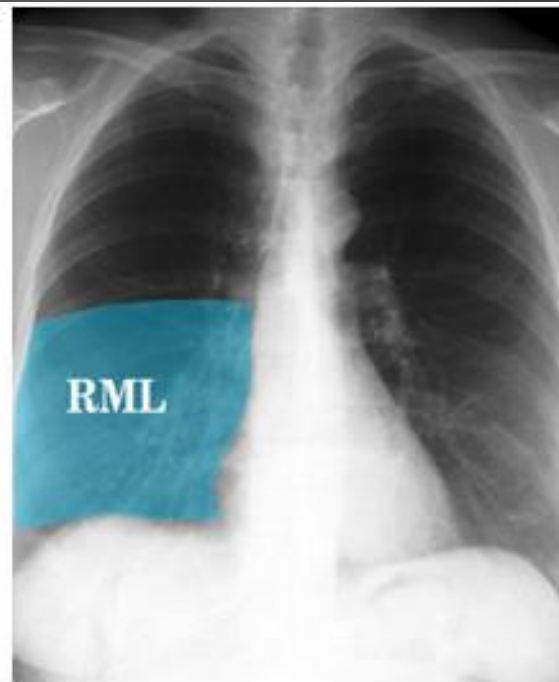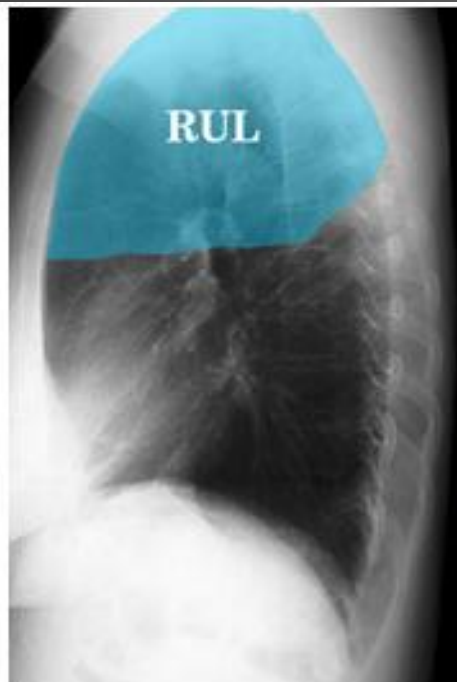
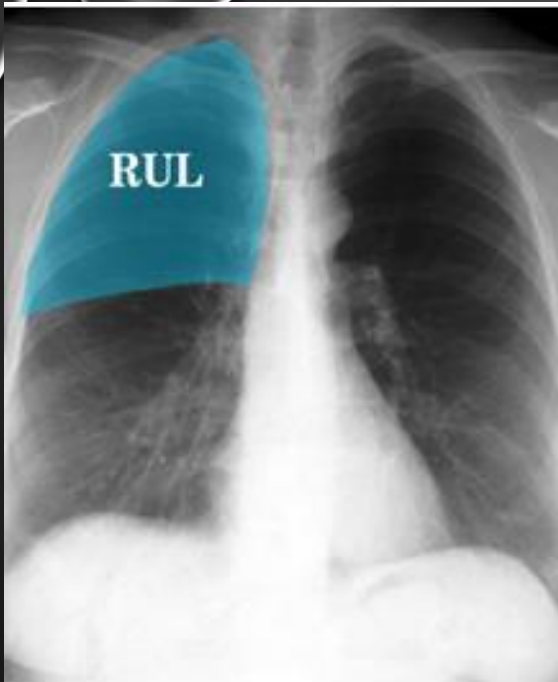
# The fissures

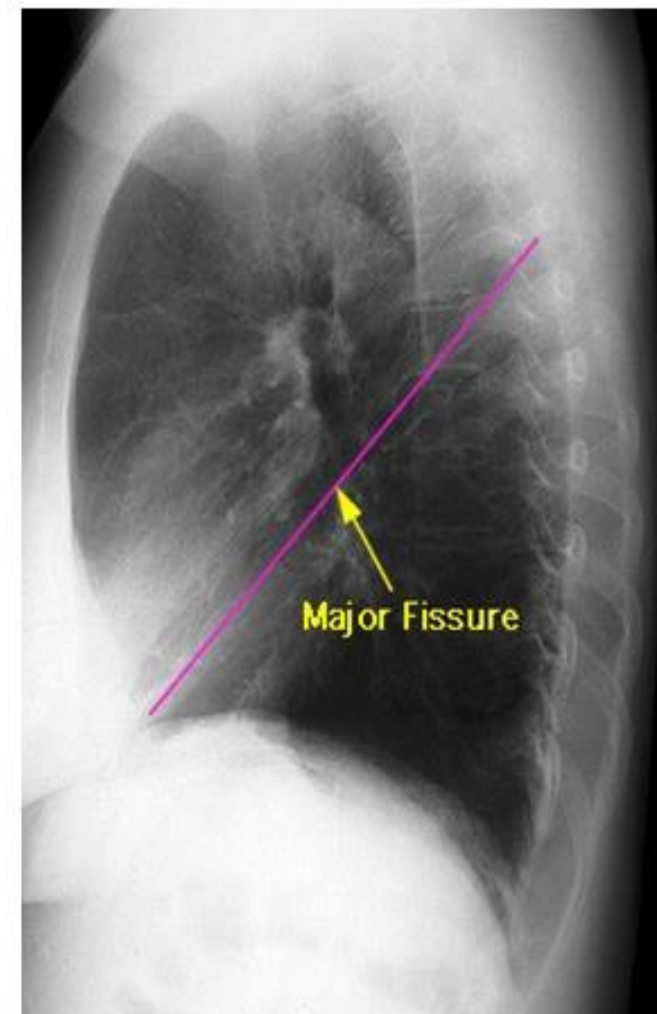
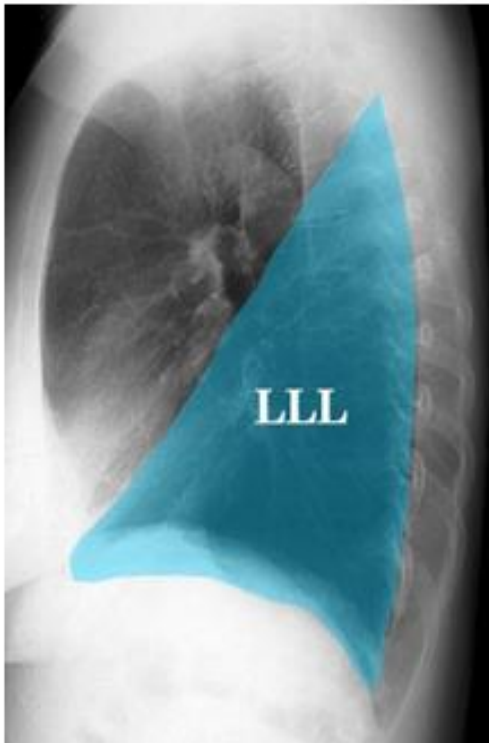
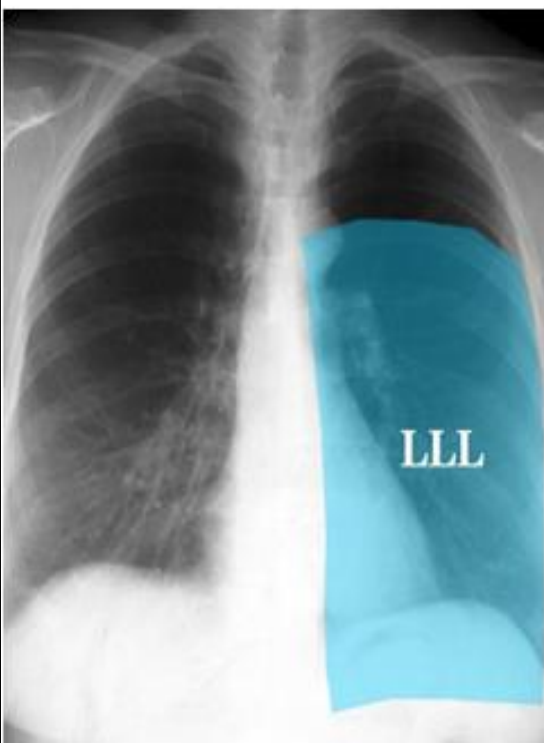
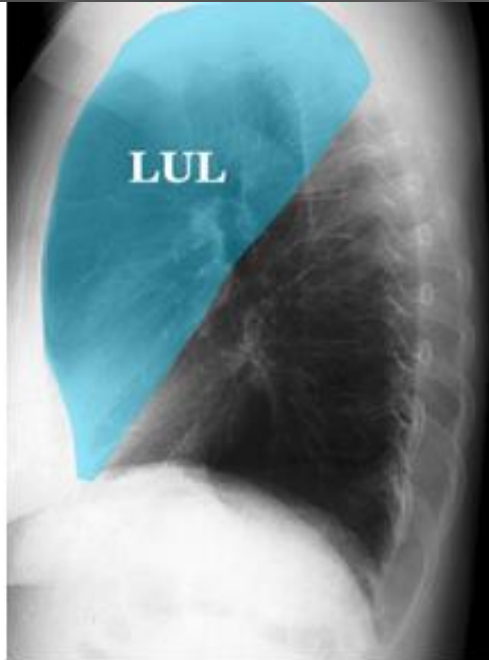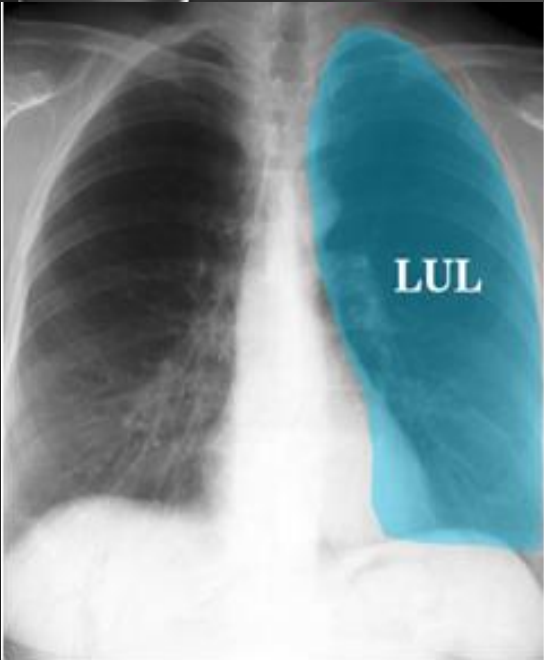## *The main fissures:*

- A fissure is a space between two lobes where visceral pleura touch.
- It is only visible when the x-ray beam is tangential to the fissure.
- Right lung has three lobes, right upper and middle lobes are separated by the **horizontal fissure or minor fissure**.
- Horizontal fissure extend in the transverse plane from hilum to the region of 6<sup>th</sup> rib in the axillary line.



- 
- Right middle lobe is separated from the right lower lobe by an **oblique fissure**.
  - In left lobe, only one **oblique fissure** is present separating the left upper lobe from left lower lobe.
  - Both oblique fissures commence posteriorly at level of T4 or T5 pass through the hilum.
  - The left fissure is steeper and finishes 5cm behind the anterior costophrenic angle, whereas the right ends just behind the angle.

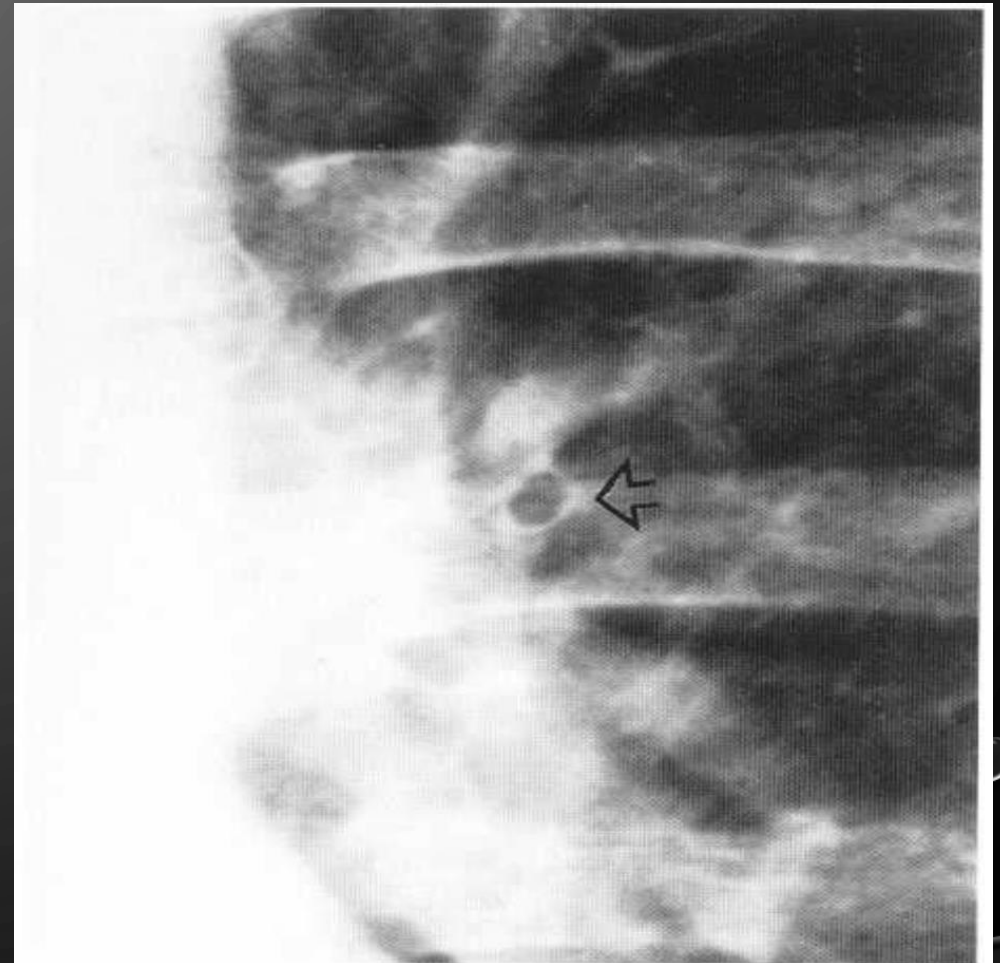






# Hilum

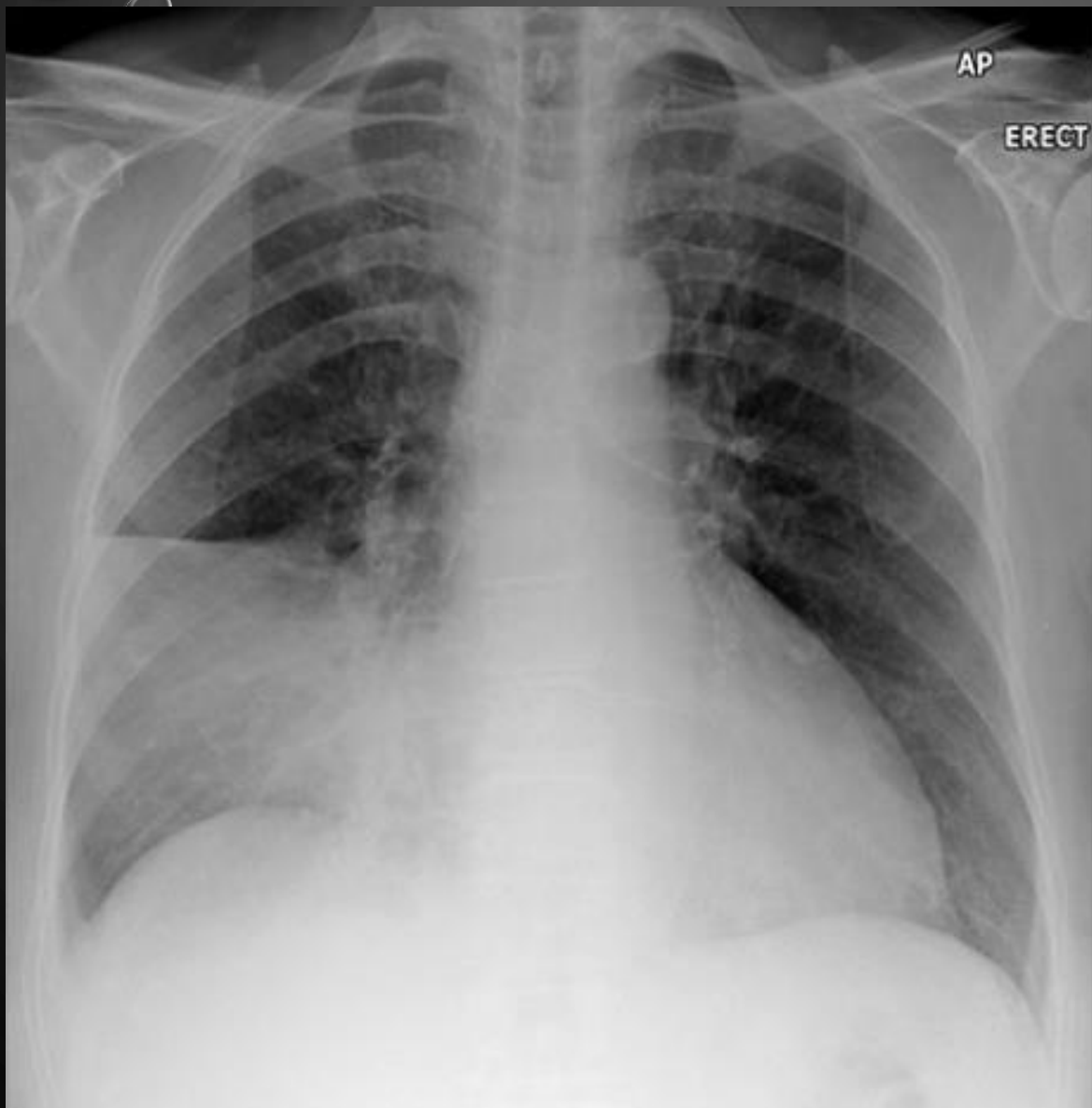- Normal lymph nodes are not seen.
- anterior segment bronchus of the upper lobe is seen as a ring adjacent to upper hilum.
- normally there is less than 5 mm soft tissue lateral to this bronchus.
- thickening of soft tissue suggest presence of abnormal pathology such as malignancy.



# Silhouette sign

- **Definition-** Two substances of the same density, in direct contact, cannot be differentiated from each other on an x-ray. This phenomenon, the loss of the normal radiographic silhouette or interface, is called the silhouette sign.
- Loss of an interface( difference in radiodensity between lung and surrounding tissue )by a disease.
- Helps in lesion localisation.

LUNG PART	ADJACENT BORDER
lingula	left cardiac border
right middle lobe	right cardiac border
apico posterior segment of LUL	aortic knuckle
anterior segments of RUL and RML	right aortic border/ ascending aorta
basal segments of lower lobes	hemidiaphragm



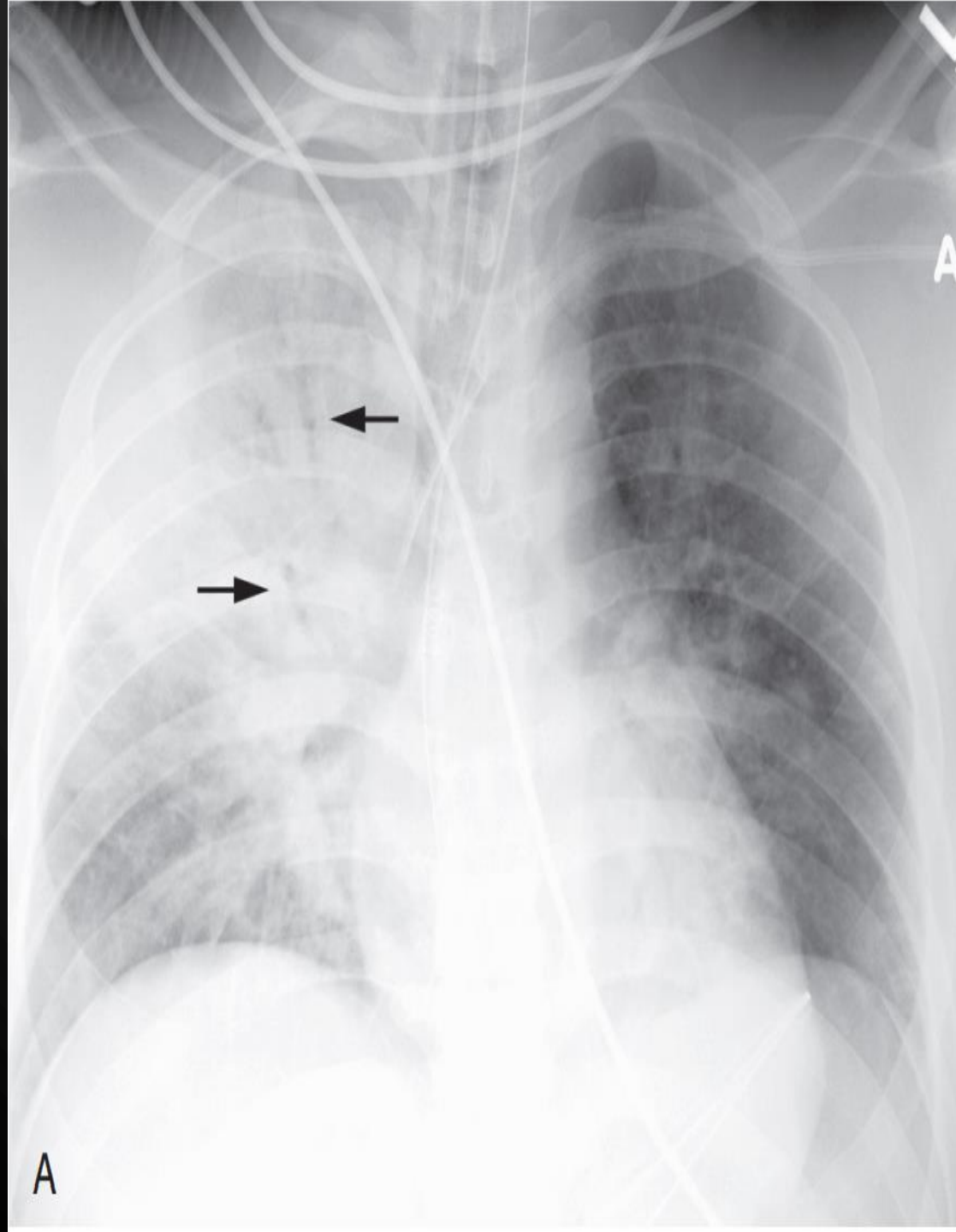


# Air bronchogram

- Visualisation of air within intrapulmonary bronchi on a chest radiograph is called an air bronchogram sign.
- Signifies the patency of the bronchus.

# Causes of air bronchogram

- Consolidation
- Pulmonary edema
- Hyaline membrane disease
- Alveolar cell carcinoma
- Lymphoma
- sarcoidosis



A

A

# Computed Tomography

The role of CT scan of thorax:

- To confirm the location and extent of disease.
- To characterise the pattern of disease.
- To demonstrate the mediastinal or chest wall involvement by pulmonary pathology.
- For staging of tumors and to monitor the response to treatment.
- To ascertain the nature of solitary pulmonary nodule.

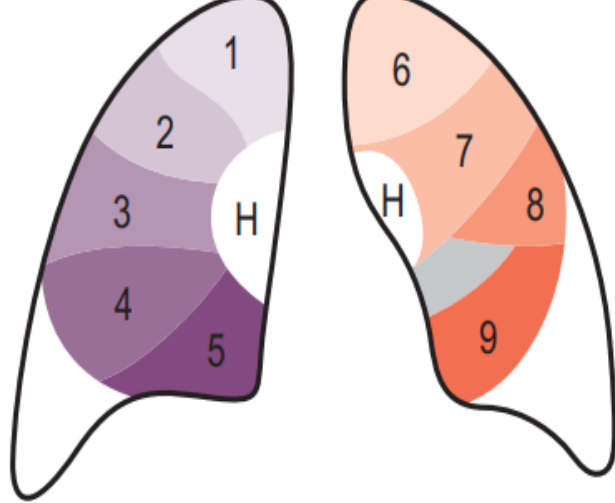


# Overview

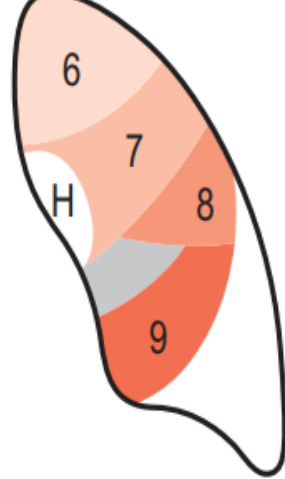
- Normal Chest Radiograph Anatomy
- Bronchopulmonary Segments
- Signs on Chest Radiograph
- Normal mediastinal anatomy on CT chest
- Classification of Lung Cancer
- Imaging pattern of Lung Cancer
- Imaging of Various subtypes of Lung cancer

# Pulmonary segments and bronchus

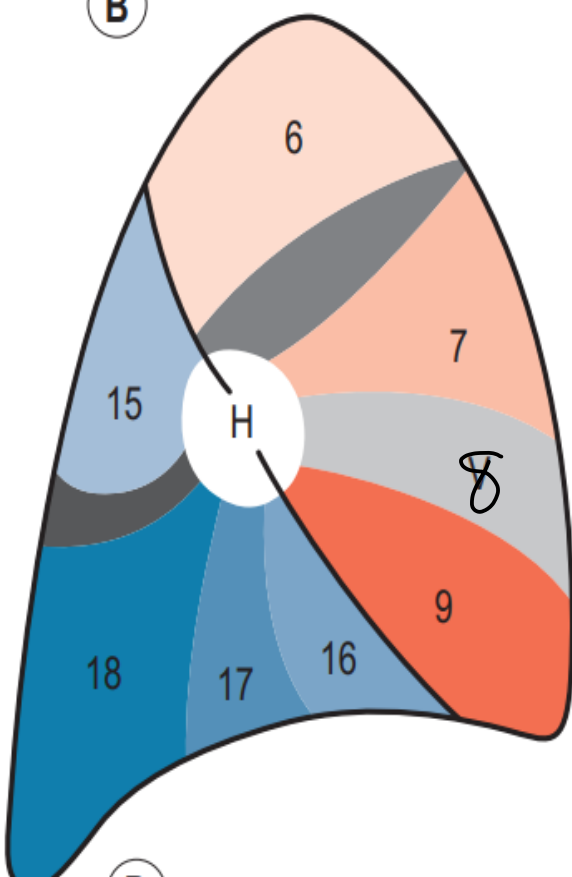
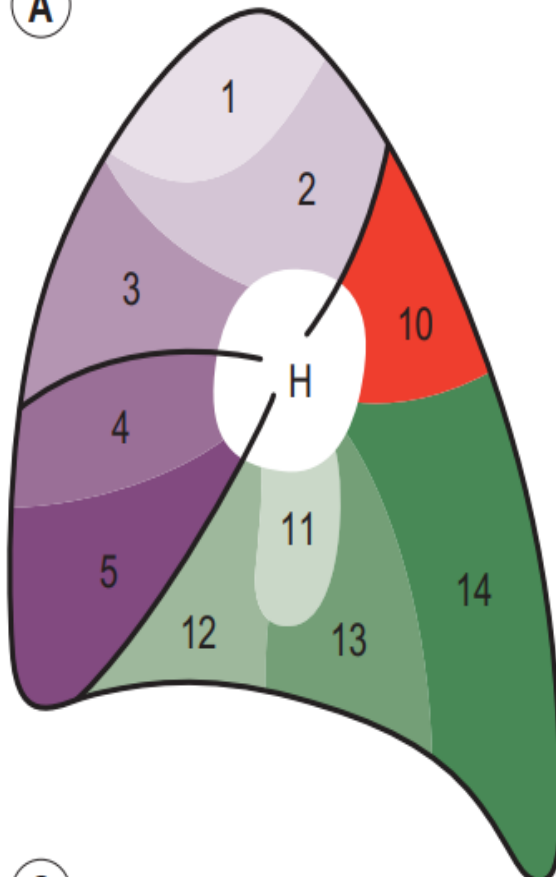
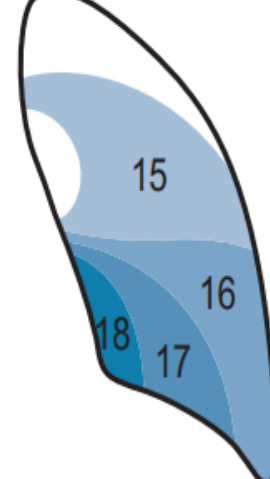
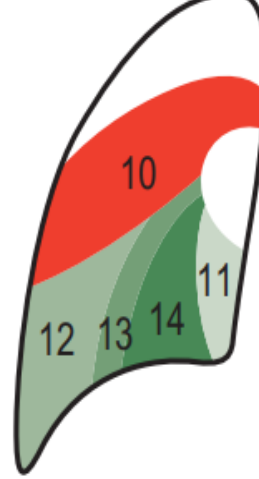- The pulmonary segments are served by segmental bronchi and arteries and are not separated by pleura.
- Right main bronchus is shorter, steeper and wider than left, bifurcating earlier.
- Right upper lobe bronchus arises after 2.5 cm below carina and higher than left upper lobe bronchus which arises after 5 cm.



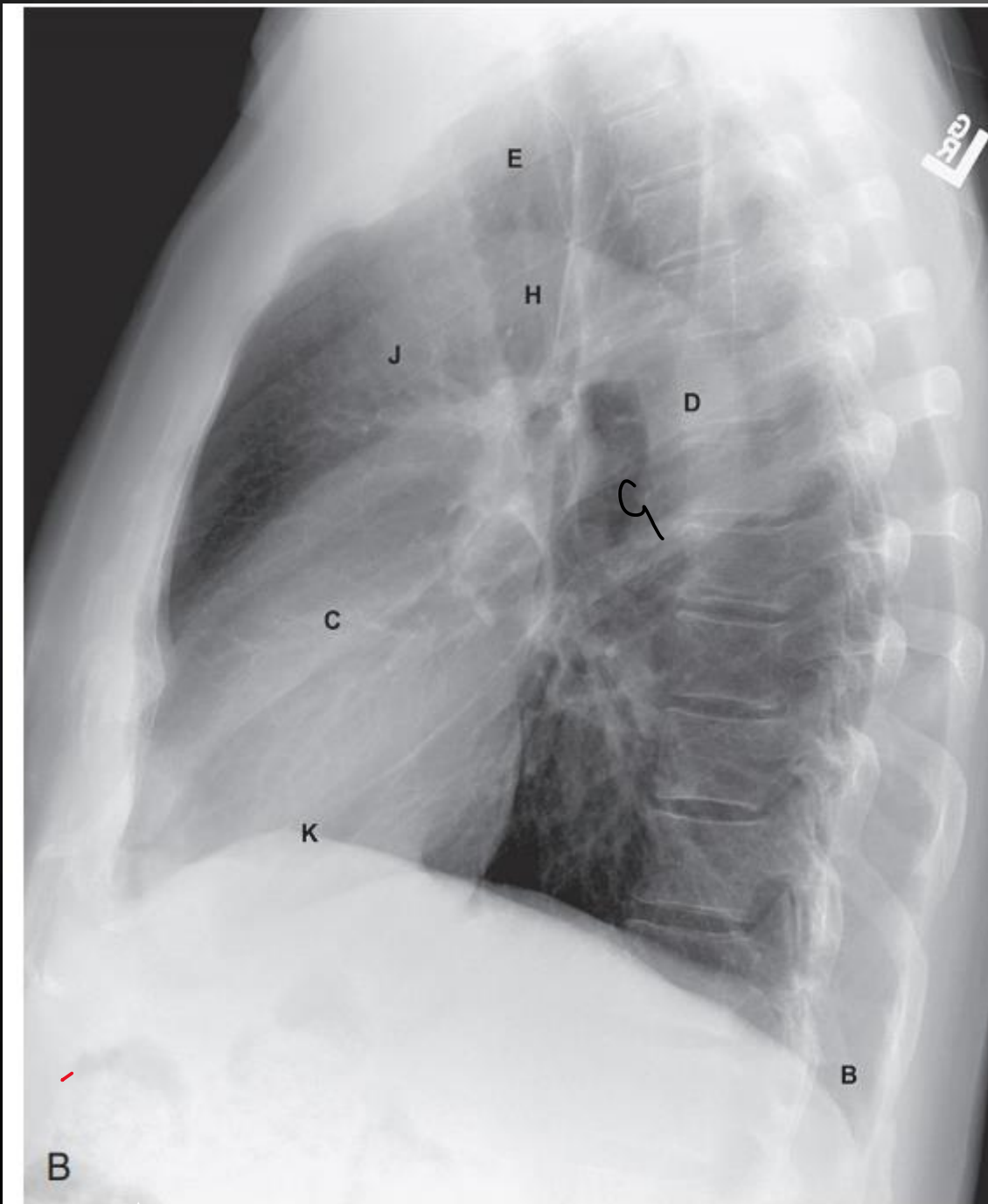
A



B



- 1, apical(RUL)
- 2, posterior (RUL)
- 3, anterior (RUL)
- 4, lateral (RML)
- 5, medial( RML)
- 6, apical posterior (LUL)
- 7, anterior LUL
- 8, superior lingular
- 9, inferior lingular
- 10, apical (superior) (RLL)
- 11, medial basal RLL
- 12, anterior basal RLL
- 13, lateral basal RLL
- 14, posterior basal RLL
- 15, apical (superior) (LLL)
- 16, anterior basal LLL
- 17, lateral basal LLL
- 18, posterior basal LLL



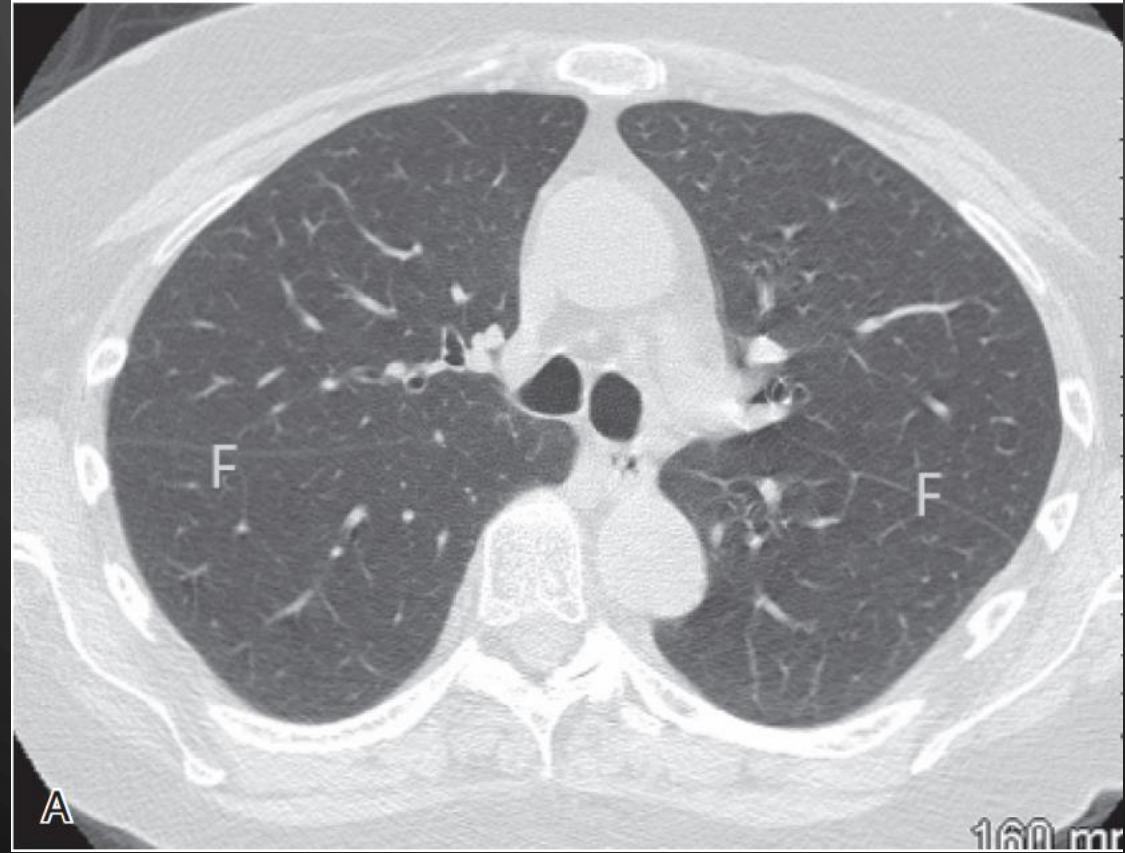
- **A.** GAS IN SPLENIC FLEXURE
- **B.** COSTOPHRENIC SULCUS (ANGLE)
- **C.** HEART
- **D.** DESCENDING AORTA
- **E.** TRACHEA
- **G.** HILUM
- **H.** AORTIC KNOB
- **J.** ASCENDING AORTA
- **K.** RIGHT DIAPHRAGM

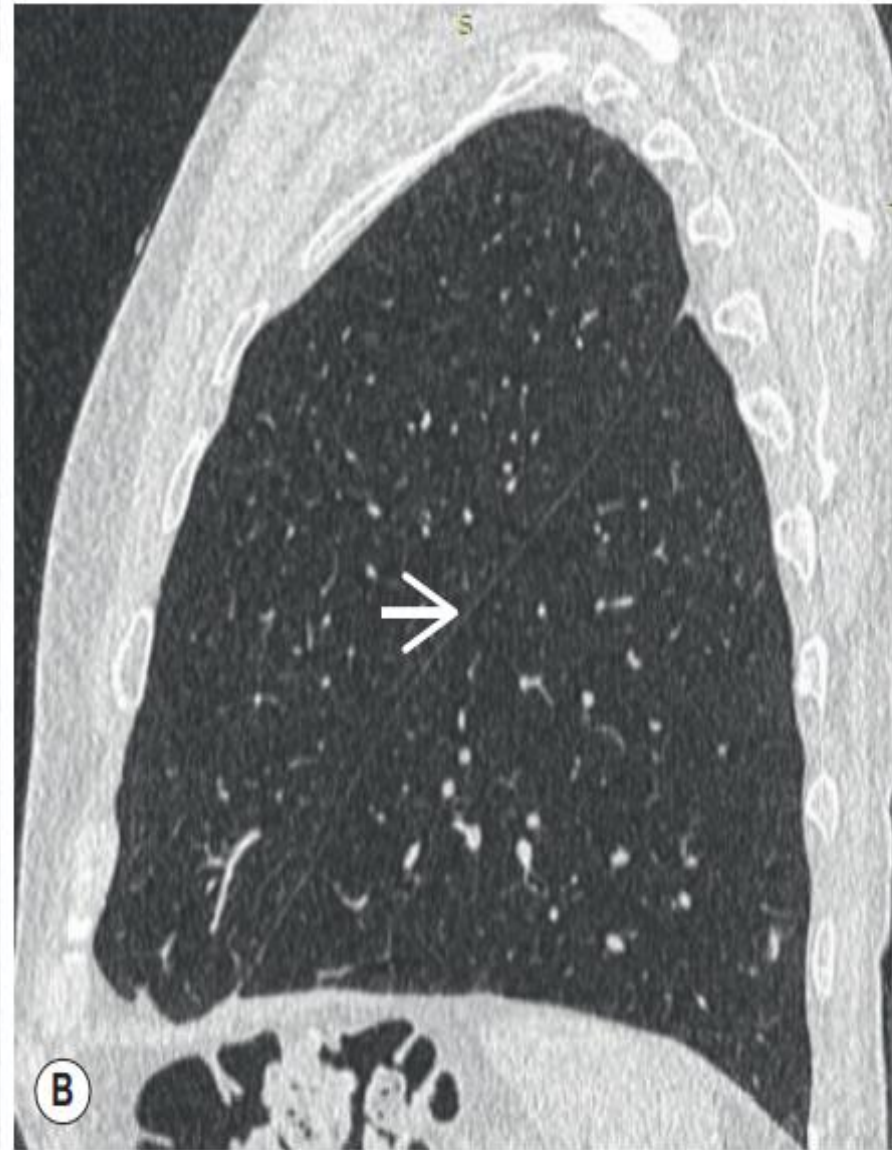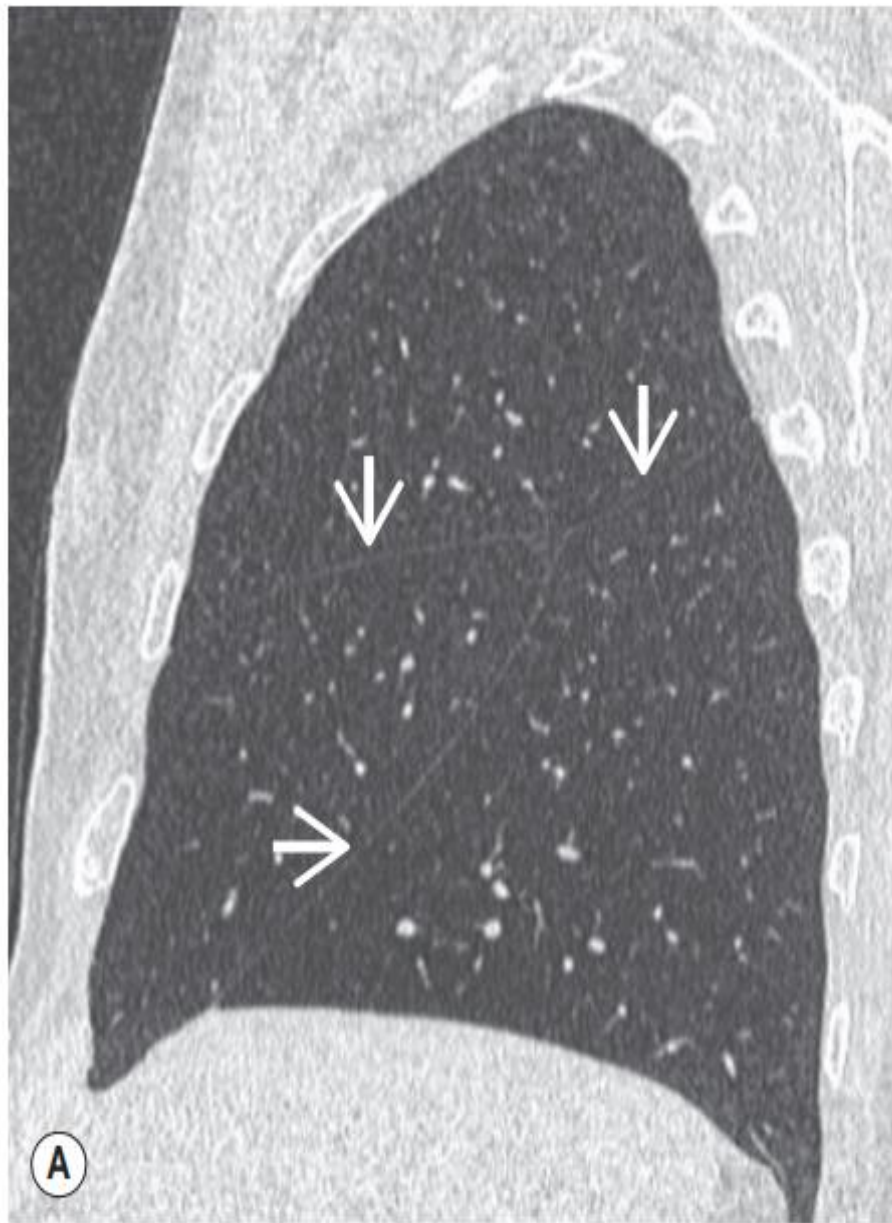


# Overview

- Normal Chest Radiograph Anatomy
- Bronchopulmonary Segments
- Signs on Chest Radiograph
- Normal mediastinal anatomy on CT chest
- Classification of Lung Cancer
- Imaging pattern of Lung Cancer
- Imaging of Various subtypes of Lung cancer

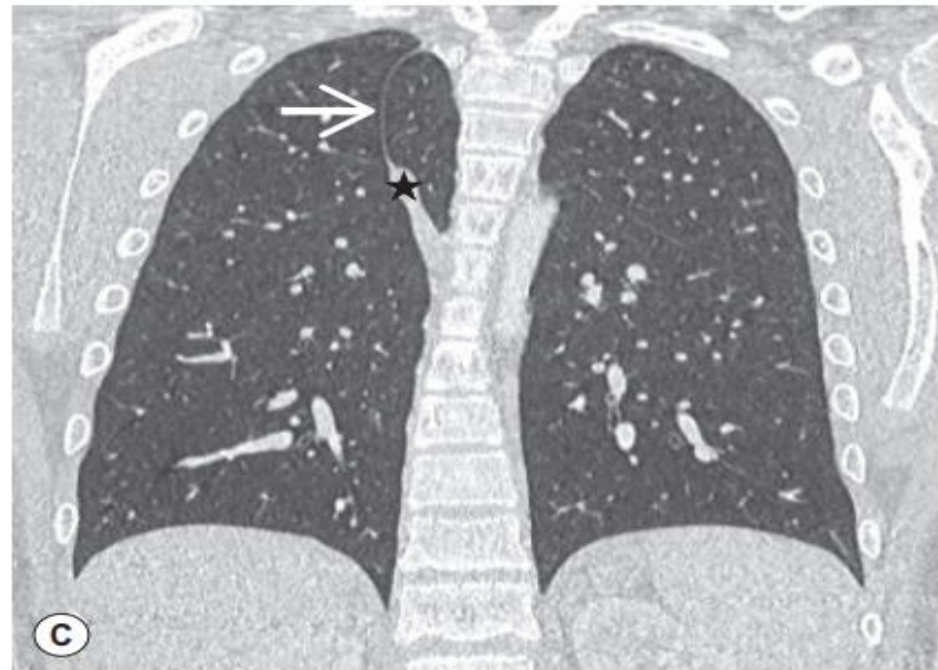
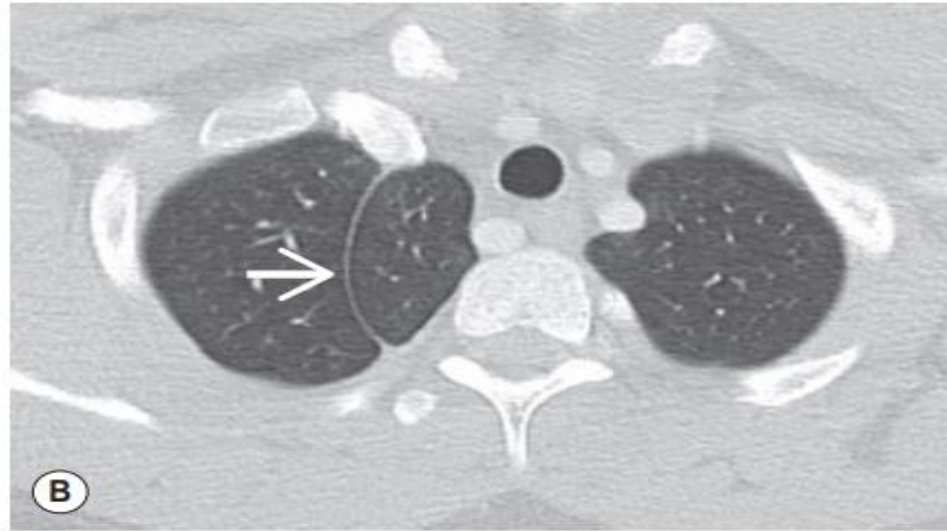
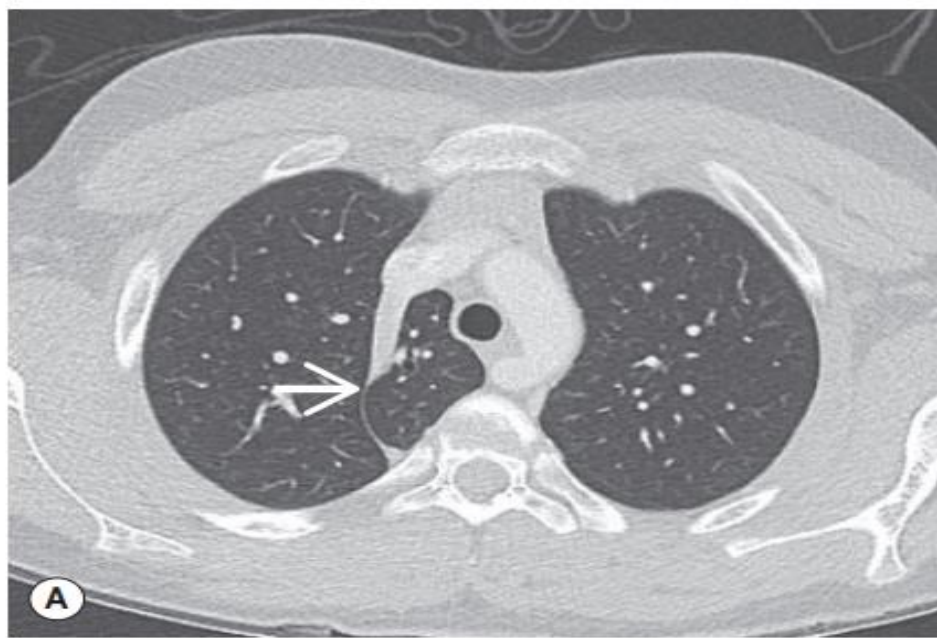
# Fissures on CT





**fig. 2.2** The position of fissures is often best shown in additional sagittal reformats (*arrows*) taken of the right lung (A) and left lung (B). The position of fissures is useful to assess for volume loss.





**Fig. 2.3** Azygos Lobe Fissure and Azygos Vein. The axial reconstruction shows the azygos vein (A) and the azygos fissure (B). The appearance of the fissure (*arrows*) and the vein (*asterisk*) on coronal reconstruction



RIGHT

Upper Lobe

■ Apical

■ Posterior

■ Anterior

Middle Lobe

■ Lateral

■ Medial

Lower Lobe

■ Superior

■ Medial

■ Anterior

■ Lateral

■ Posterior

LEFT

Upper Lobe

■ Apicoposterior

■ Anterior

■ Superior lingular

■ Inferior lingular

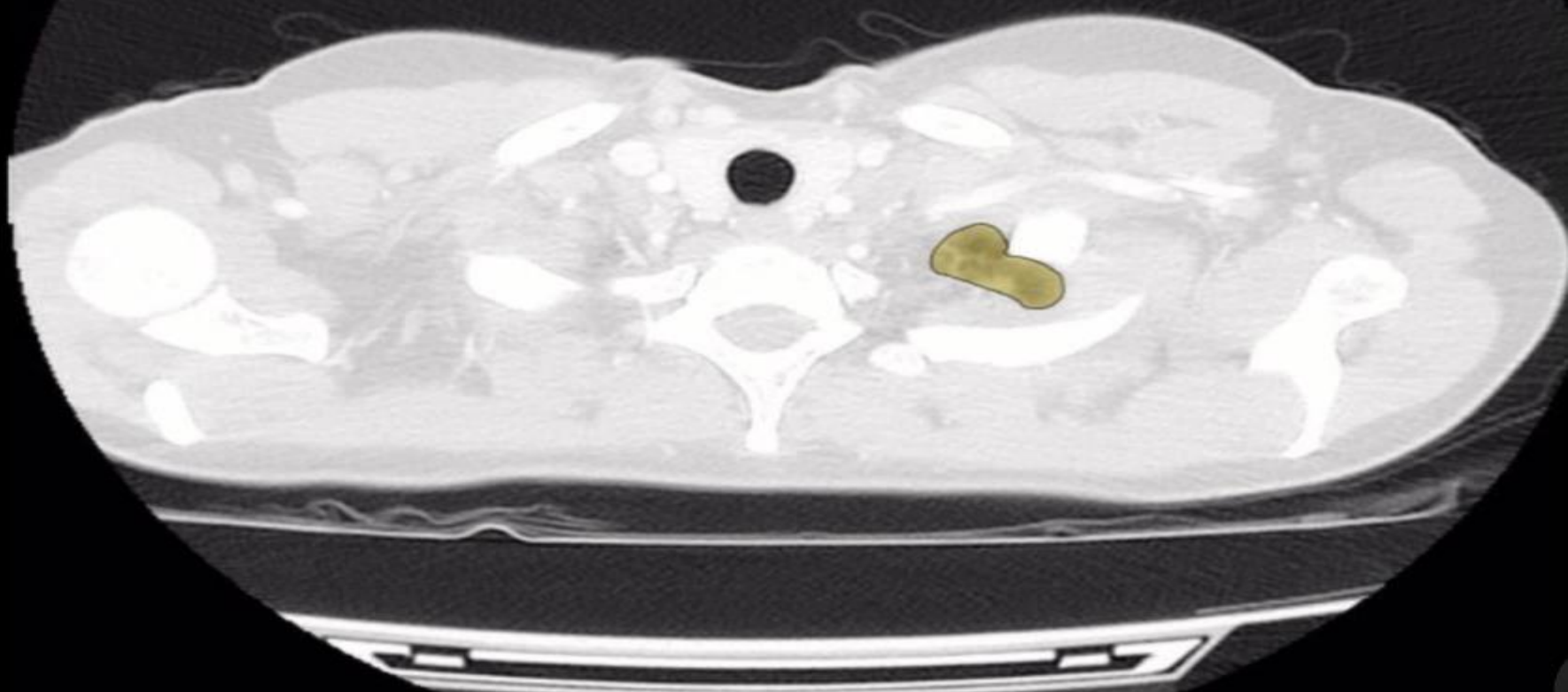
Lower Lobe

■ Superior

■ Anteromedial

■ Lateral

■ Posterior

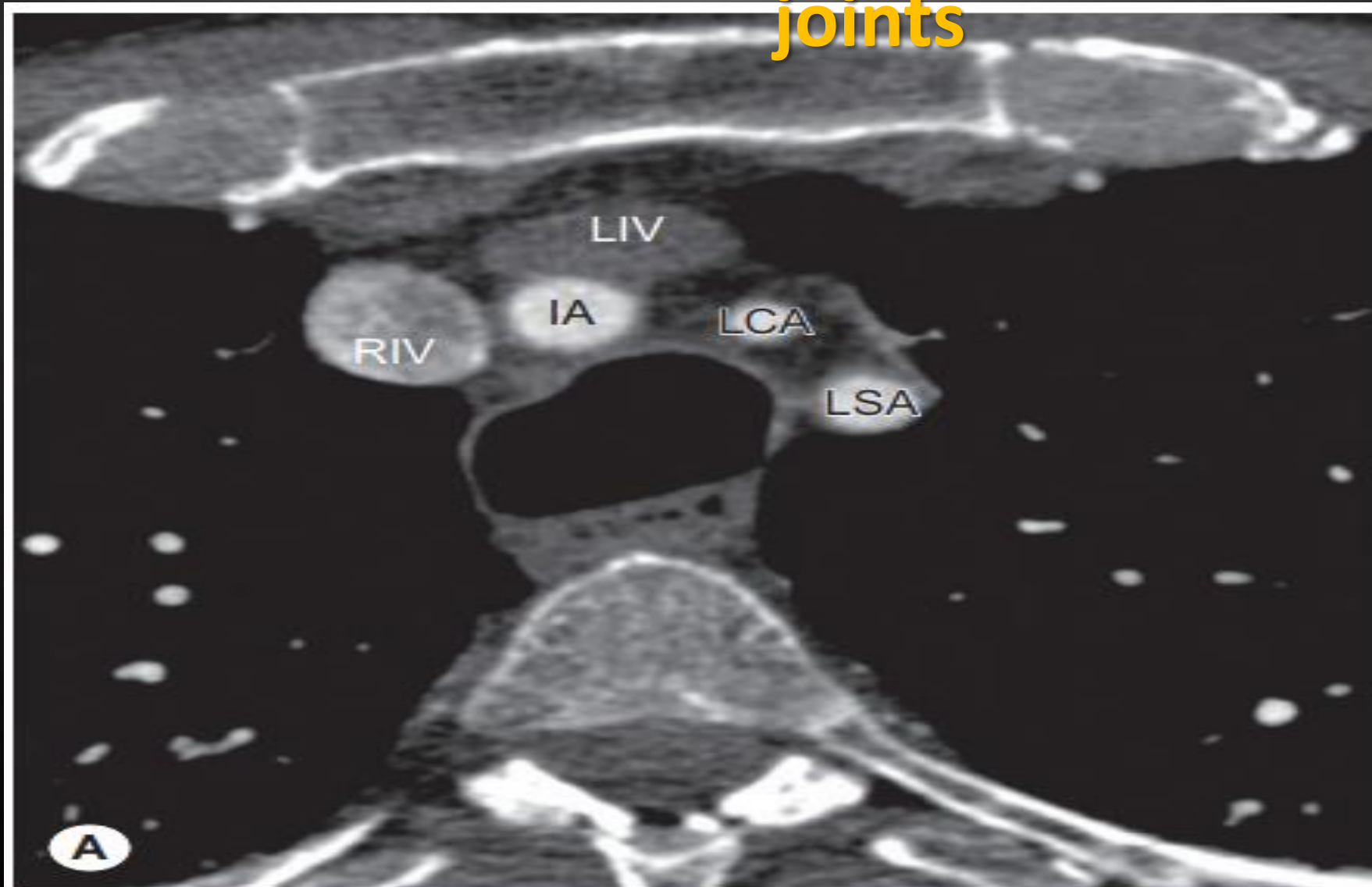




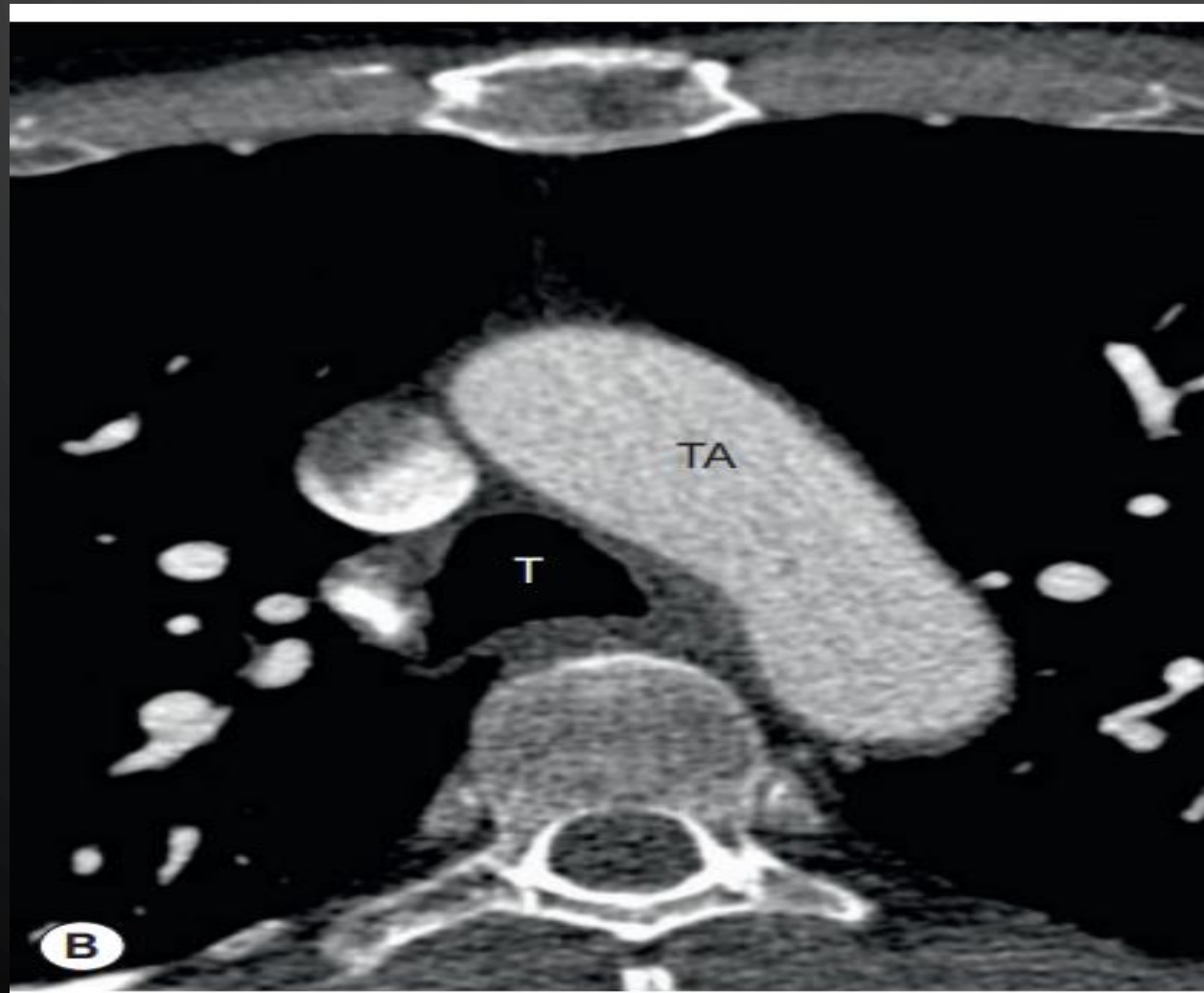# Overview

- Normal Chest Radiograph Anatomy
- Signs on Chest Radiograph
- Bronchopulmonary Segments
- Normal mediastinal anatomy on CT chest
- Classification of Lung Cancer
- Imaging pattern of Lung Cancer
- Imaging of Various subtypes of Lung cancer

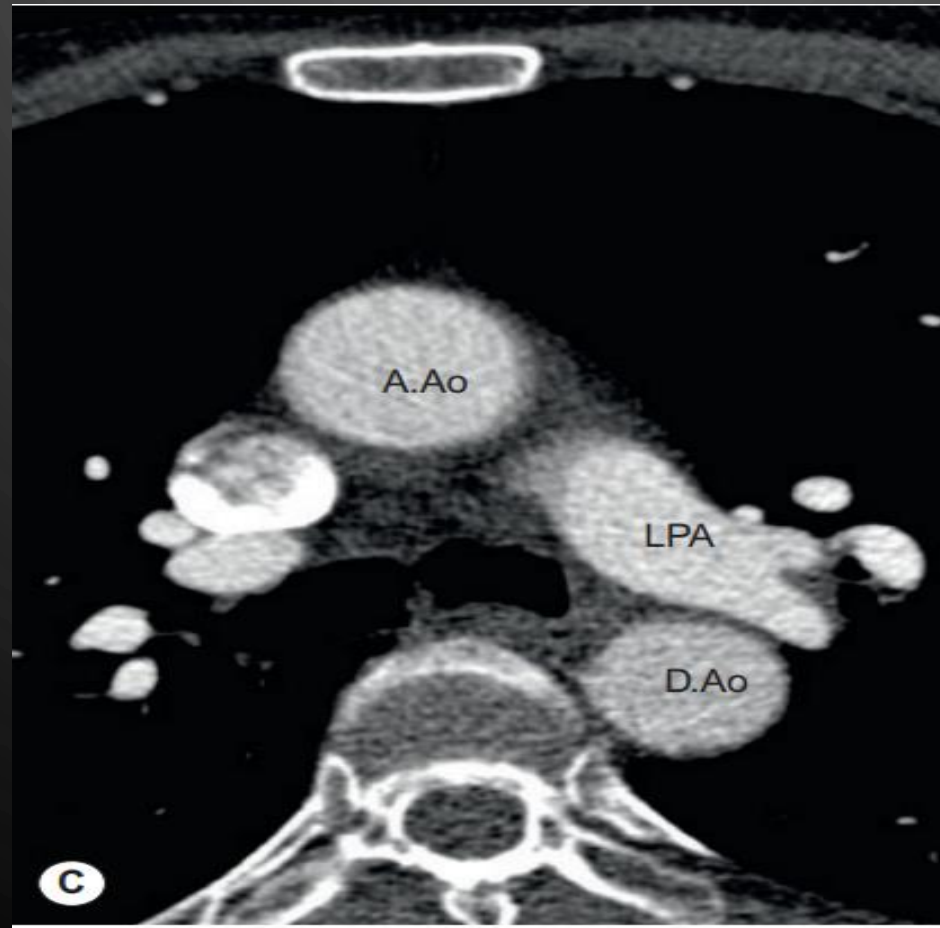
# Above the aortic arch at sternoclavicular joints



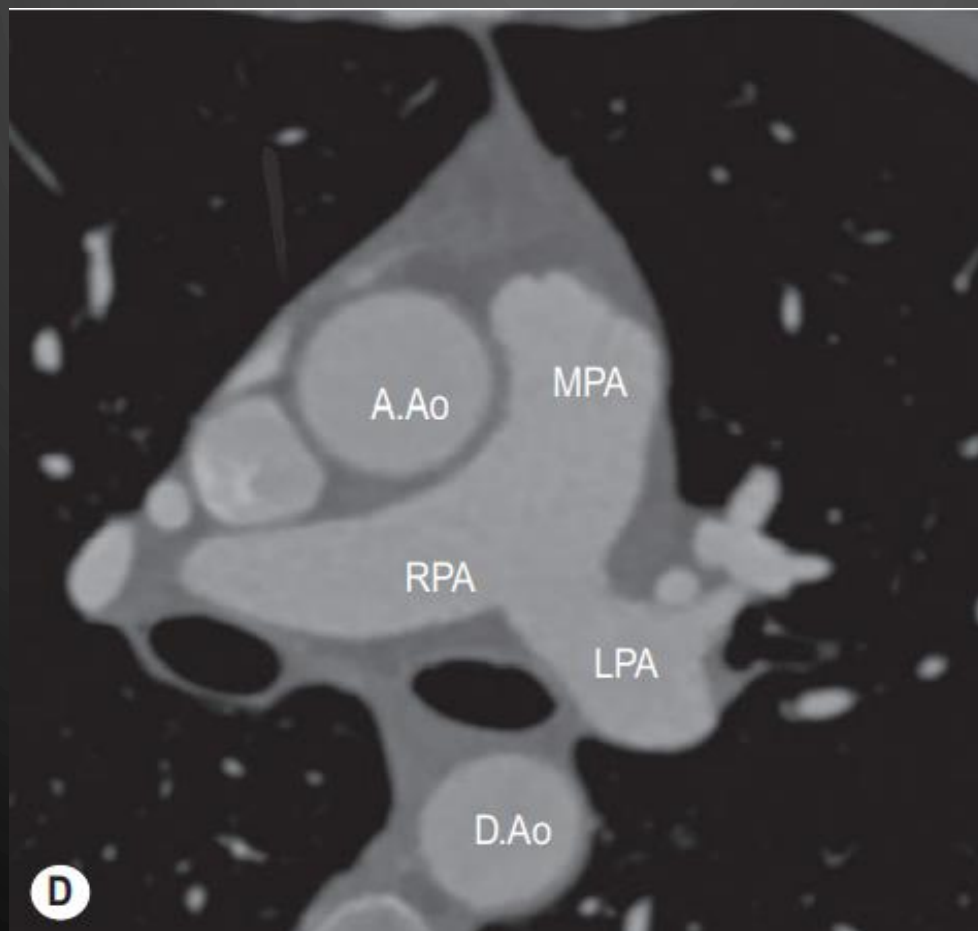
## At arch of aorta



# Below the aortic arch through the aortopulmonary window

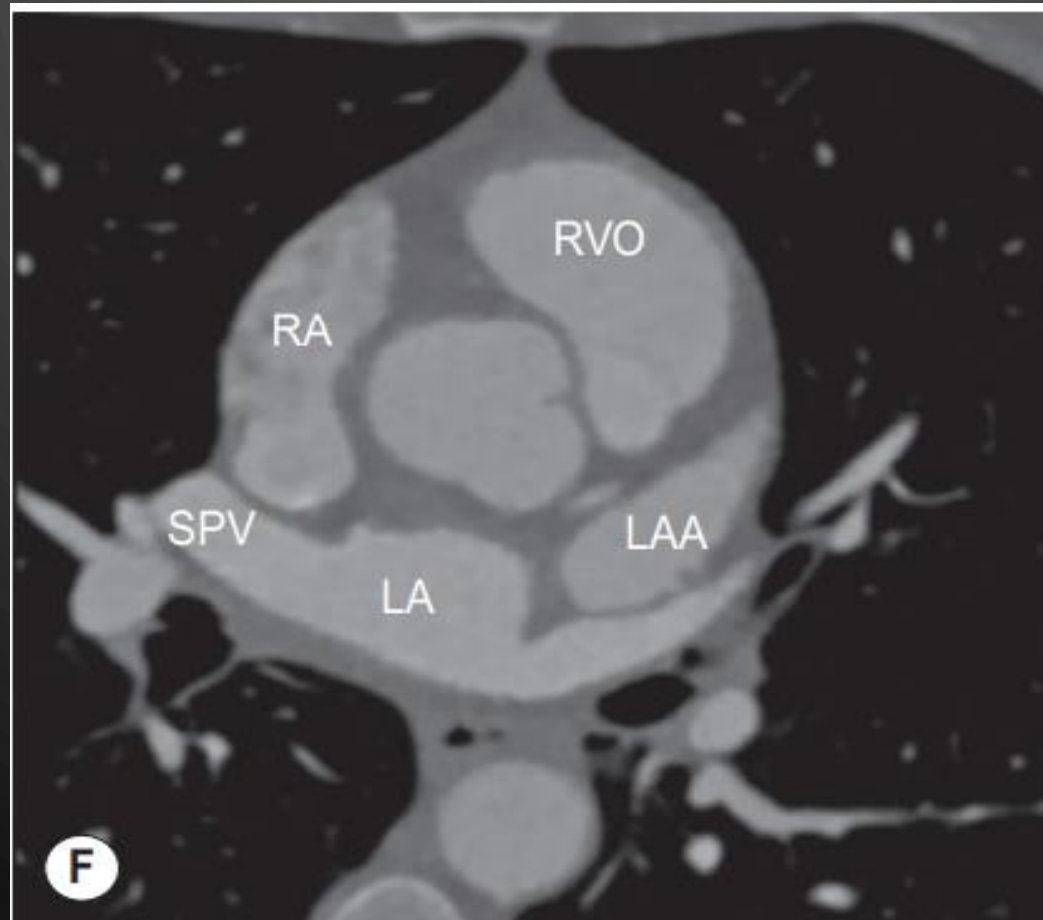


# Main pulmonary artery and its branches

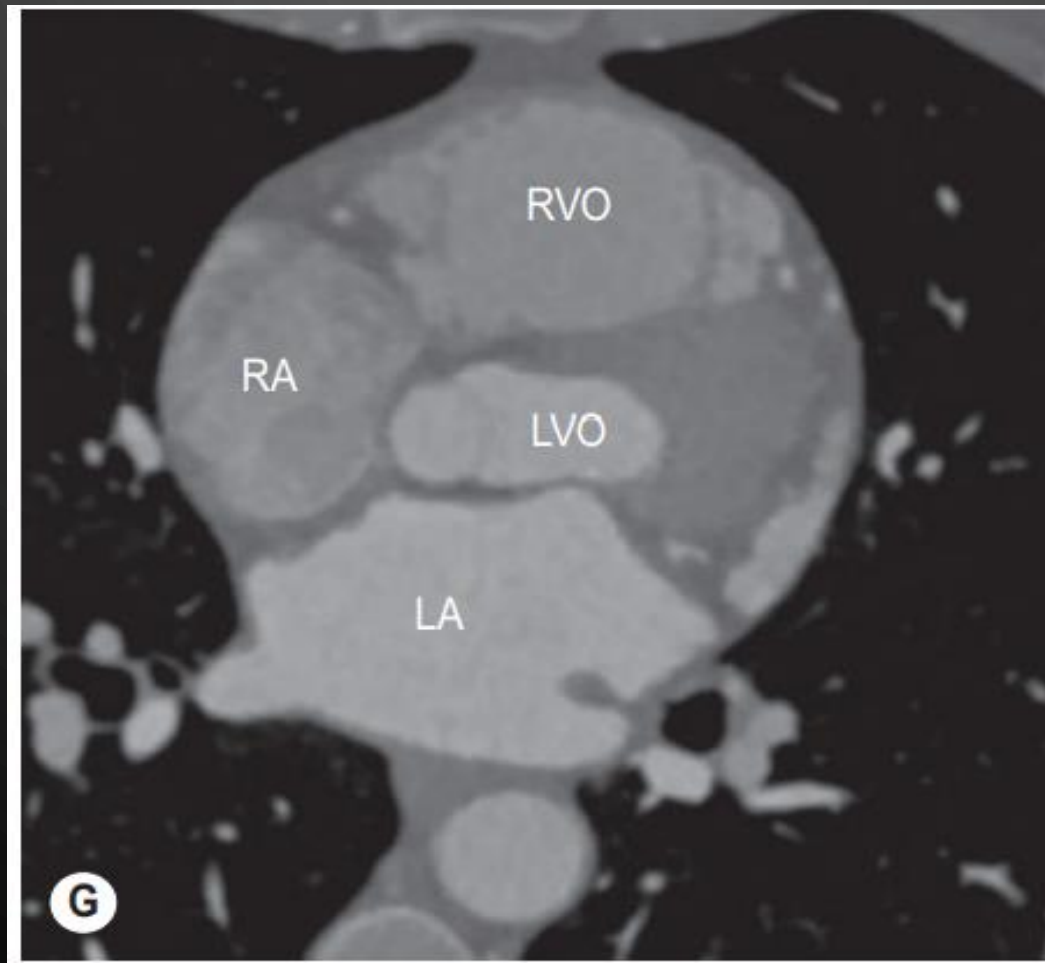




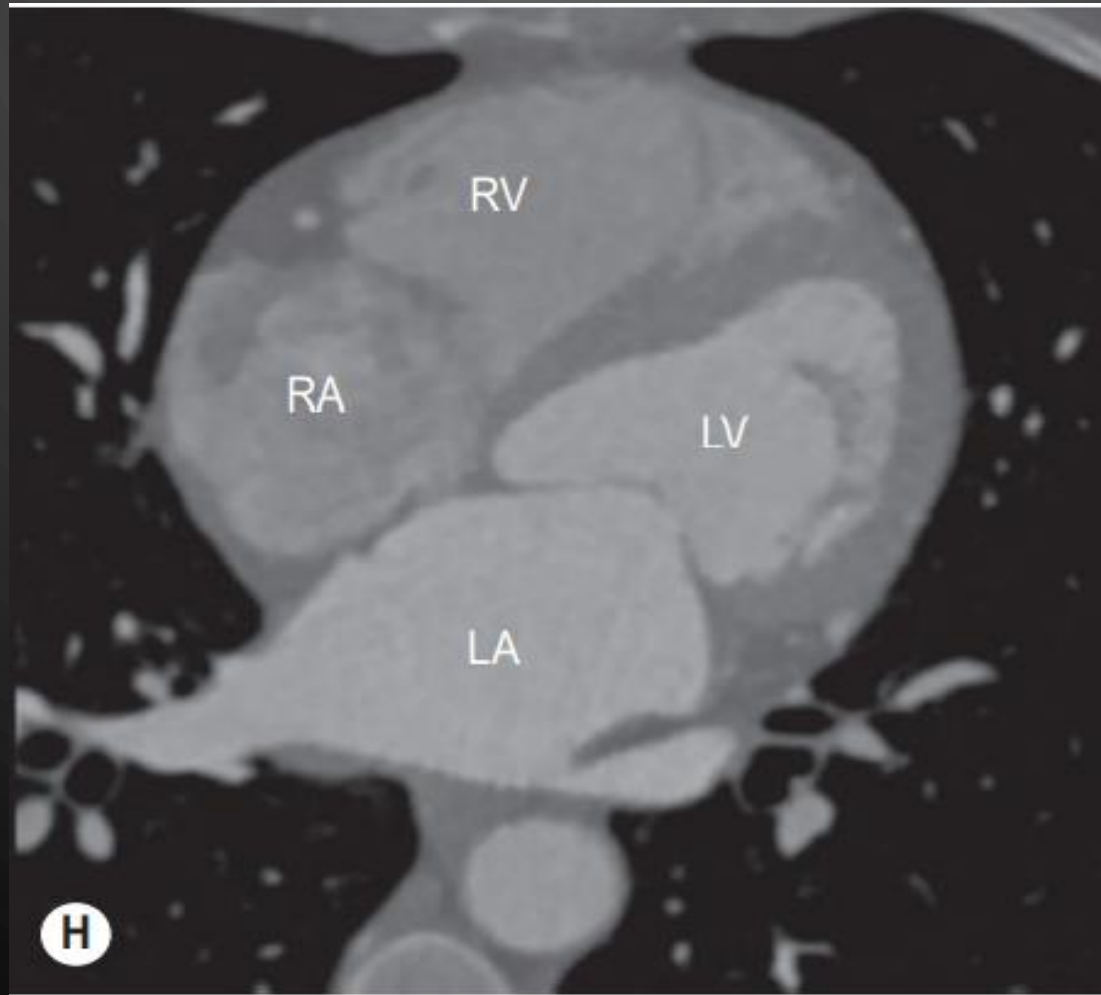
# Left and right atria



# Cardiac Level



# Left and right ventricles



# Overview

- Normal Chest Radiograph Anatomy
- Signs on Chest Radiograph
- Bronchopulmonary Segments
- Normal mediastinal anatomy on CT chest
- Classification of Lung Cancer
- Imaging pattern of Lung Cancer
- Imaging of Various subtypes of Lung cancer

# Definition

LUNG CANCER or BRONCHOGENIC CARCINOMA is a malignant neoplasm of the lung arising from the epithelium of the bronchus or bronchiole.

It is the leading cause of cancer mortality worldwide in both men and women and accounts for approx. 20 % of all cancer deaths.



# Epidemiology

Lung cancer is the most common fatal malignancy worldwide both in male and female. The major risk factor is CIGARATTE SMOKING which is implicated in 90% of the cases and increase the risk of lung cancer 20 – 30 times.

Other RISK FACTORS –

- Increasing age
- Occupational exposures – uranium , radon ,arsenic , chromium
- Asbestos – 5x increased risk
- Diffuse lung fibrosis – 10x increased risk
- Chronic obstructive pulmonary disease

# Classification

## According to anatomy –

- Central lung cancer - squamous cell carcinoma and small cell carcinoma.
- Peripheral lung cancer - adenocarcinoma and large cell carcinoma.

Central	Peripheral
Proximal to segmental bronchi	Distal to segmental bronchi
Hilar enlargement , dense hila sign	Appear as soft-tissue nodules or irregular masses
e.g. Small cell carcinoma	e.g. <u>Adenocarcinoma</u>
Bronchial Obstruction, Collapse or consolidation	Collapse or consolidation may occur, but are less obvious
Associated with hilar or <u>mediastinal</u> lymph node enlargement	

# Classification

## According to pathology –

- The term bronchogenic carcinoma is somewhat loosely used to refer to primary malignancies of the lung that are associated with inhaled carcinogens and includes four main histological subtypes.
- These are broadly divided into non small cell carcinoma (NSCLC) and small cell carcinoma as they differ clinically in terms of presentation , treatment and prognosis.

### Non small cell lung cancer (NSCLC)

- squamous cell lung carcinoma
- adenocarcinoma
- large cell carcinoma

### Small cell lung cancer(SCLC)

# Imaging modalities

- Chest radiograph
- Computed tomography
- Magnetic resonance imaging
- Barium studies
- Ultrasonography
- Positron emission tomography
- Angiography

# Chest Radiograph

- First line of investigation
- Cheap
- Readily available
- Can depict most of the features of lung cancer and its complications



# Computed Tomography

- gold standard in diagnosis and staging of lung cancer
- cross sectional imaging with better depiction of anatomy
- gives clear depiction of mediastinal adenopathy and invasion of adjacent mediastinal structures

# MRI

- Excellent soft tissue resolution
- Depicts vascular invasion better than ct
- Imaging modality of choice in pancoast tumor
- Important in cases where CT is equivocal

# PET

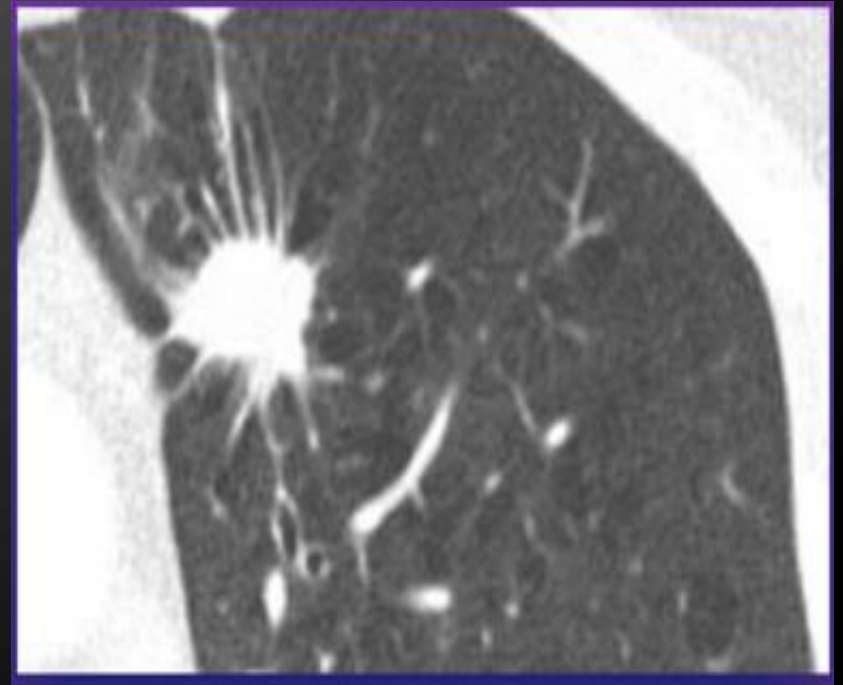
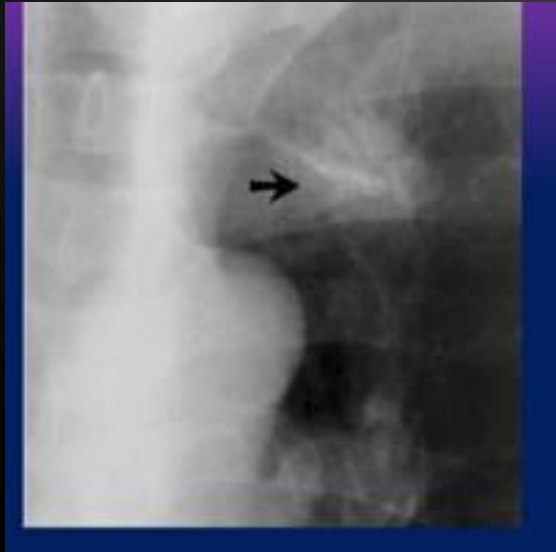- PROVIDES EXCELLENT DEPICTION OF FUNCTIONAL STATUS OF SUSPICIOUS LUNG MASSES
- HELPS TO SORT OUT STATUS OF NODAL ENLARGEMENT COEXISTING WITH LUNG MASS

# Presentation of lung tumours

- solitary peripheral nodule/pleural tail sign/satellite lesion/corona radiata sign
- ground glass haze
- consolidation
- cavitation
- central mass - common in small cell carcinoma
- unilateral hilar enlargement
- anterior and middle mediastinum widening(smcc)
- reverse golden s sign
- bronchial cutoff sign
- segmental/lobar/lung atelectasis
- local hyperaeration

# solitary pulmonary nodule / mass

- It is defined as discrete, well margined, round opacity less than or equal to 3 cm in diameter that is completely surrounded by lung parenchyma, does not touch the hilum or mediastinum, and is not associated with adenopathy, atelectasis or pleural effusion.
- Lesions larger than 3 cm are considered as masses and are treated as malignancies until proven otherwise.





- Compared to benign nodules, malignant nodules show a greater degree of enhancement following intravenous injection of iodinated contrast medium, such that an increase in attenuation on CT scanning of **GREATER THAN 20 HOUNSFIELD UNITS** is very suggestive of malignancy.
- Bronchial carcinomas usually have a doubling time of between 1 and 18 months. Therefore, comparison with previous X-rays can be very helpful, and any mass or nodule that HAS NOT changed in appearance **OVER A 2-YEAR PERIOD** is almost certainly benign.

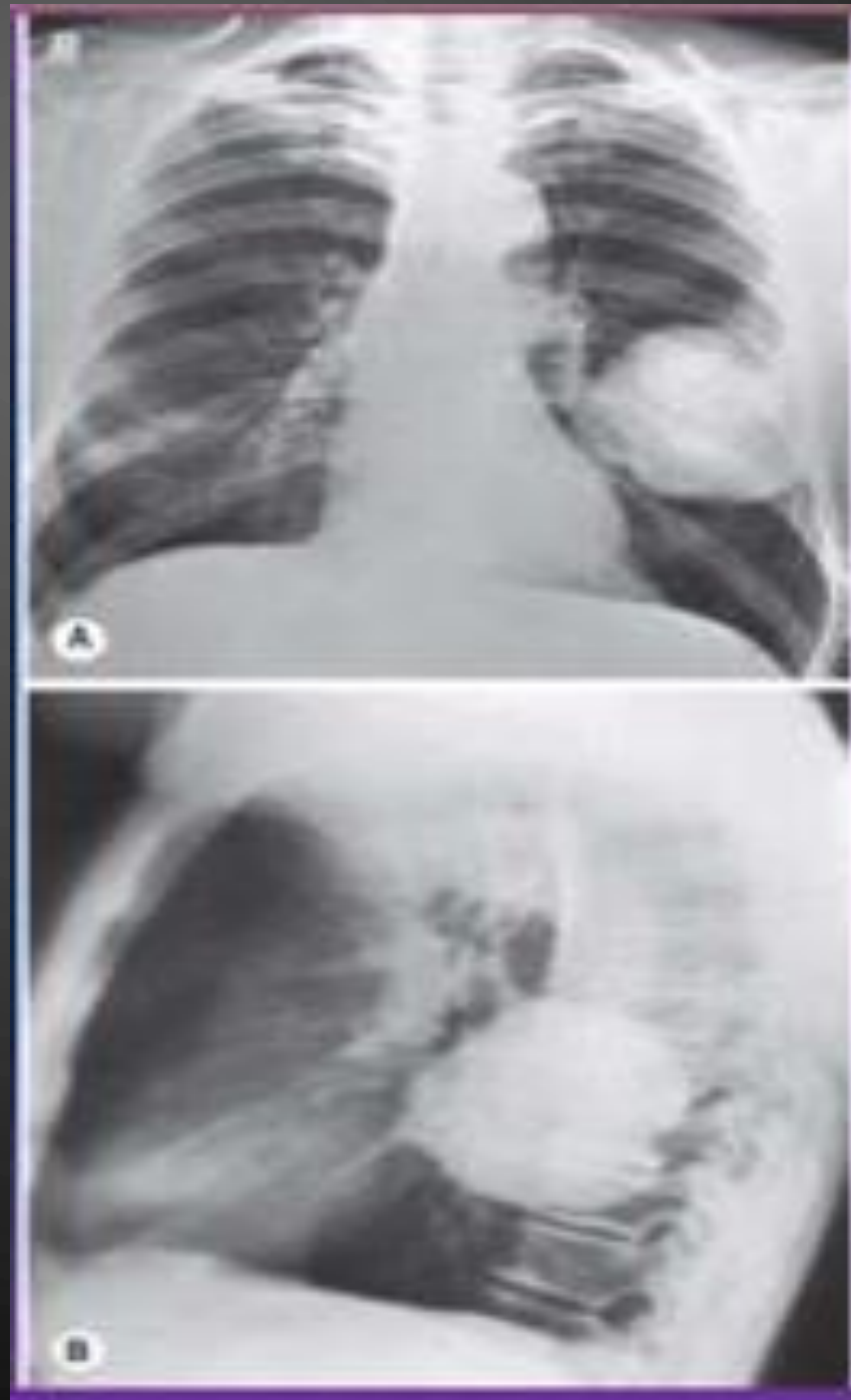# Peripheral mass

- A peripheral pulmonary mass on the chest X-ray is a common presentation of lung cancer. If other features are present, such as hilar enlargement or bony metastases, then the malignant nature of the mass is easily appreciated.

Benign	Malignant
Smaller	Larger
Satellite opacities around the main lesion are more frequently seen	May be associated with satellite opacities around the main lesion
Diffuse or central calcification in a peripheral pulmonary mass is very suggestive	Occasionally a calcified granuloma will have been engulfed by a malignant tumour.

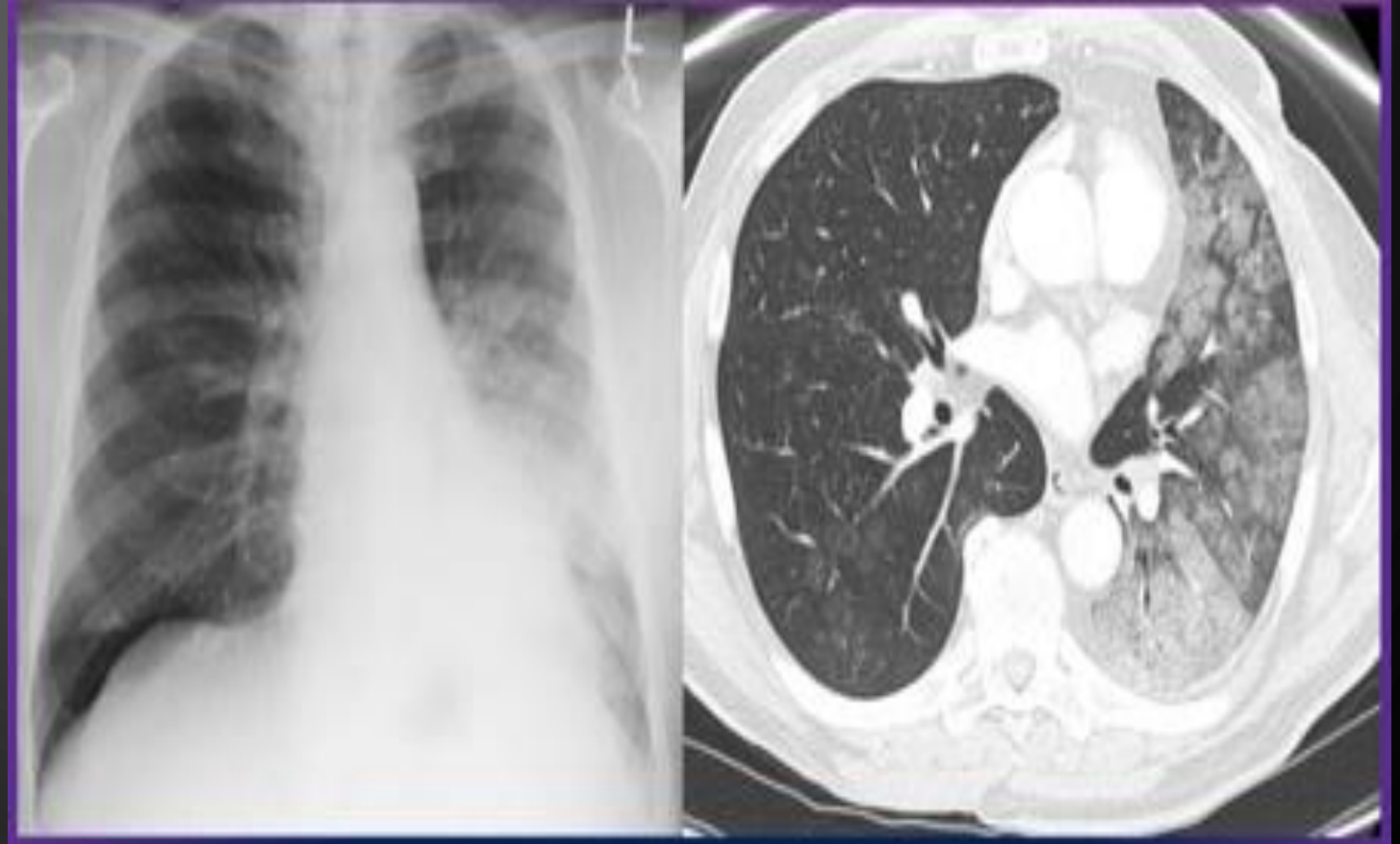
# Mass

- A Mass in left lower lobe showing typical rounded with slightly lobular configuration.



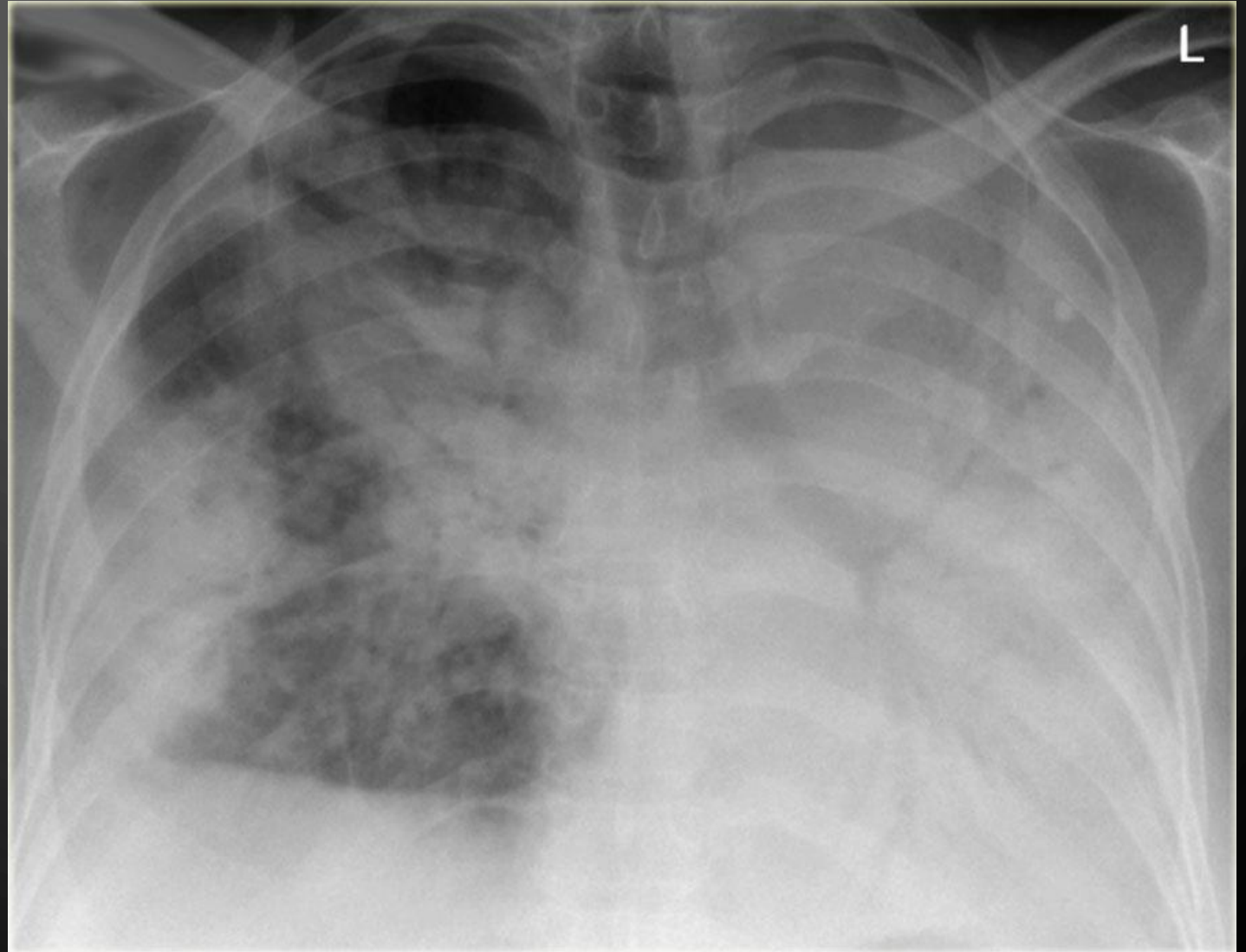
# Ground glass haze

- Areas of increased attenuation in lung on CT with preserved bronchial and vascular markings
- Early stage (due to lepidic growth pattern along septa with relative lack of acinar filling)
- Bubblelike hyperlucencies/ pseudocavitation
- Airway dilatation
- Lesion progresses within 6 to 8 weeks ..

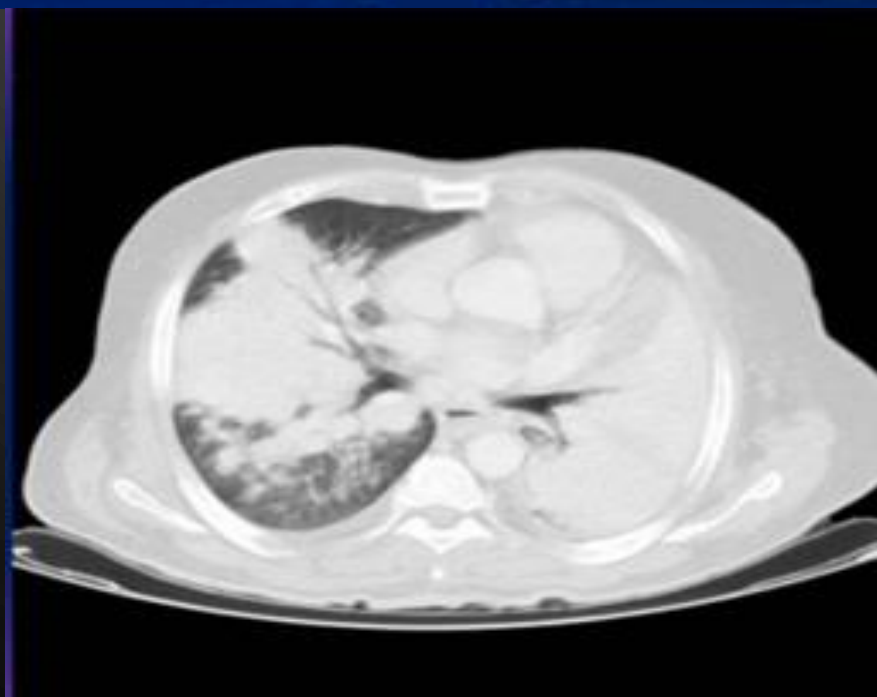
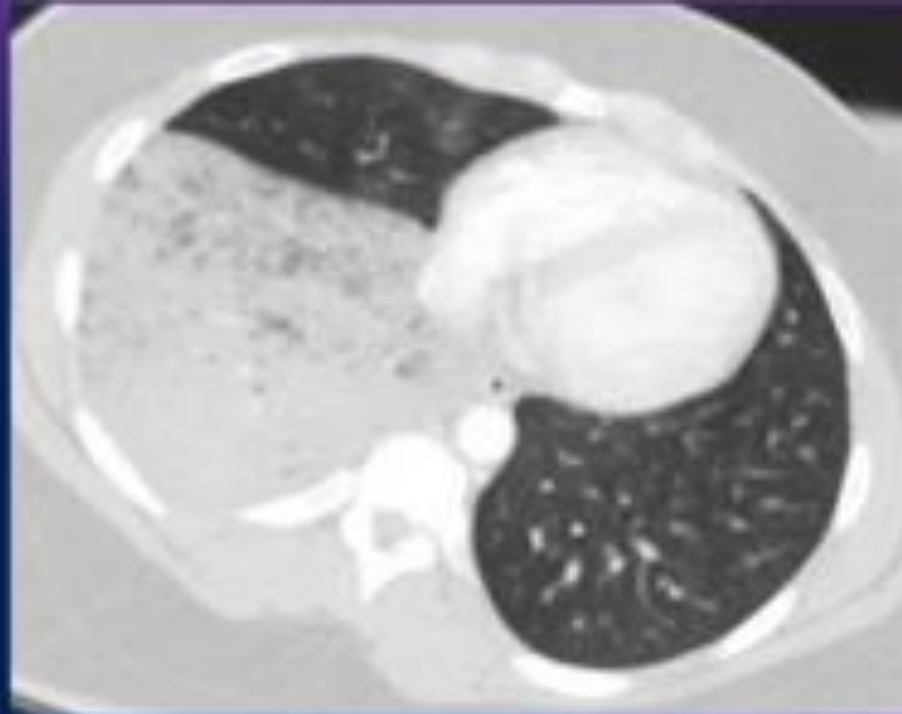
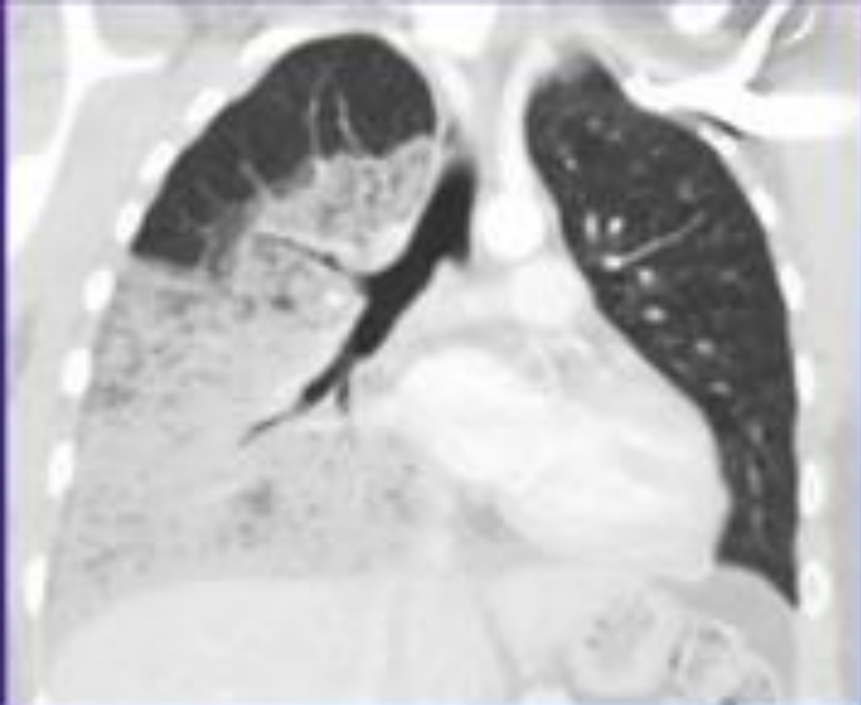


# Consolidation

- Any pathologic process that fills the alveoli with fluid, pus, blood, tumour cells resulting in lobar, diffuse or multifocal ill defined opacities
- Acinar airspace consolidation + air bronchogram + poorly margined borders +/- cavitations within consolidation

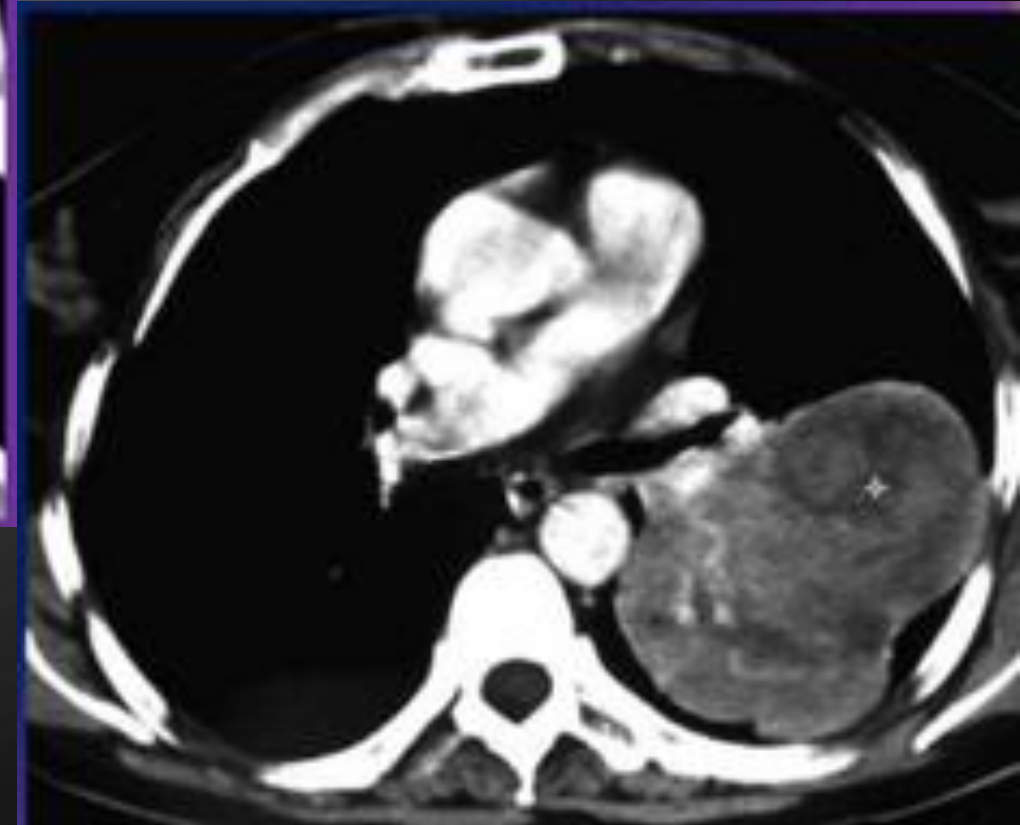
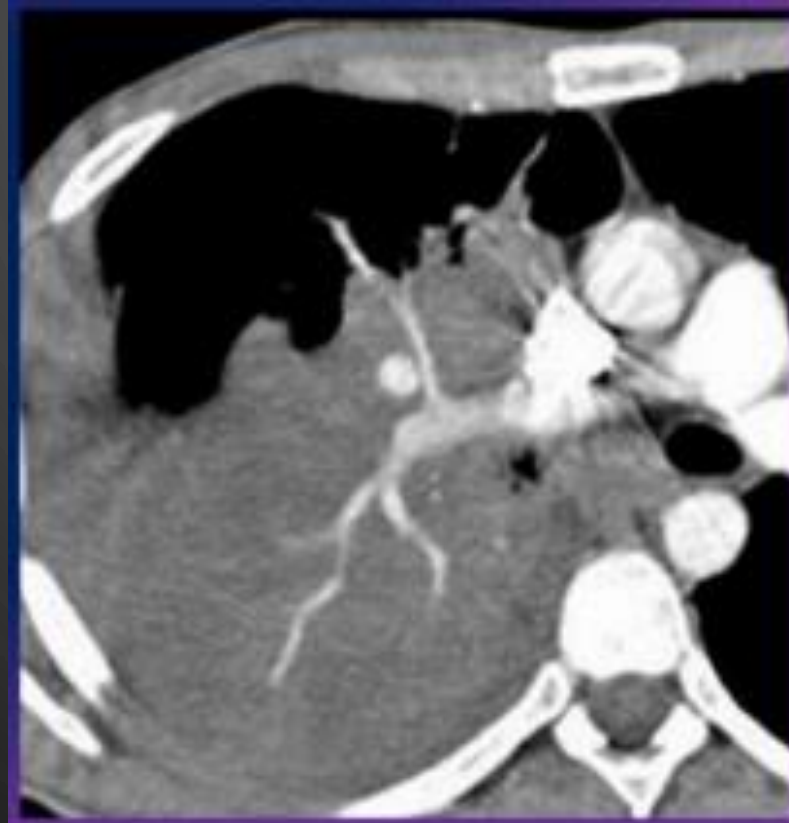





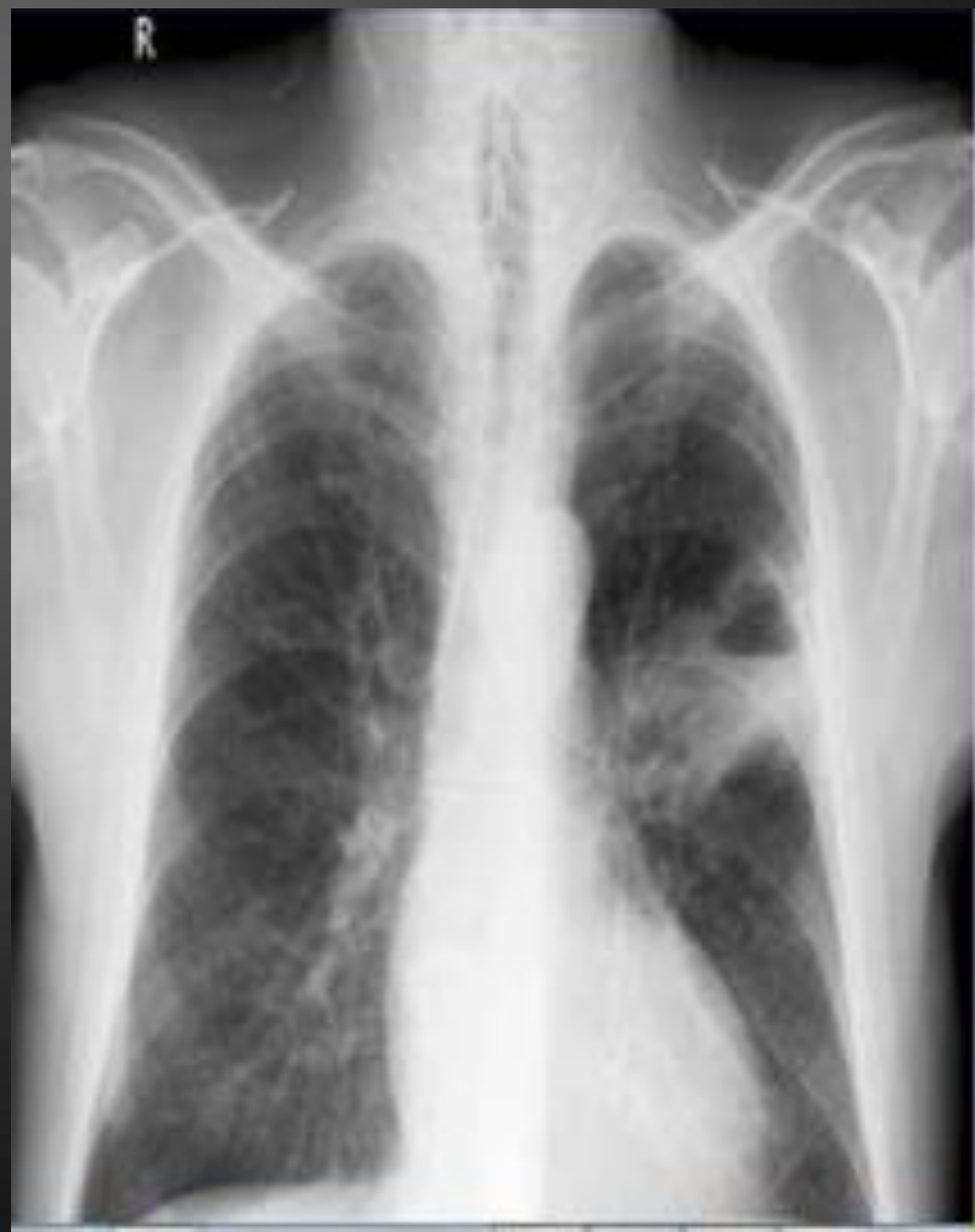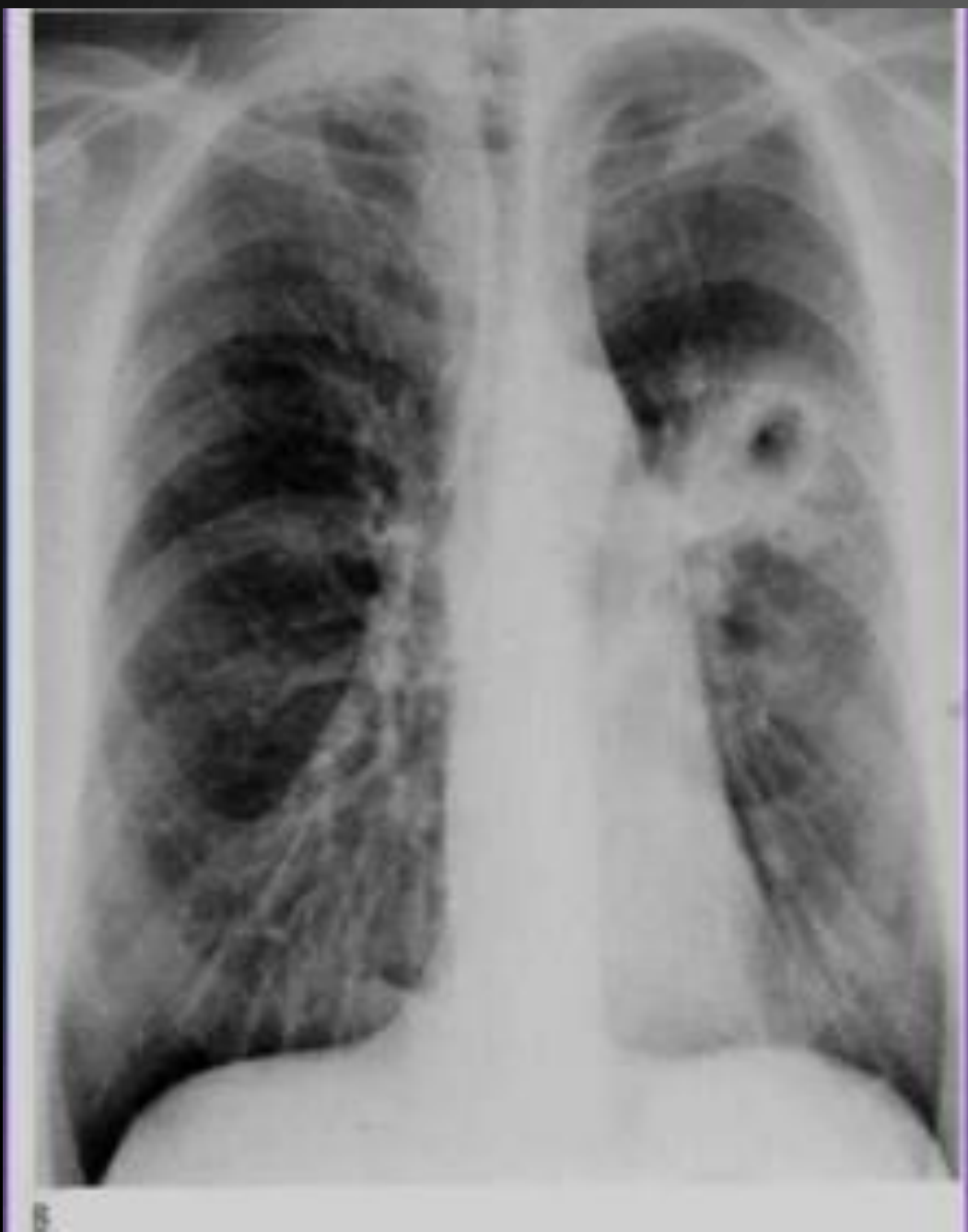# CT Angiogram sign

The CT angiogram sign is seen on contrast material enhanced scans and consists of enhancing branching pulmonary vessels in a homogenous low attenuating consolidation of lung parenchyma relative to chest wall musculature

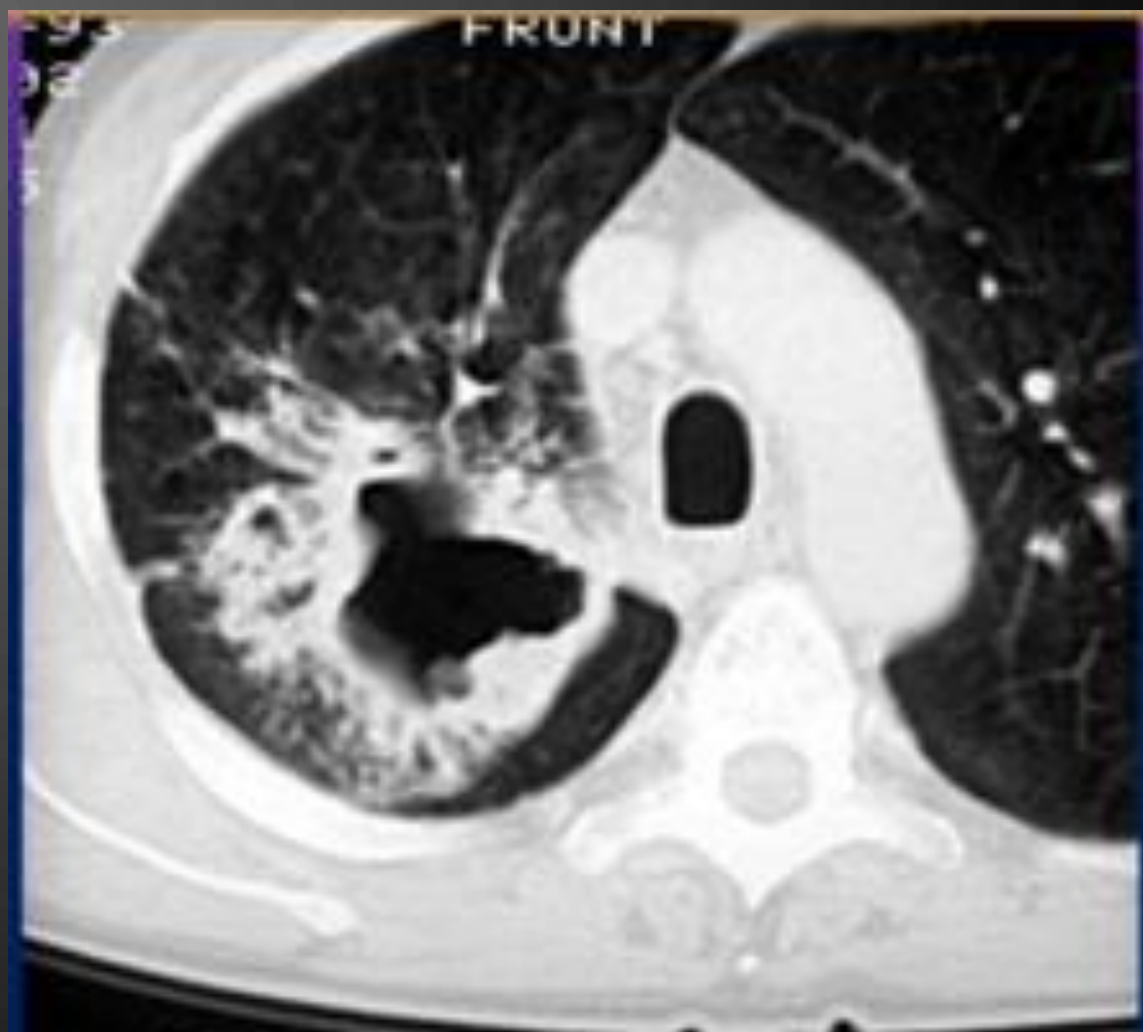
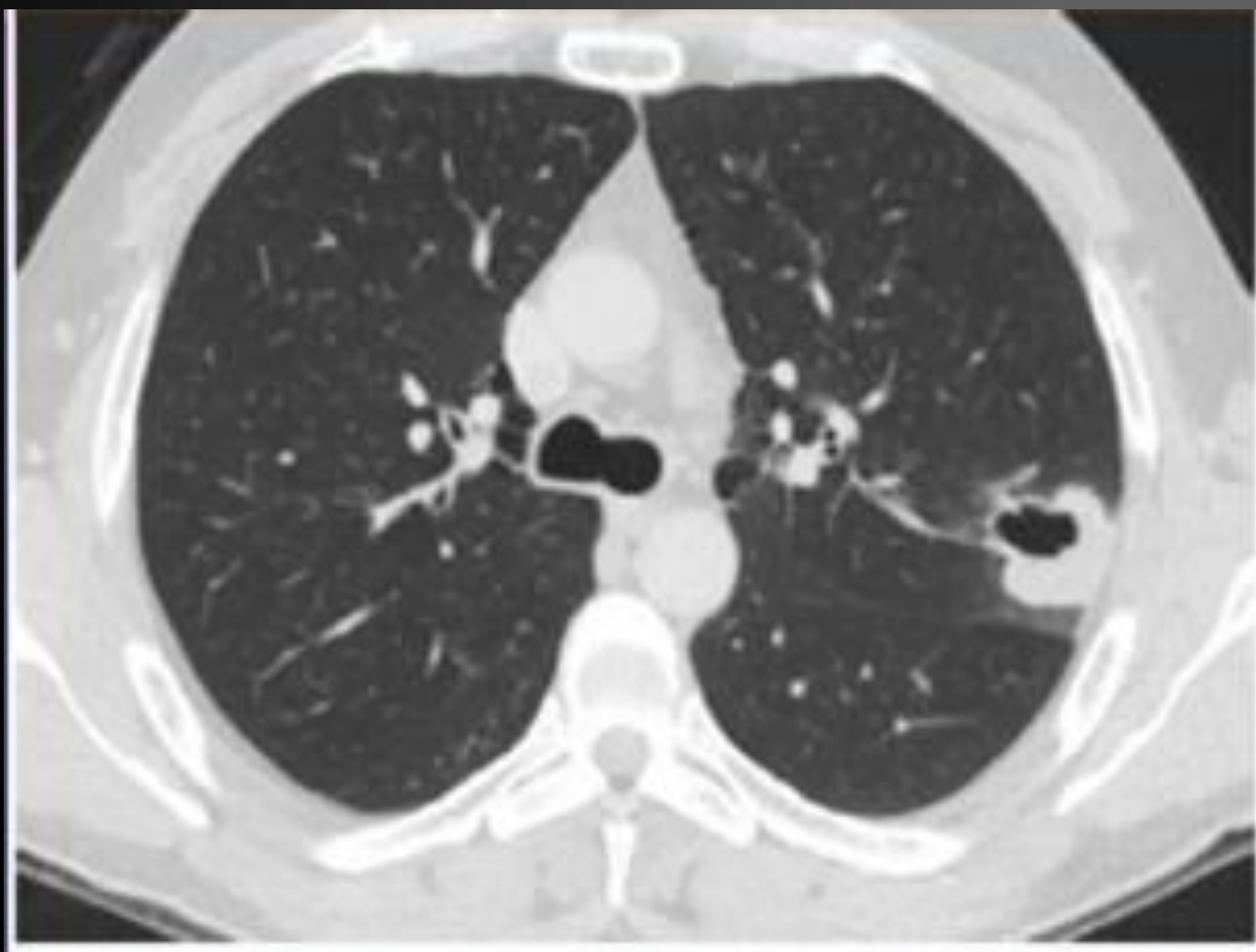


# Cavitation

- Typically, malignant cavities are **thick walled (>5mm)** with an irregular, nodular inner margin, but some may appear thinly walled. Because lung cancers tend to be associated with bronchial occlusion they virtually **never show an air bronchogram on the plain x-ray**.
- However, it is not unusual to see an air bronchogram on the CT of an adenocarcinoma, and it is a common finding in alveolar cell carcinoma.
- Secondary to squamous cell carcinoma followed by bronchoalveolar carcinoma.



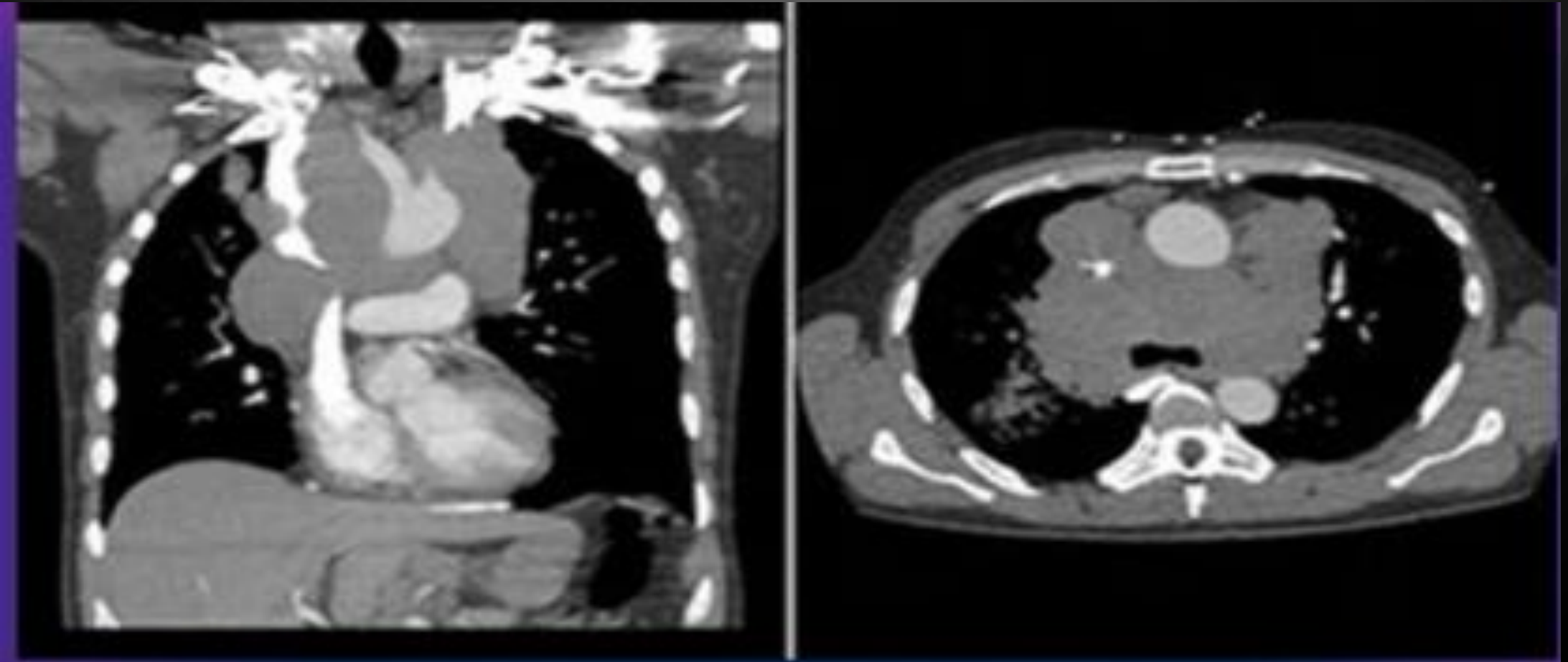






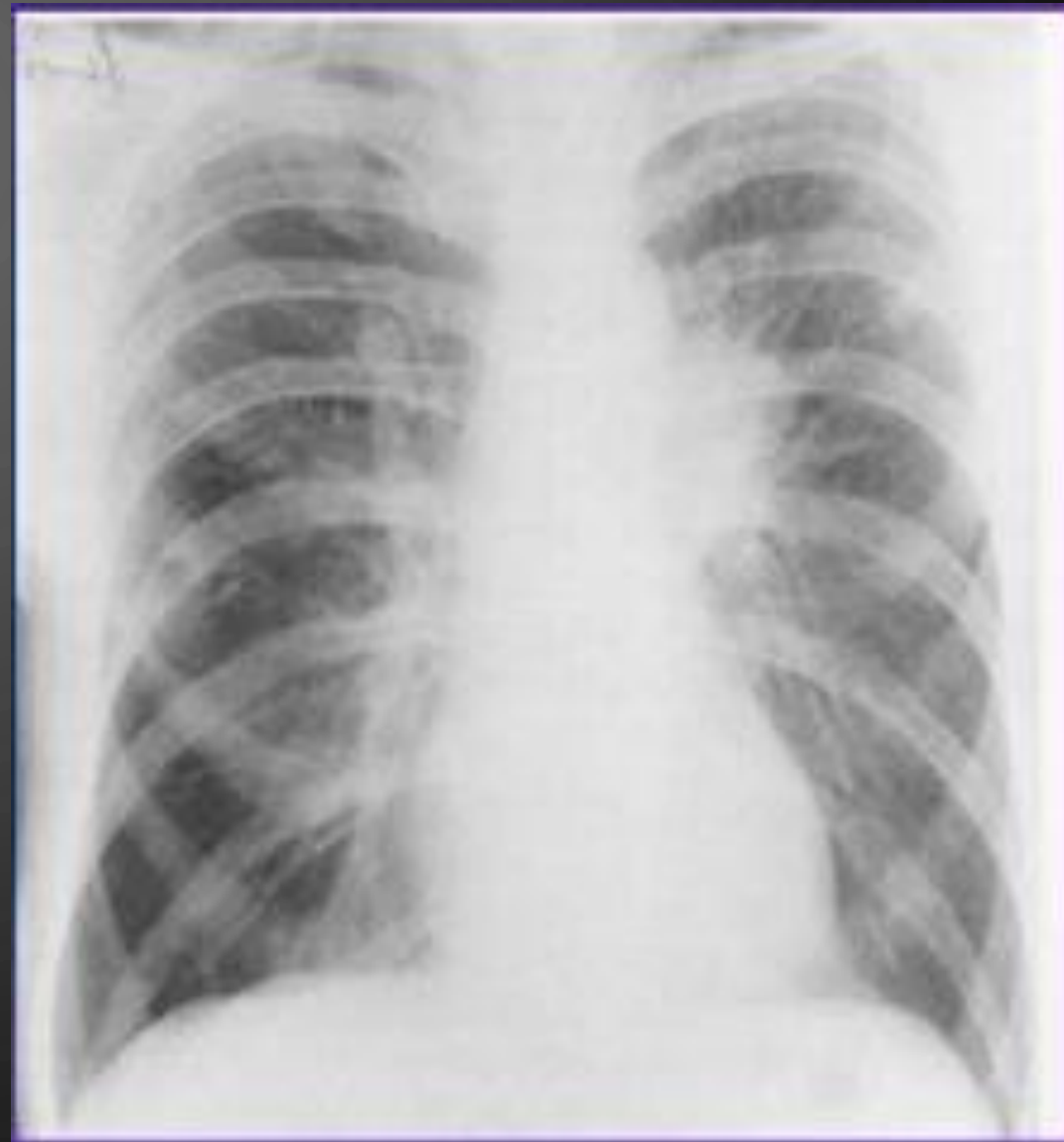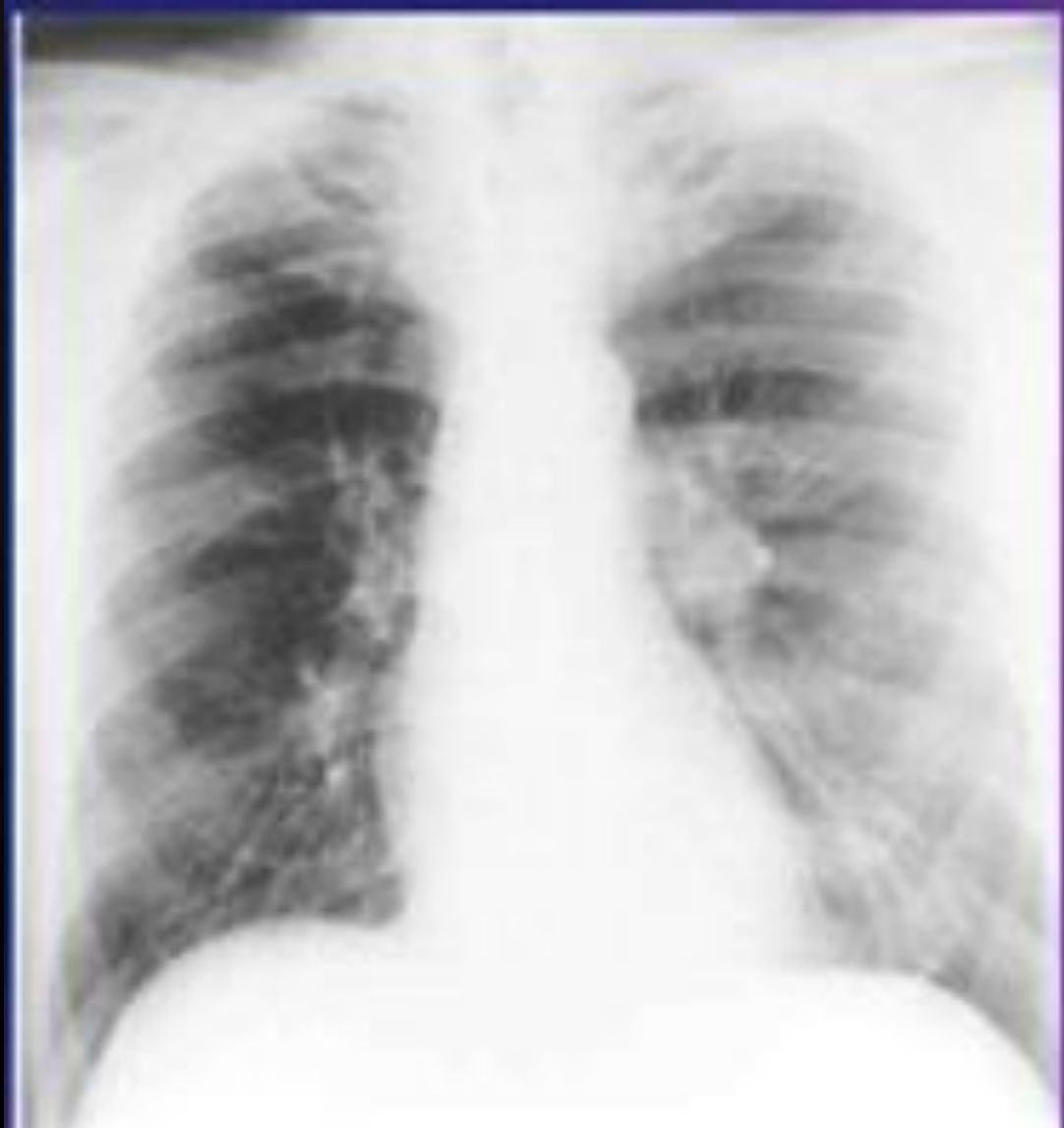# Central mass

- Common in small cell carcinoma.
- Central tumors may be visible on the chest radiograph as an abnormal convexity or density in the hilar region.

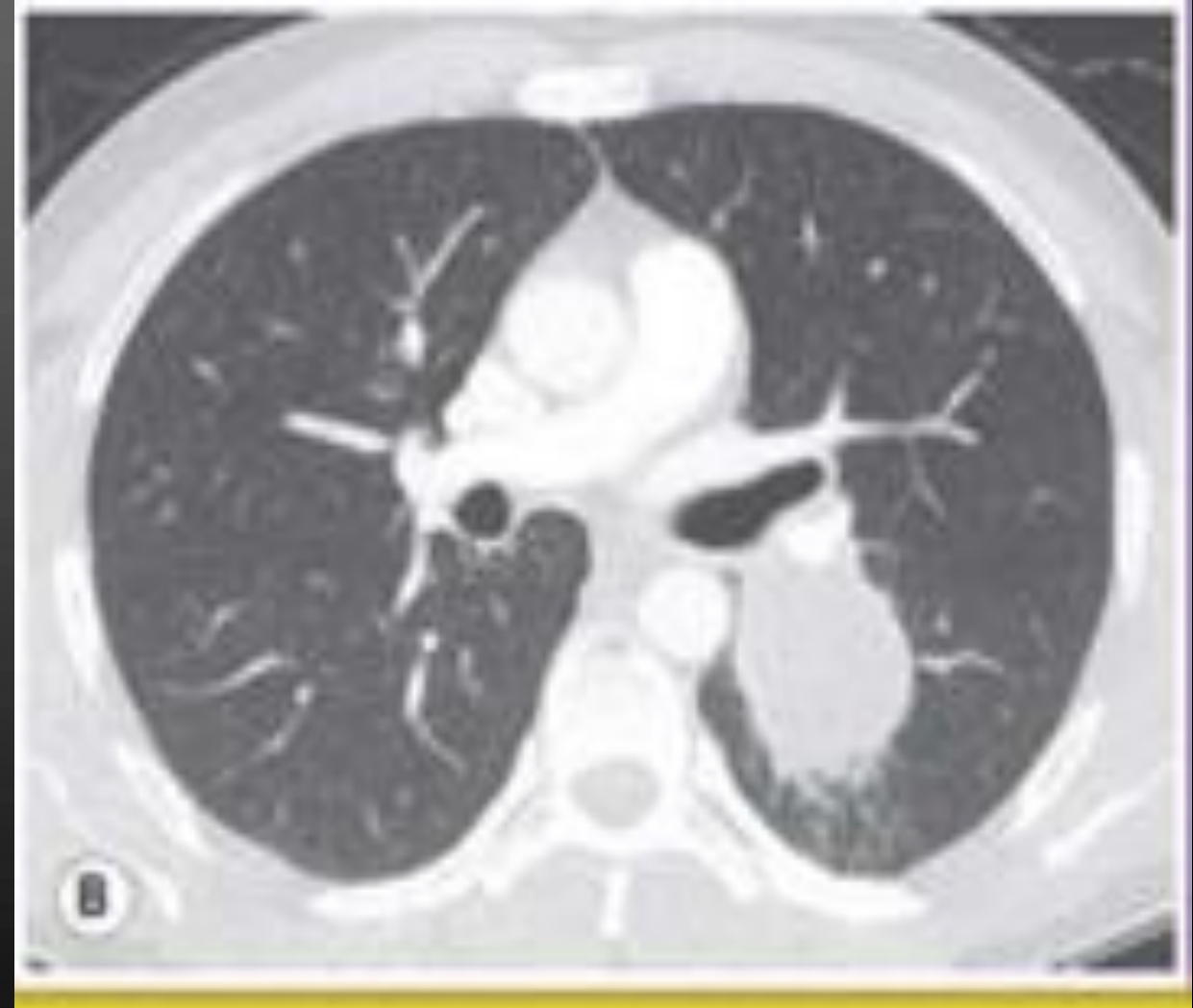
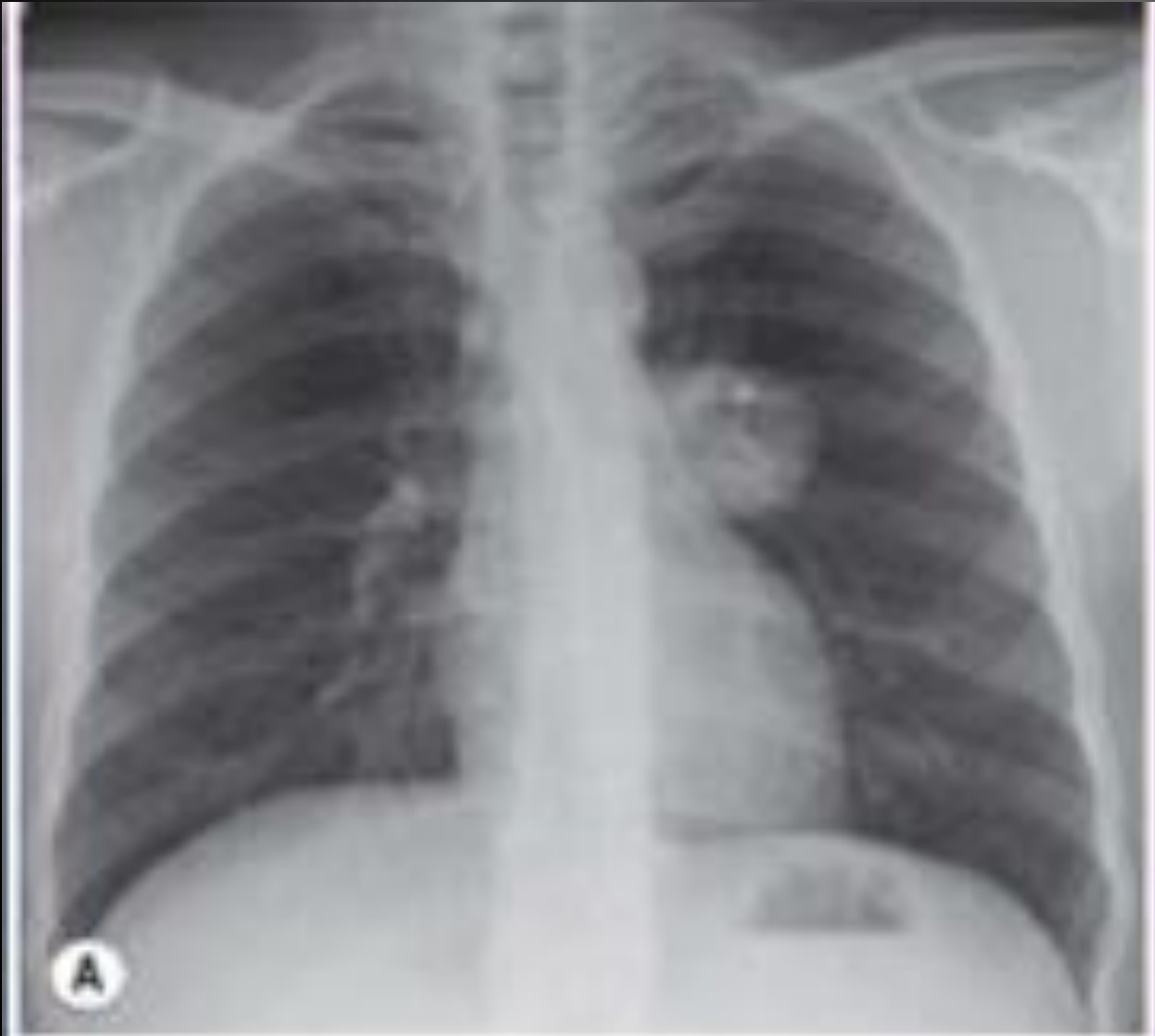
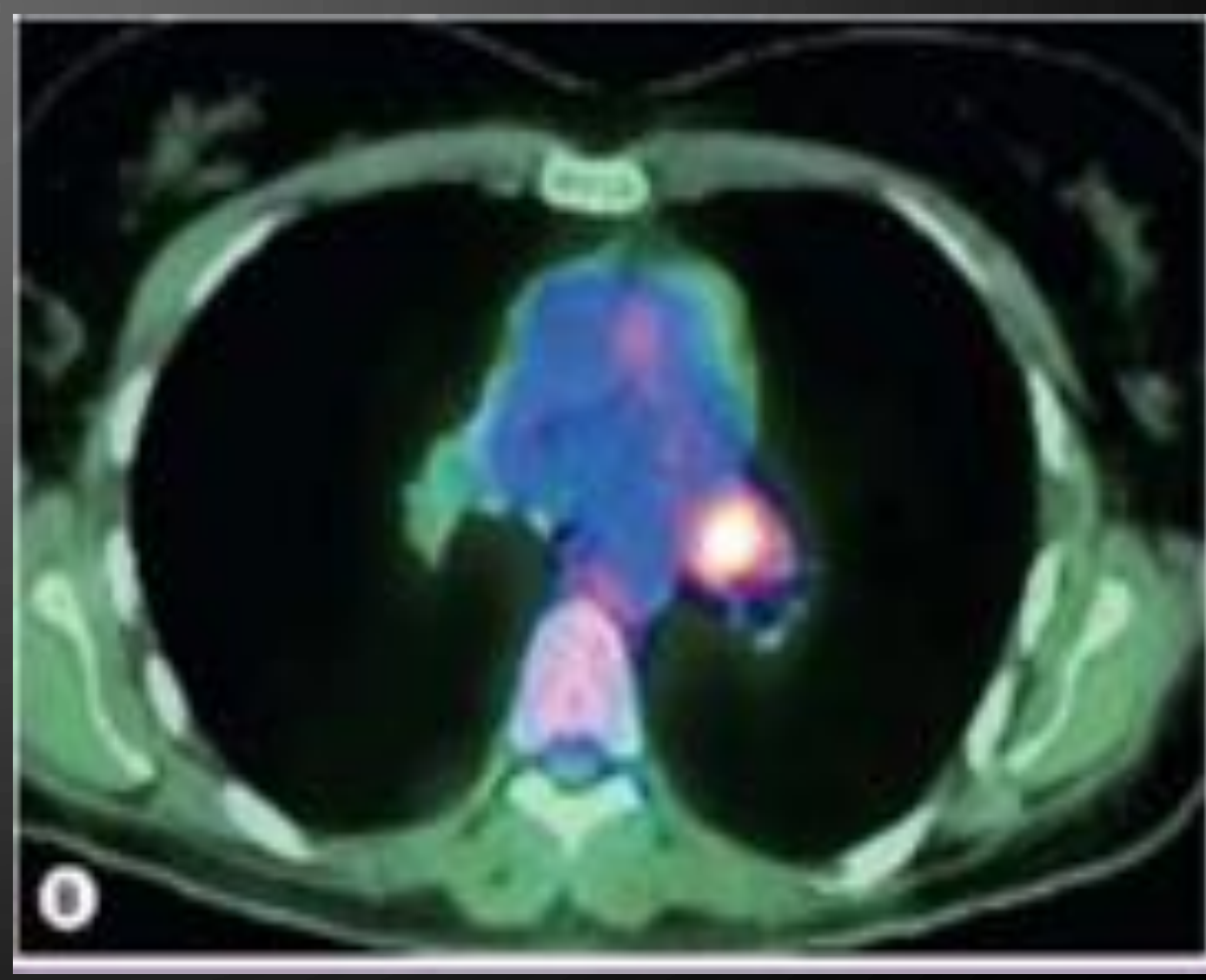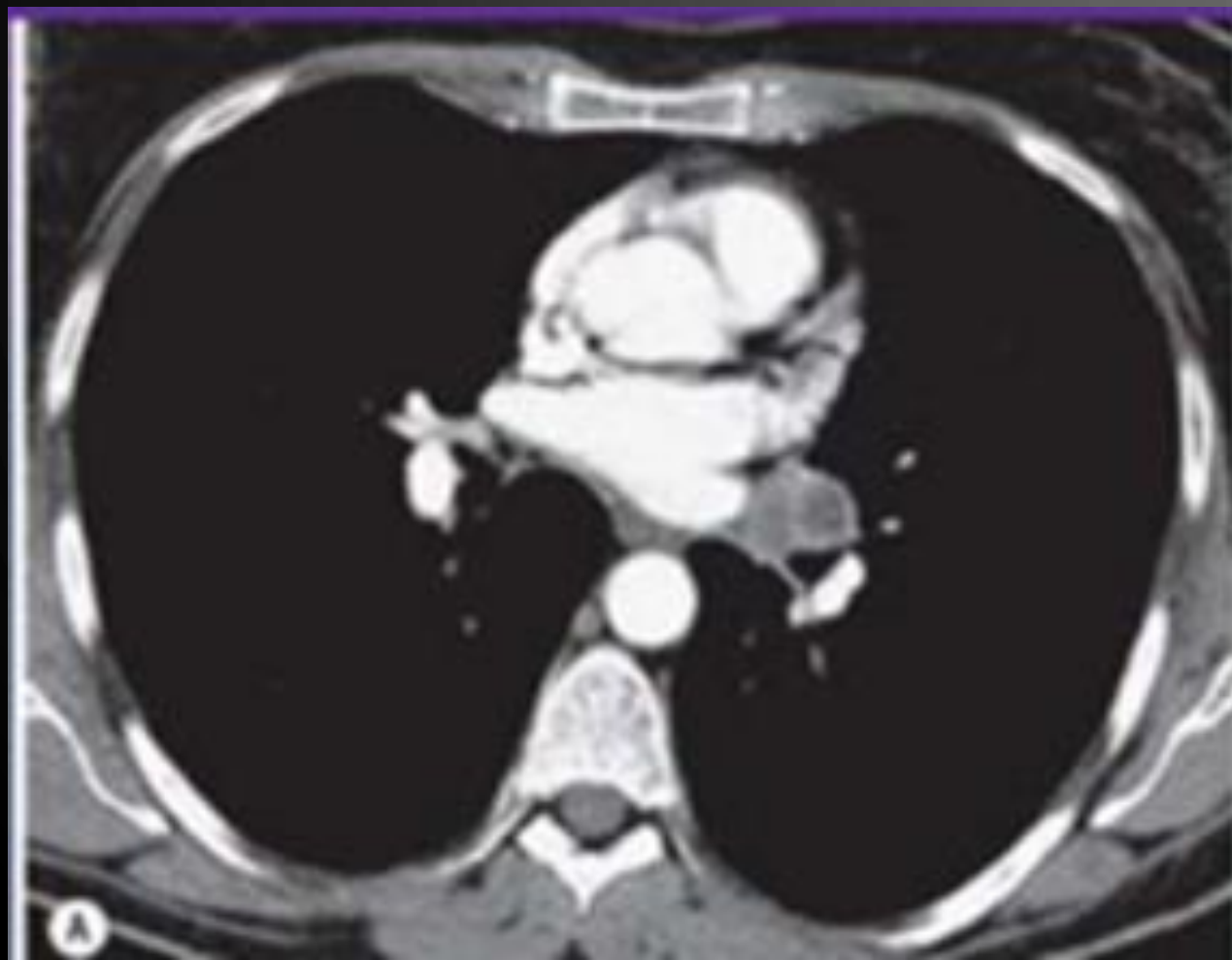# Unilateral hilar mass

- Unilateral hilar enlargement (secondary to primary tumour / enlarged lymph nodes)
- Calcified enlarged nodes frequently benign
- Nodes in short axis diameter –
  - a ) 0 – 10 mm normal suggests micro metastases.
  - b) > 10 mm (65% sensitive and specific for tumour)
- PET (89% sensitive , 99 % specific)



# Dense hilum

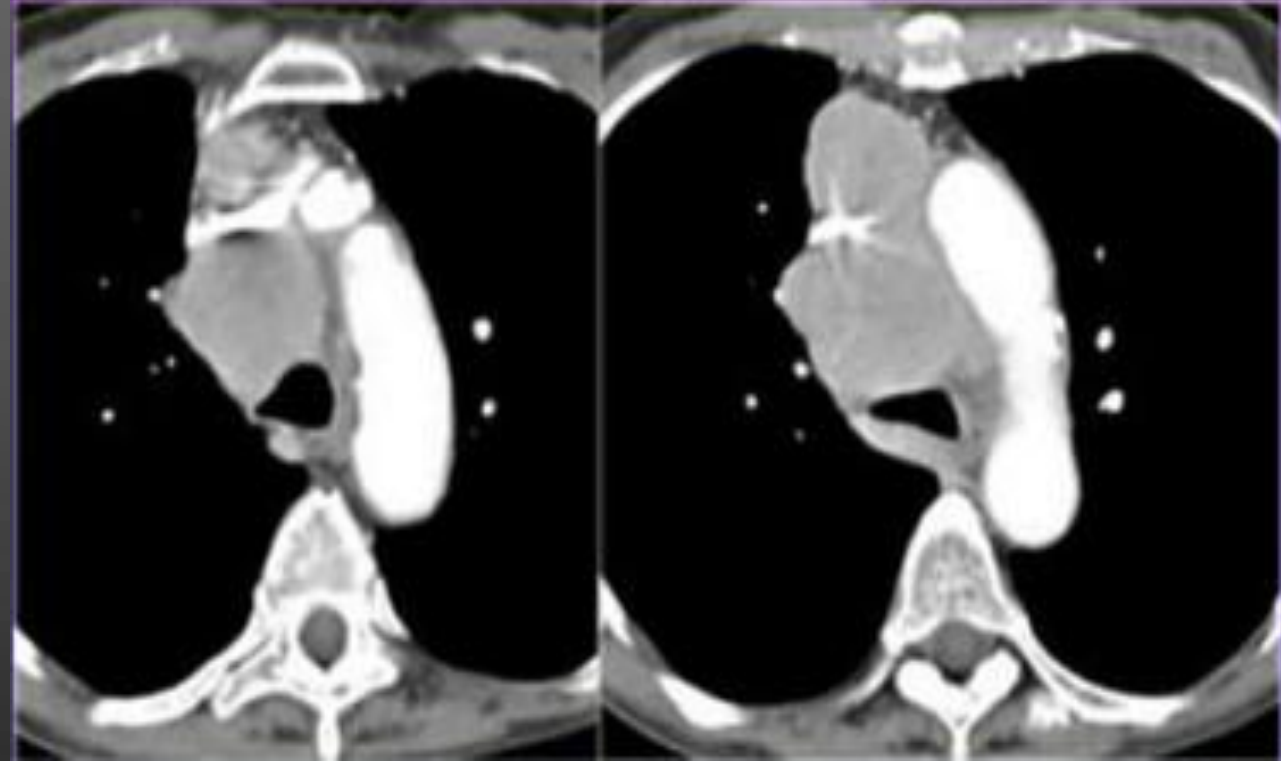
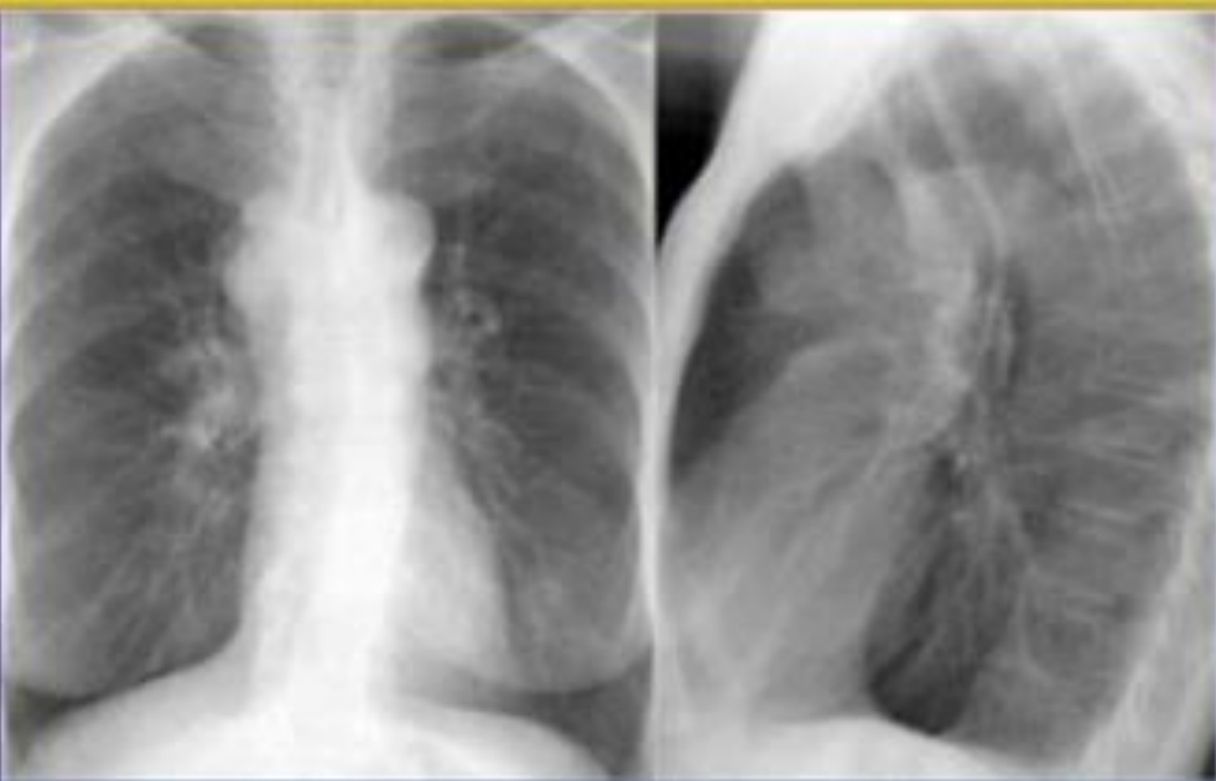






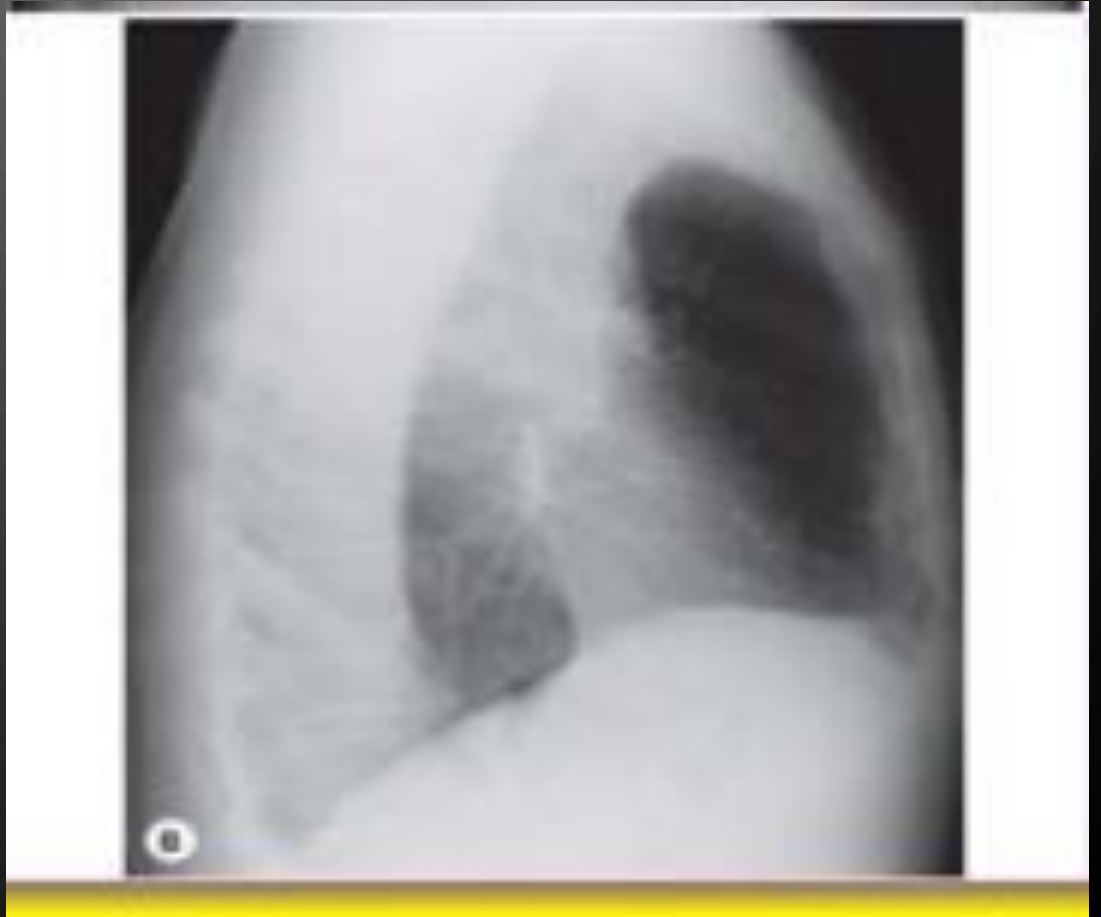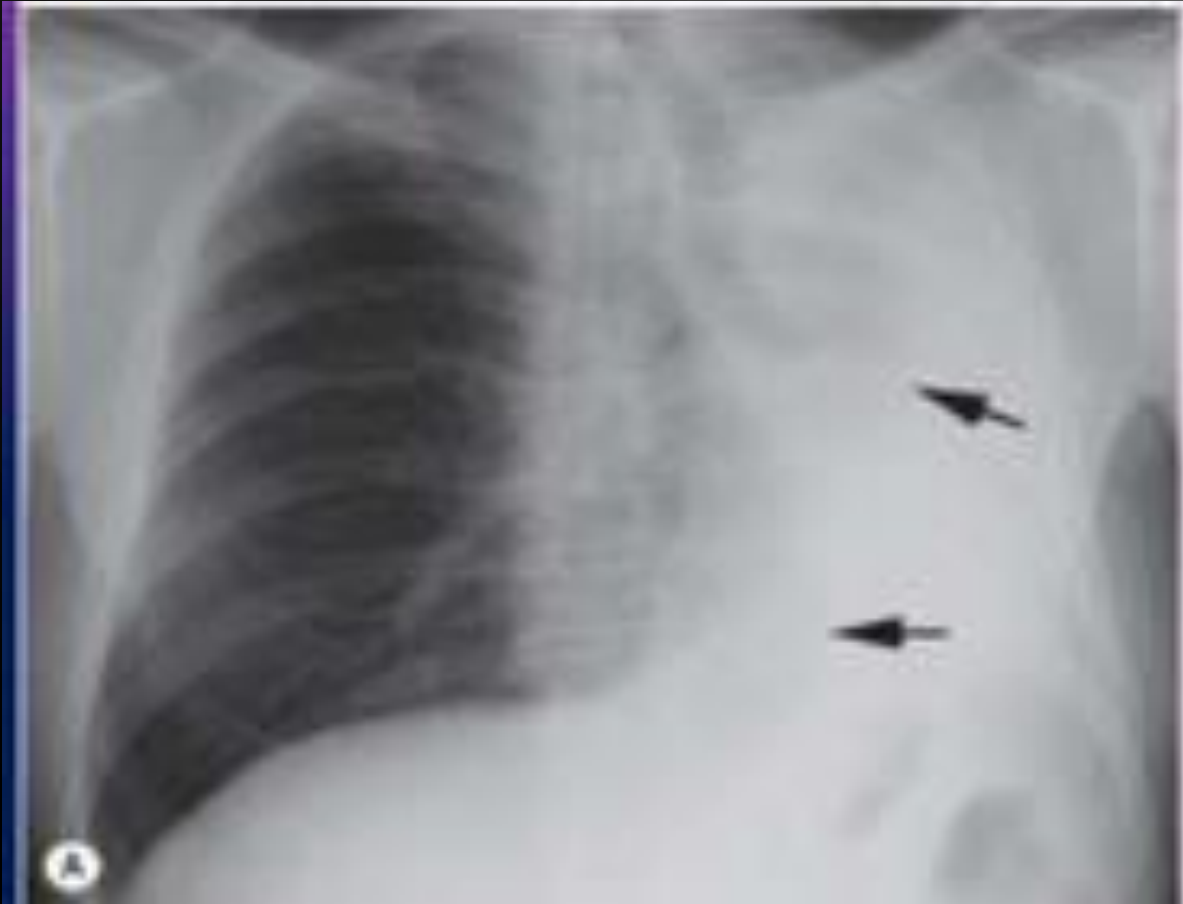# Mediastinal widening

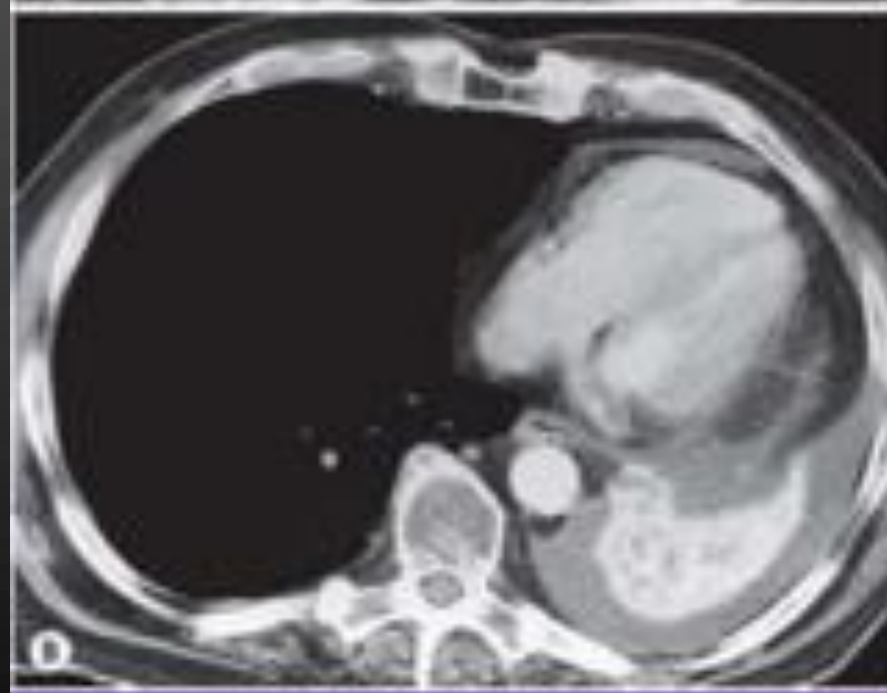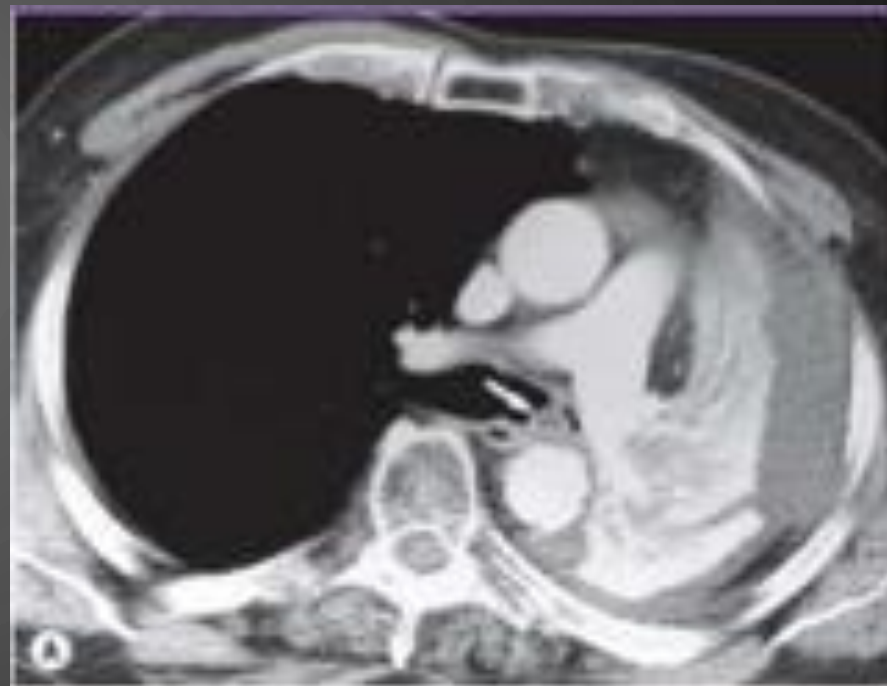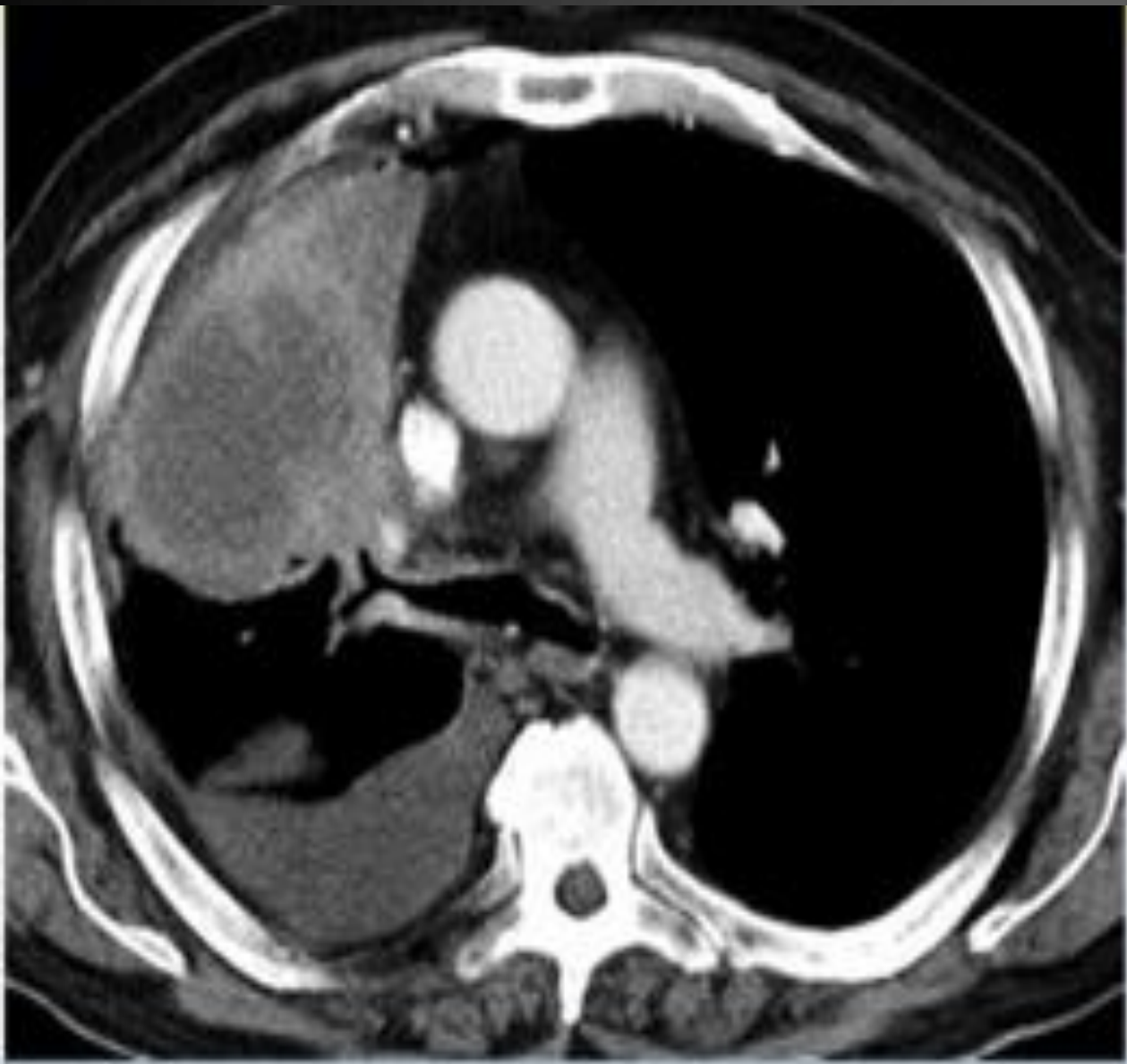
- Anterior+ middle widening – might suggest small cell carcinoma



# Segmental / lobar / lung atelectasis

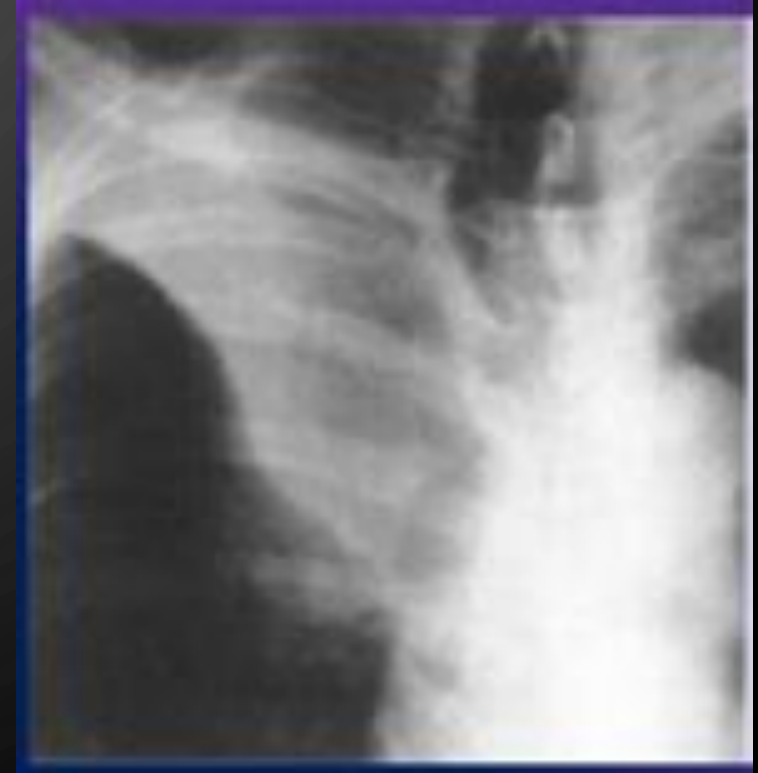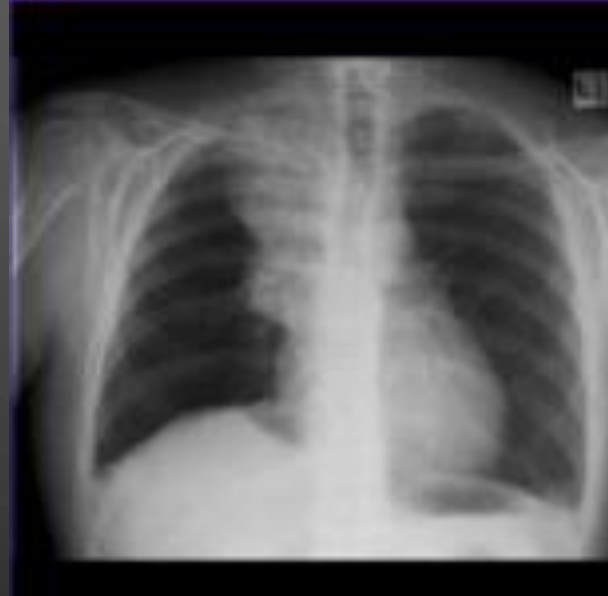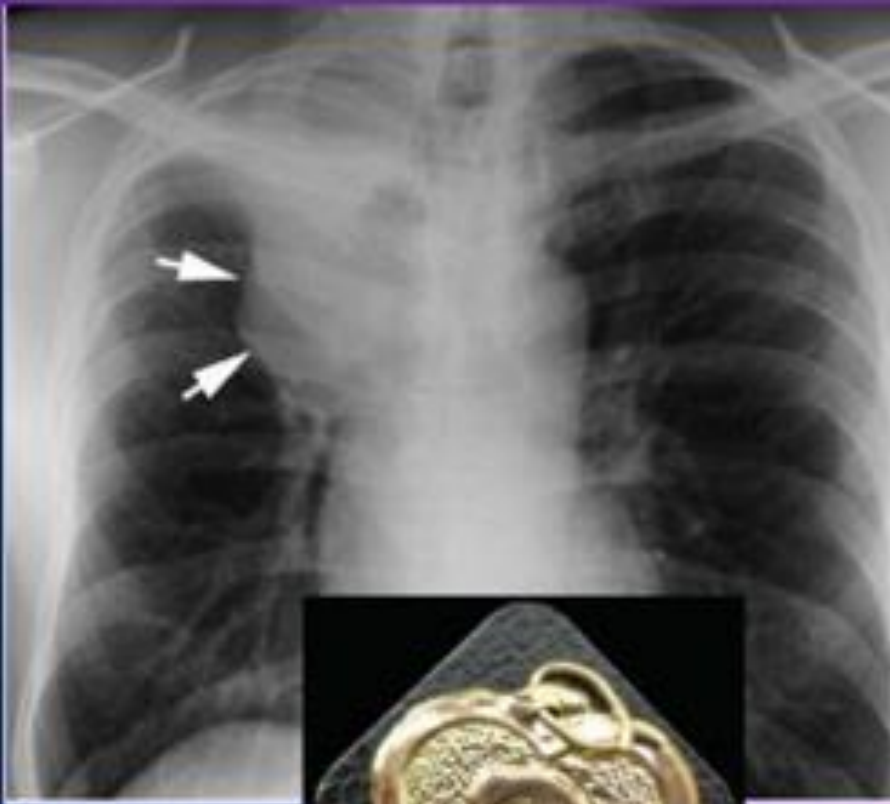- Secondary to airway obstruction – mainly in squamous cell carcinoma
- Post obstructive lung enhances to a greater extent than tumour on CECT





# Golden s sign

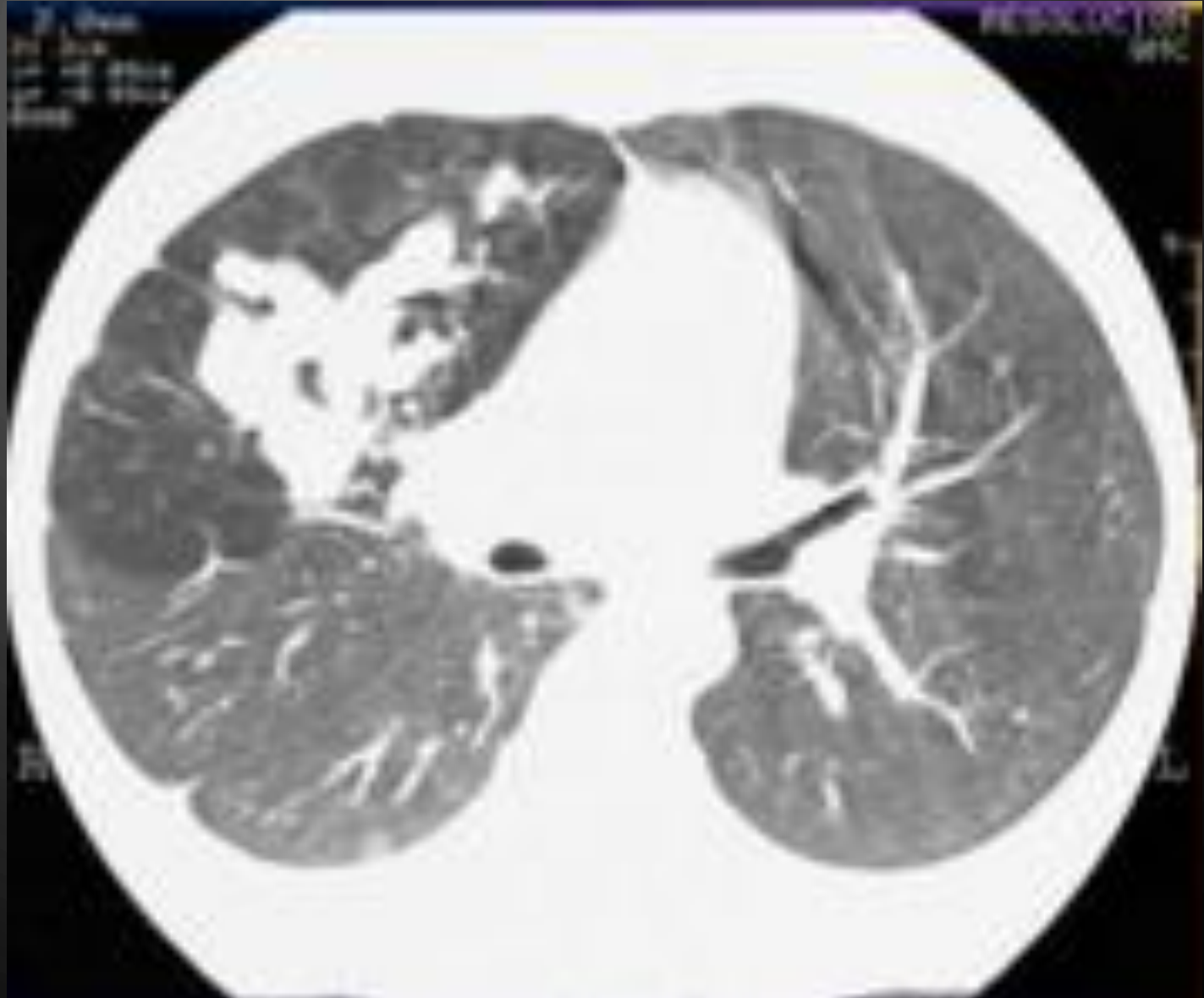- Reverse S sign of golden on PA CXR is a combination of –  
RUL COLLAPSE + BULGE OF THE CENTRAL TUMOUR





# Local hyperaeration

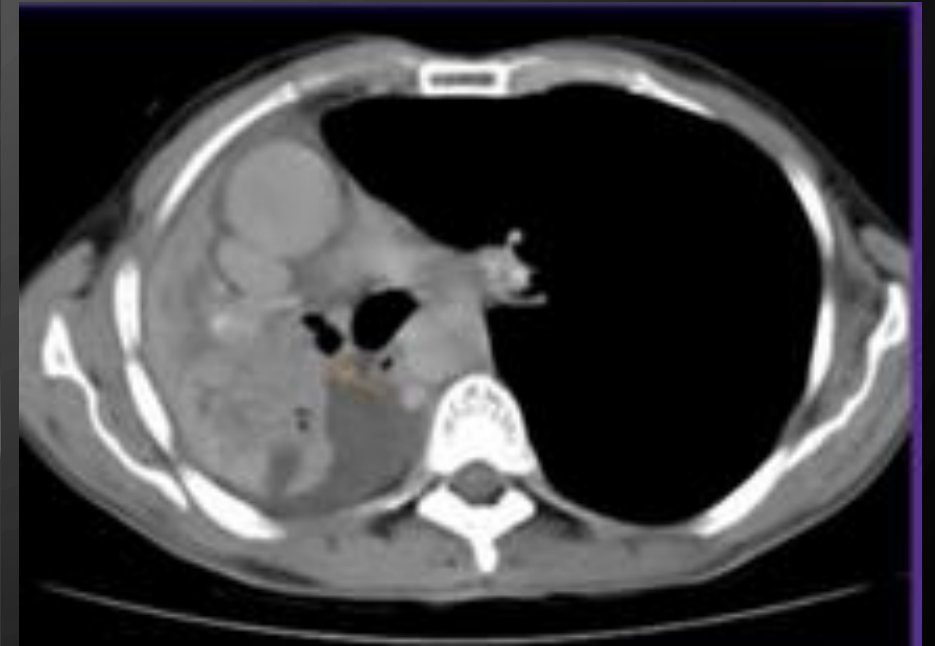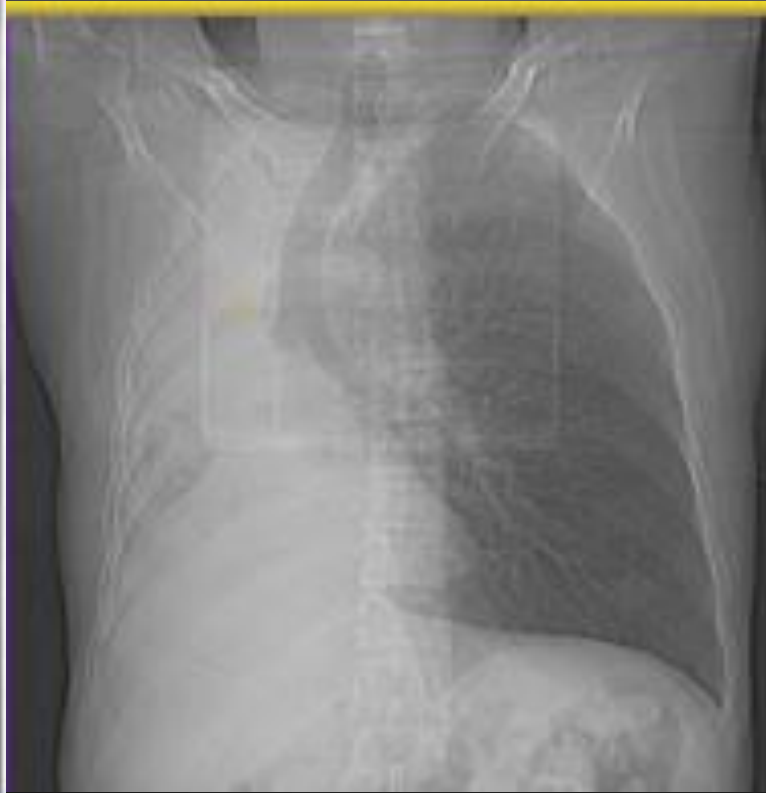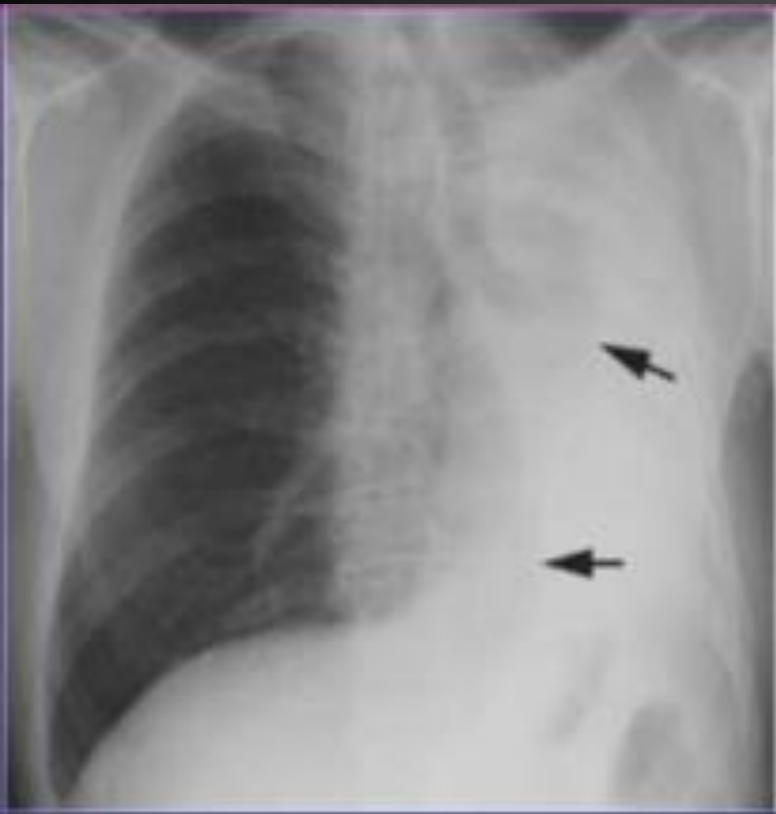- Due to check valve type endobronchial obstruction
- Best seen on expiratory view.
- CT shows dilated , fluid filled bronchi in the right middle lobe , secondary to carcinoma at right hilum with local hyperaeration seen





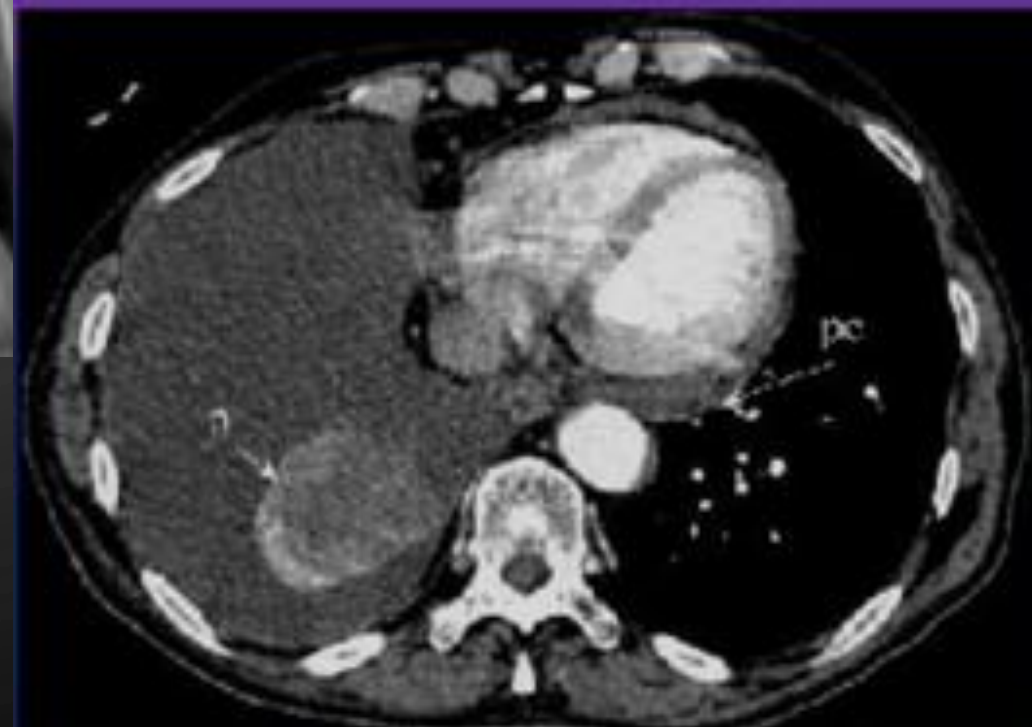
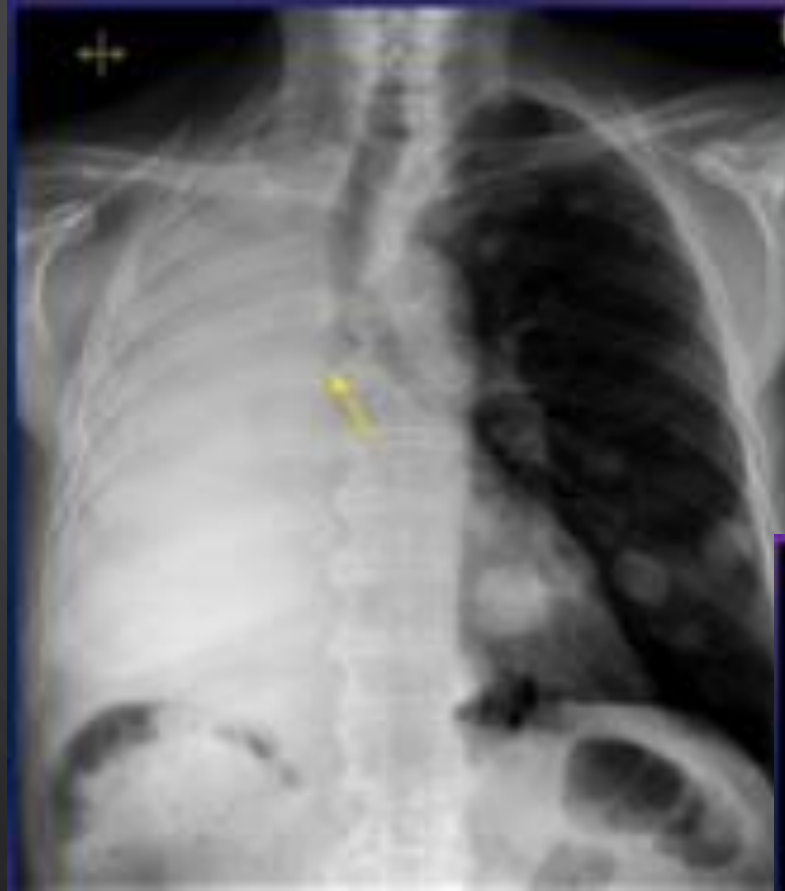# Bronchial cut off sign

It refers to the abrupt truncation of a bronchus from obstruction , which may be due to cancer , mucous plugging , trauma or foreign bodies associated with distal lobar collapse .

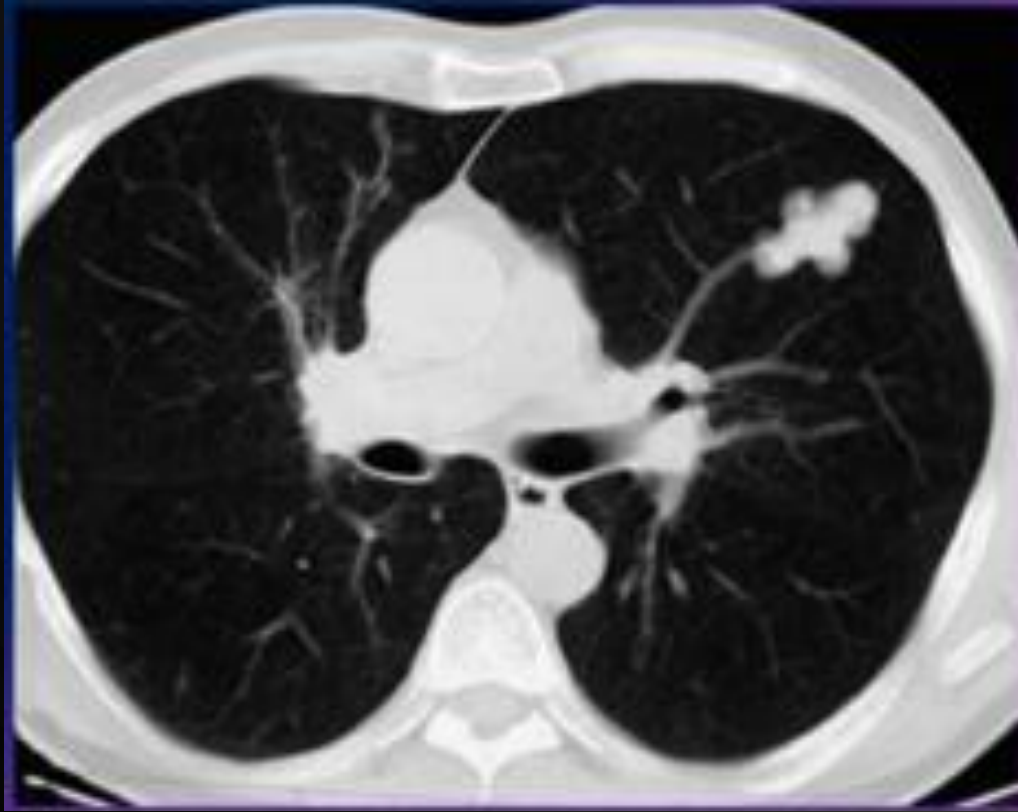


# Malignant pleural effusion

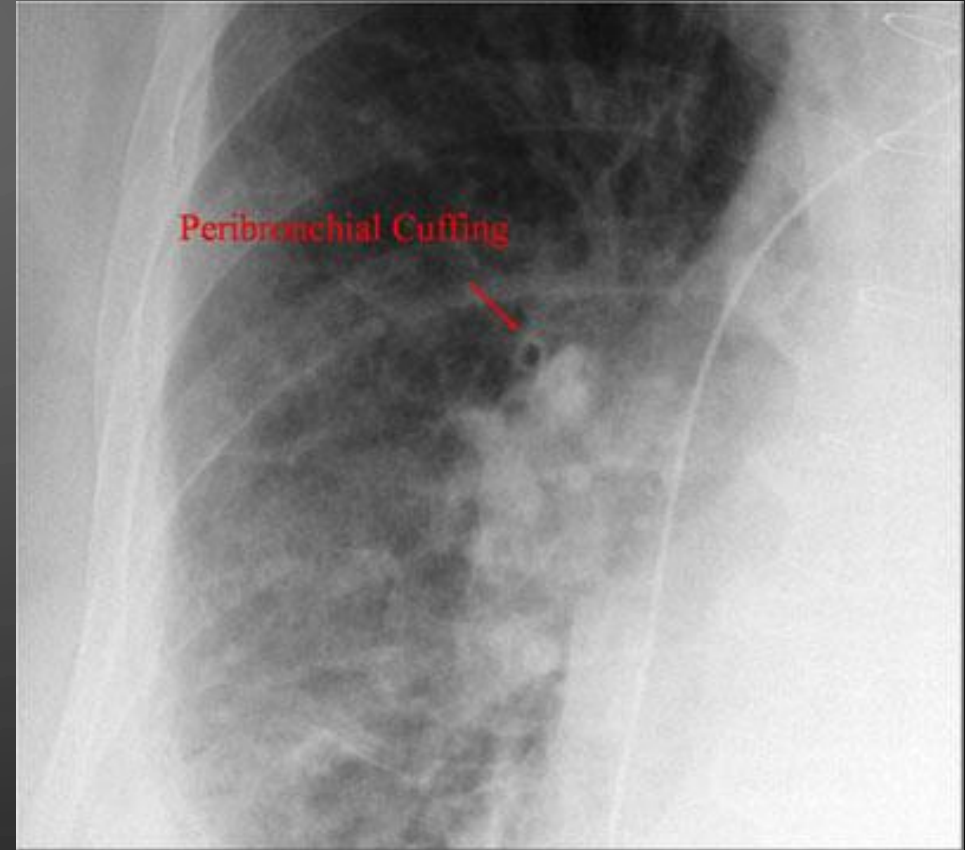
- Usually unilateral
- More common due to adenocarcinoma and frequently seen in patient > 45 years
- Bloody and massive pleural effusion is the typical clinical picture with significant high LDH and CEA level (>20 ug/L)



# Feeding vessel sign & bronchial cuff sign



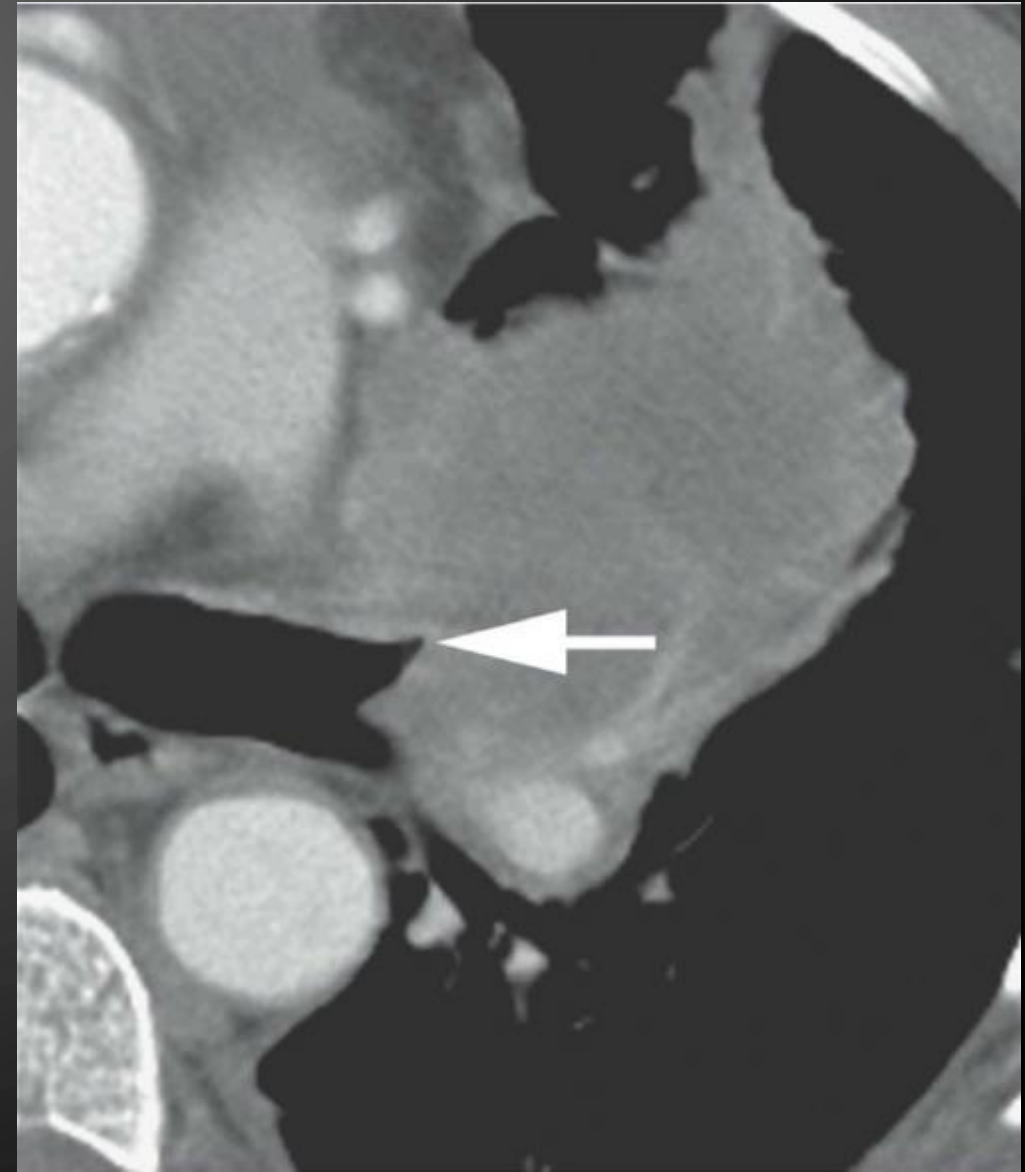
- In case of bronchial carcinoma left pulmonary artery leading directly to the mass is seen .



There is focal / circumferential thickening of bronchial wall imaged end on ( early sign)

# Rat-tail appearance

Narrowing or tapering of the bronchial lumen, a finding that reflects the tendency of lung carcinomas to infiltrate along the bronchial wall ; a tapered narrowing, or “rat-tail,” appearance of the bronchial lumen is highly suggestive of carcinoma.



# Staging the tumour

The main purposes of accurate staging of lung cancer are:

1. To identify those patients with non-small cell tumors who will benefit from surgery
  2. To avoid surgery in those who will not benefit, and
  3. To provide accurate data for assessing and comparing different methods of treatment
- Currently the main hope for curative treatment lies with surgery for non-small cell cancer, and chemotherapy for small cell tumors.

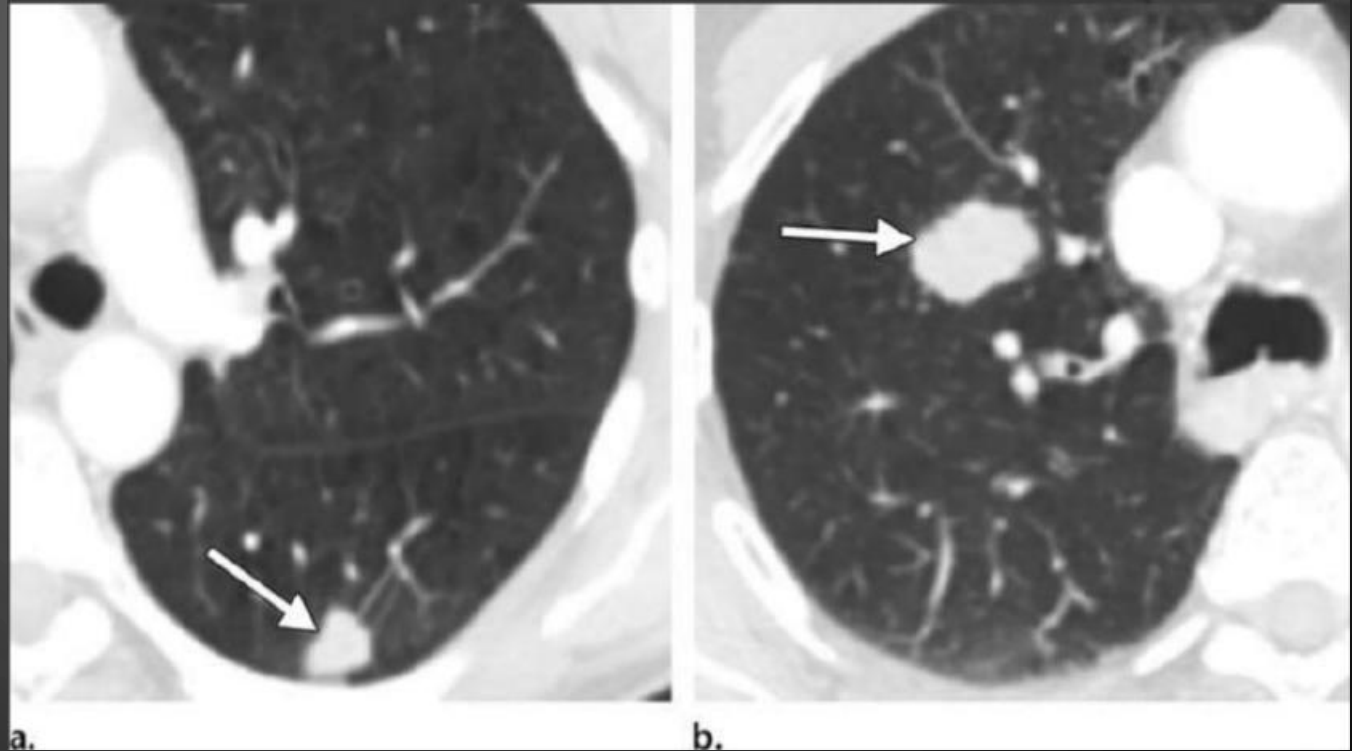


## TNM 8<sup>th</sup> - Primary tumor characteristics

<b>T<sub>x</sub></b>	Tumor in sputum/bronchial washings but not be assessed in imaging or bronchoscopy
<b>T<sub>0</sub></b>	No evidence of tumor
<b>T<sub>is</sub></b>	Carcinoma in situ
<b>T<sub>1</sub></b>	≤ 3 cm surrounded by lung/visceral pleura, not involving main bronchus
<b>T<sub>1a(mi)</sub></b>	Minimally invasive carcinoma
<b>T<sub>1a</sub></b>	≤ 1 cm
<b>T<sub>1b</sub></b>	> 1 to ≤ 2 cm
<b>T<sub>1c</sub></b>	> 2 to ≤ 3 cm
<b>T<sub>2</sub></b>	> 3 to ≤ 5 cm <i>or</i> involvement of main bronchus without carina, regardless of distance from carina <i>or</i> invasion visceral pleural <i>or</i> atelectasis or post obstructive pneumonitis extending to hilum
<b>T<sub>2a</sub></b>	>3 to ≤4cm
<b>T<sub>2b</sub></b>	>4 to ≤5cm
<b>T<sub>3</sub></b>	>5 to ≤7cm in greatest dimension <i>or</i> tumor of any size that involves chest wall, pericardium, phrenic nerve <i>or</i> satellite nodules in the same lobe
<b>T<sub>4</sub></b>	> 7cm in greatest dimension <i>or</i> any tumor with invasion of mediastinum, <b>diaphragm</b> , heart, great vessels, recurrent laryngeal nerve, carina, trachea, oesophagus, spine <i>or</i> separate tumor in different lobe of ipsilateral lung
<b>N<sub>1</sub></b>	Ipsilateral peribronchial and/or hilar nodes and intrapulmonary nodes
<b>2</b>	Ipsilateral mediastinal and/or subcarinal nodes
<b>3</b>	Contralateral mediastinal or hilar; ipsilateral/contralateral scalene/supraclavicular
<b>M<sub>1</sub></b>	Distant metastasis
<b>M<sub>1a</sub></b>	Tumor in contralateral lung or pleural/pericardial nodule/malignant effusion
<b>M<sub>1b</sub></b>	Single extrathoracic metastasis, including single non-regional lymphnode
<b>M<sub>1c</sub></b>	Multiple extrathoracic metastases in one or more organs

# T classification

- T1 – TUMOUR SIZE < 3 cm
  - Tumour < 1cm - T1a
  - Tumour > 1cm but < 2 cm - T1b
  - Tumour > 2 cm but < 3cm - T1c
- T1a(mi) – is a pathology proven minimally invasive ,irrespective of size
- T1a(ss) – is a superficial spreading tumour in the central airways but confined to tracheal

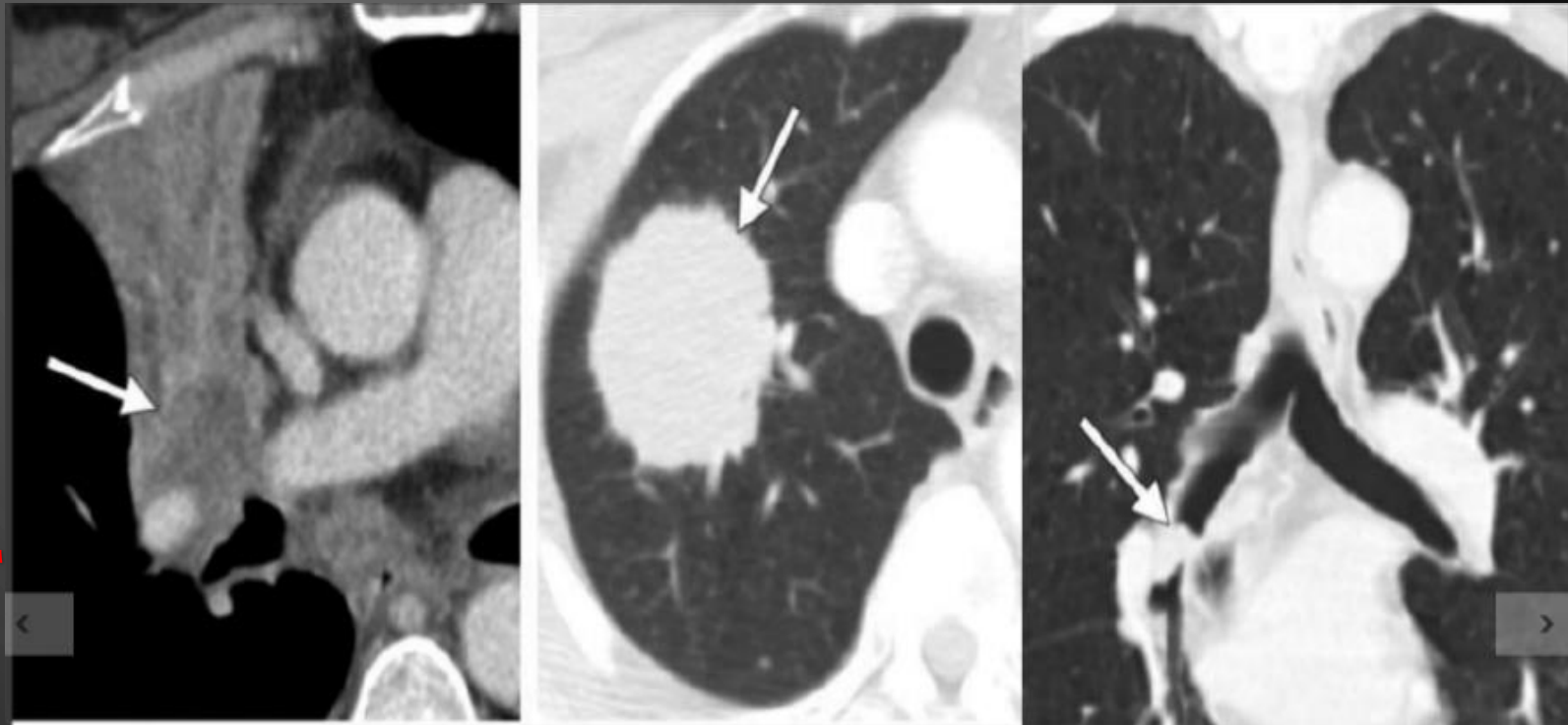


# T classification

- T2 – TUMOUR SIZE  $> 3\text{cm}$   
to  
 $< 5\text{ cm}$

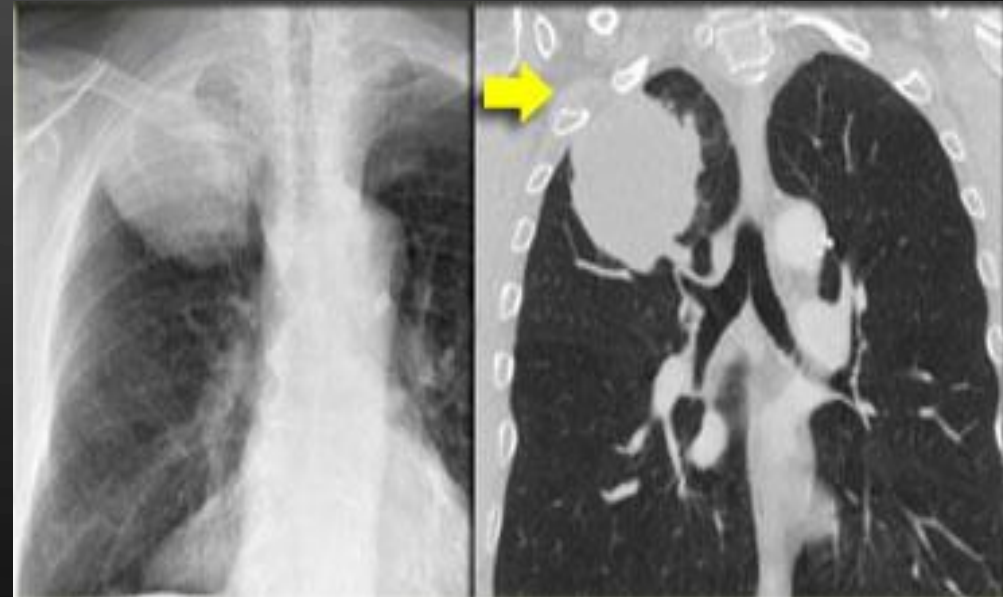
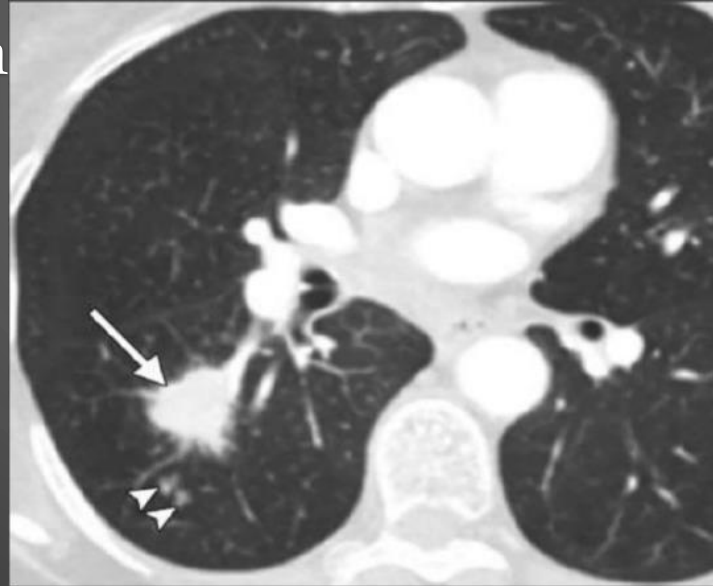OR

- TUMOUR OF ANY SIZE  
THAT
  - Invades the visceral pleura
  - Involves main bronchus , **BUT  
NOT THE CARINA**
  - Shows atelectasis or  
obstructive pneumonitis that  
extends to the hilum.
- T2a =  $> 3$  to  $4\text{ cm}$
- T2b =  $> 4$  to  $5\text{ cm}$



# T classification

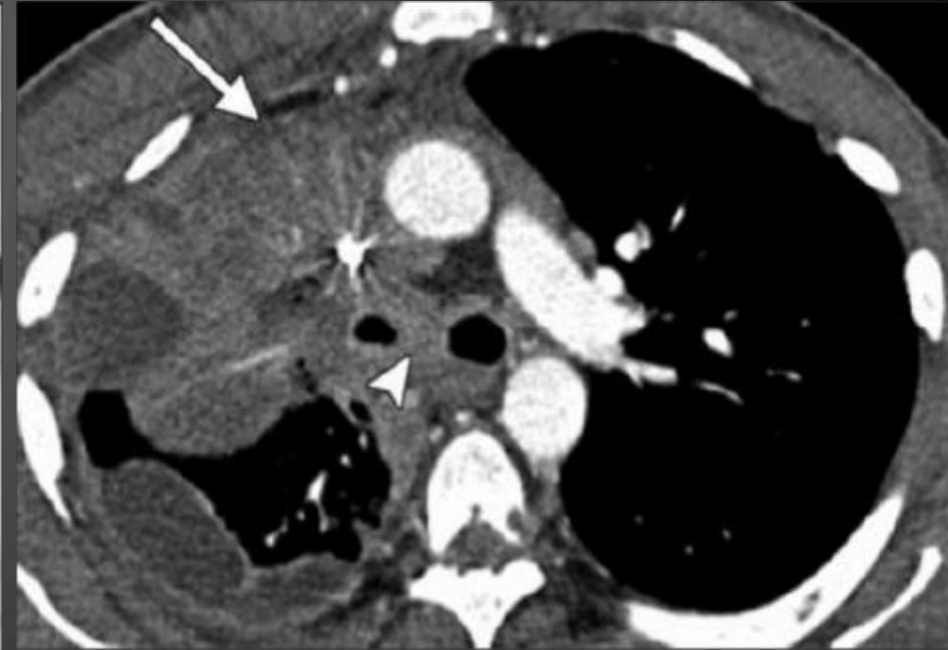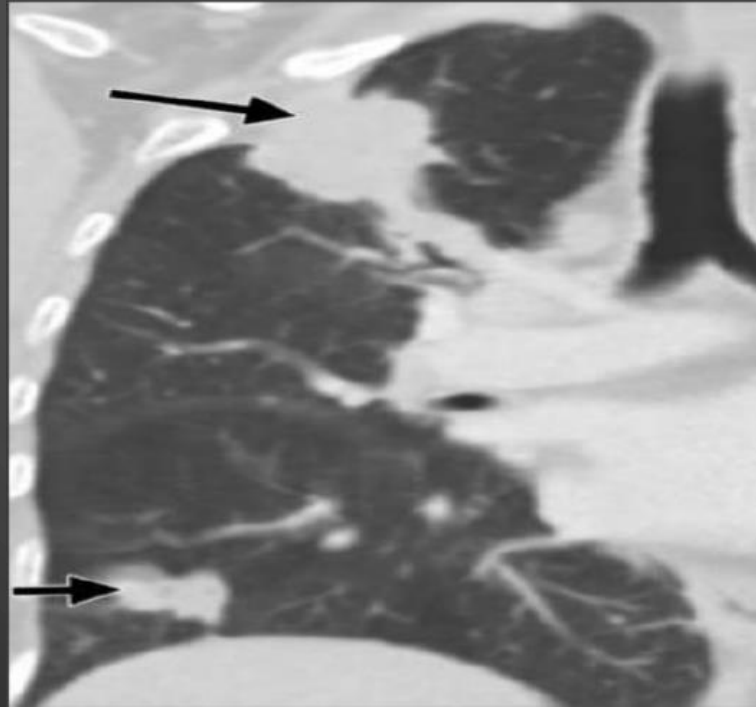
- T3 – TUMOR SIZE >5cm to 7cm  
OR
- TUMOUR OF ANY SIZE THAT
  - invades the chest wall
  - invades the pericardium
  - invades the phrenic nerve
  - shows one or more satellite nodules in the same lung lobe





# T classification

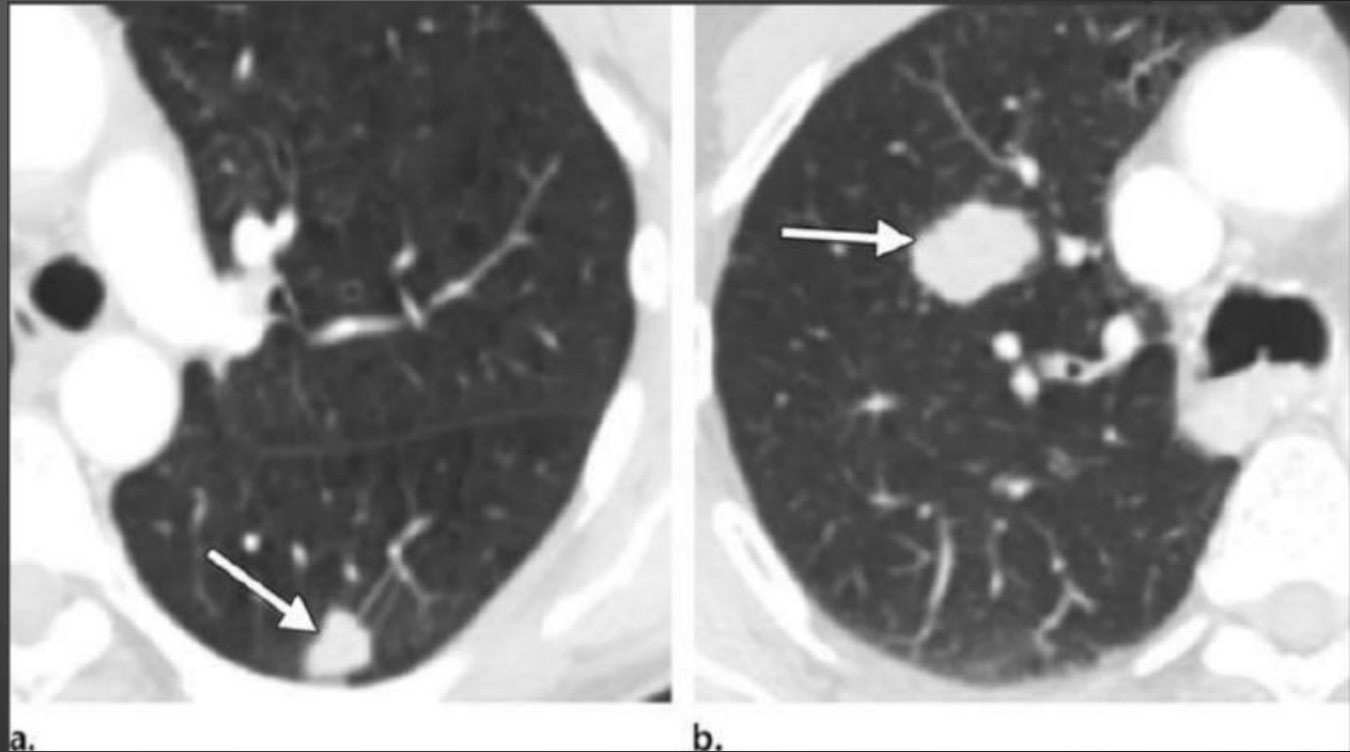
- T4 – TUMOUR SIZE > 7 cm
- OR
- TUMOUR OF ANY SIZE THAT
  - Invades mediastinal fat or structures
  - Involves the carina
  - Involves the diaphragm
  - Shows one or more satellite nodules in another lobe on the ipsilateral side .





# T classification

- T1 – TUMOUR SIZE < 3 cm
  - Tumour < 1cm - T1a
  - Tumour > 1cm but < 2 cm - T1b
  - Tumour > 2 cm but < 3cm - T1c
- T1a(mi) – is a pathology proven minimally invasive ,irrespective of size
- T1a(ss) – is a superficial spreading tumour in the central airways but confined to tracheal and bronchial wall.

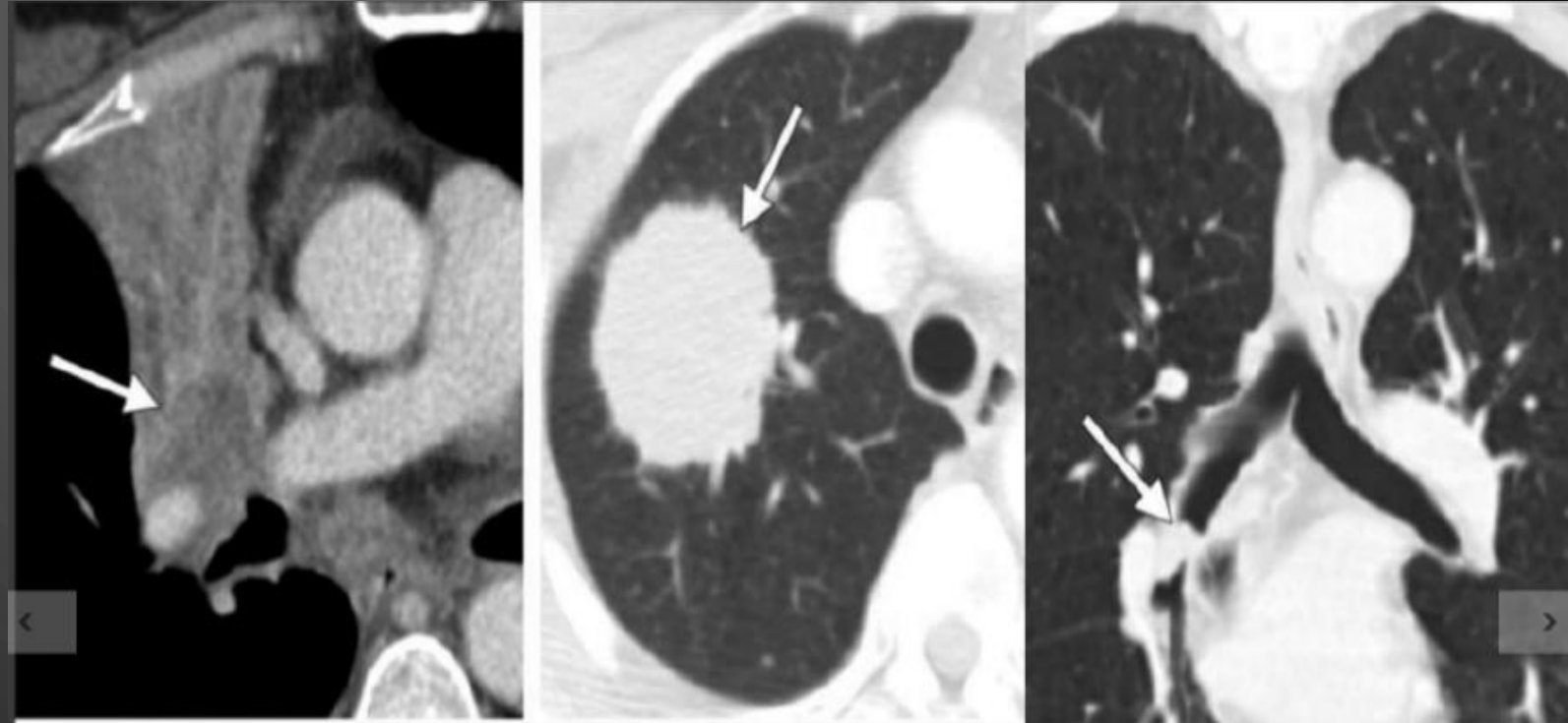


# T classification

- T2 – TUMOUR SIZE > 3cm to < 5 cm

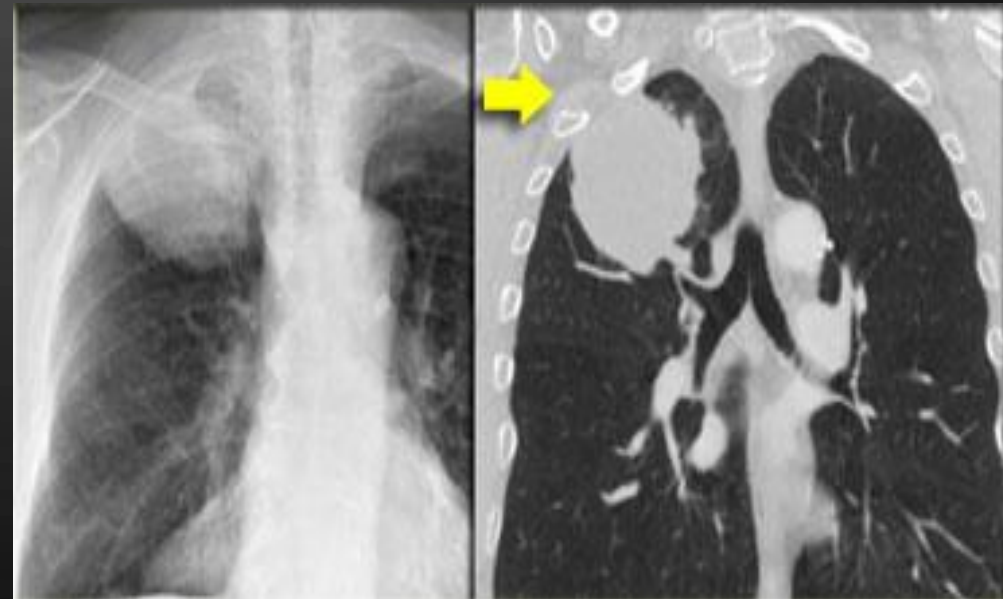
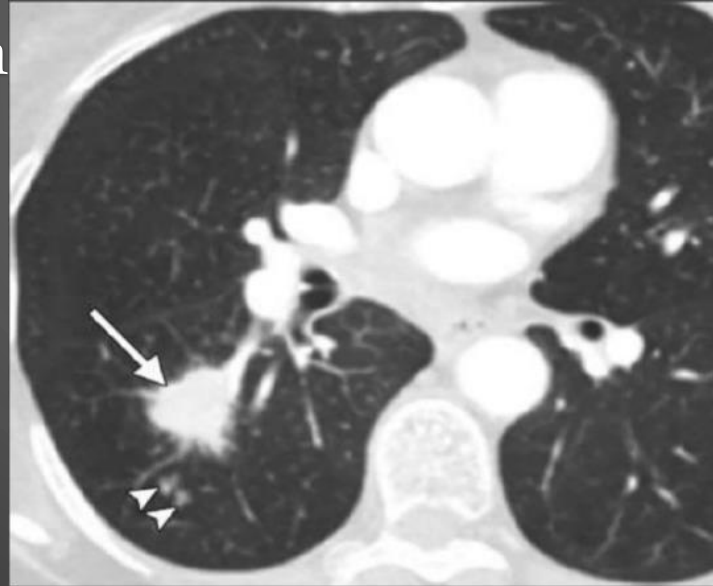
OR

- TUMOUR OF ANY SIZE THAT
  - Invades the visceral pleura
  - Involves main bronchus , **BUT NOT THE CARINA**
  - Shows atelectasis or obstructive pneumonitis that extends to the hilum.
- T2a = > 3 to 4 cm
- T2b = > 4 to 5 cm



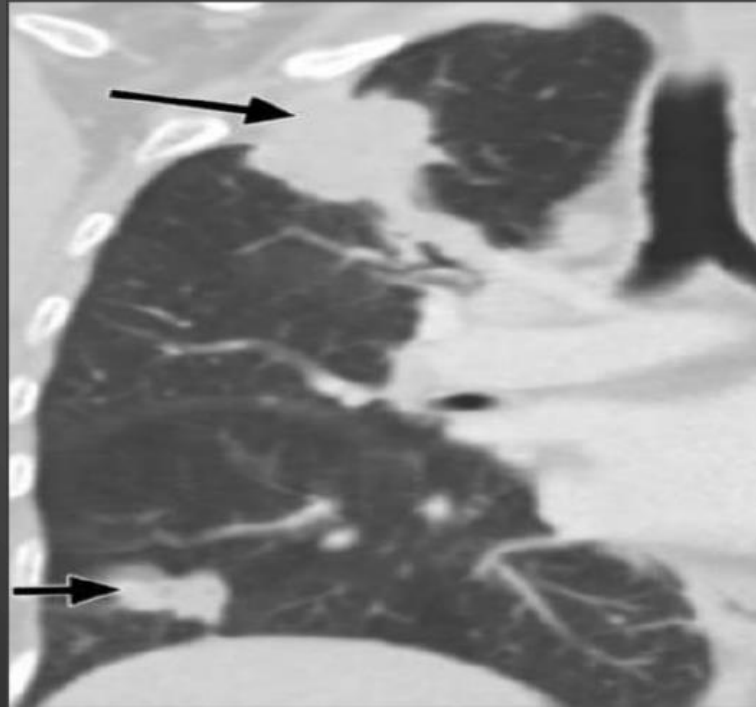
# T classification

- T3 – TUMOR SIZE >5cm to 7cm  
OR
- TUMOUR OF ANY SIZE THAT
  - invades the chest wall
  - invades the pericardium
  - invades the phrenic nerve
  - shows one or more satellite nodules in the same lung lobe



# T classification

- T4 – TUMOUR SIZE > 7 cm
- OR
- TUMOUR OF ANY SIZE THAT
  - Invades mediastinal fat or structures
  - Involves the carina
  - Involves the diaphragm
  - Shows one or more satellite nodules in another lobe on the ipsilateral side .

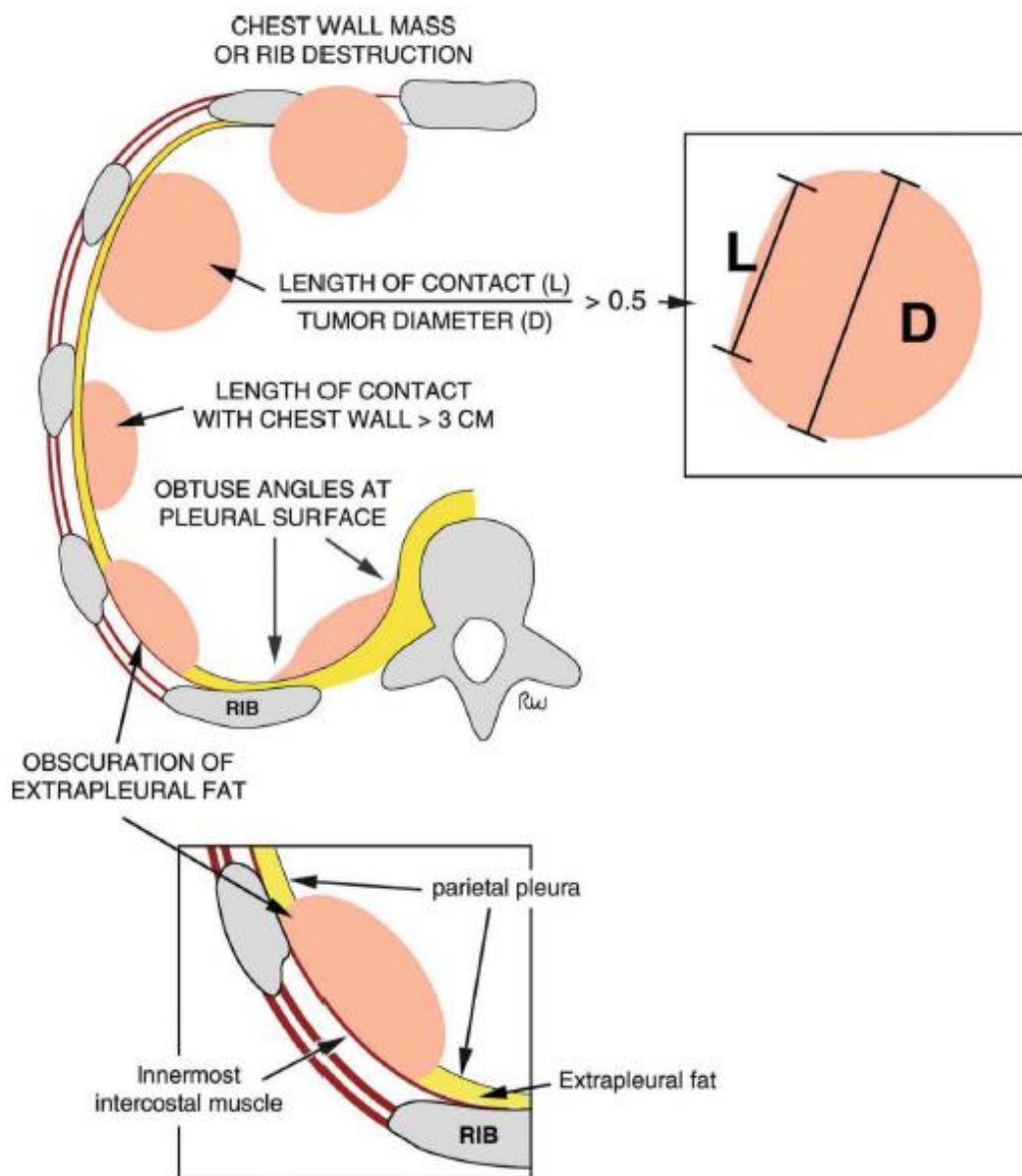


# Chest Wall Invasion

The accuracy of CT in diagnosing chest wall invasion is 70% to 80%, although sensitivity and specificity values vary from 40% to 90% in different studies. CT findings of value in the diagnosis of chest wall invasion include the presence of the following:

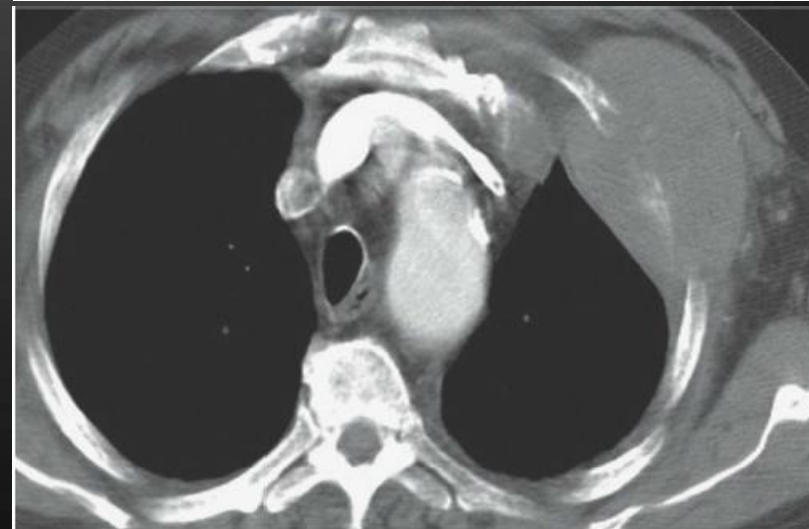
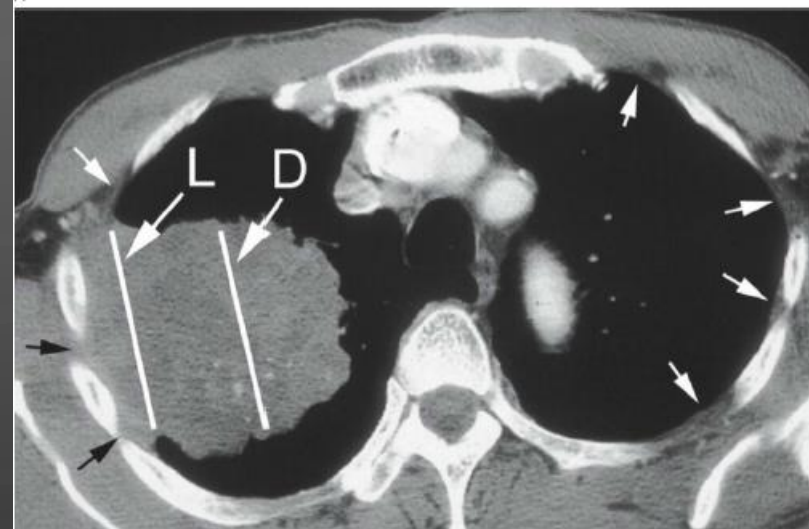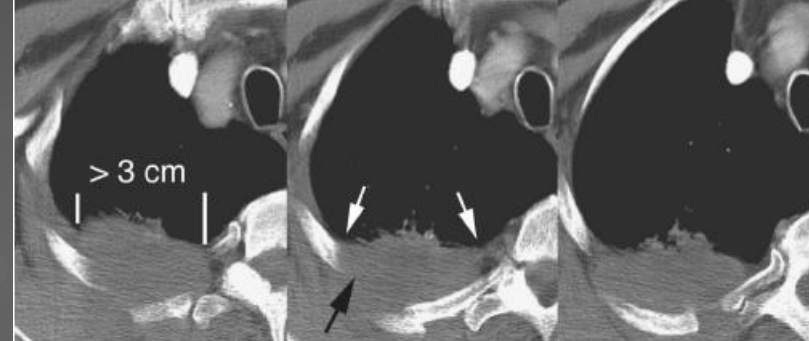
1. Obtuse angles or pleural thickening at the point of contact between tumor and pleura
2. More than 3 cm of contact between tumor and the pleural surface (5 cm of contact is more specific but less sensitive)
3. A ratio of the tumor diameter to the length of pleural contact by the tumor exceeding 0.5  
(the higher this ratio, the more specific this finding)
4. Invisibility of extra pleural (chest wall) fat planes at the point tumor contacts chest wall
5. A mass involving the chest wall
6. Rib destruction





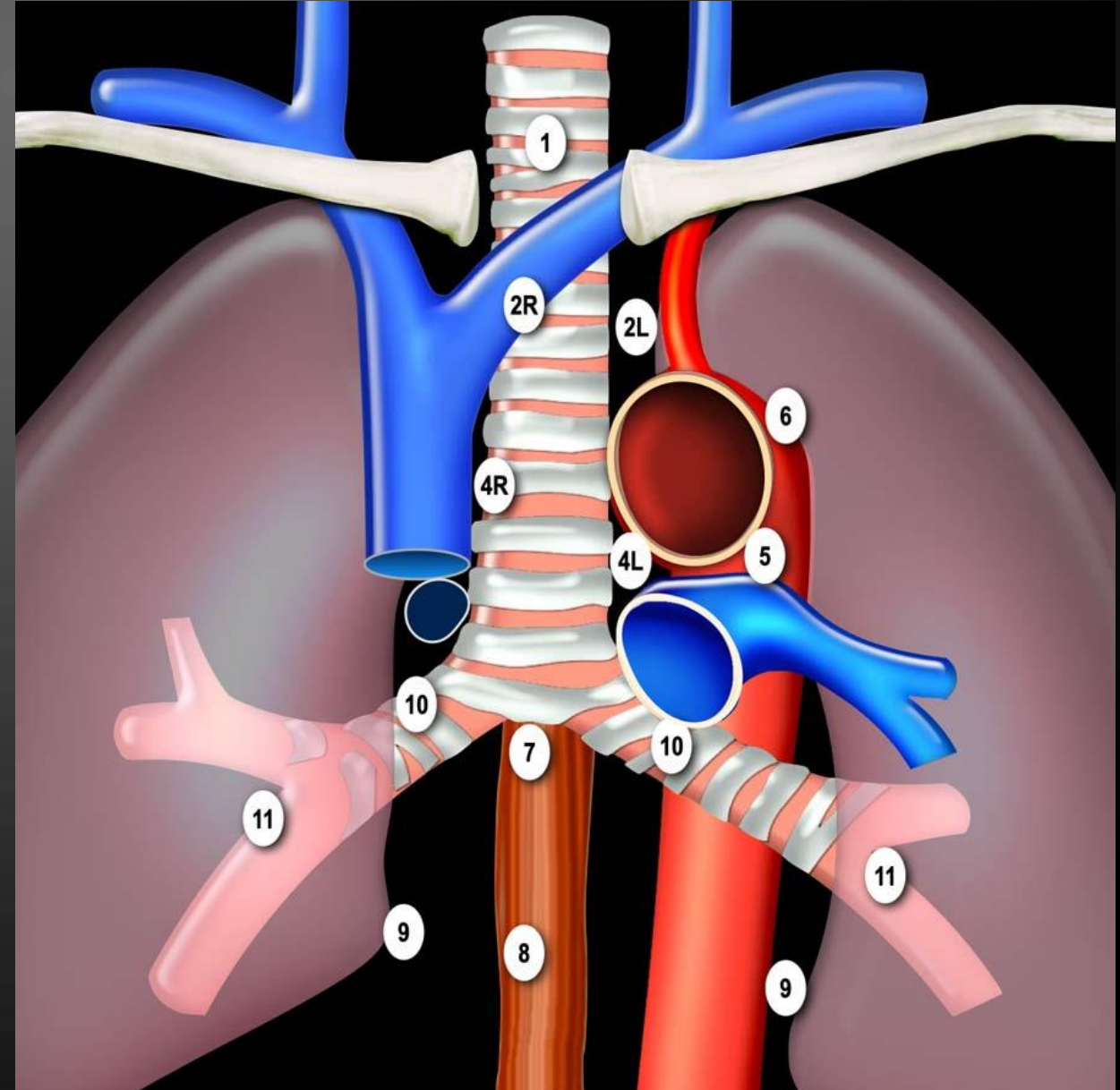
EXTRAPLEURAL FAT INVASION - Detail View

FIG. 4.49. CT findings of chest wall invasion.



# Regional lymph node classification

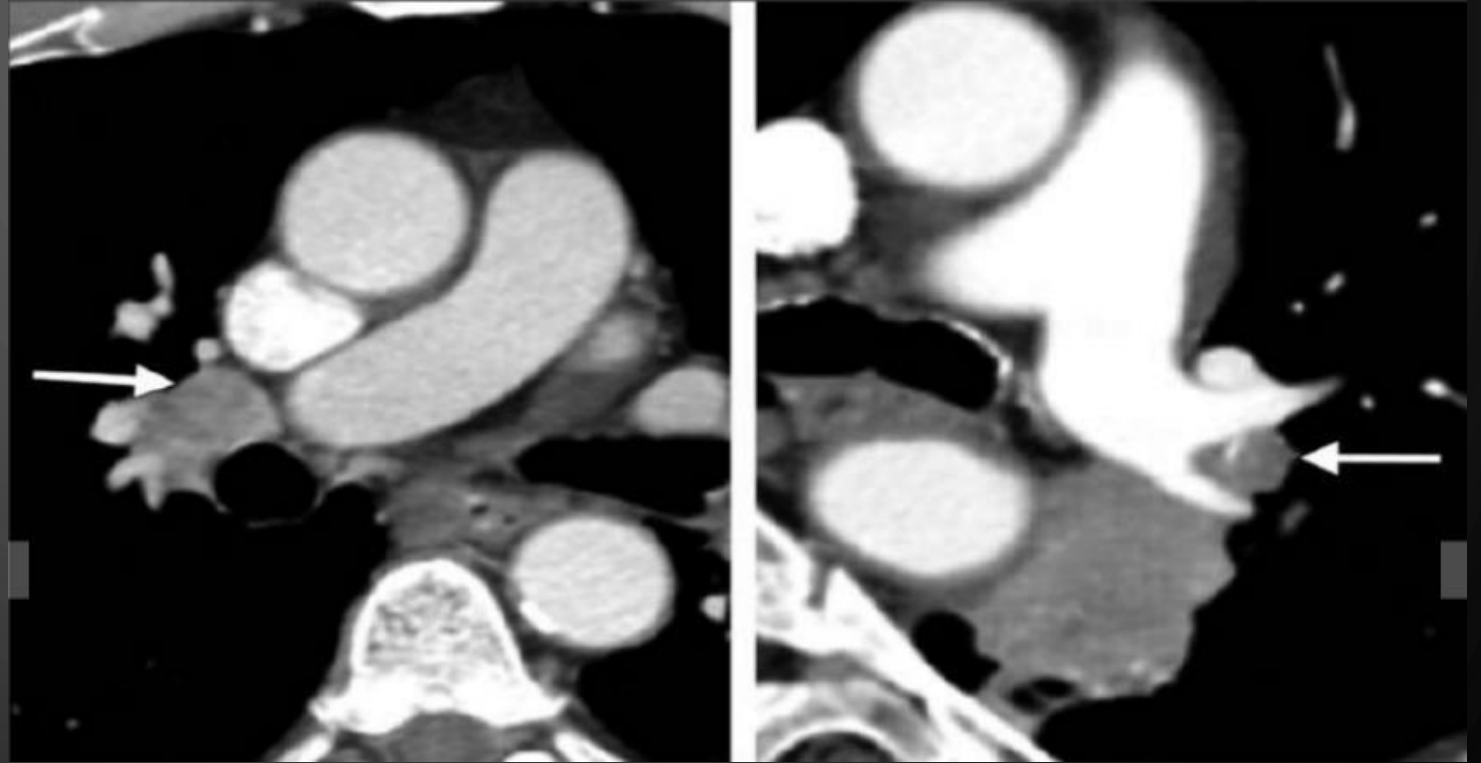
- LEVEL 1 – SUPRA CLAVICULAR
- LEVEL 2 – UPPER PARATRACHEAL
- LEVEL 3A – PREVASCULAR
- LEVEL 3P – PREVERTEBRAL
- LEVEL 4 – LOWER PARATRACHEAL
- LEVEL 5 – SUBAORTIC NODES
- LEVEL 6 – PARA AORTIC NODES
- LEVEL 7 – SUB CARINAL NODES
- LEVEL 8 – PARAOESOPHAGEAL
- LEVEL 9 – PULMONARY LIGAMENT
- LEVEL 10-14 – PULMONARY NODES



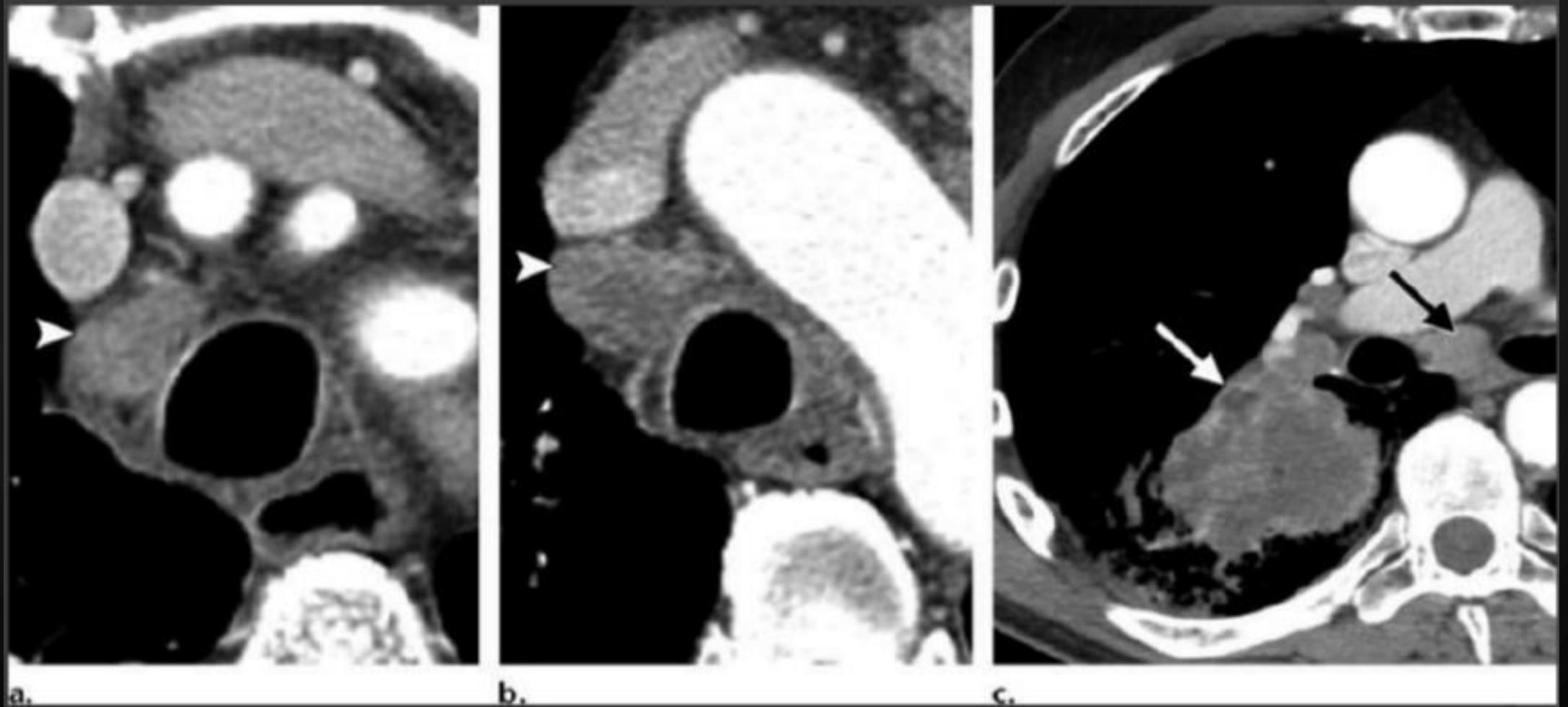
# N staging

- **NODAL STATUS**

- Nx : Regional nodes cannot be assessed
- N0 : no regional nodal metastases
- N1 : ipsilateral peribronchial , hilar or intrapulmonary nodes
- N2 : ipsilateral mediastinal or subcarinal nodes
- N3 : contralateral nodal involvement

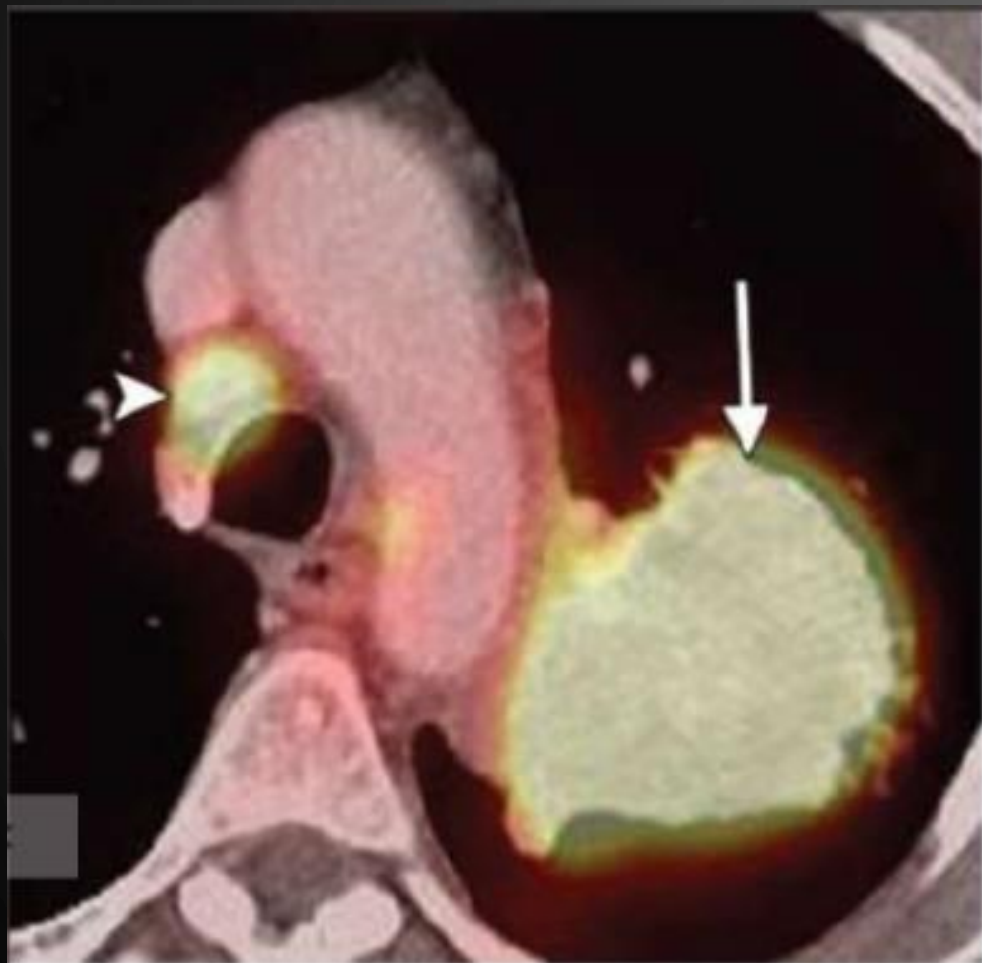


**N1 NODES**

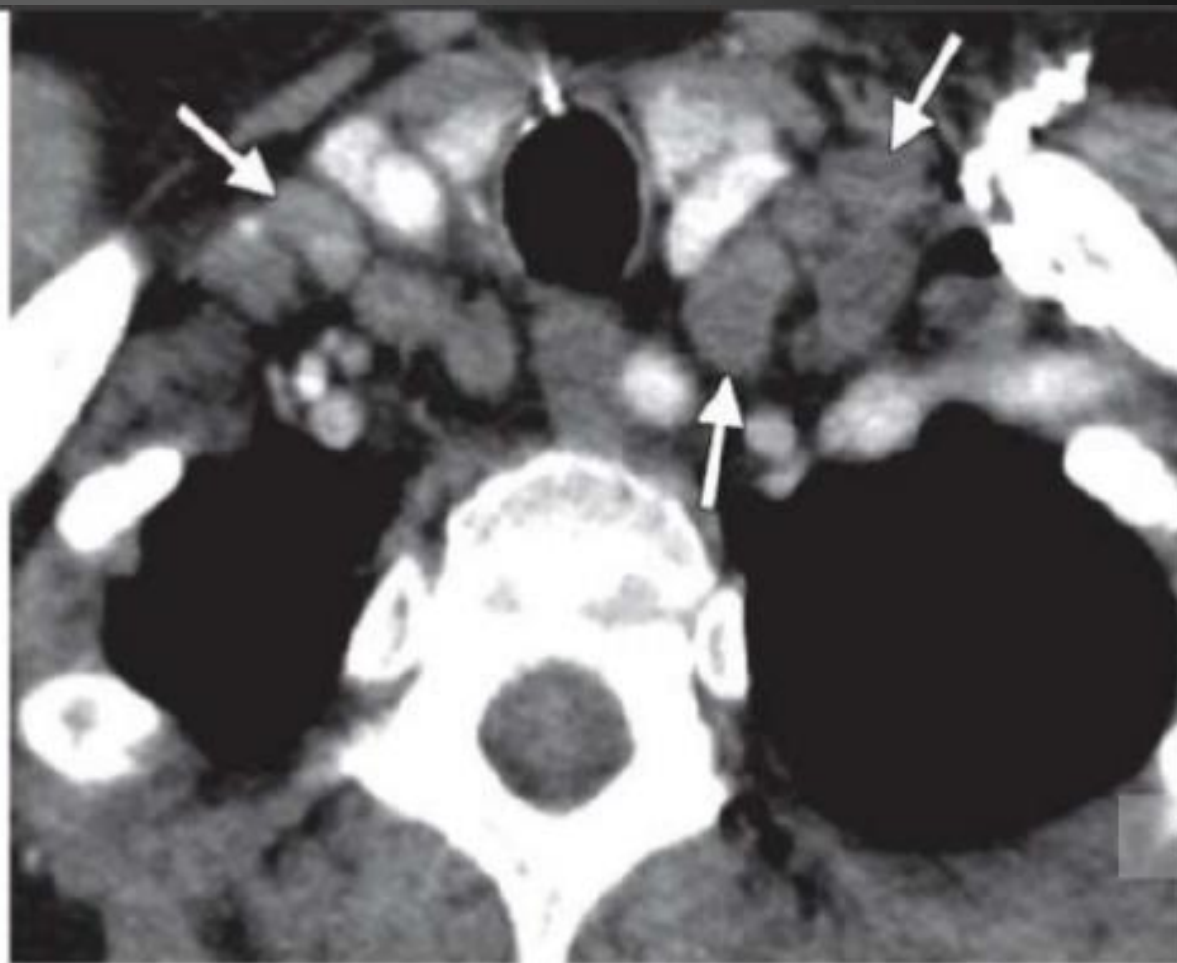


STAGE N2 LYMPH NODES





a.



b.

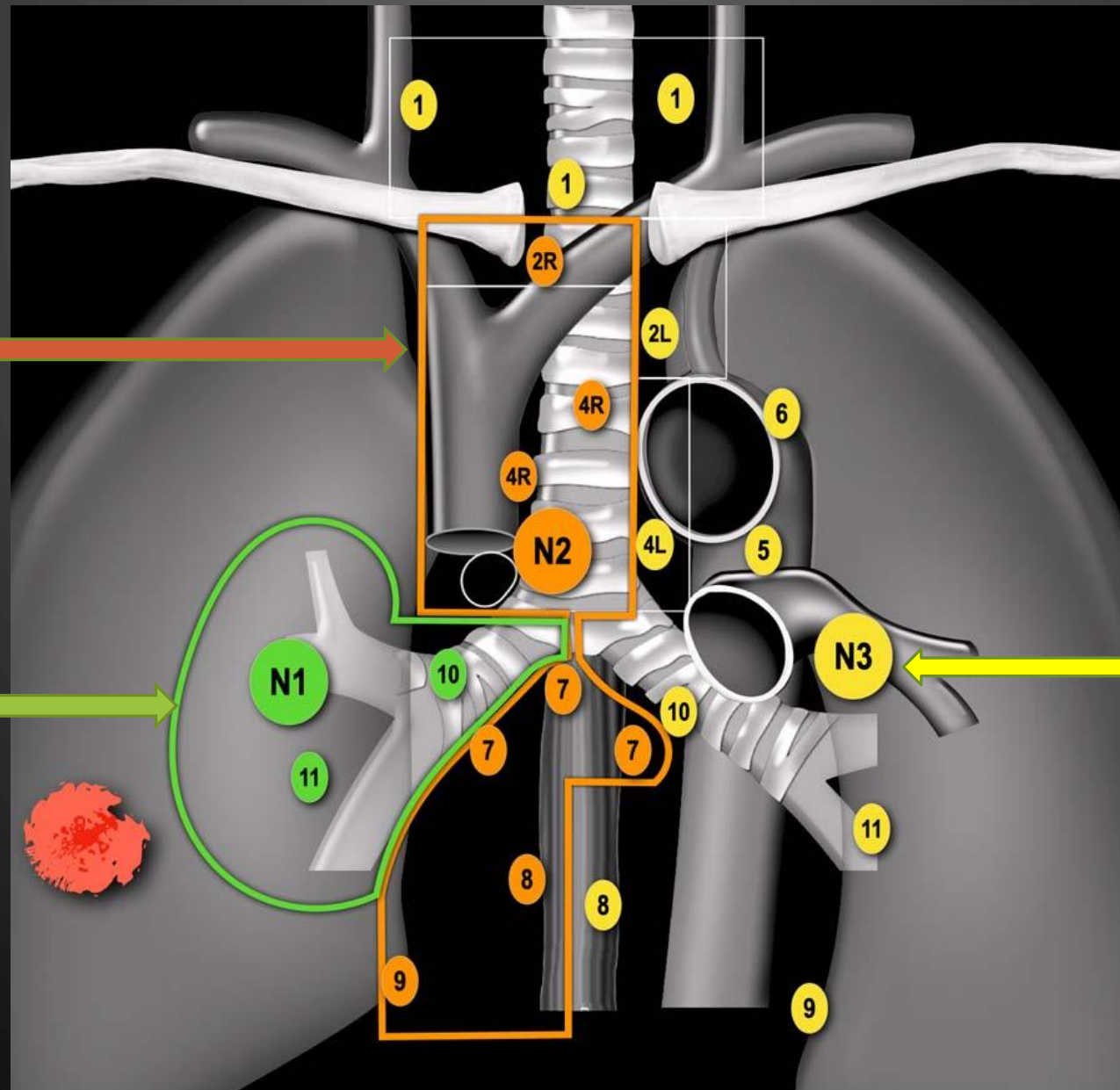
STAGE N3 LYMPH NODES



# Right lung tumour

IPSILATERAL MEDIASTINAL  
AND /OR SUBCARINAL  
NODES

IPSILATERAL  
PERIBRONCHIAL AND  
HILAR NODES(10R –  
14R)



CONTRALATERAL  
MEDIASTINAL OR HILAR  
+SUPRACLAVICULAR  
NODES

# Assessing treatment

A tumor is likely to be inoperable if

1. It extends directly into parietal pleura, chest wall, diaphragm or mediastinum.
  2. Metastasis to contralateral hilar nodes, mediastinal nodes or more distantly precludes surgical cure.
- Any node over 2 cm in diameter is likely to be involved
  - Nodes of 1 cm or less are usually regarded as normal
  - Following chemotherapy for small cell cancer, bulky mediastinal and hilar nodes and peripheral lesions may show complete regression.
  - Follow-up chest X-rays are required to detect local recurrence, although recurrent disease is often extrathoracic

# Distant metastasis (m)

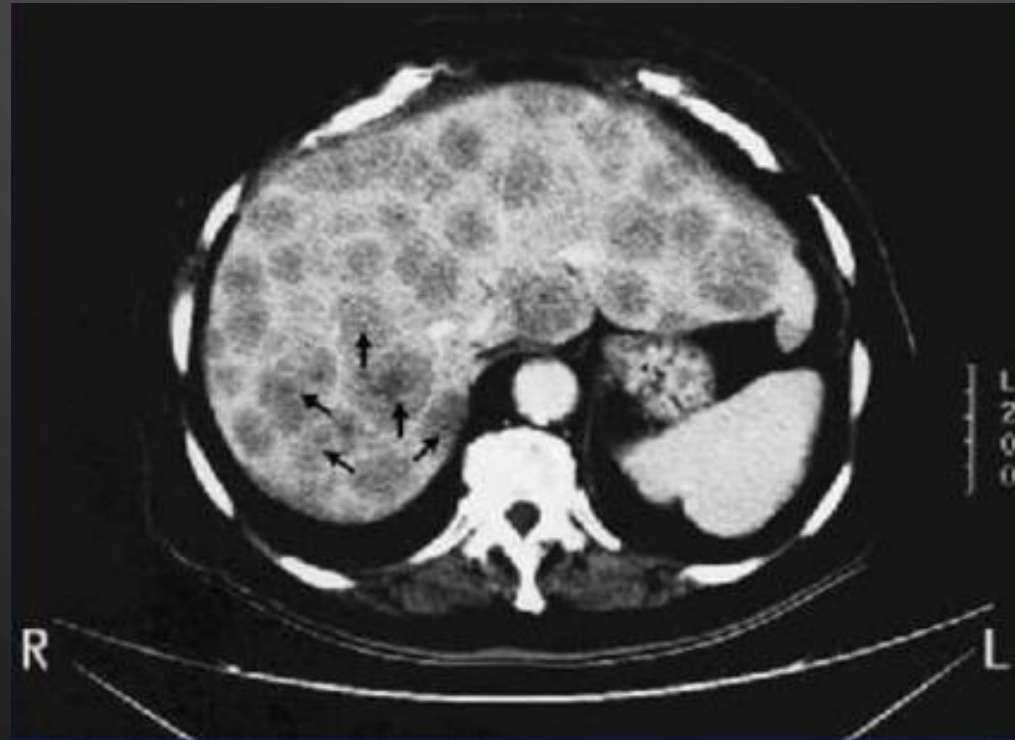- Mx – Distant metastases cannot be assessed
- M0 – no distant metastases
- M1 - Regional metastatic disease defined as malignant pleural or pericardial effusion as well as contralateral or bilateral pulmonary nodules
- M1b – solitary extra thoracic metastases
- M1c - solitary extra thoracic metastases either in a single organ or in multiple organs

# Distant metastases

- nearly 40 % of people with lung cancer have metastases to distant region of the body at the time of diagnosis.
- **small cell > adeno > large > squamous**
- lung cancer can spread to any region of the body , but most commonly spreads to the
  - liver
  - lymph nodes
  - brain
  - bones
  - adrenal glands

# Liver metastases

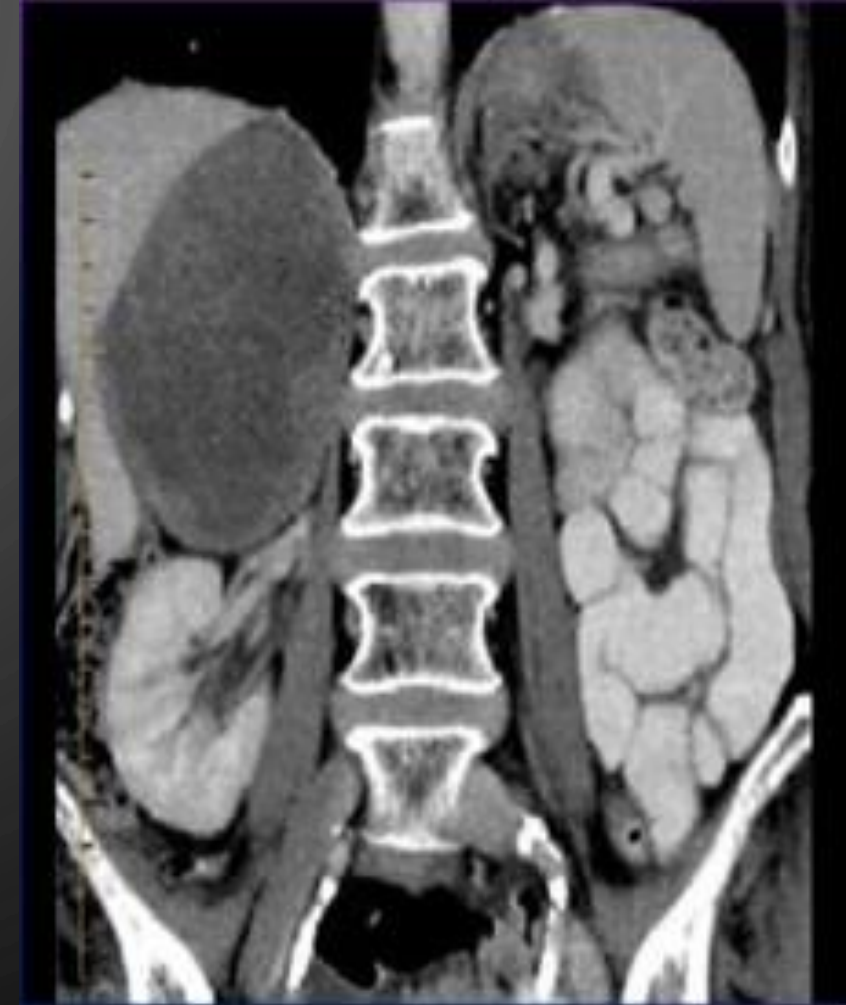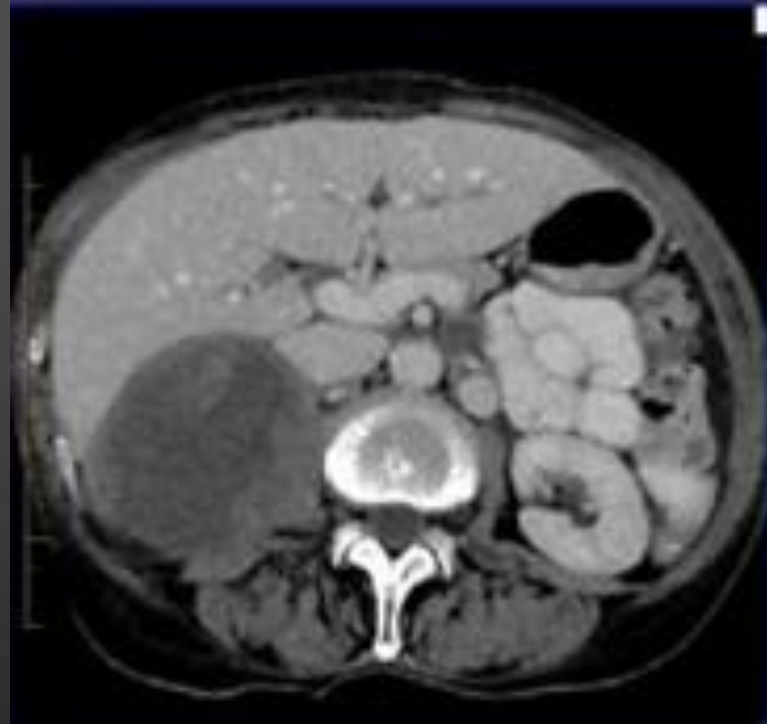- The staging CT scan of the thorax is usually extended to include the liver and adrenal glands.
- CT scans has a sensitivity of about 85% in the detection of liver mets.





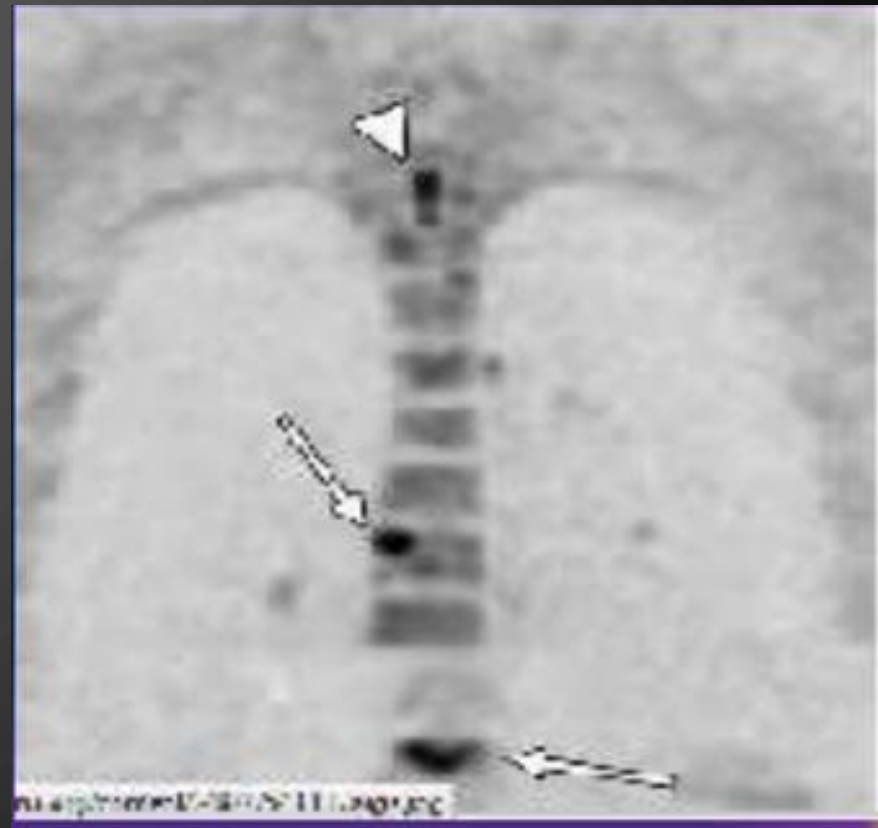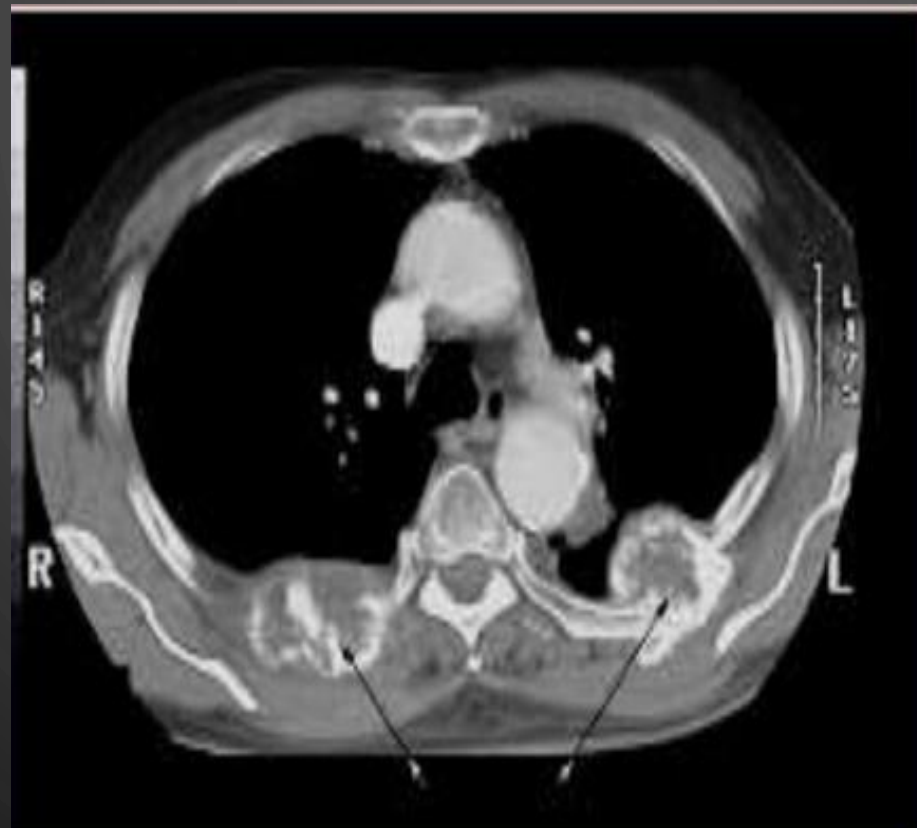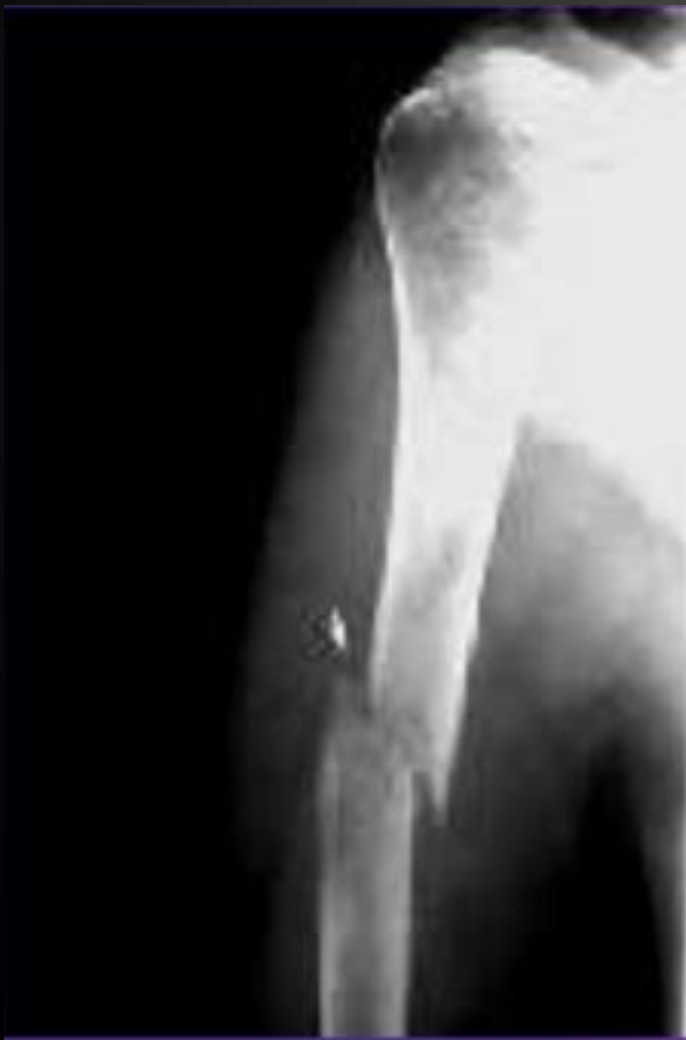# Adrenal metastases

- These are common and often solitary.
- These must be differentiated from adrenal adenomas.
- Lesions smaller than 1 cm are usually benign.
- Metastases are usually larger than 3 cm on non enhanced CT scans and have an attenuation coefficient of 10 HU or higher



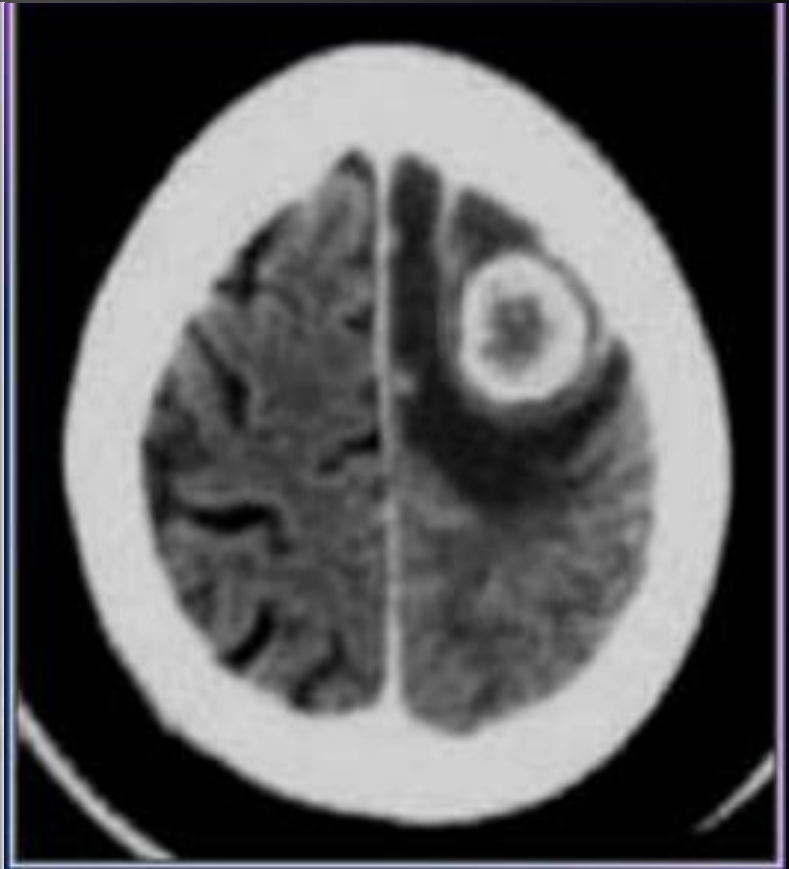
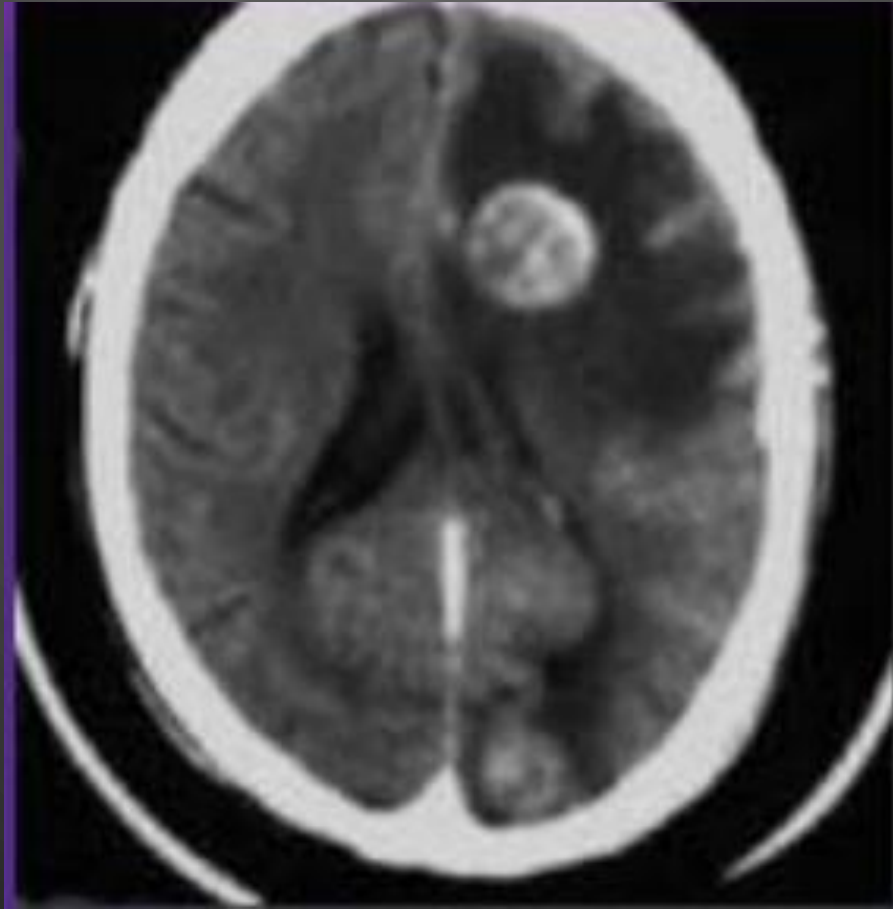
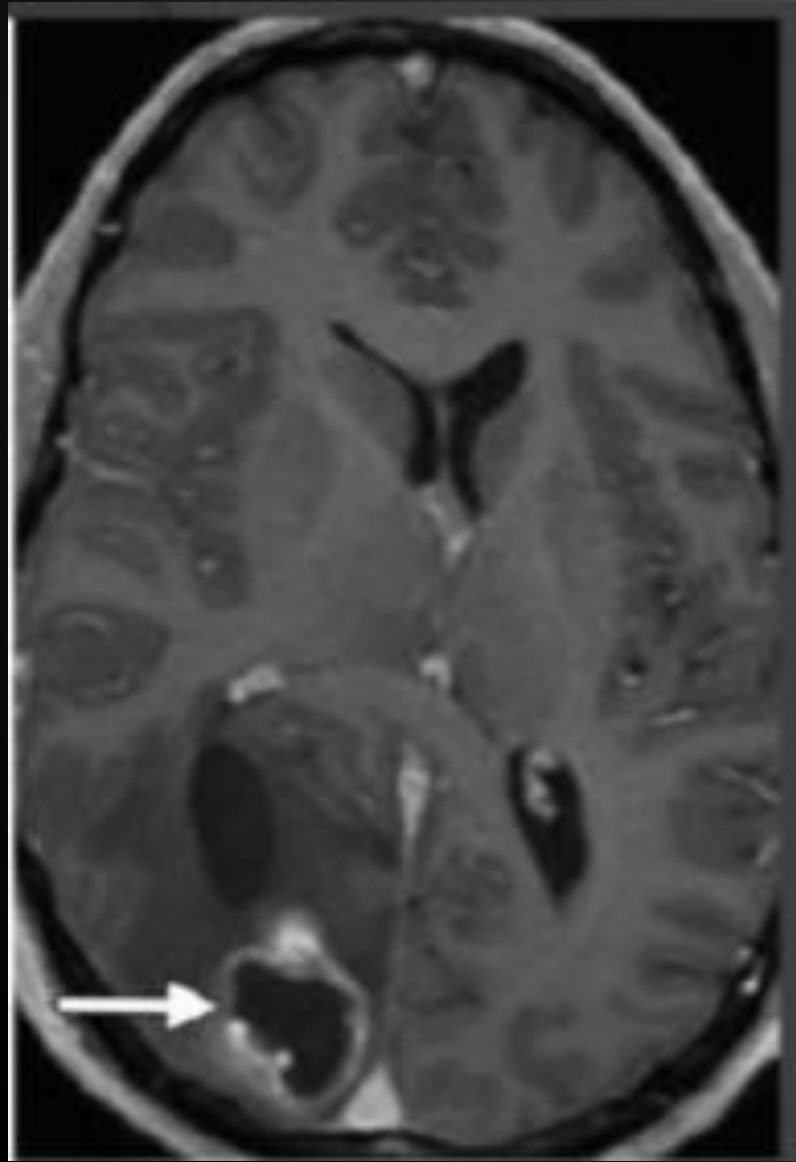
# Bone metastases

- Osteolytic (70%) and Osteoblastic (30%)
- Vertebrae (70%) , Pelvis (40%) , Femur (25%)
- The assessment requires comparison of the bone scans with plain radiograph.
- Plain radiograph typically shows destructive lytic lesions +/- pathological fractures.
- Technetium – 99m radionuclide bone scanning is indicated in patients with bone pain or local tenderness.
- The test has a 95% sensitivity for detection of mets but a high false positive rate because of degenerative disease and trauma .



# Brain metastases

- SCLC and Adenocarcinoma are the most common sources of cerebral Mets.
- Brain Mets are typically hemorrhagic and occur at the grey – white matter junction of the brain.
- MRI is superior to CT , specially in depicting the posterior fossa and the area of the adjacent skull base
- The brain is not routinely imaged in asymptomatic patients with NSCLC because of low incidence of silent cerebral mets (2-4%)





# Small cell carcinoma (OAT CELL LUNG CANCER)

**TABLE 4.7 Small Cell Lung Carcinoma**

15%–20% of lung cancers

Strongly associated with smoking

Neuroendocrine carcinoma

Paraneoplastic syndromes commonly associated

Most occur in main or lobar bronchi

Extensive peribronchial invasion

Large hilar or parahilar mass

Bronchial narrowing

Lymph node enlargement

Metastases at diagnosis in >90%

Prognosis very poor

# Radiographic features

- located centrally in majority of cases (90%)
- arise from main stem of lobar bronchi – appears as hilar or peri hilar mass
- commonly associated with mediastinal lymph node involvement
- cxr shows mediastinal widening due to lymph node enlargement
- ct shows numerous enlarged nodes with direct infiltration to the adjacent structures – m/c/c for **svc syndrome**.
- rarely present as a solitary pulmonary nodule
- **associated paraneoplastic syndromes**

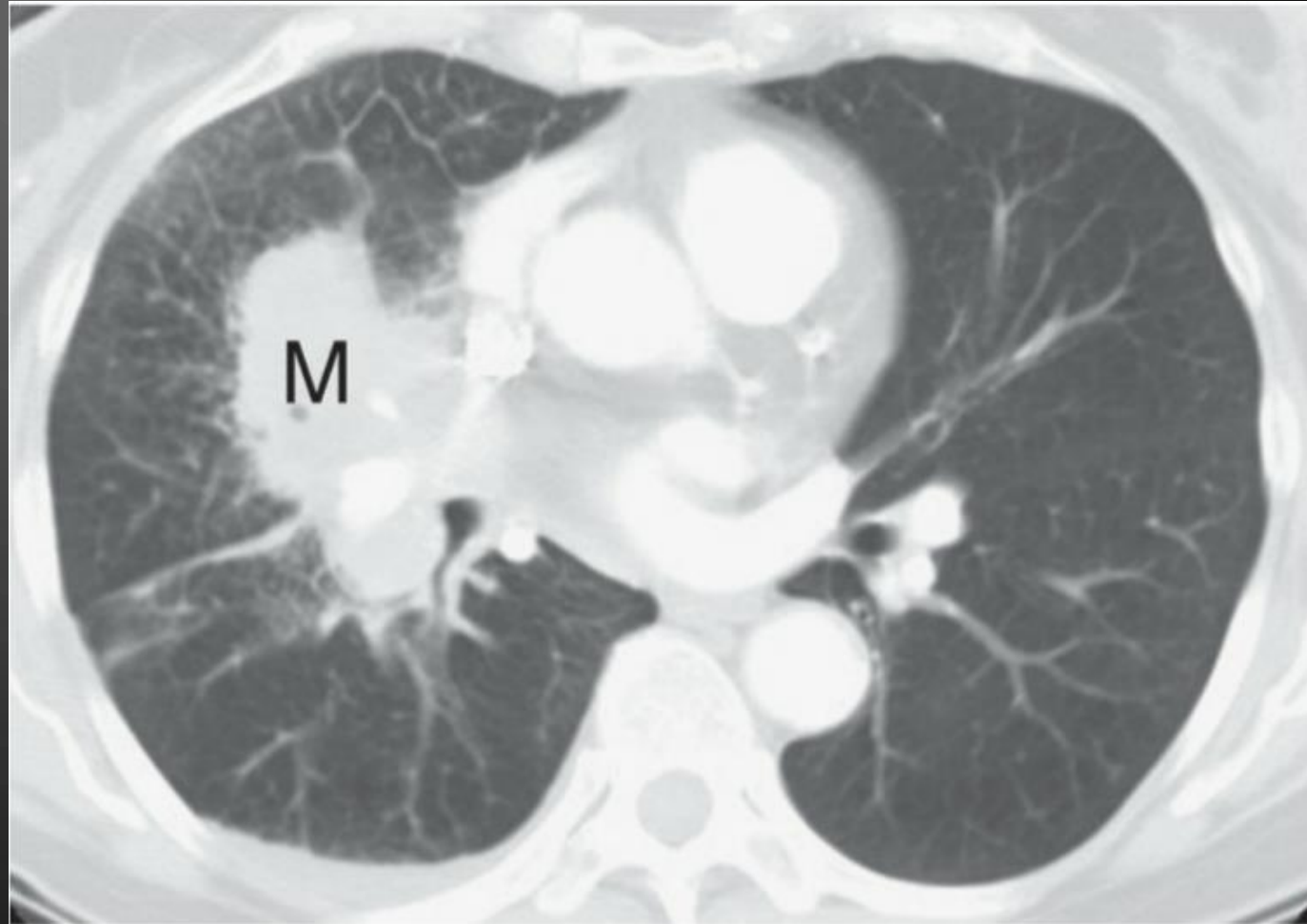
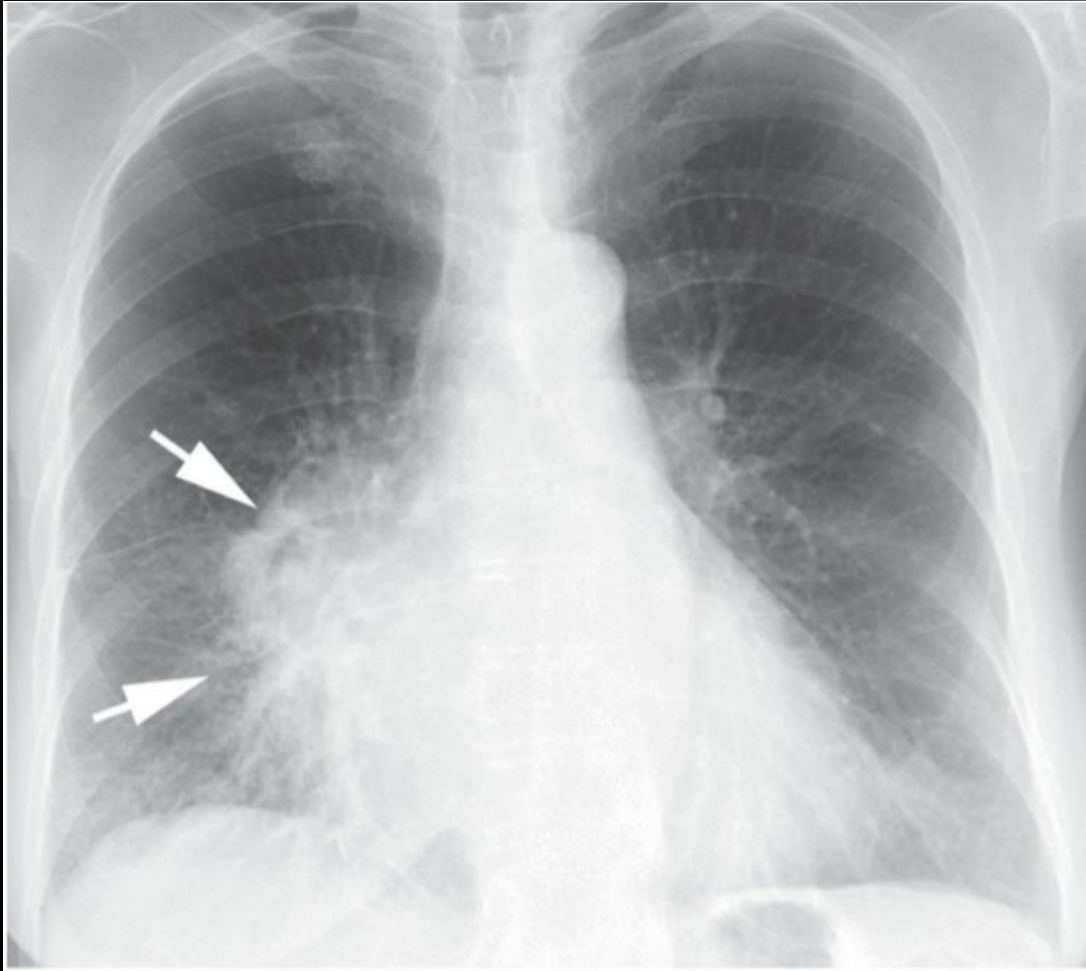
= siadh

= acth secretion – cushing syndrome

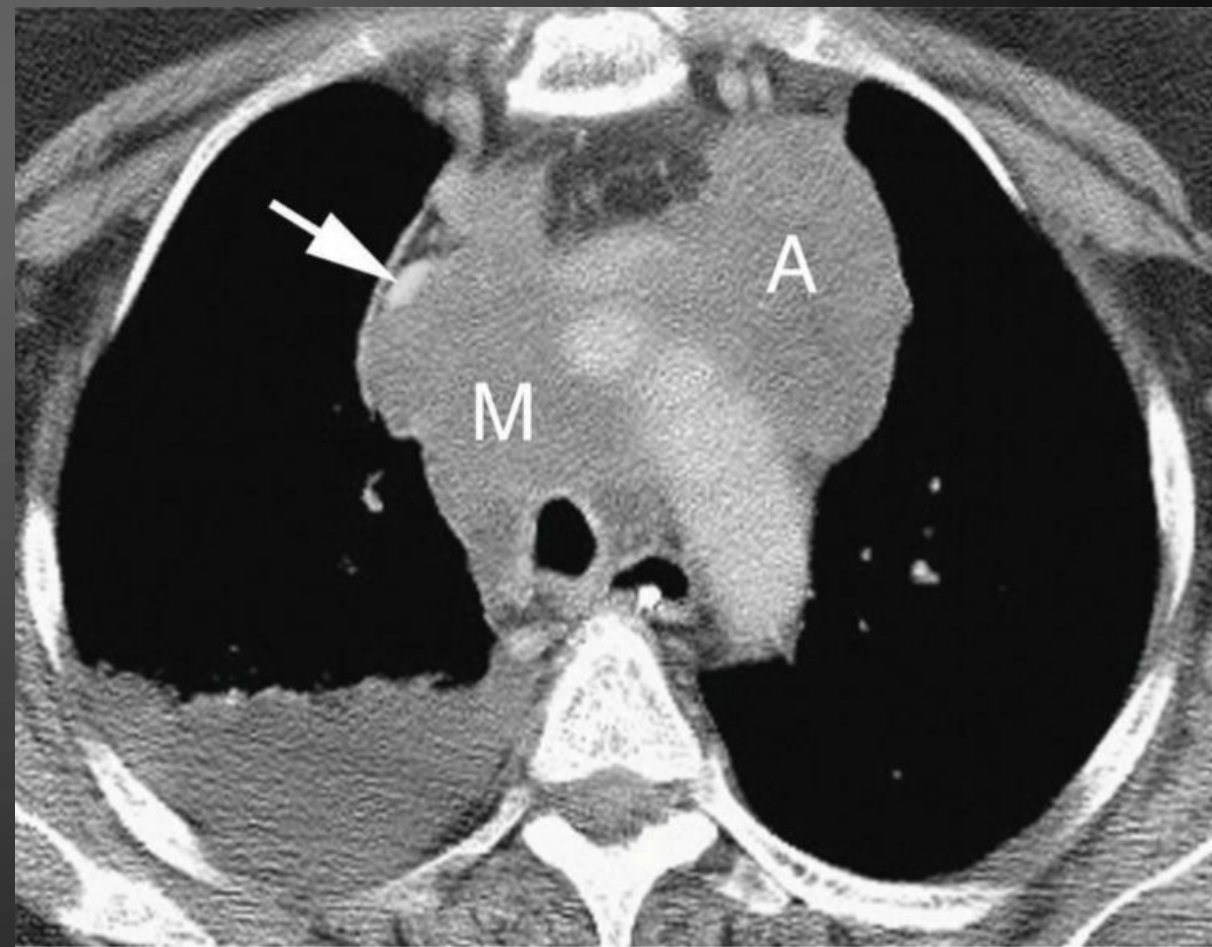
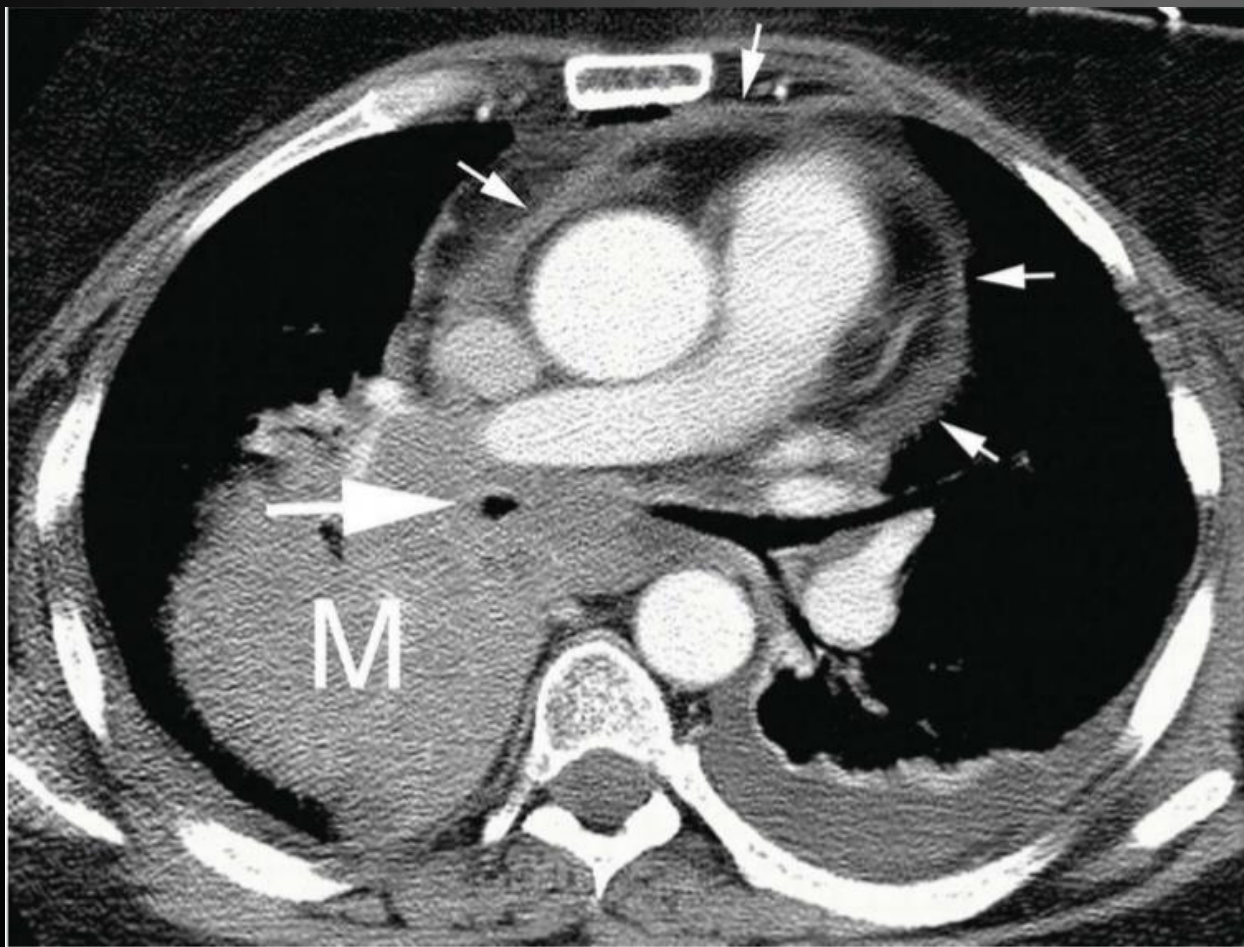
= acromegaly

= eaton lambert syndrome

# Radiographic features







# Squamous cell carcinoma

20% of lung cancer cases

Strongly associated with cigarette smoking **(MALES)**

65% arise in main, lobar, or segmental bronchi

- Endobronchial mass

- Bronchial obstruction

- Infiltration of bronchial wall

- Local invasion

- Hilar mass

- Atelectasis and consolidation common

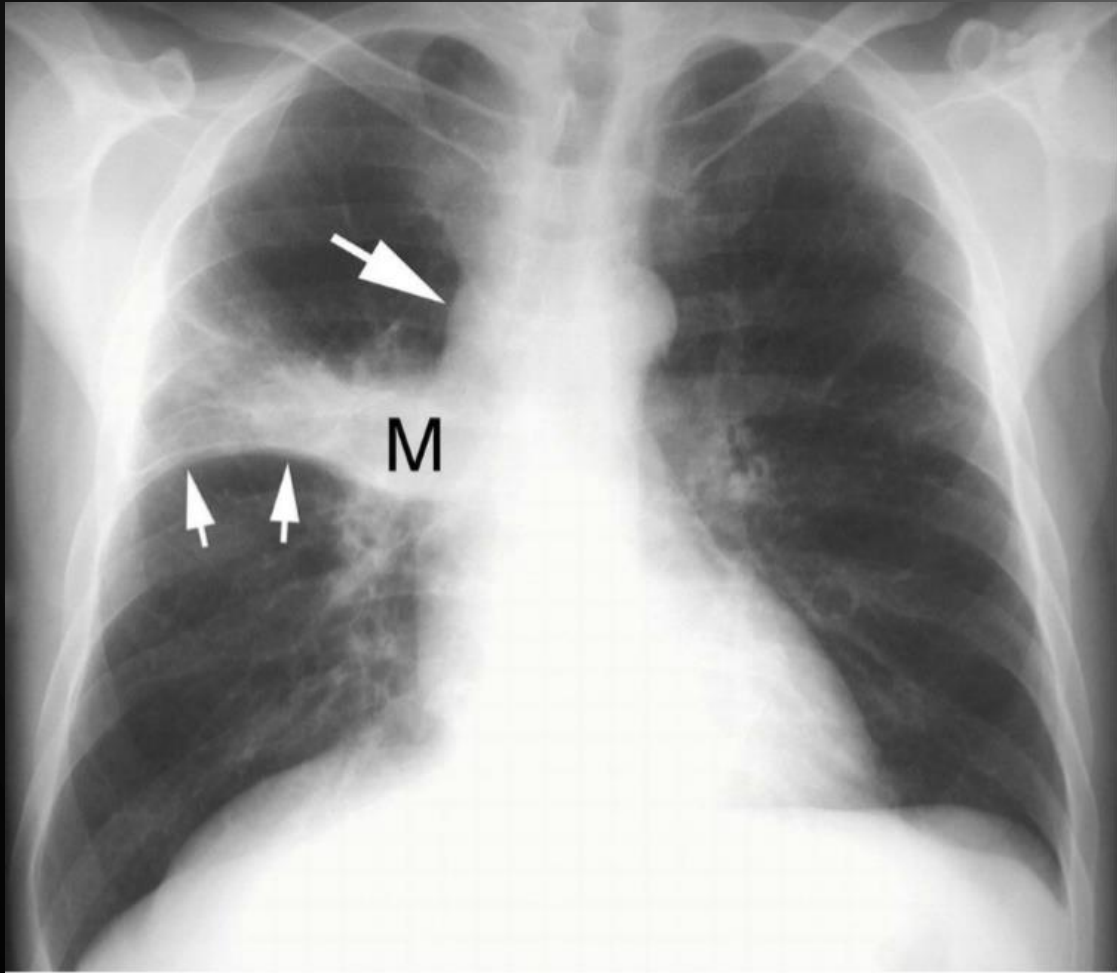
30% present as solitary nodule or mass

- Cavitation relatively common

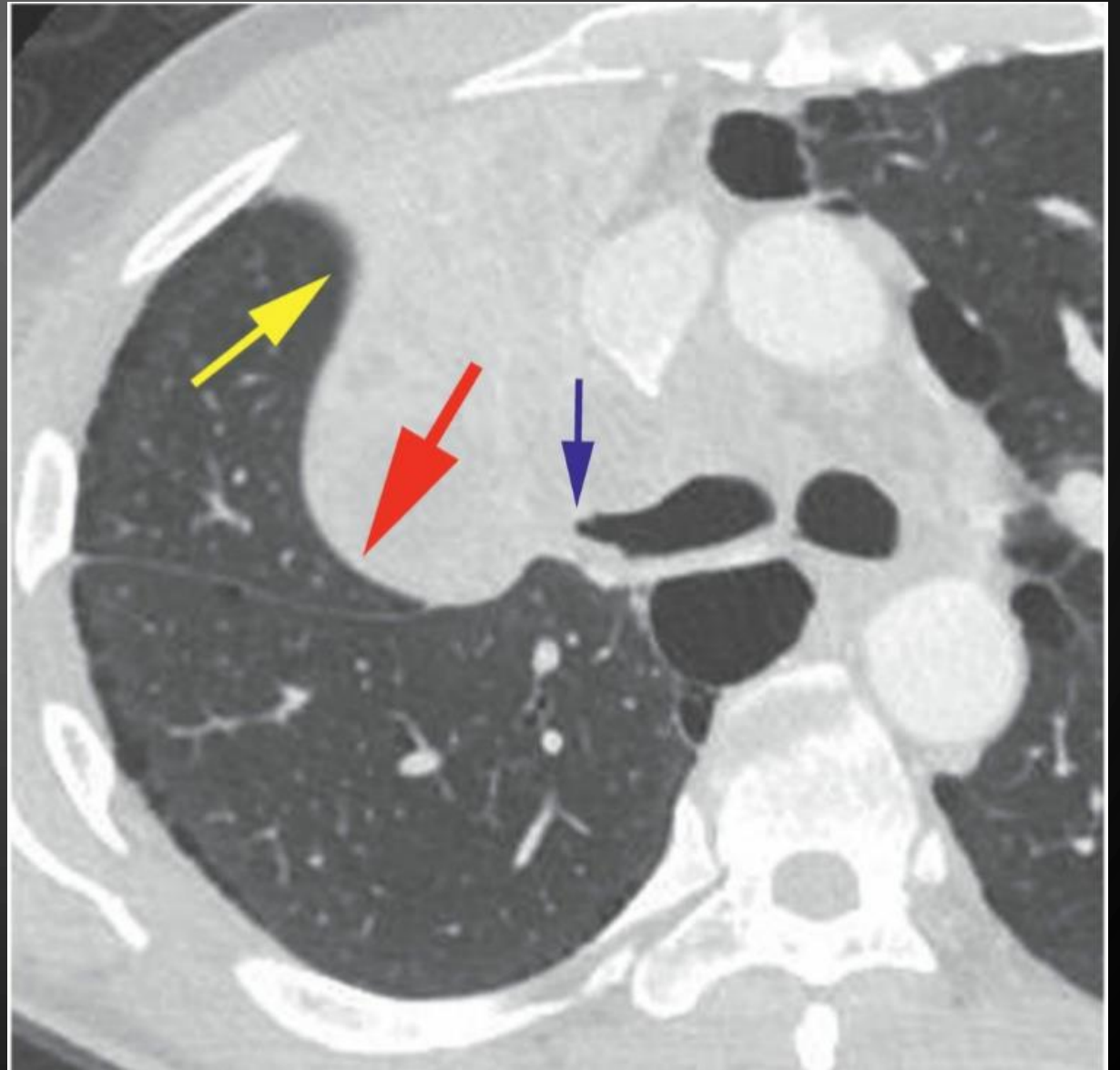
Metastasizes late **(GOOD 5 YEARS SURVIVAL RATE)**

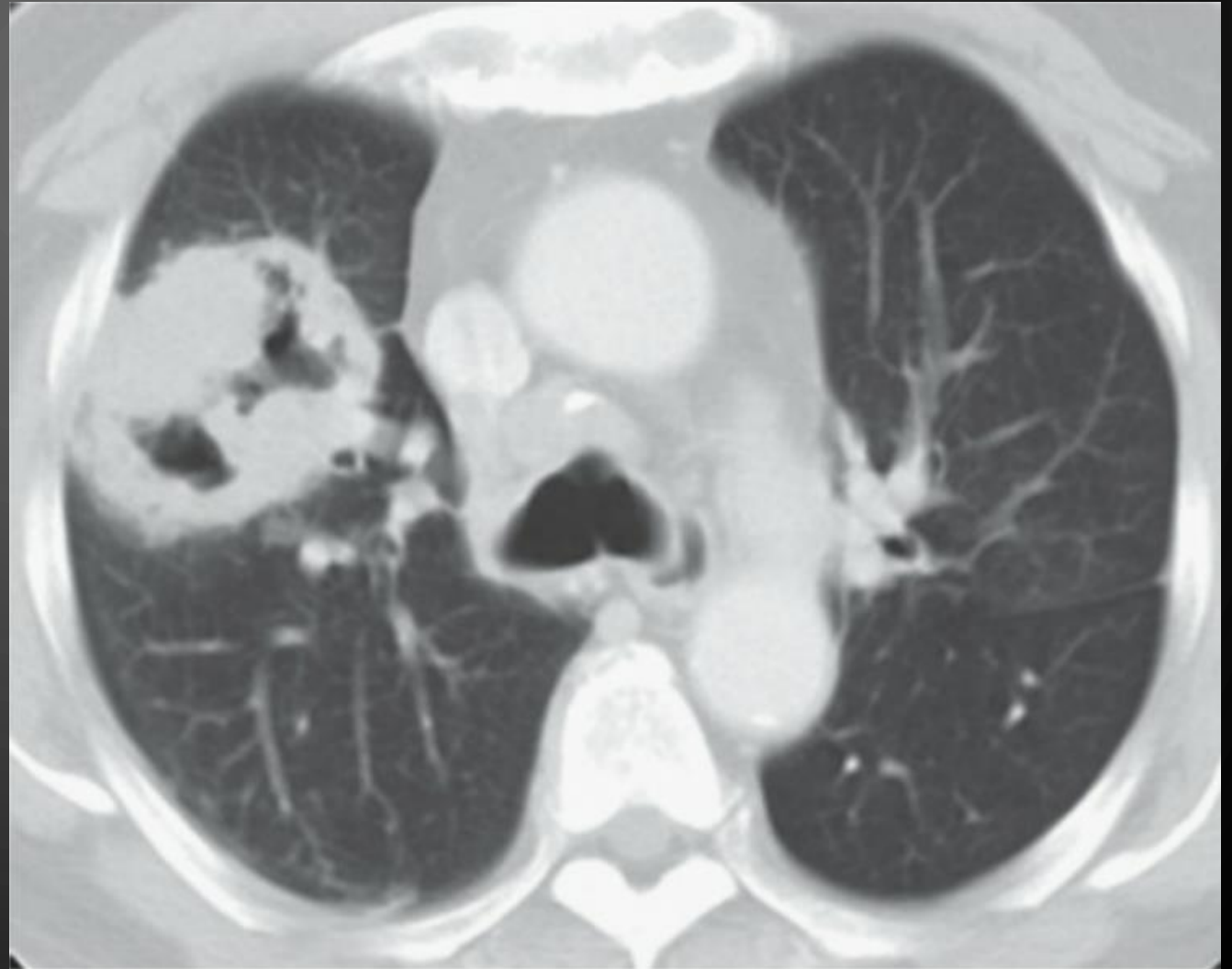
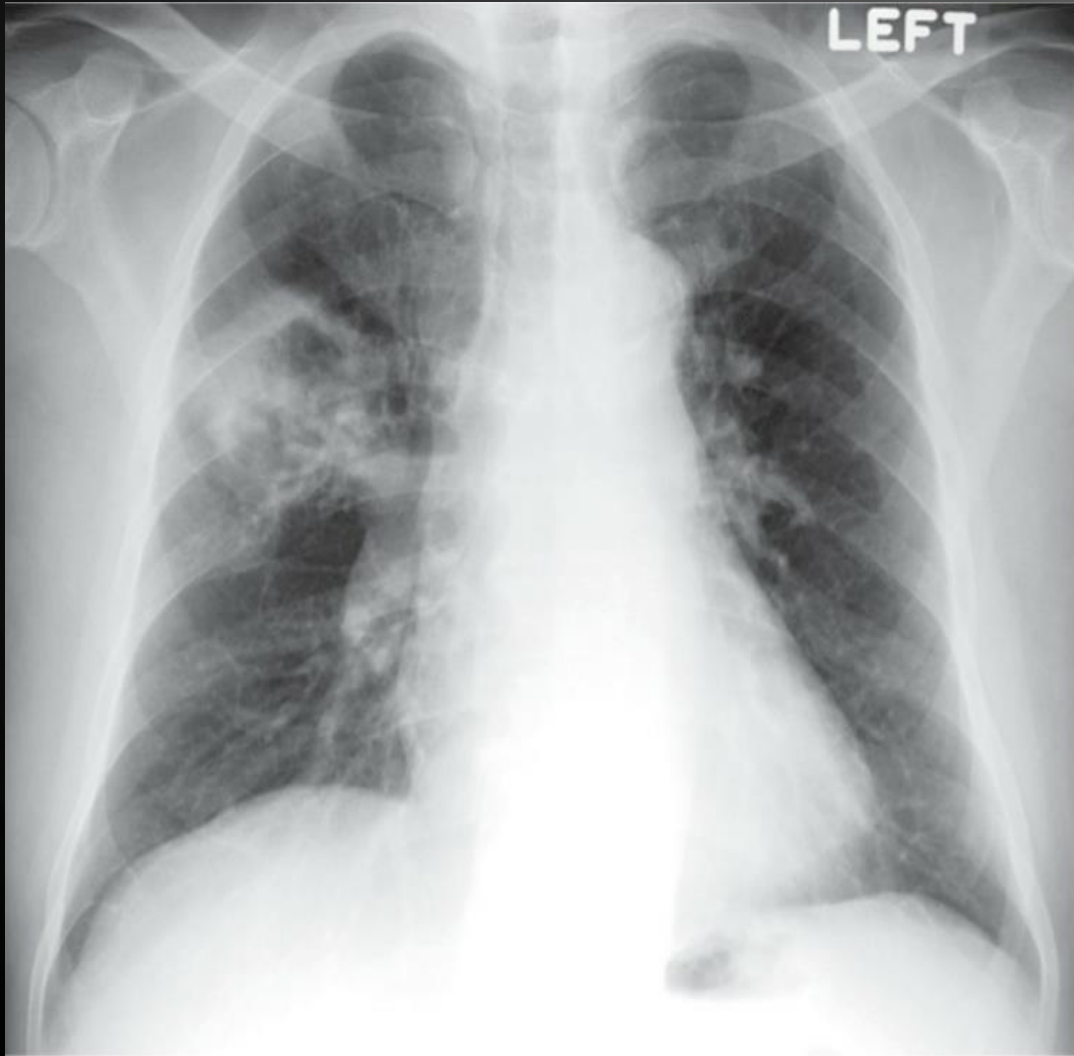Relatively good prognosis



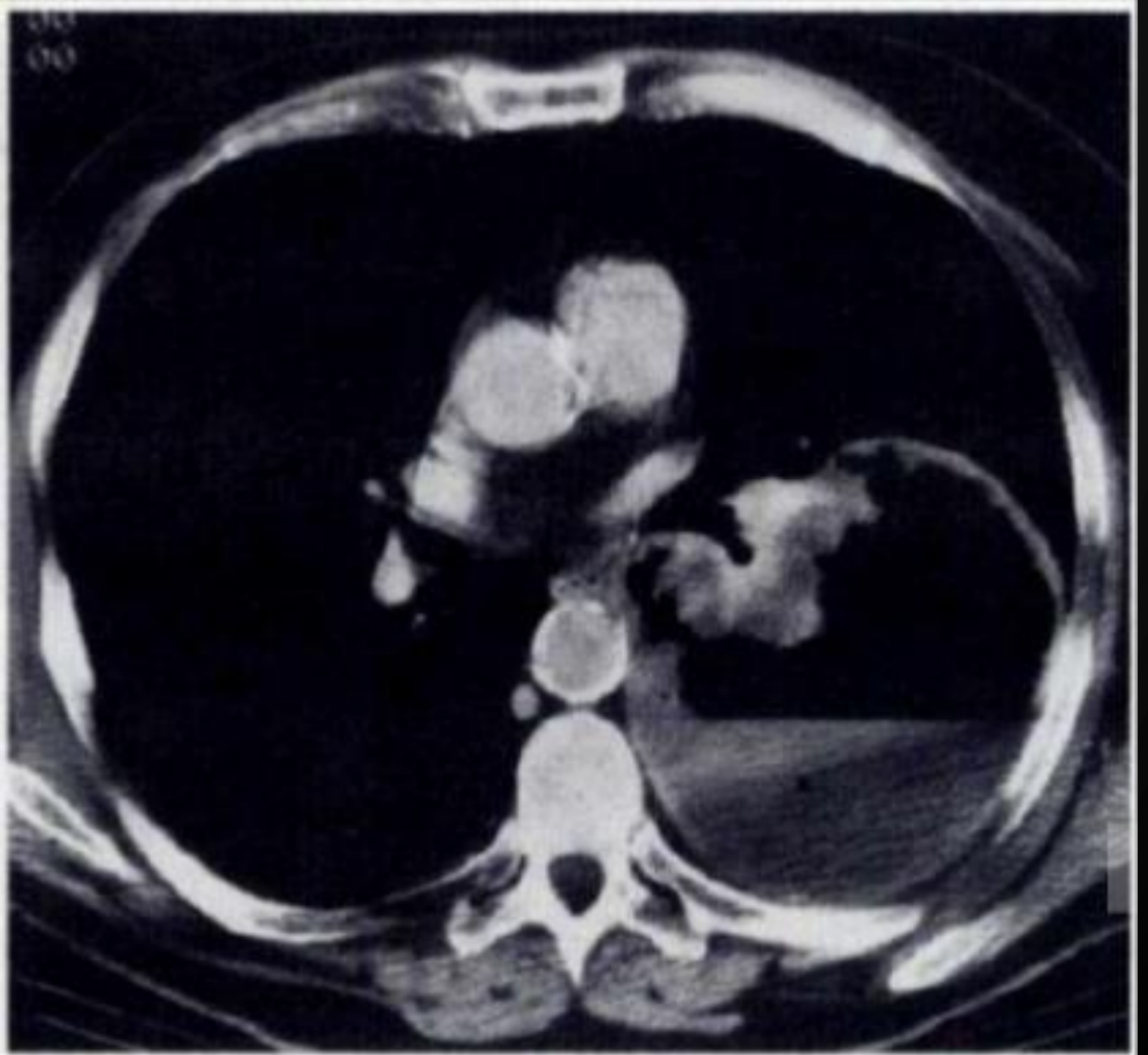
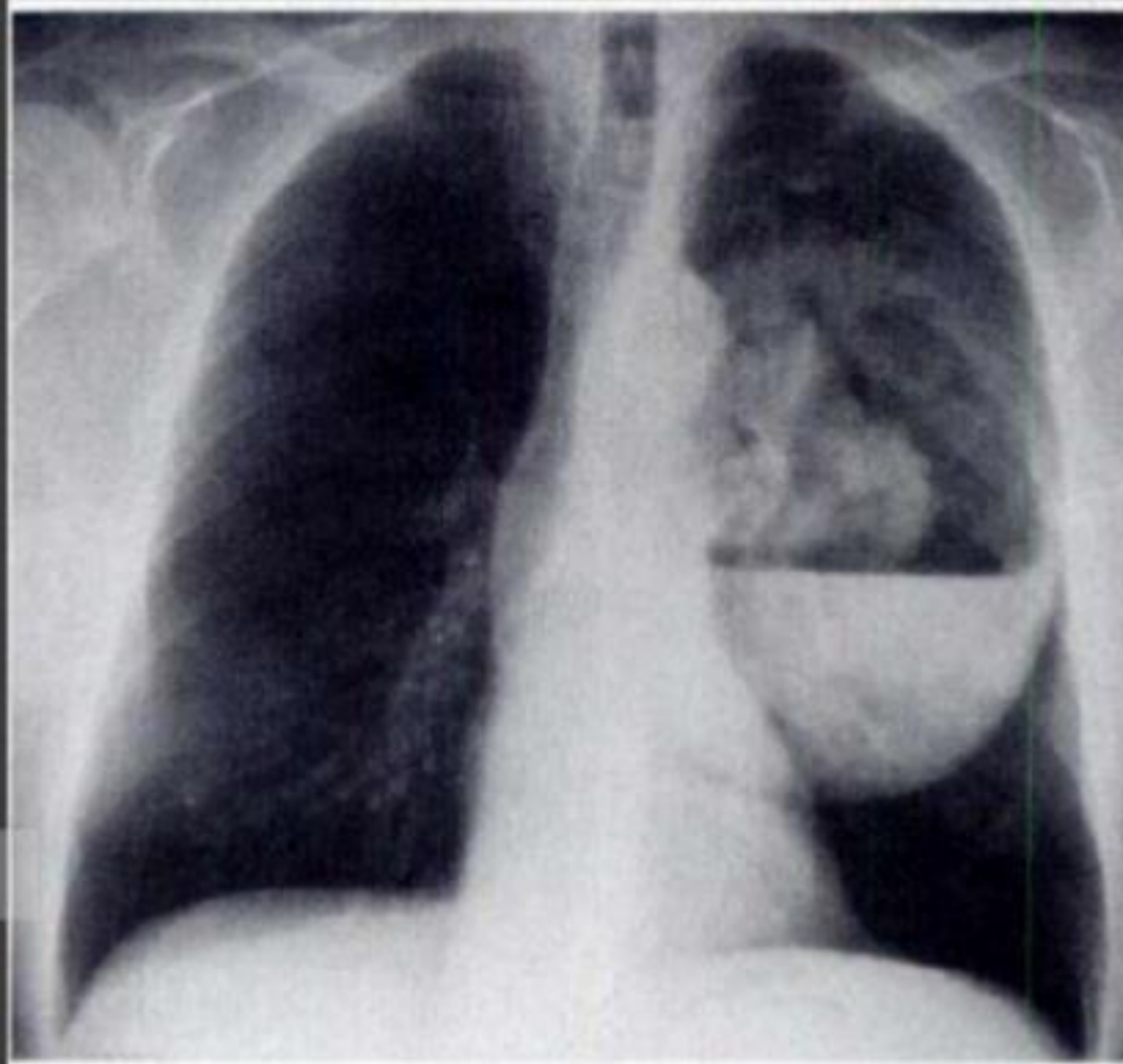


**GOLDEN S SIGN**





**CAVITATIONS**



CAVITATIONS IS SECONDARY TO TUMORAL NECROSIS



# Adenocarcinoma

40%–50% of lung cancer cases (most common cell type)

Weak association with smoking

Early metastases common

75% present as peripheral lung nodule

Common in the upper lobes

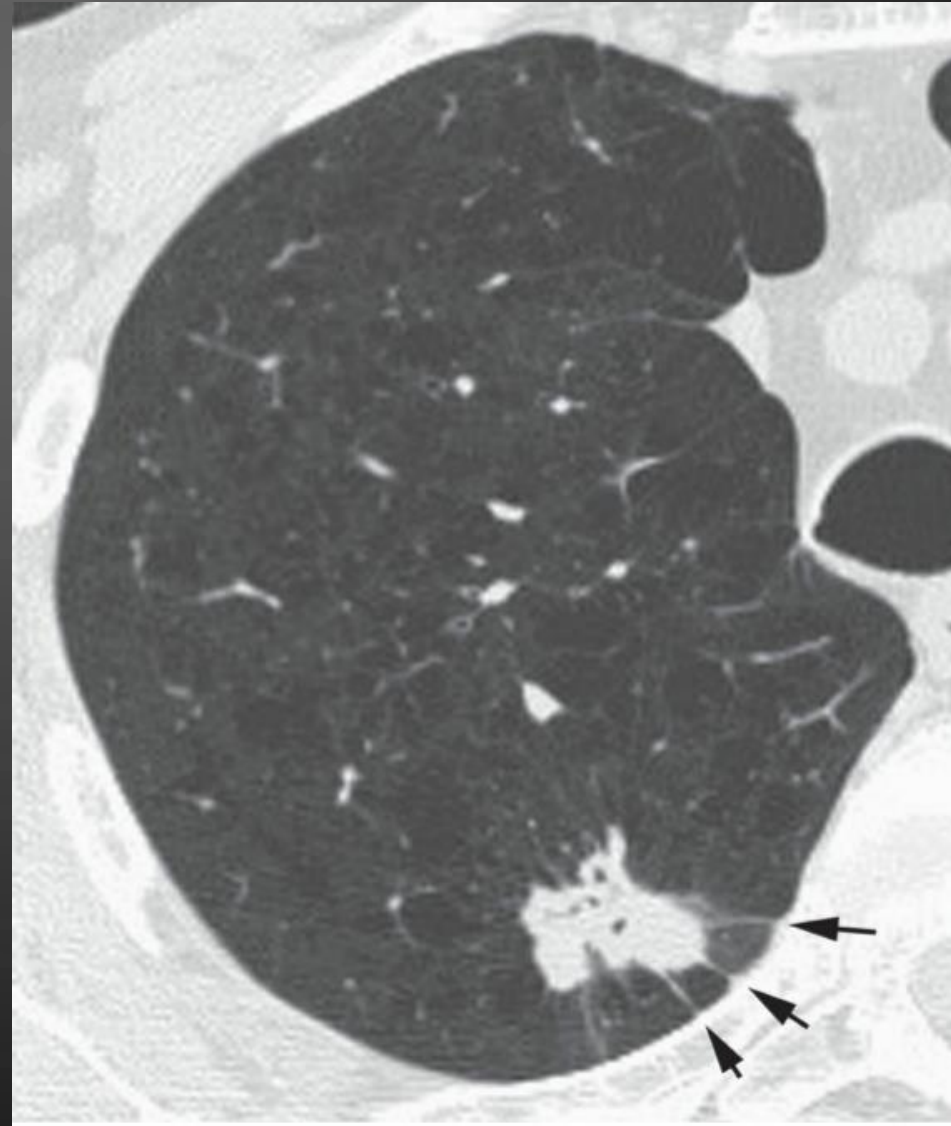
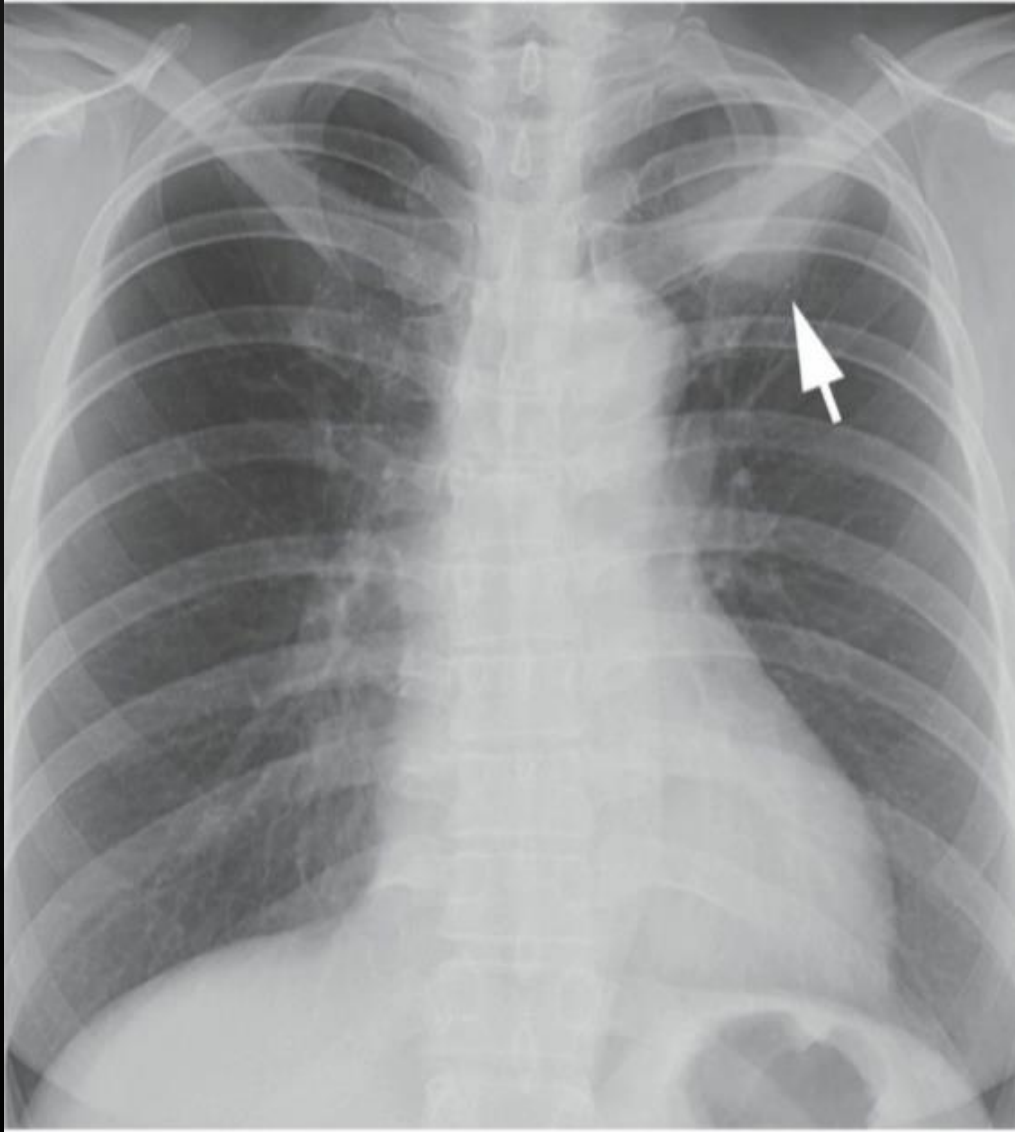
Often appear speculated

May be solid, part solid, or nonsolid (ground-glass opacity)

Appearance correlates with tumor type and survival

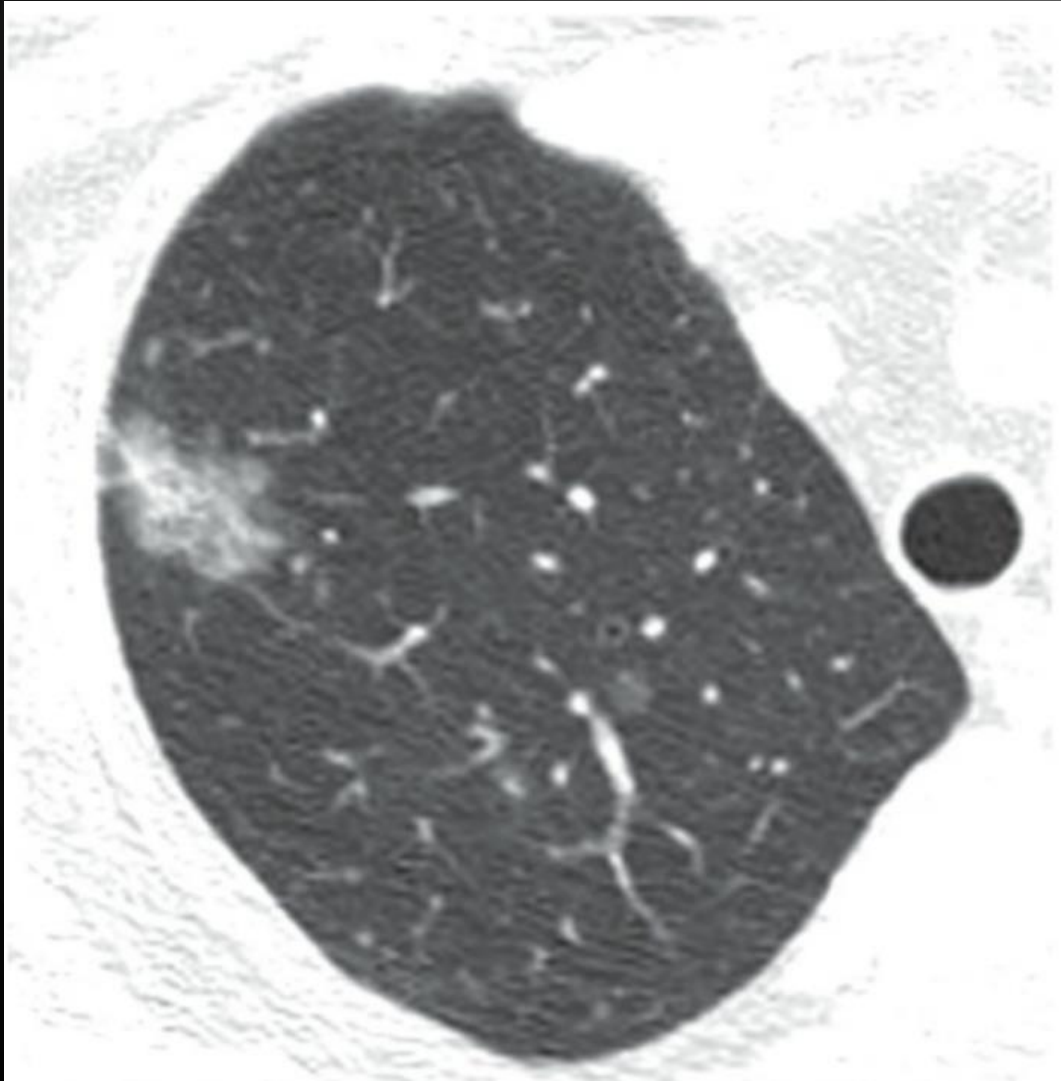
Mucinous and nonmucinous subtypes

- TUMOUR EXHIBITS VARIOUS PATTERNS AND DEGREE OF DIFFERENTIATION INCLUDING LEPIDIC , ACINAR ,PAPILLARY AND SOLID WITH MUCIN FORMATION
- MALIGNANT TUMOUR WITH GLANDULAR DIFFERENTIATION AND MUCIN PRODUCTION

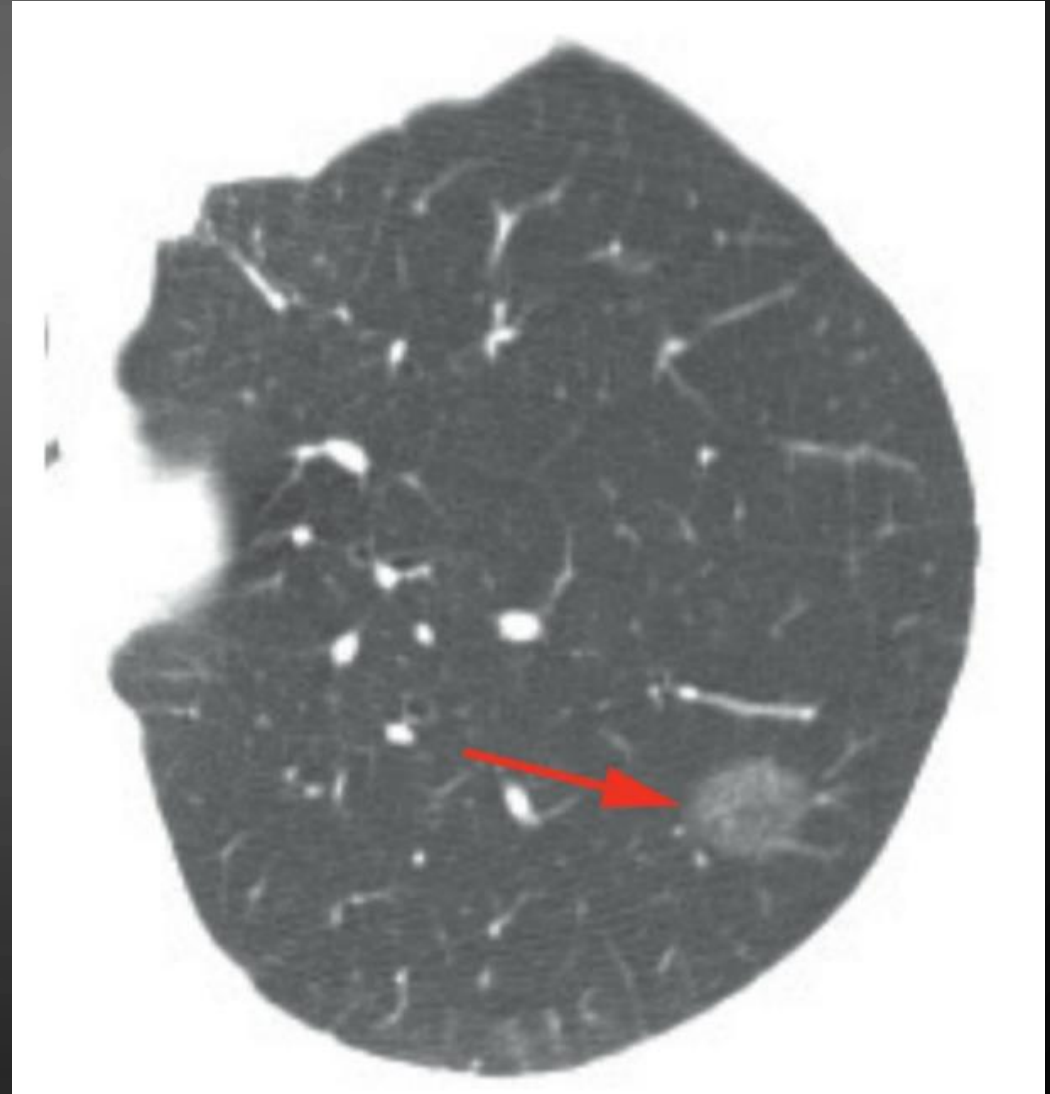


**SOLID**



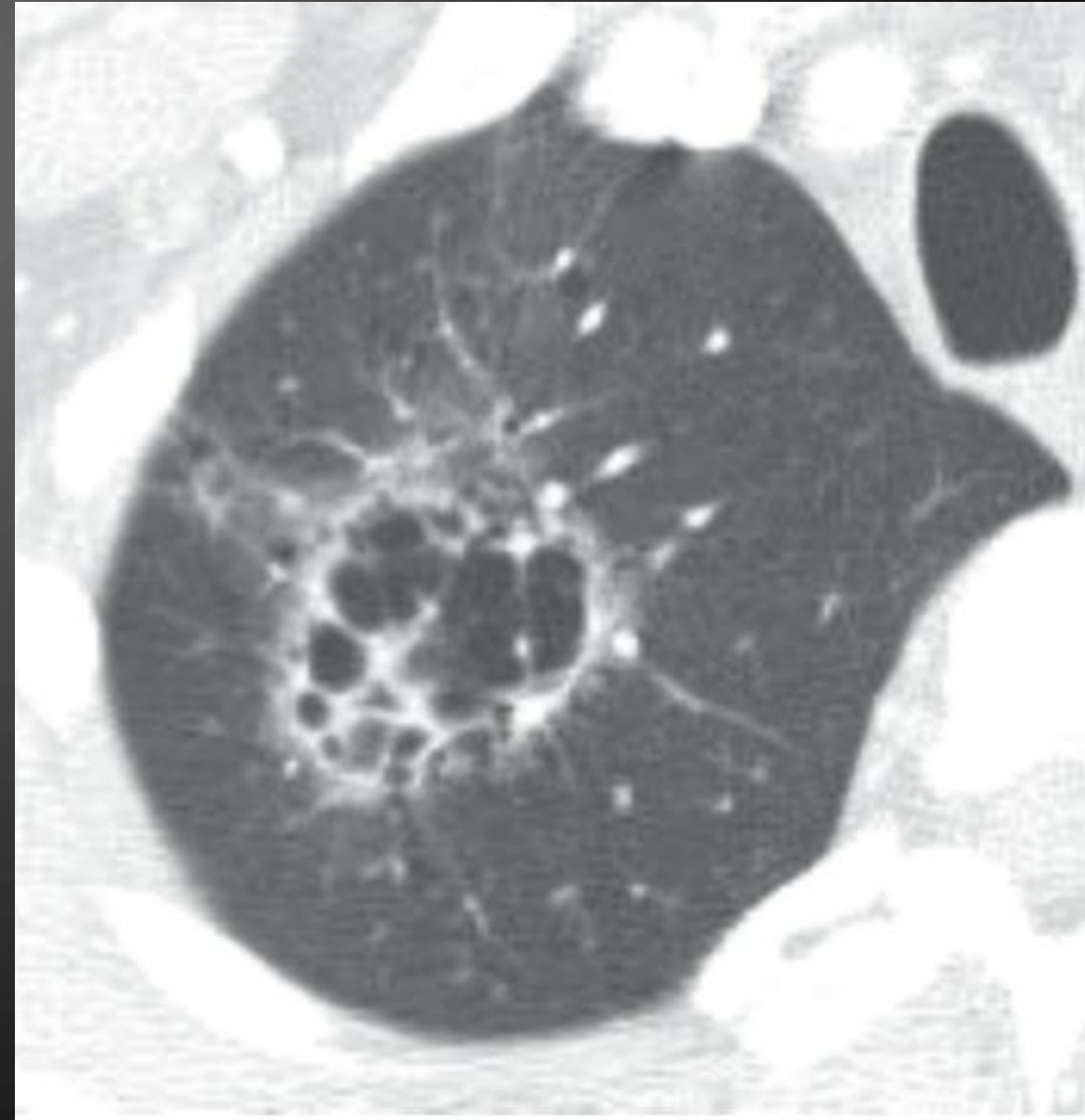


**SUB SOLID**



**NON SOLID**

- adenocarcinoma arising from wall of central bronchus is radiographically indistinguishable from scc
- ct features in adeno have been associated with egrf(air bronchogram , pleural tail) , alk and kras mutations
- adeno may appear as cystic or multi cystic mimicking a benign lesion



# Alveolar cell carcinoma

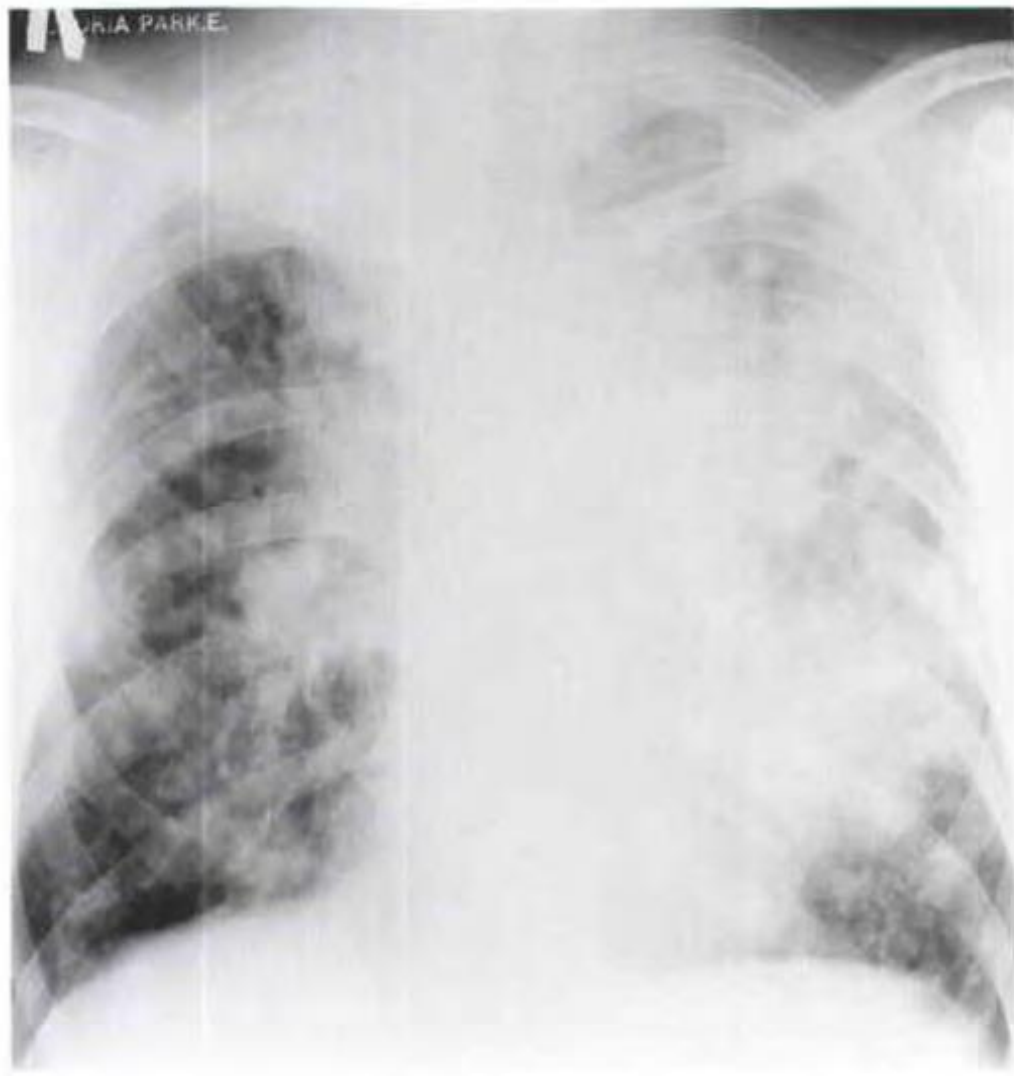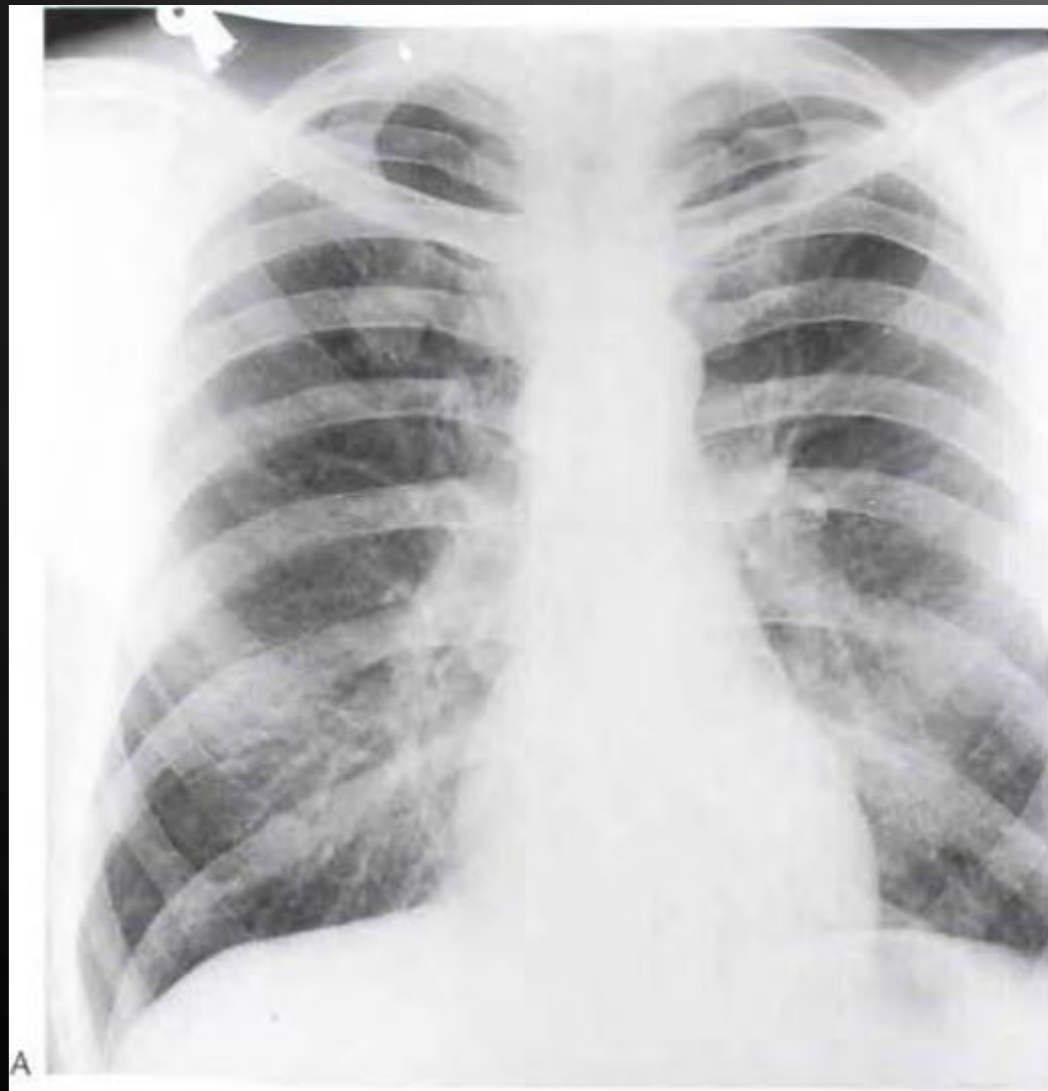
1. **Alveolar cell carcinoma = bronchiolar = bronchioloalveolar carcinoma**
2. is a *subtype of adenocarcinoma* with certain special features.
3. It arises more peripherally than typical lung cancer, probably from type II pneumocytes.
4. It accounts for 2–5% of all lung cancers, usually occurring between the ages of 50 and 70 years with an equal sex incidence.
5. It is not associated with smoking but may be associated with diffuse pulmonary fibrosis and pulmonary scars.
6. These tumors arise within alveoli and produce areas of consolidation. Clinically two patterns are seen.

## **FOCAL FORM**

As a solitary peripheral mass  
An air bronchogram is often visible

## **DIFFUSE FORM**

As multiple acinar shadows throughout the lungs  
Resemble pulmonary edema or bronchopneumonia





# Large cell carcinoma

5% of lung cancers

Strongly associated with smoking

Reclassified as an undifferentiated carcinoma without markers of another cell type (e.g., adenocarcinoma, squamous cell carcinoma, LCNEC)

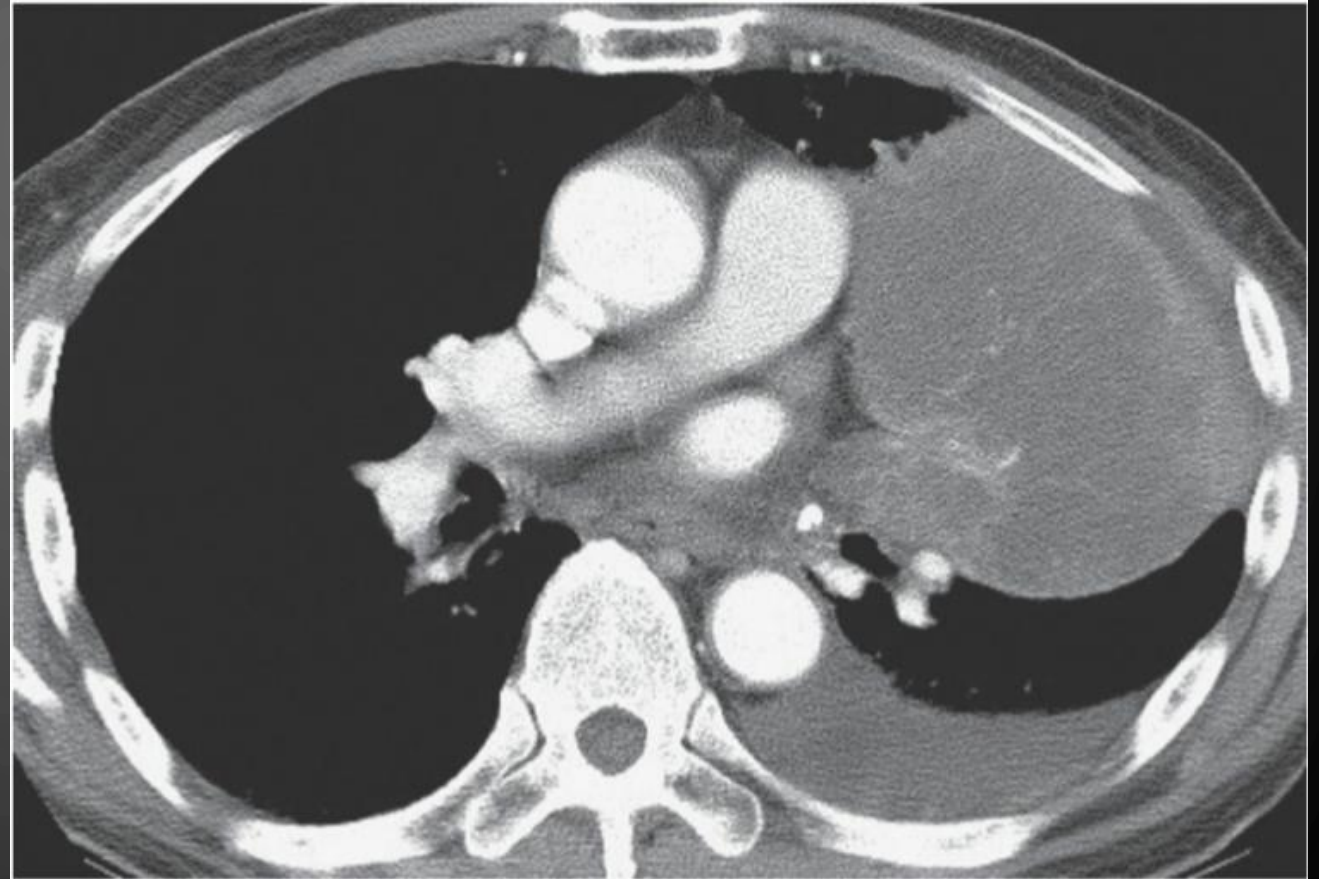
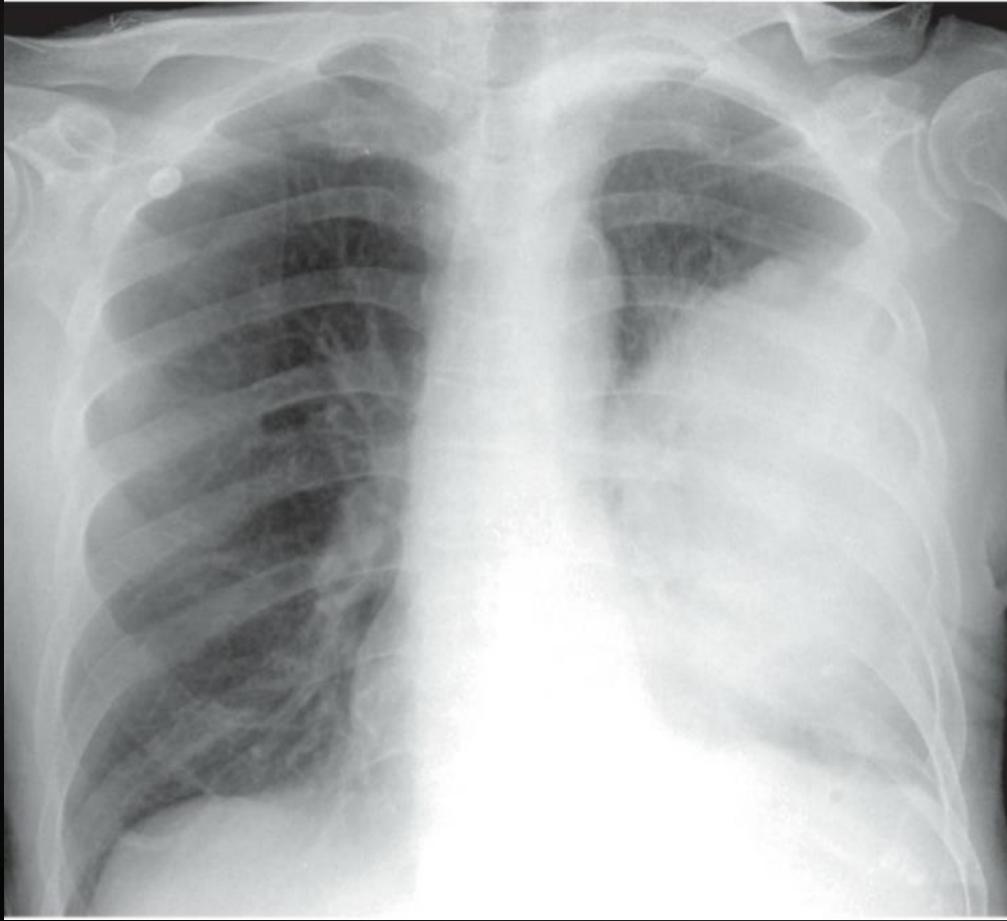
Usually present as a large peripheral mass (>4 cm)

Metastasizes early

Prognosis poor

**IT IS SIMILAR TO ADENOCARCINOMA IN ITS RADIOLOGICAL FEATURES EXCEPT FOR ITS LARGE SIZE**





TYPICALLY PRESENTS AS A LARGE PERIPHERAL MASS OF SOLID ATTENUATION AND IRREGULAR MARGIN WITH FOCAL NECROSIS

**TABLE 4.10 Plain Radiologic Findings in Lung Cancer by Cell Type<sup>a</sup>**

Finding	Squamous (%)	Adenocarcinoma (%)	Small Cell (%)	Large Cell (%)
Peripheral nodule or mass	30	75	5	65
Atelectasis	40	10	20	15
Consolidation	20	15	20	25
Hilar enlargement	40	20	80	30
Mediastinal mass	<5	<5	15	10
Pleural effusions	5	5	5	5
No abnormalities	5	<5	0	0
Multiple abnormalities	35	30	65	45

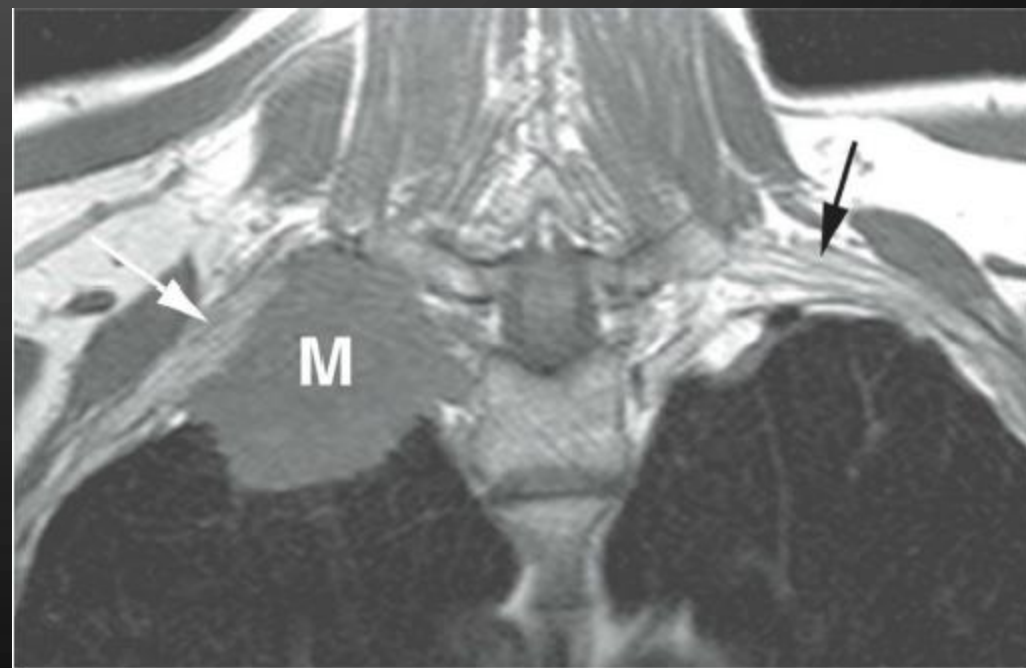
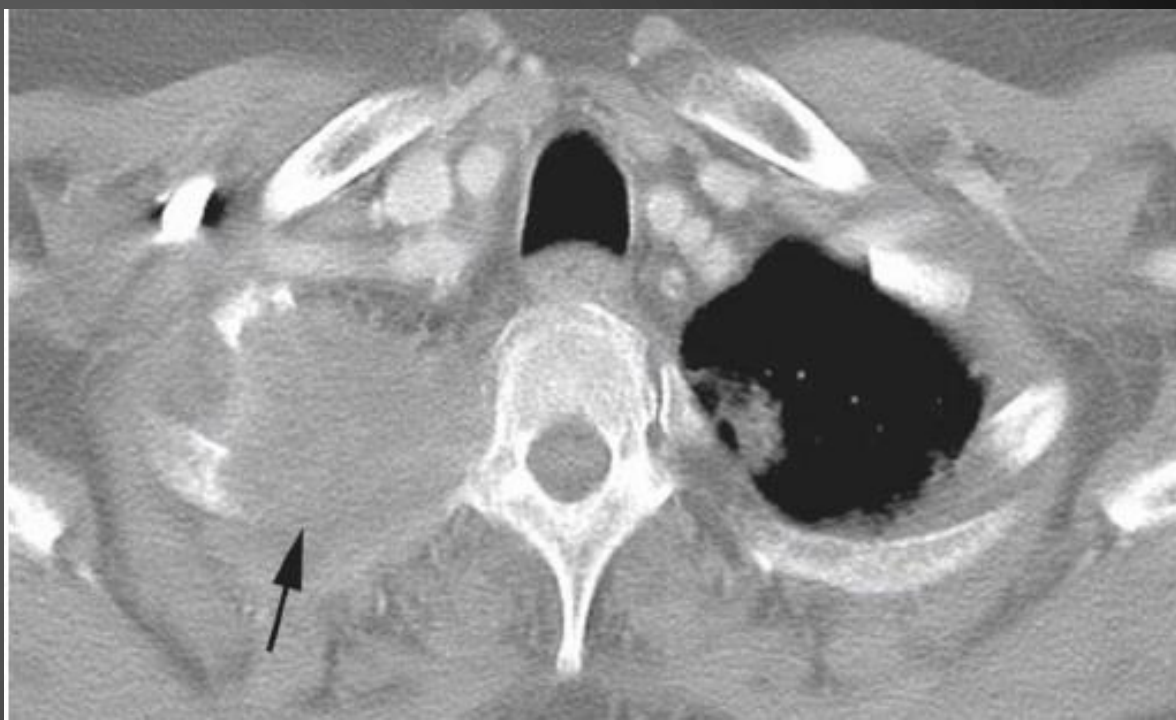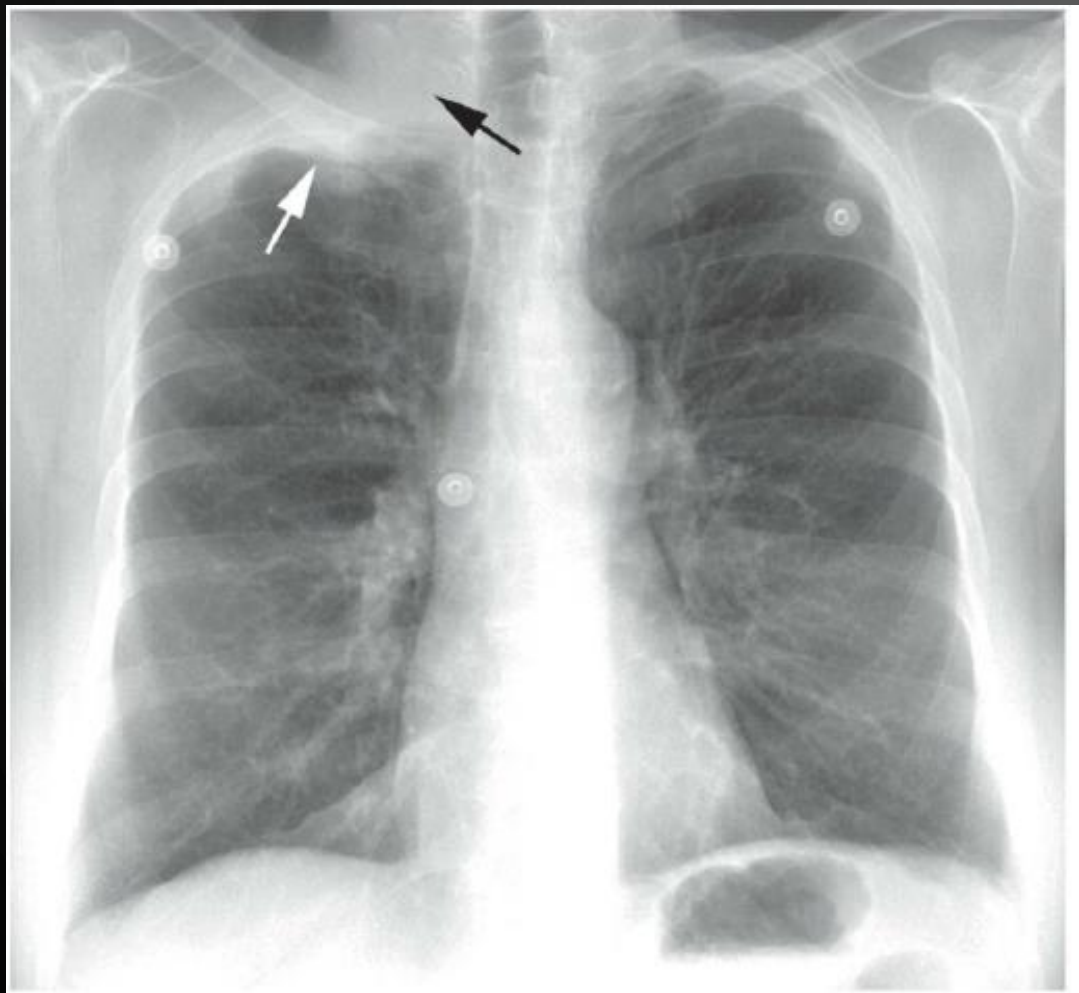
# Superior Sulcus (Pancoast) Tumor

- Approximately 3% to 5% of lung cancers occur in the superior sulcus; any cell type may be responsible, **BUT ADENOCARCINOMA PREDOMINATES**.
- Tumors arising at or near the lung apex are termed superior sulcus carcinoma, thoracic inlet carcinoma, or simply apical carcinoma.
- Pancoast syndrome results from involvement of the brachial plexus and sympathetic ganglia and consists of the combination of
  1. Pain in the shoulder
  2. Radicular pain along the distribution of the eighth cervical and first and second thoracic nerves, sometimes associated with wasting of the small muscles of the hand
  3. Horner's syndrome, consisting of ptosis, miosis, and hemifacial anhidrosis

# Radiographic findings

- Radiographic findings include an apical mass (60%), unilateral or asymmetrical apical pleural thickening (“apical cap,” 40%), and bone destruction (25%). Asymmetry in the thickness of an apical cap exceeding 5 mm is considered suggestive. The presence of an apical cap may reflect diseases other than carcinoma.
- MRI in the sagittal or coronal planes is particularly advantageous and is more accurate than CT in diagnosing apical chest wall invasion and its extent

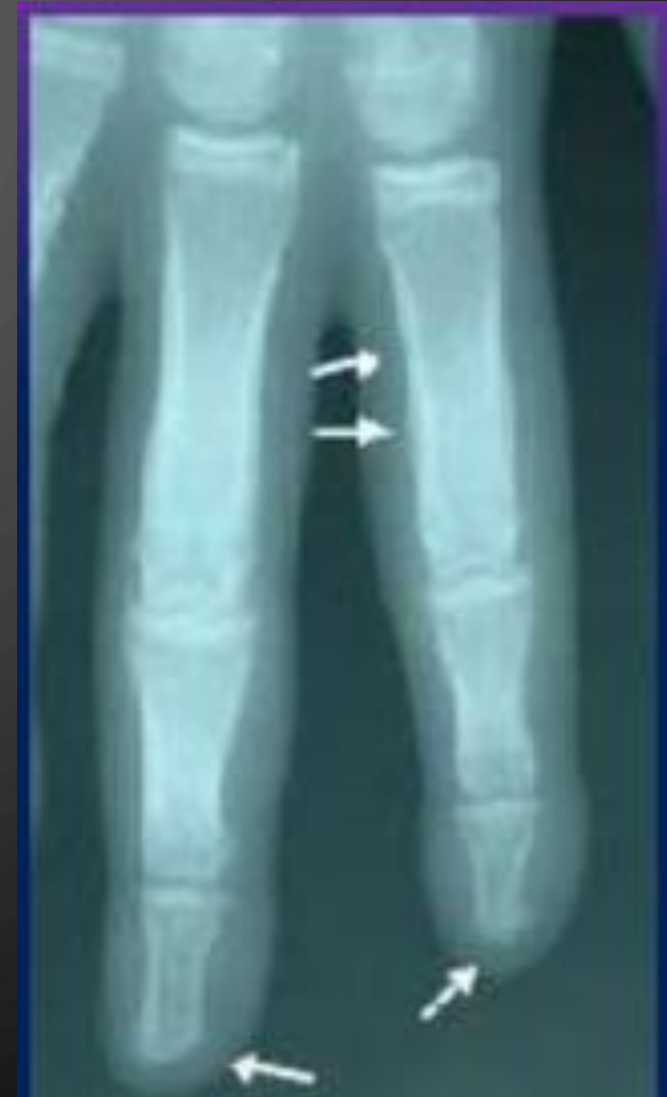





# Hypertrophic osteoarthropathy

- Aka Bamberger – marie syndrome
- It is a paraneoplastic syndrome most often found in non – small cell lung cancer
- It is a medical condition combining clubbing and periostitis of the upper and lower extremities.
- Distal expansion of the long bones as well as painful , swollen joints and synovial villous proliferation are seen .
- Diagnosis is confirmed by the characteristic bone changes on plain radiograph and periostitis on bone scintigram



Thank you!

© John McPherson/Distributed by Universal Uclick via CartoonStock.com 2-20 McPHERSON



**"It was a placebo surgery. I cut him open and just stitched him back up. I guarantee his phantom chest pains will be gone."**