

# Imaging In Brain & Spinal Tumours

MRI & PET-CT; Radiology & Radio-genomics

**Dr. Ritika Harjani Hinduja**

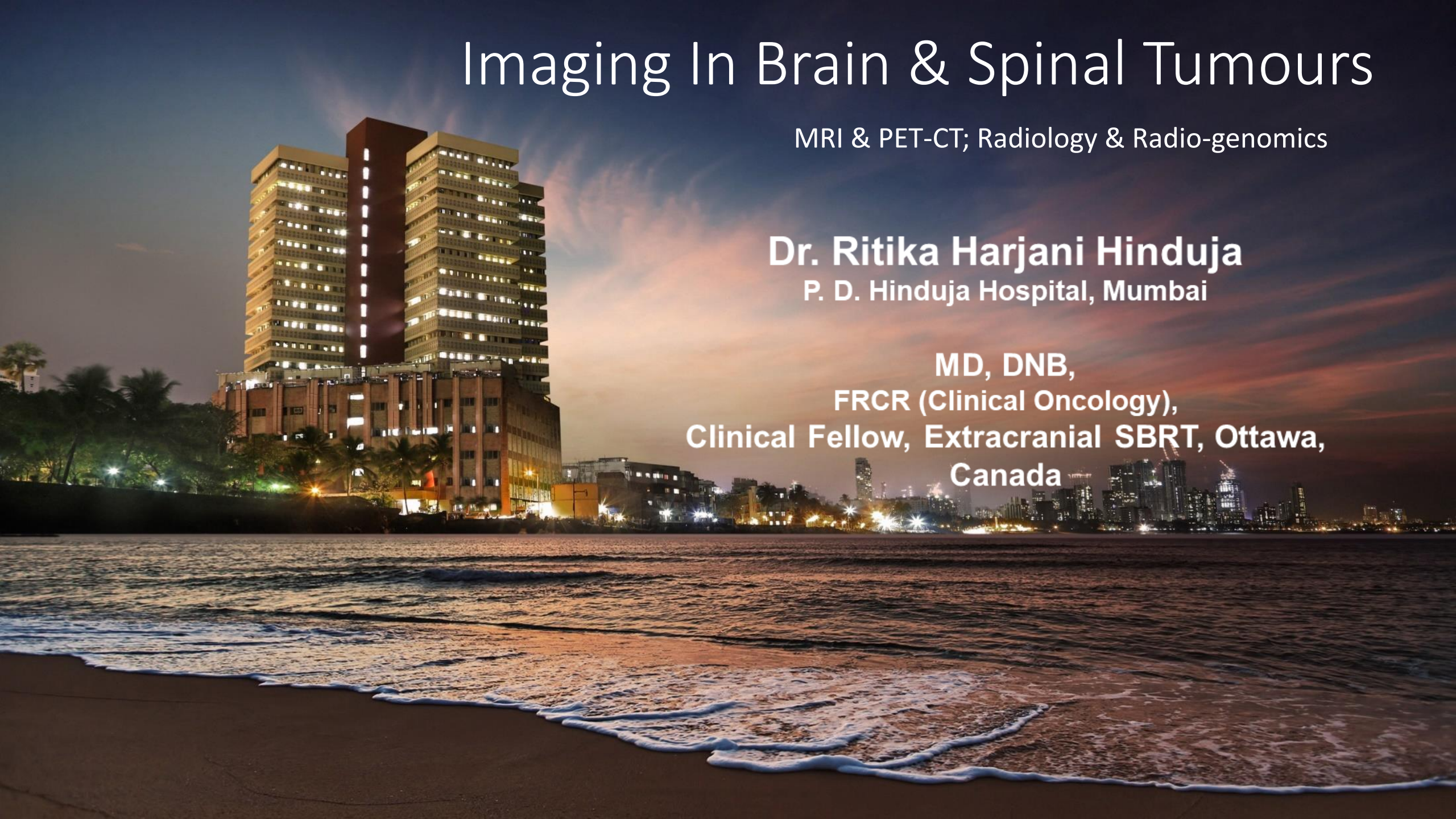P. D. Hinduja Hospital, Mumbai

MD, DNB,

FRCR (Clinical Oncology),

Clinical Fellow, Extracranial SBRT, Ottawa,

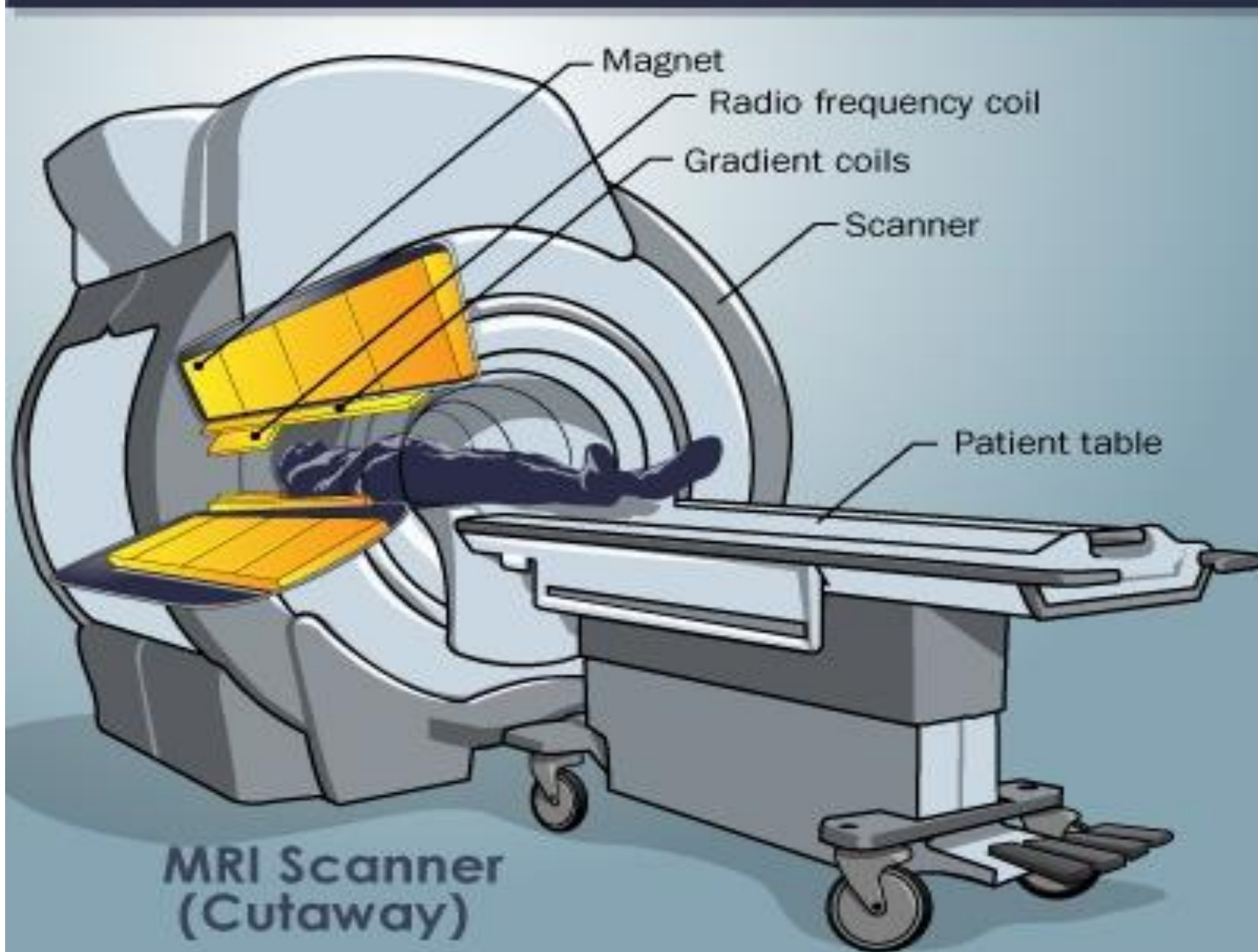
Canada



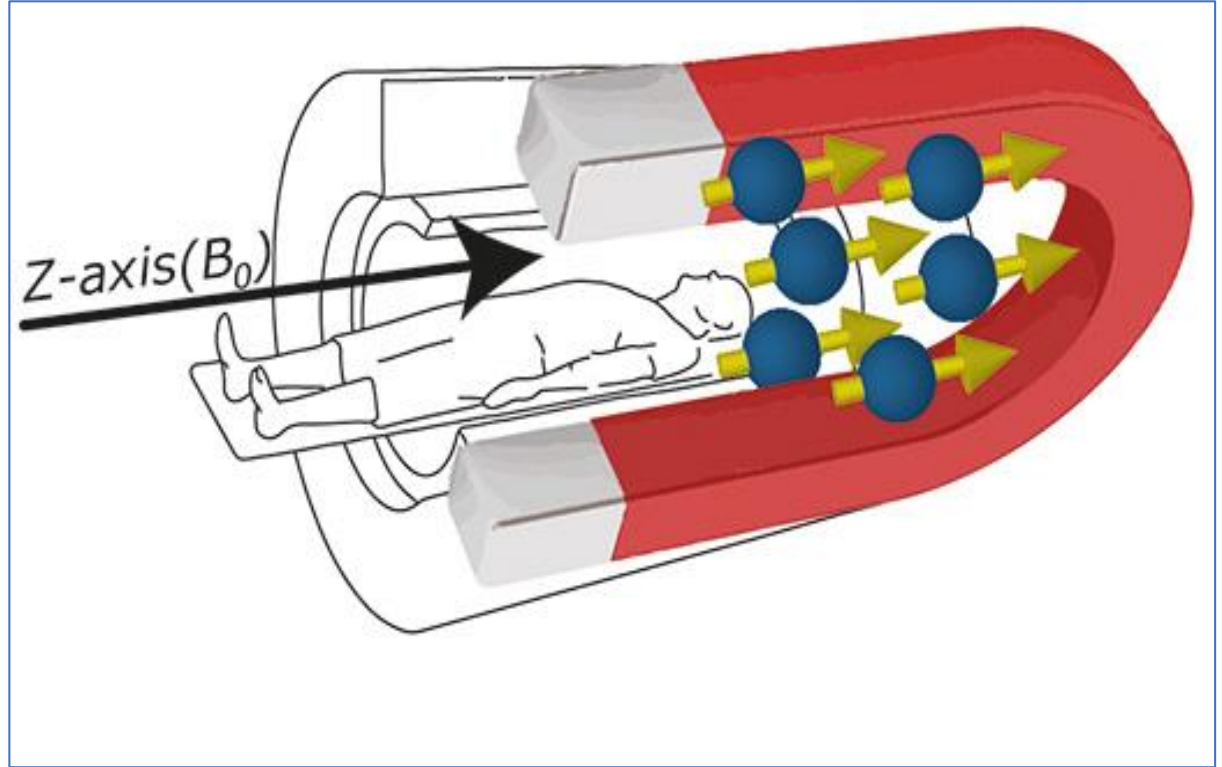
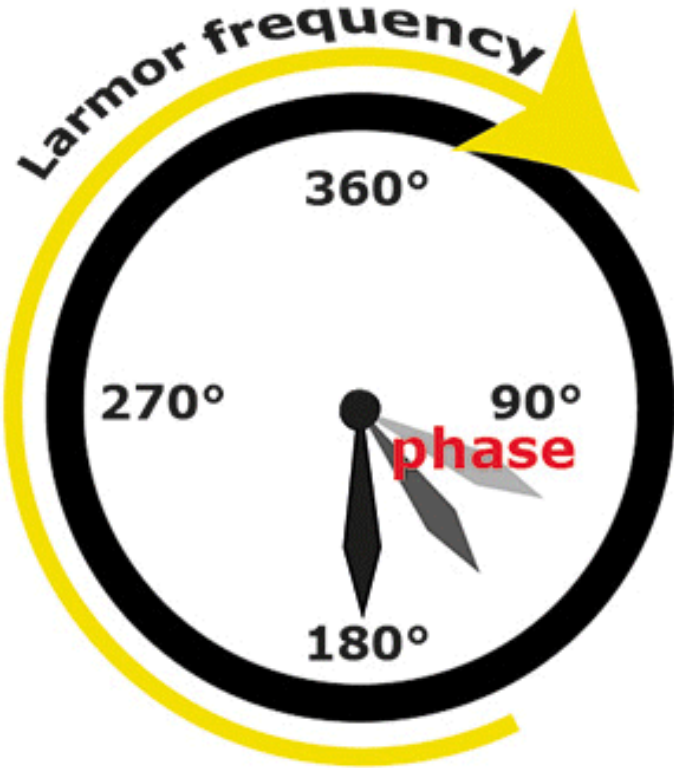

# MRI- Magnetic Resonance Imaging

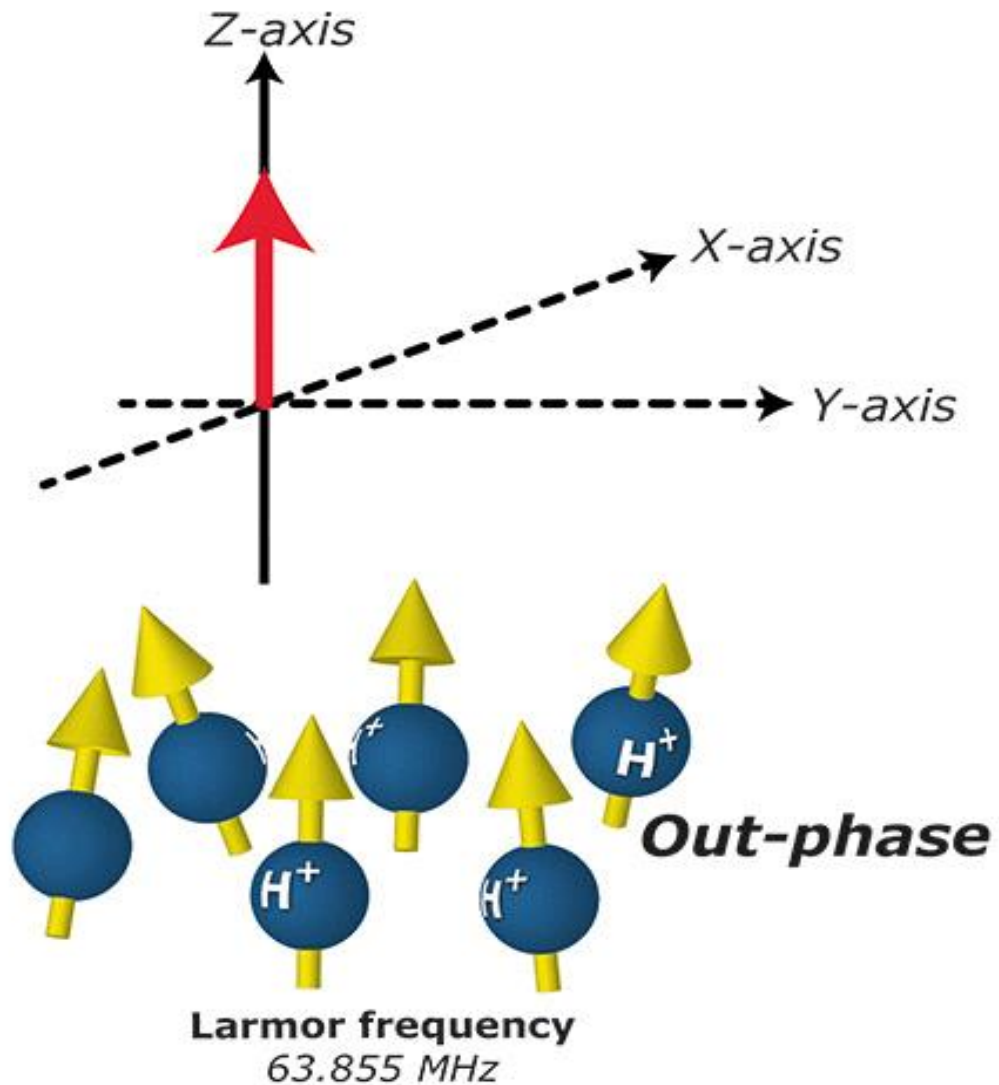
- Integral part of brain imaging
- Based on magnetic resonance of hydrogen protons in the body





Larmor frequency





By applying a RF pulse,

- Protons spin in phase
- Magnetization flips from Z axis to XY-axis

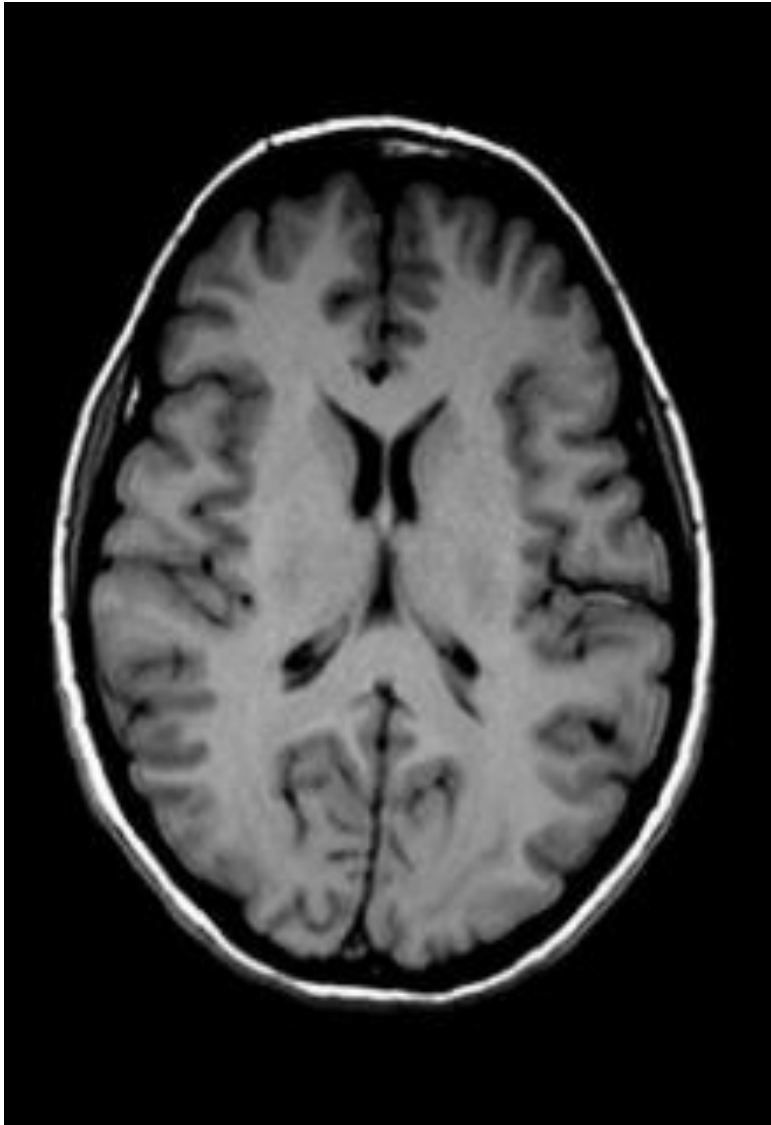
### EXCITATION

On removal of a RF pulse,

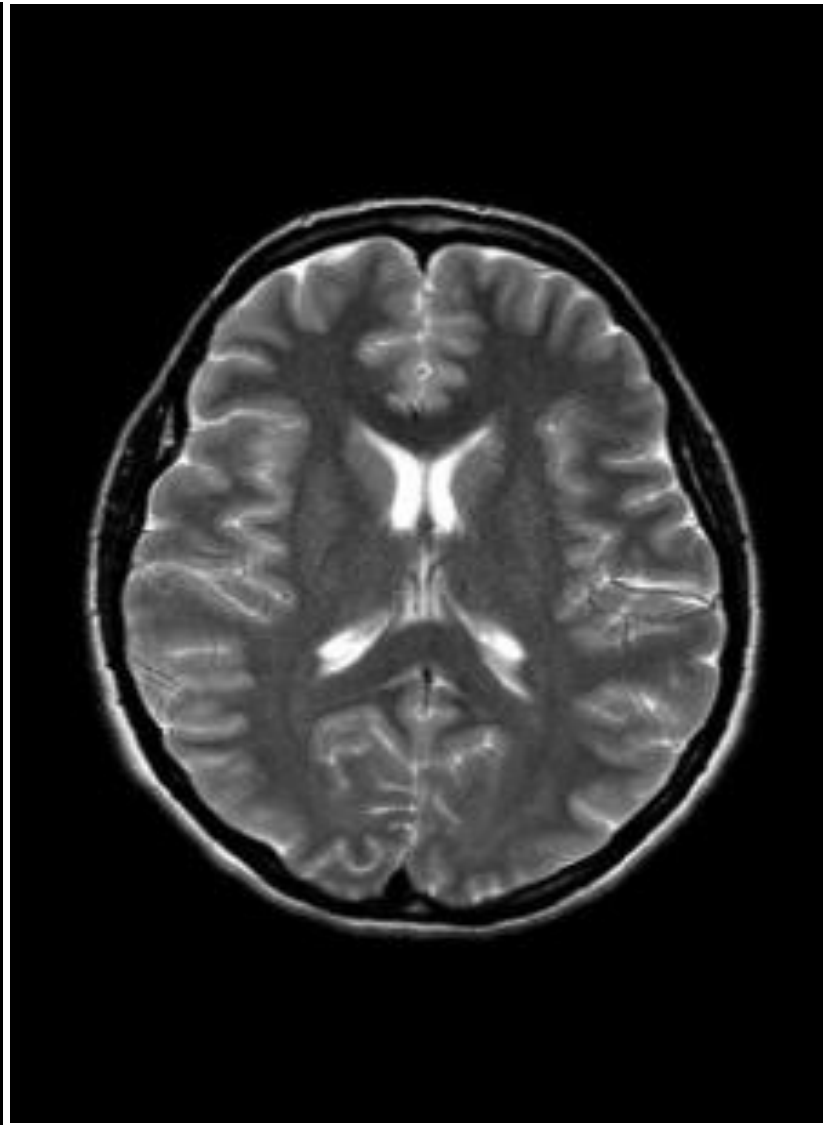
- T1 relaxation- flipping back to Z axis
- T2 relaxation- going back -out of phase (dephasing)

### RELAXATION

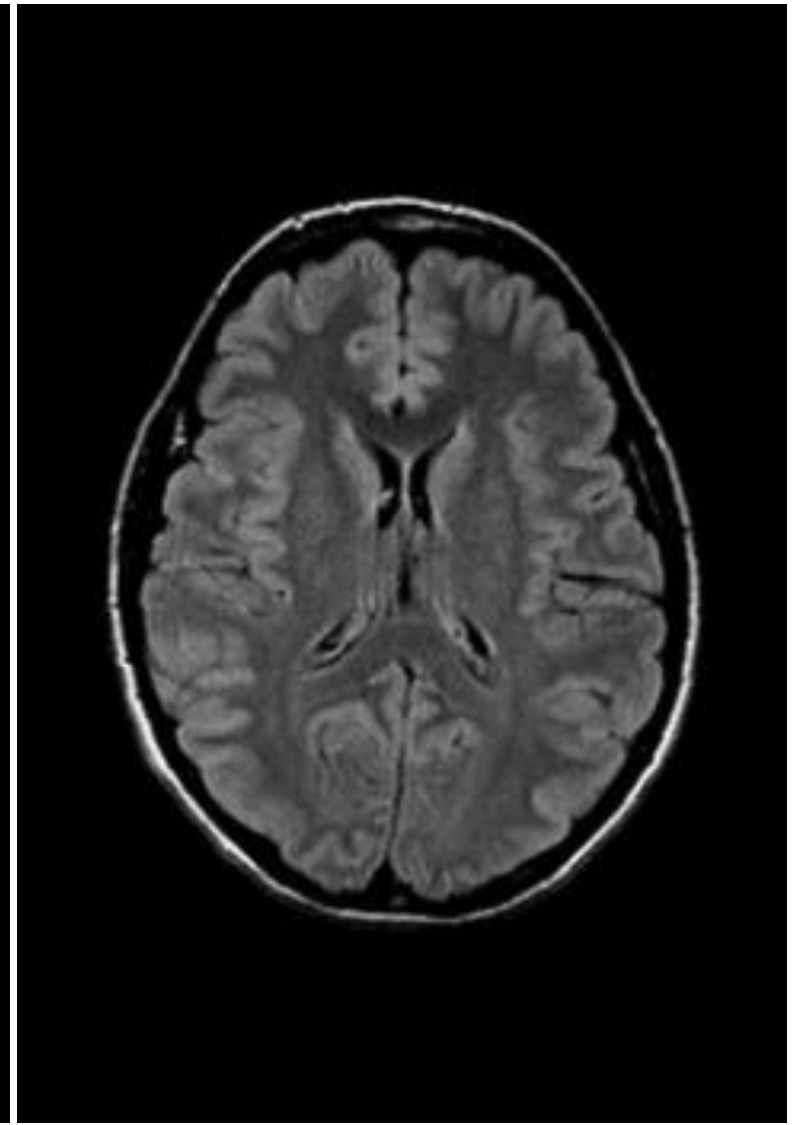
- Signals can only be received and processed when there is EXCITATION- that the net magnetization in XY plan and protons are spinning in phase
- By varying the sequence of RF pulses applied & collected, different types of images are created. **Repetition Time (TR)** is the amount of time between successive pulse sequences applied to the same slice. **Time to Echo (TE)** is the time between the delivery of the RF pulse and the receipt of the echo signal.
- Various sequences used in MRI- Commonly used T1, T2 and FLAIR



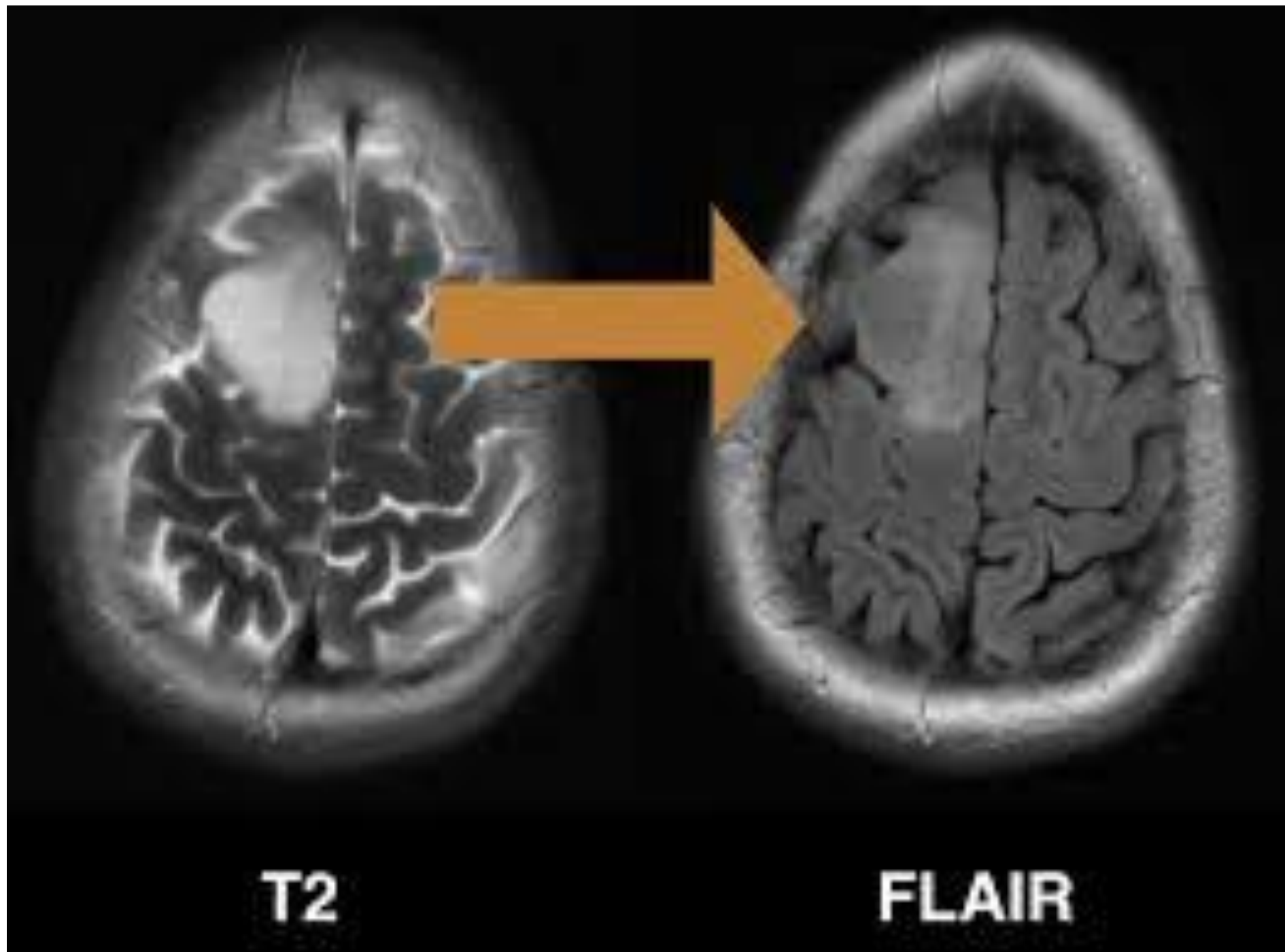
T1-weighted



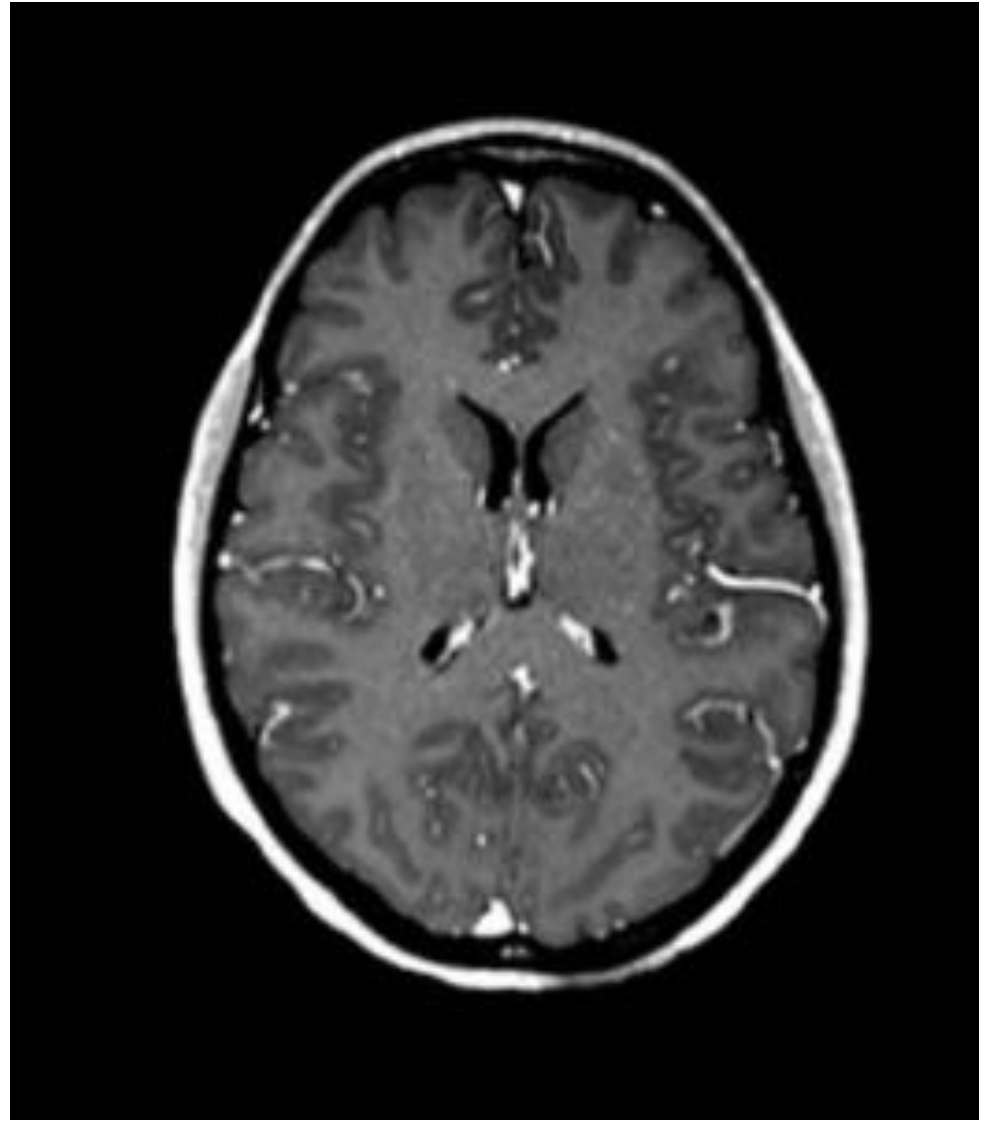
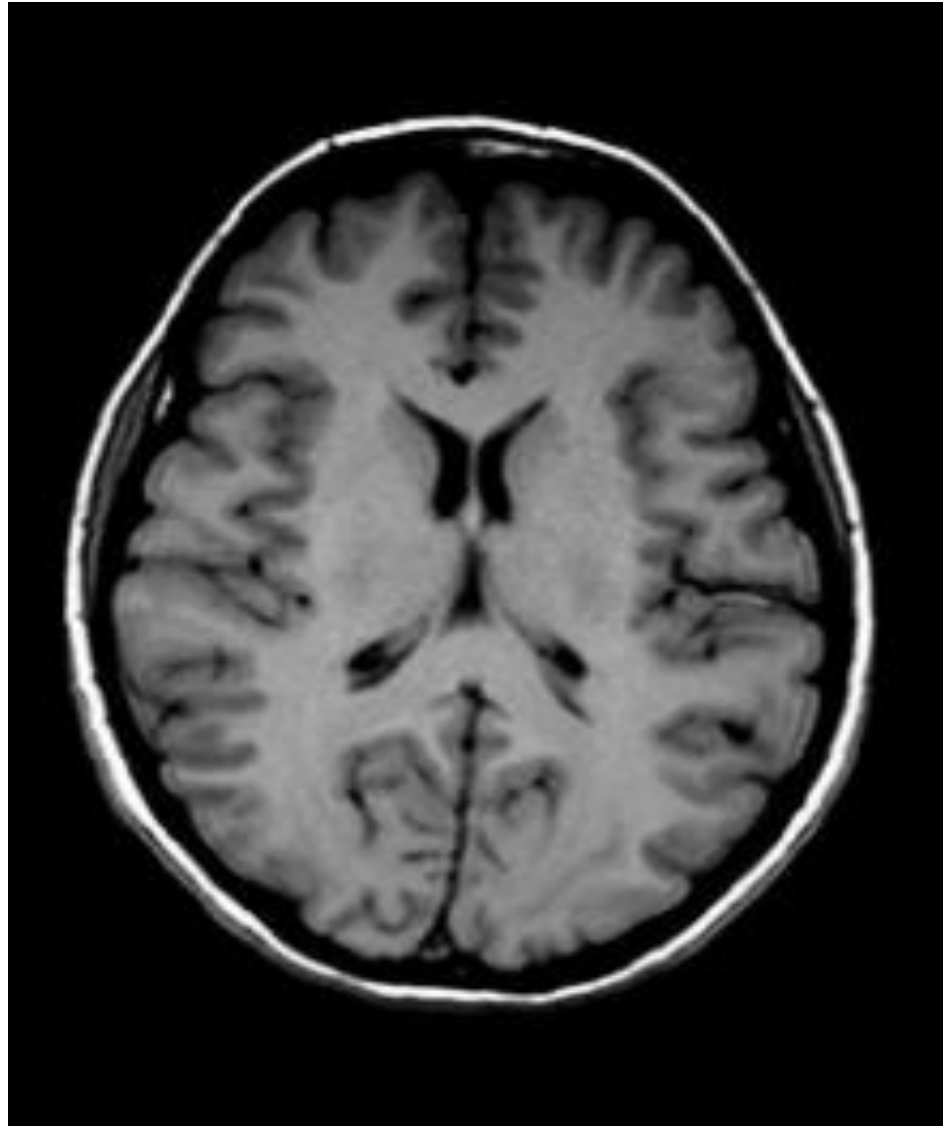
T2-weighted



FLAIR



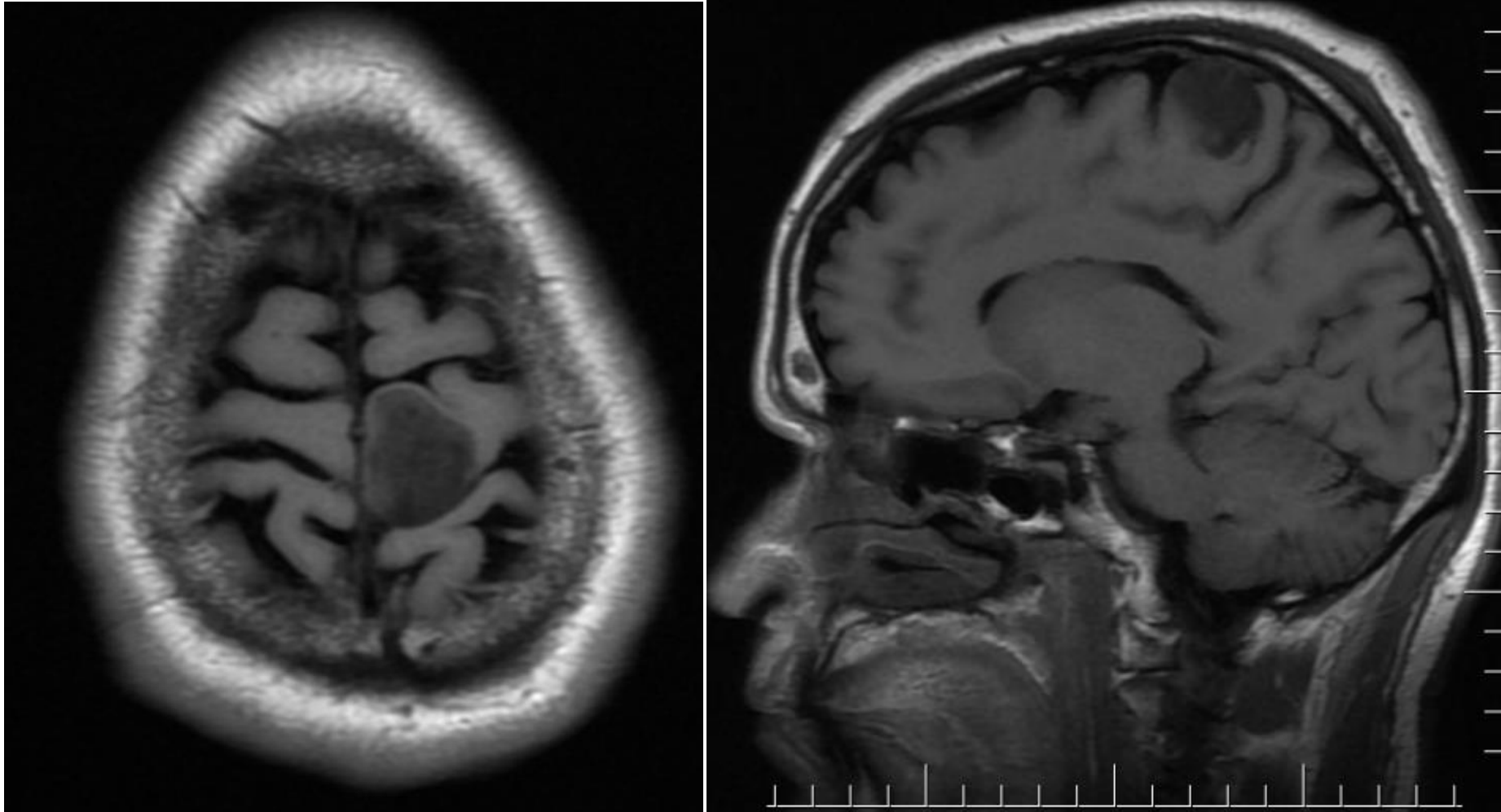




# Gliomas

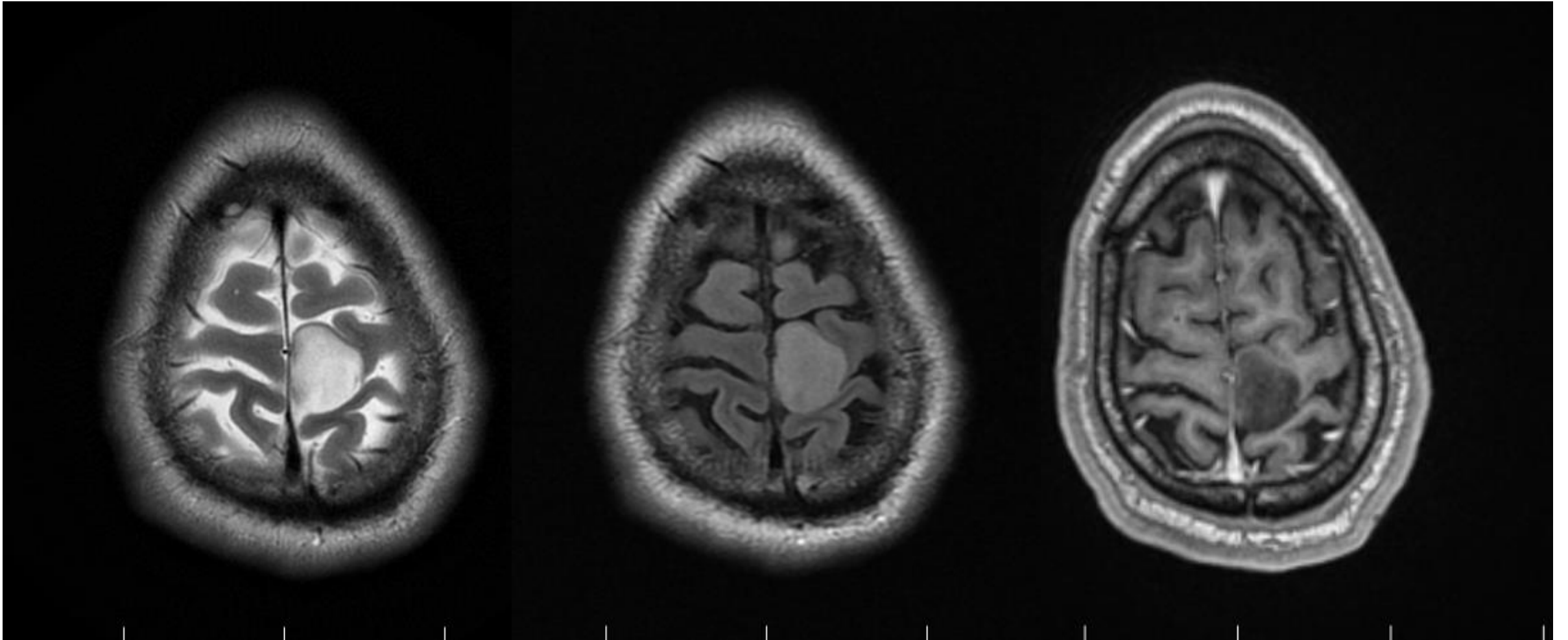
- Astrocytomas
- Oligodendrogliomas
- Ependymomas
  
- Grades I to IV

# Low grade gliomas- Grade 2 glioma



T1- weighted

- Isointense on T1



**T2-weighted**

- Hyperintense on T2

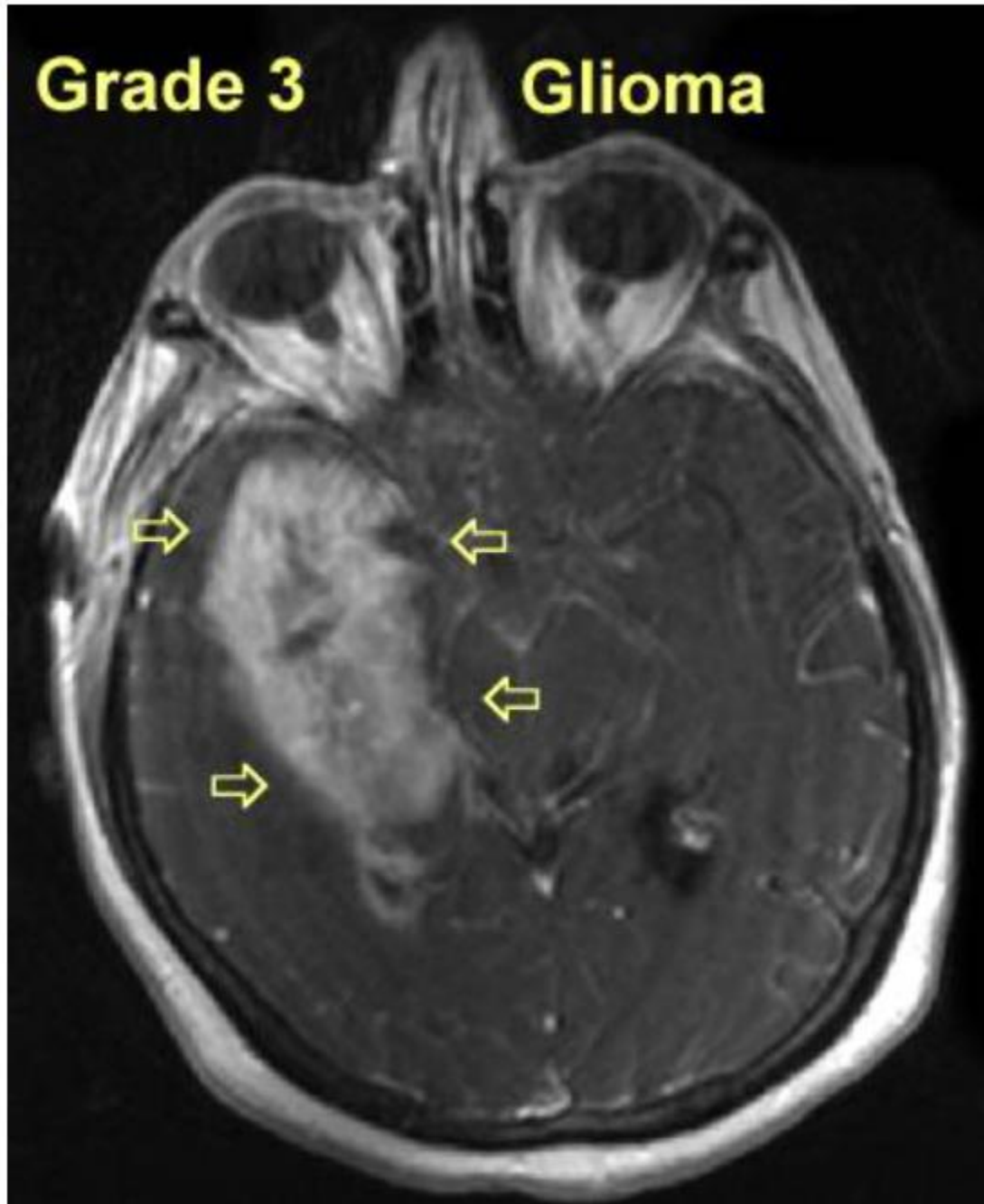
**FLAIR**

- Hyperintense on FLAIR

**T1-w with Gado**

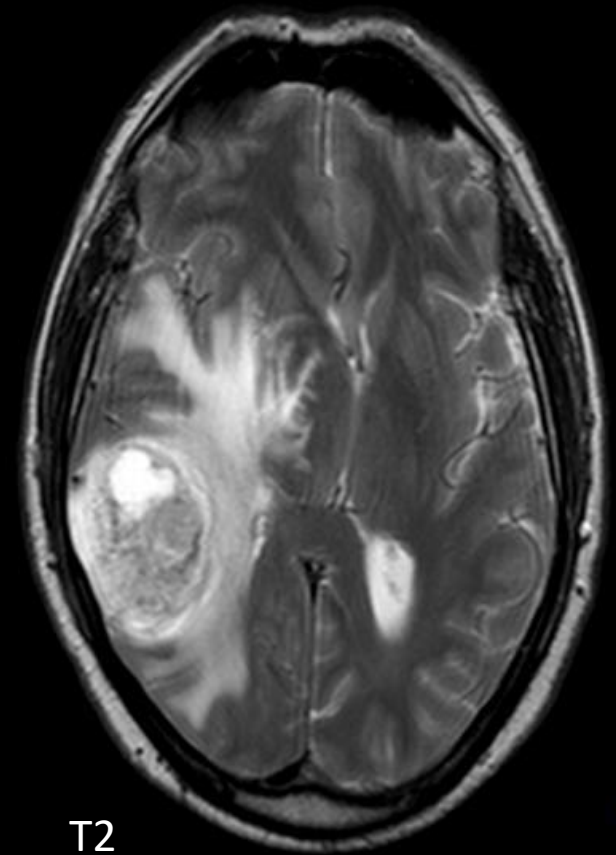
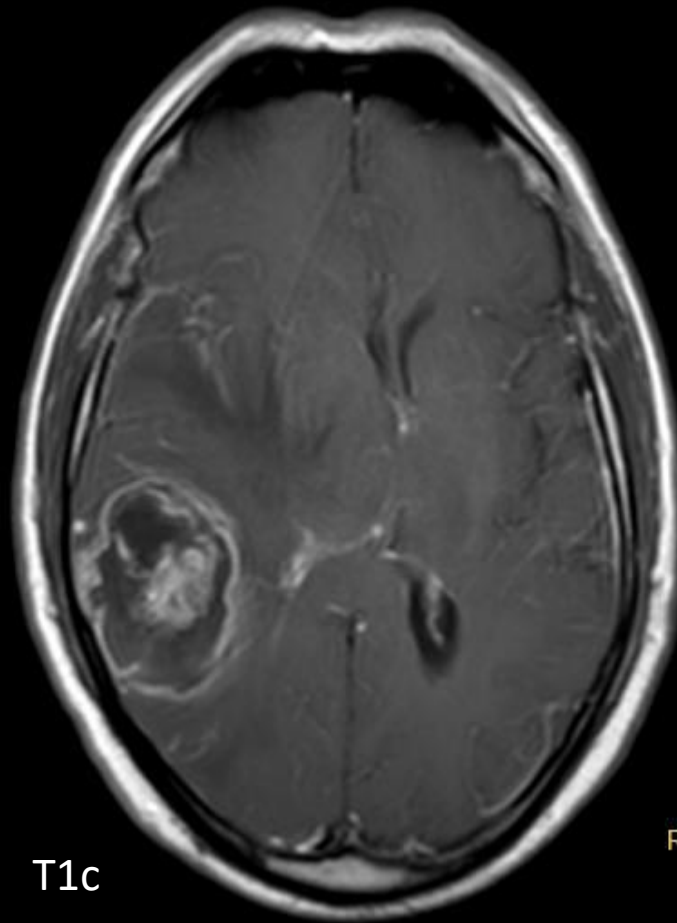
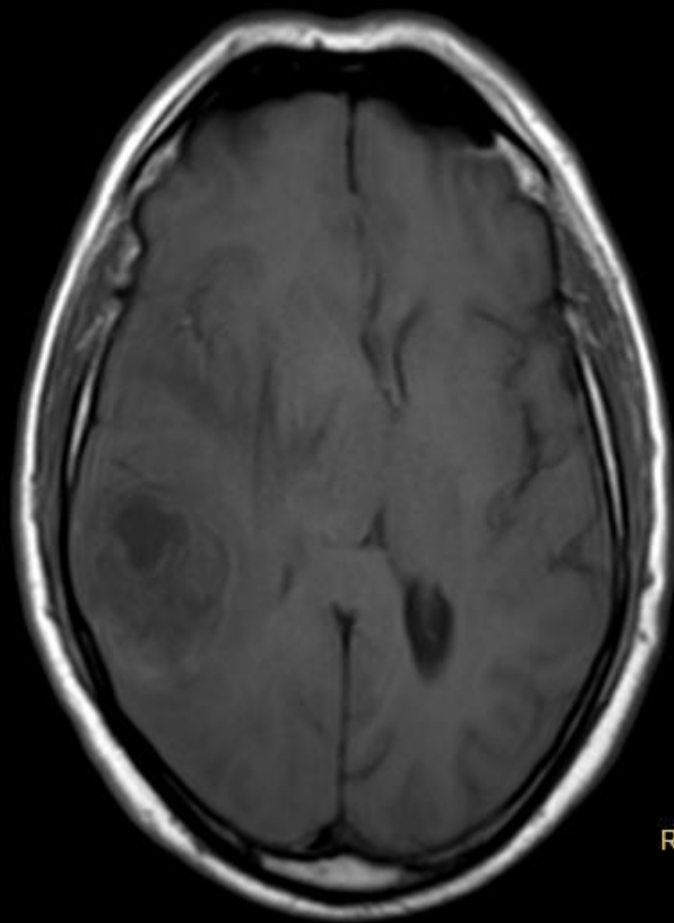
- Non Contrast enhancing

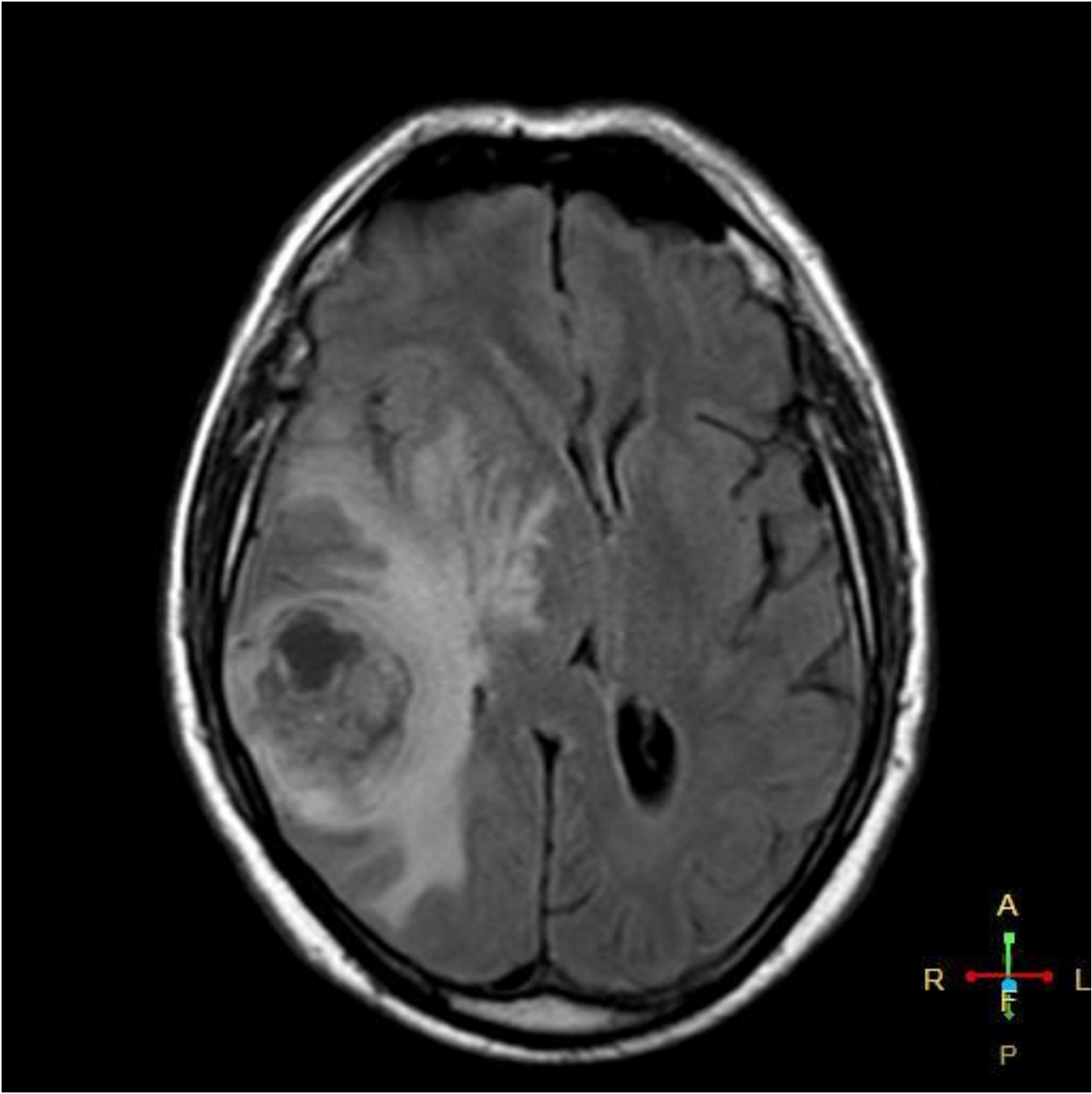




- More heterogeneous
- Contrast enhancing
- No necrosis! (differentiating from Grade 4)

# Glioblastoma multiforme



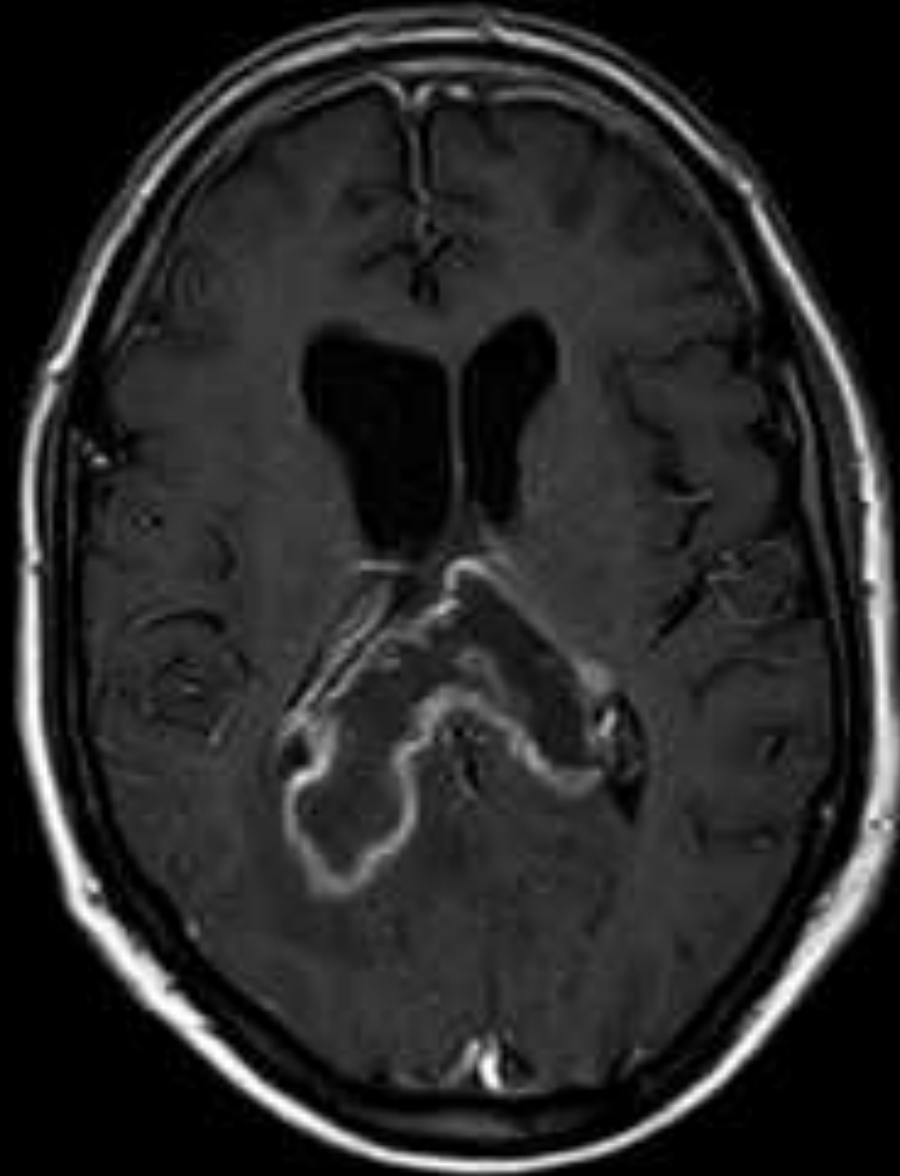


# MRI

- **T1**
  - hypo to isointense mass within white matter
  - central heterogeneous signal (necrosis, intratumoral hemorrhage)
- **T1 C+ (Gd)**
  - enhancement is variable but is almost always present
  - typically peripheral and irregular with nodular components
  - usually surrounds necrosis
- **T2/FLAIR**
  - hyperintense
  - surrounded by vasogenic edema
  - flow voids are occasionally seen



# BUTTERFLY GLIOMA



# Additional tests

- MR spectroscopy
- Diffusion weighted imaging
- Cerebral perfusion studies

# MR spectroscopy

- Analytic chemistry methods that allows tissue to be interrogated for the presence and concentration of various metabolites.
- It provides chemical and thereby physiological information

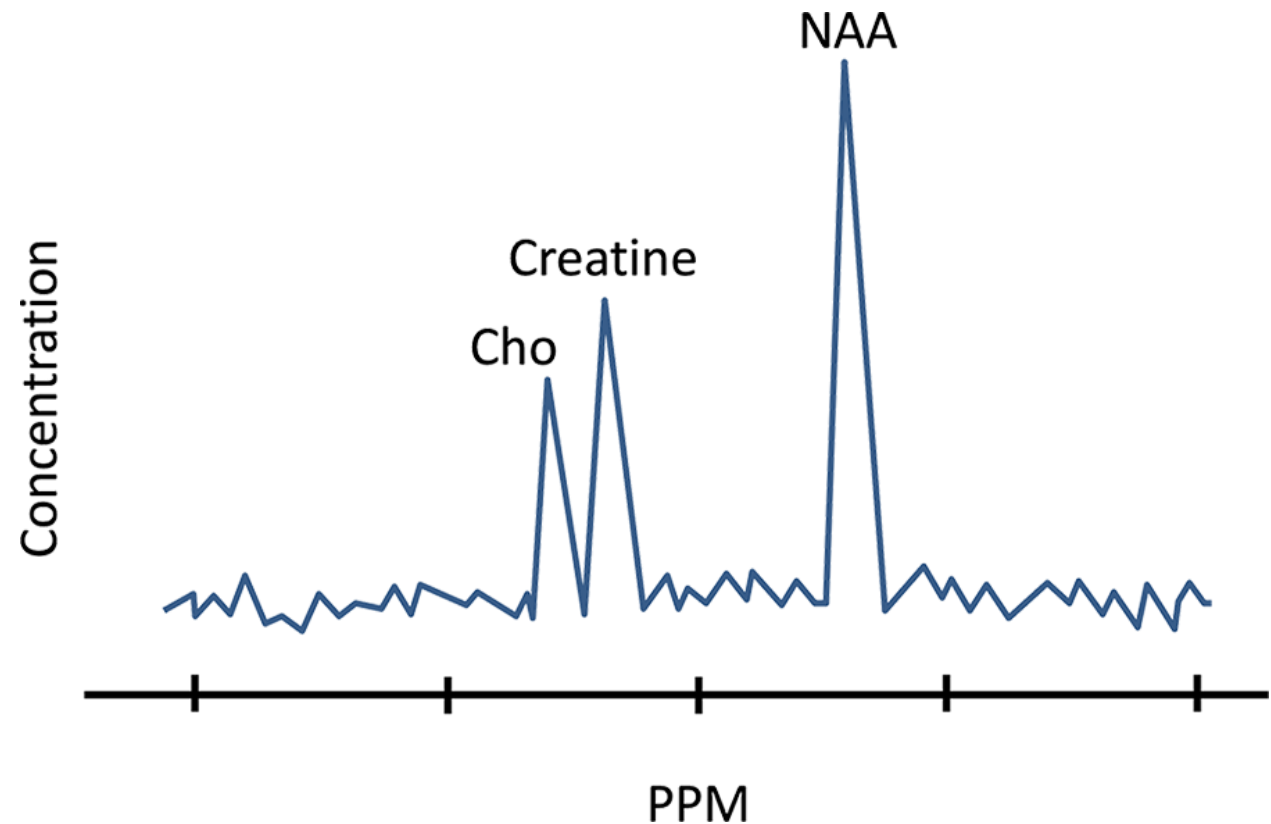
## Principle

Distribution of electrons within an atom cause nuclei in different molecules to experience a slightly different magnetic field. This results in slightly different resonant frequencies, which in turn return a slightly different signal.

Number of metabolites can be measured.

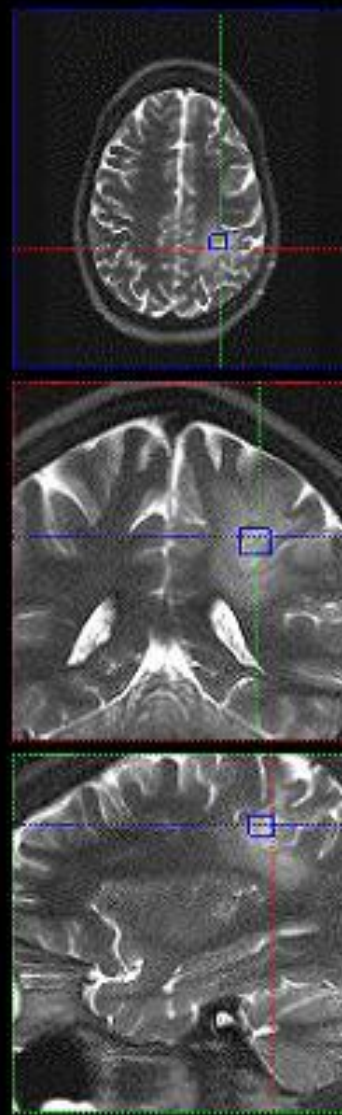
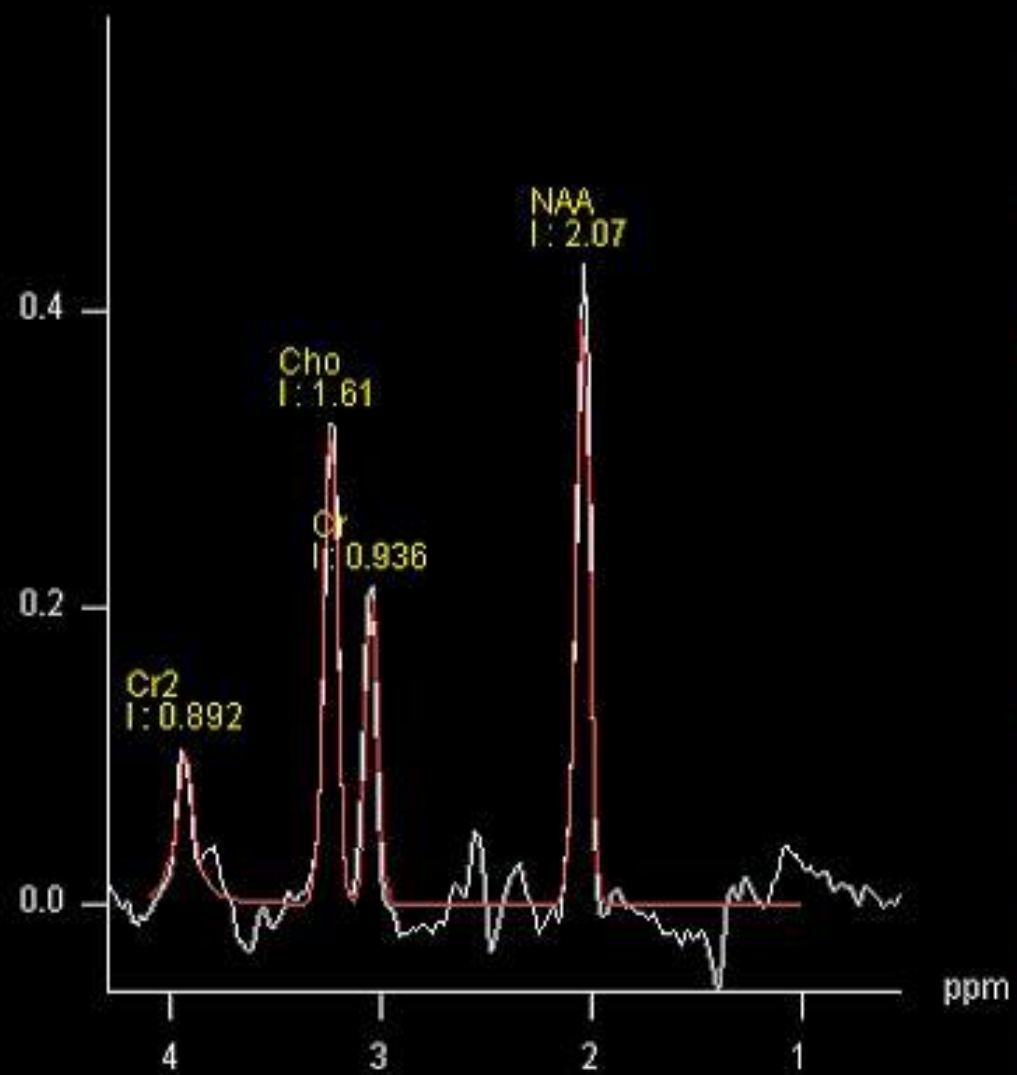
- Aminoacids
- Lipids
- Lactate
- Alanine
- N-acetyl aspartate
- Choline
- Creatine
- Myoinositol

The frequency of these metabolites is measured in units called parts per million (ppm) and plotted on a graph as peaks of varying height. By measuring each metabolite's ppm and comparing it to normal brain tissue, the neuroradiologist can determine the type of tissue present.





I : Integral



- **NAA-**

2 ppm, marker of neuronal and axonal viability and density

Malignant neoplasms destroy neurons , decrease NAA, not in extra- axial lesions

- **Creatine-**

3.02 ppm, marker of energetic systems and intra cellular metabolism

In brain tumors- decreases, increased slightly in gliosis

- **Choline**

- 3.22 ppm, marker of cellular membrane turnover( phospholipid synthesis and degradation)- marker of cellular proliferation

In active tumor growth- choline increases, reflects cellularity; non specific

- **Lactate** – 1.33ppm, product of anaerobic metabolism

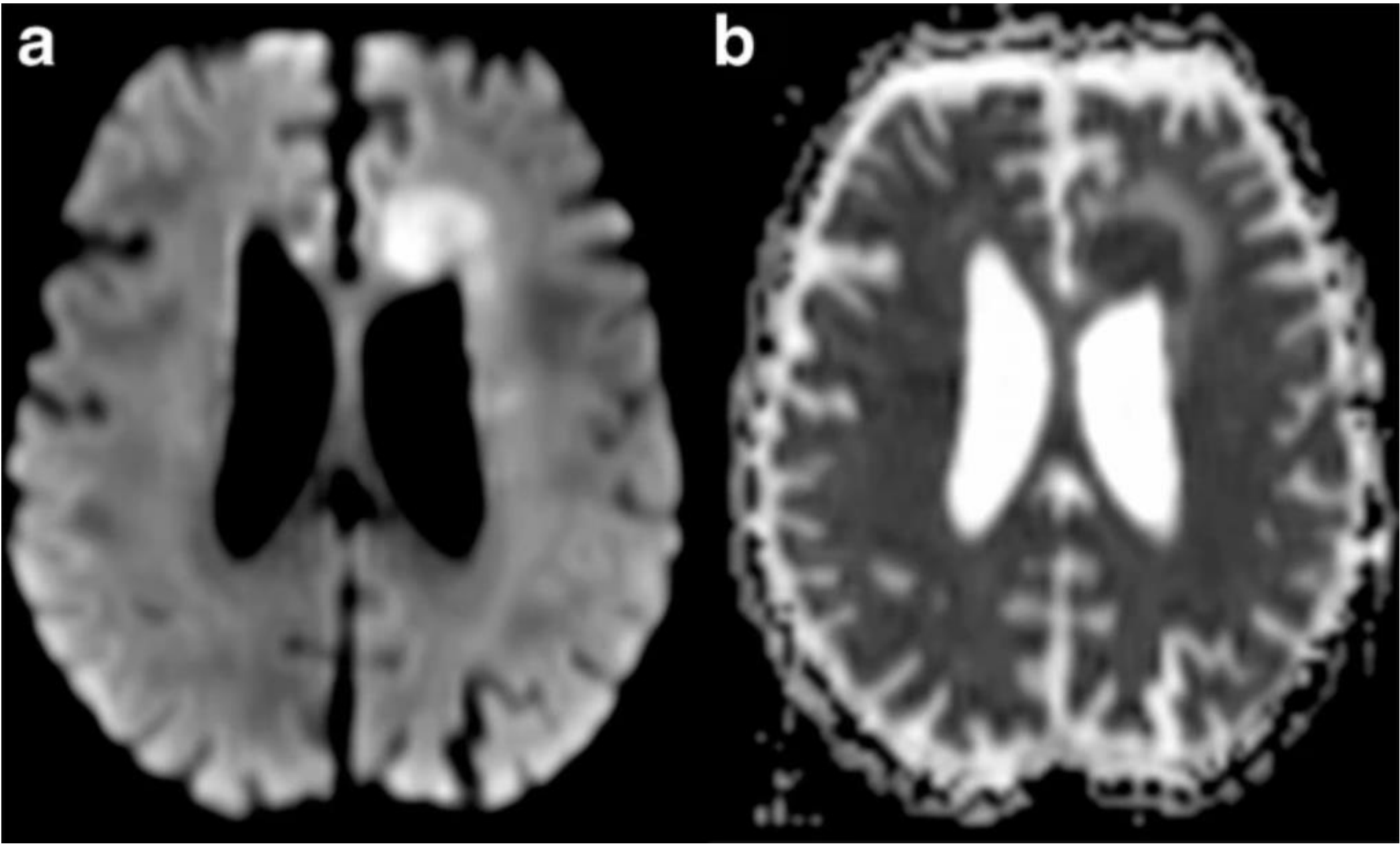
- **Lipid**- 0.9 to 1.2 ppm

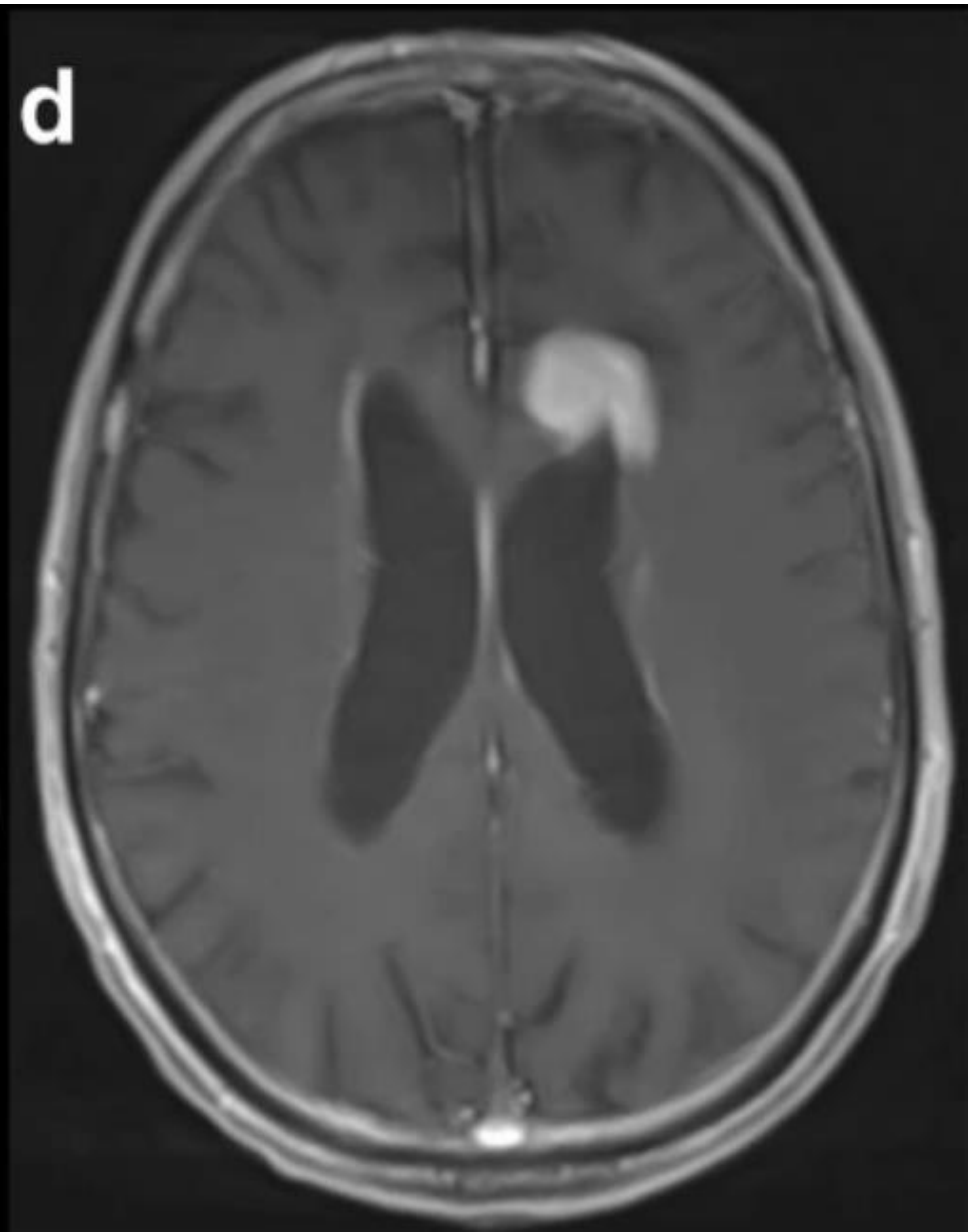
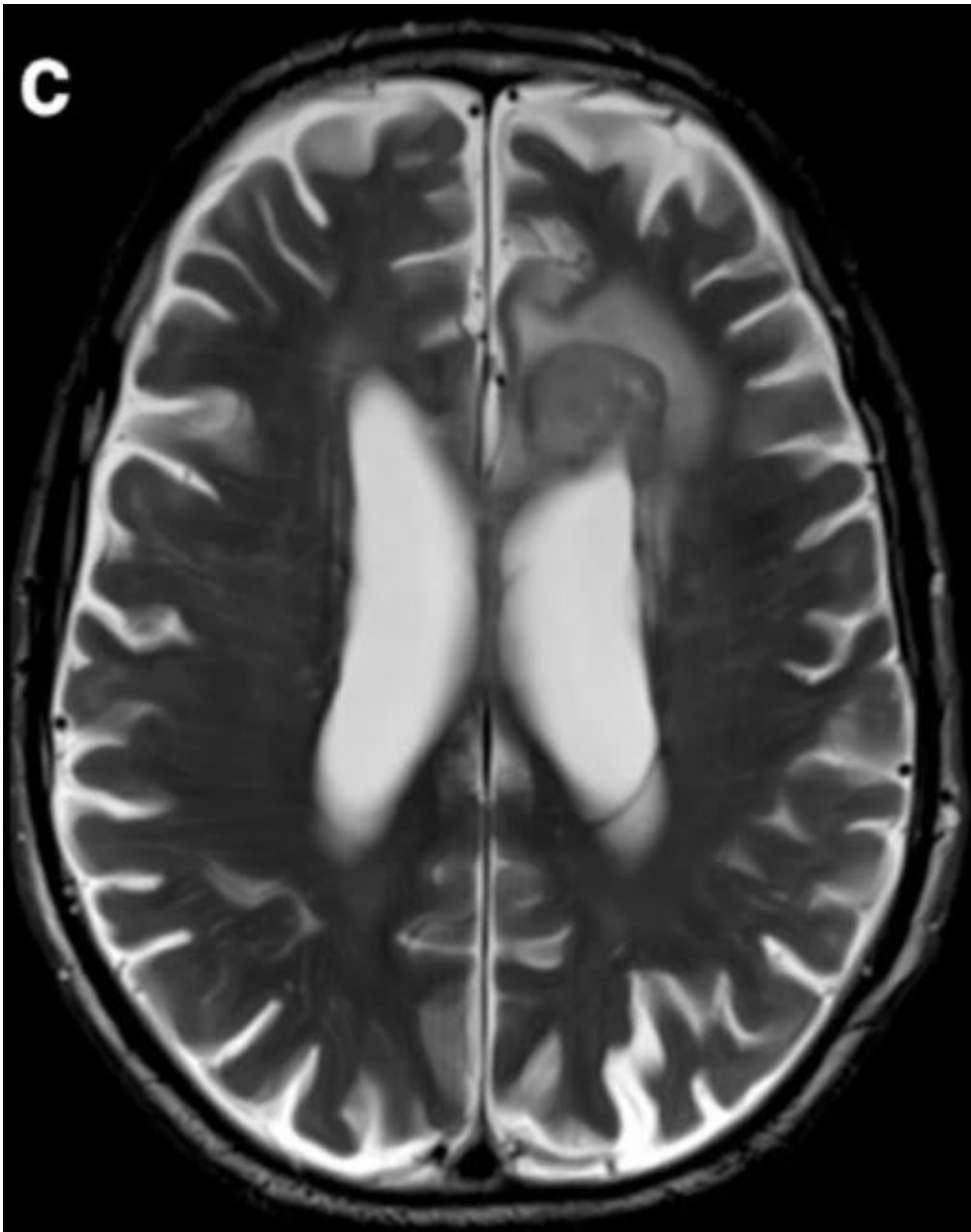


**Both are  
released in cell  
destruction and  
necrosis**

# Diffusion weighted imaging (DWI)

- It is based upon measuring the random Brownian motion of water molecules within a voxel of tissue.
- The extent of tissue cellularity and the presence of intact cell membrane help determine the impedance of water molecule diffusion
- This impedance of water molecules diffusion can be quantitatively assessed using the apparent diffusion coefficient (ADC) value. ADC values are calculated using a software ( $\text{mm}^2/\text{s}$ )





# Cerebral perfusion and permeability studies

Perfusion MRI provides information about

- tissue vascularization
- in vivo tumor angiogenesis
- microcirculation.

Perfusion MRI offers information about tissue blood volume, blood flow, and oxygenation of tissues.




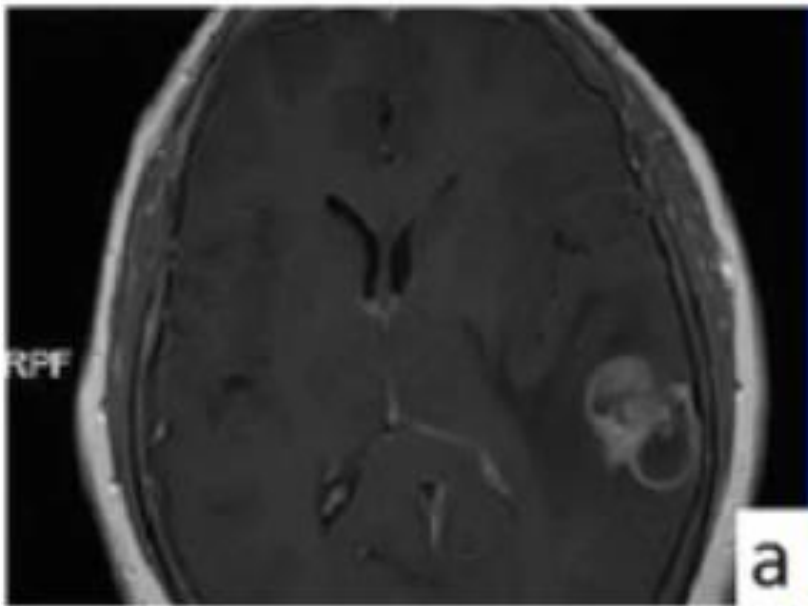
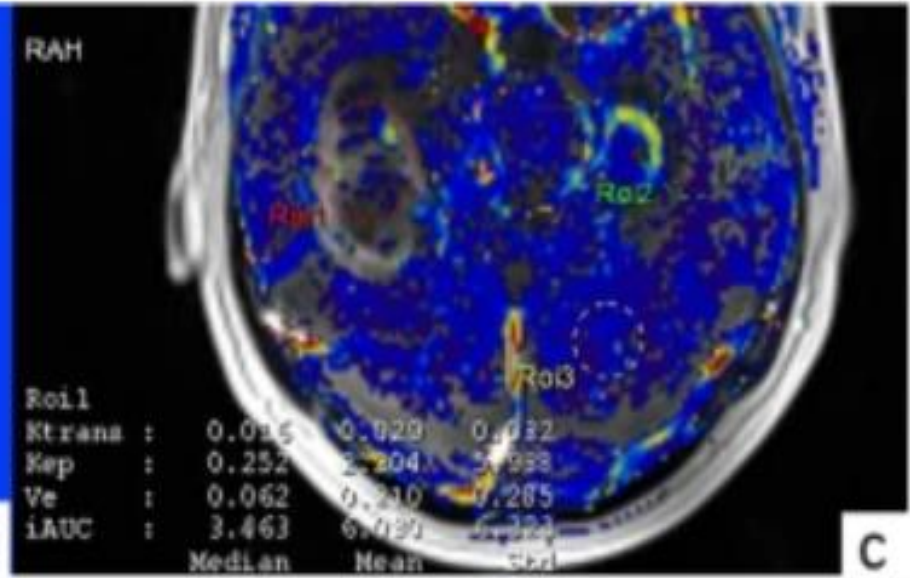

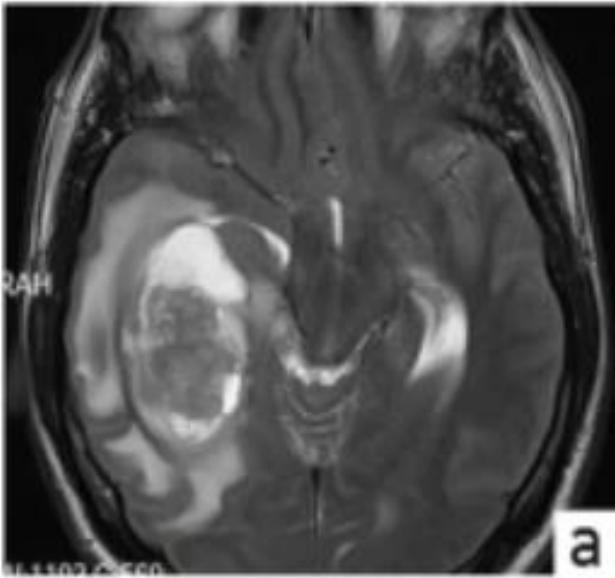
The signal changes in arteries/veins, which occur with the passage of paramagnetic contrast agent are used to create

- relative cerebral blood volume (rCBV)
- mean transit time (MTT)
- cerebral blood flow (rCBF).

Permeability is used to estimate vascular permeability by measuring contrast medium leakage through the BBB. Its main parameters:

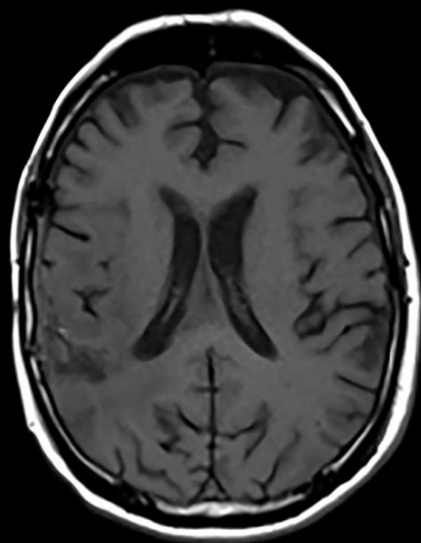
- Vascular transfer constant ( $K_{trans}$ )- describes the permeability of blood vessels to contrast medium
- Extravascular and extracellular volume fraction ( $V_e$ ) is the interstitial volume in which extracellular contrast agents may accumulate if they cross the BBB

- High grade tumours have more neoangiogenesis, vascular proliferation and increased permeability due to disruption of BBB
- This correlates with increase in rCBV, rCBF, MTT, kTrans and Ve.



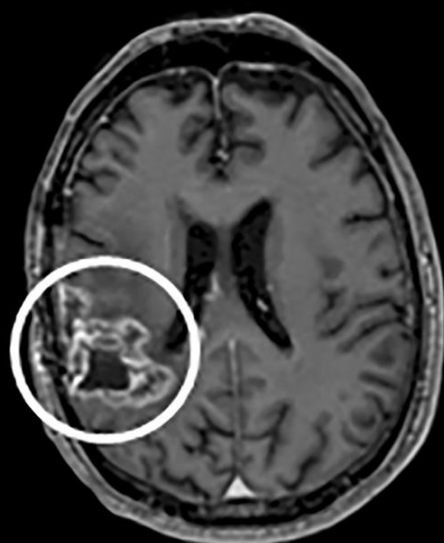
- Differentiating recurrence from pseudoprogression
- Differentiating progression from pseudoresponse after angiogenic therapy

**(a)**



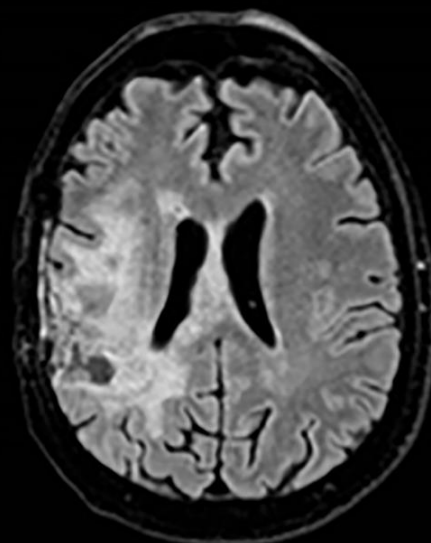
Pre-contrast T1

**(b)**



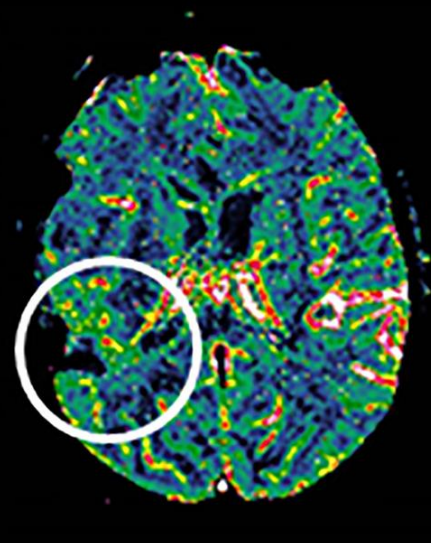
Post-contrast T1

**(c)**



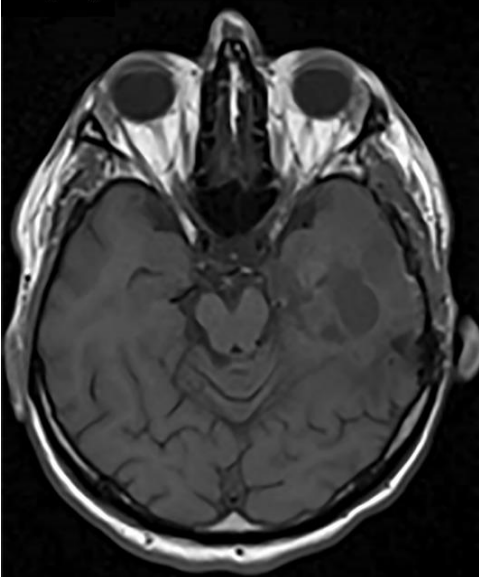
FLAIR

**(d)**

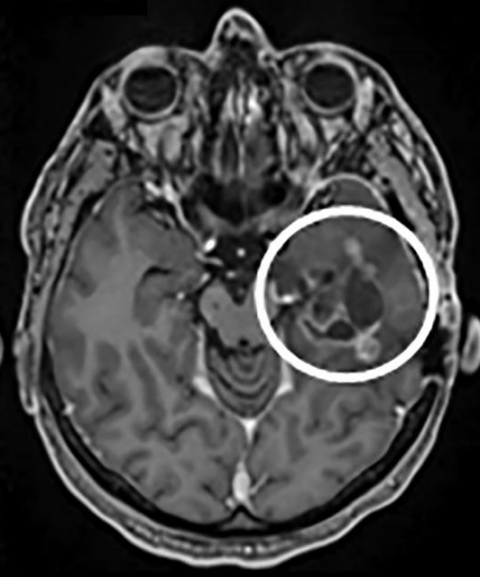


DSC-rCBV

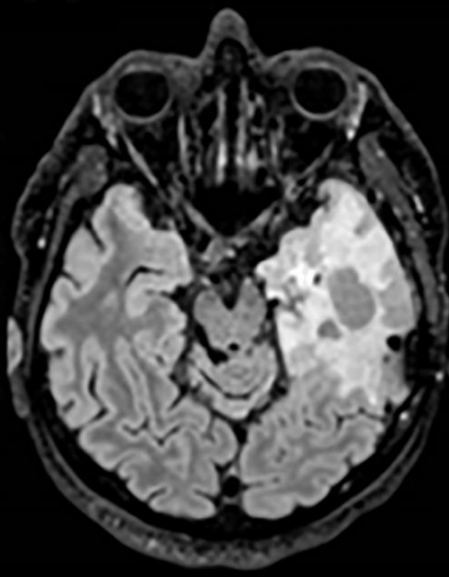
**(a)**



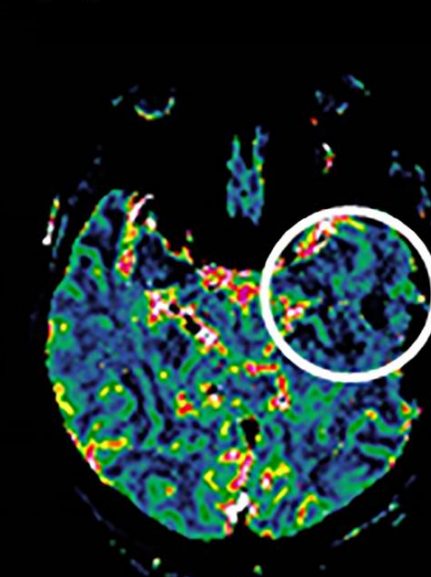
**(b)**



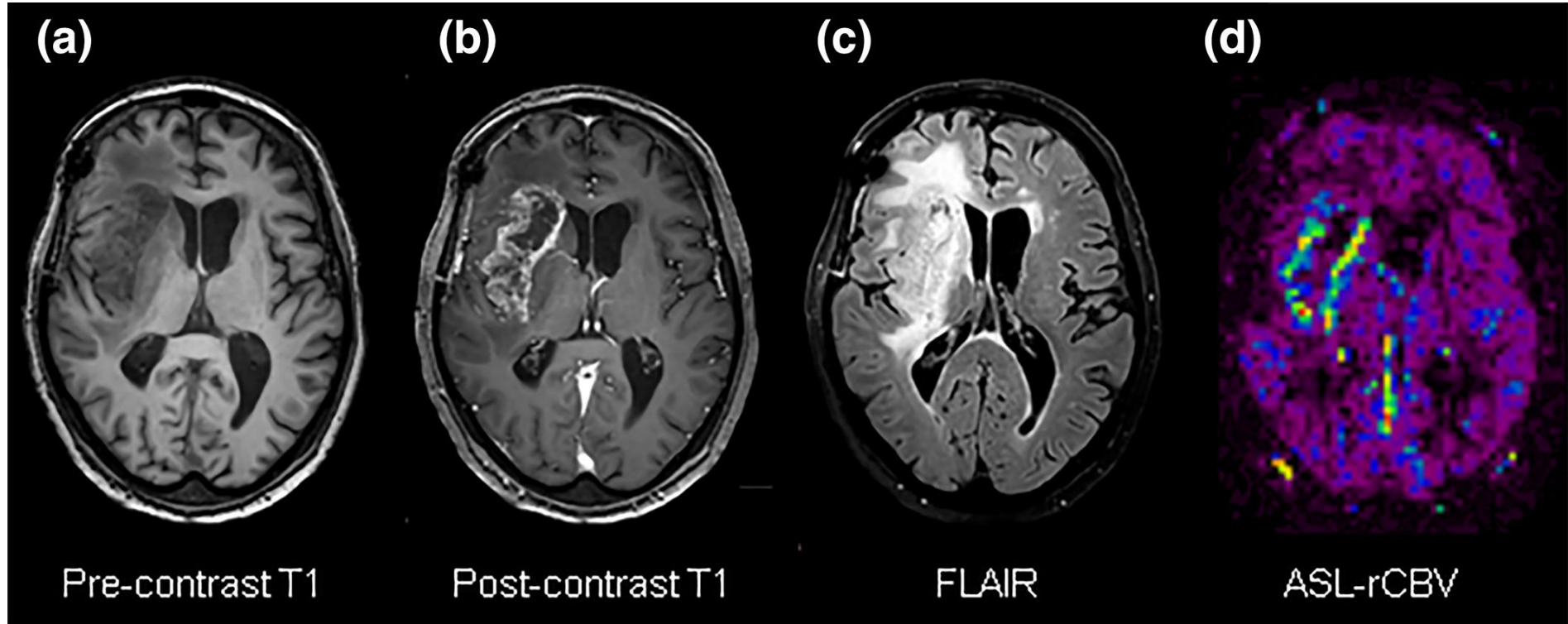
**(c)**



**(d)**









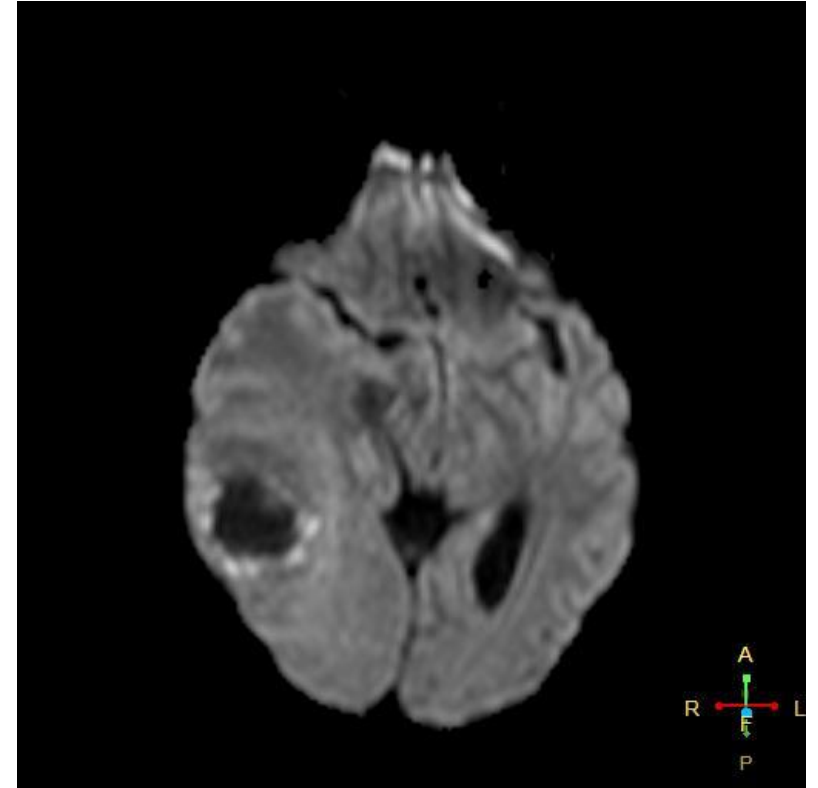
# These techniques in gliomas

## DWI imaging

- Peripheral enhancing component- elevated signal
- Surrounding vasogenic edema- facilitated diffusion
- ADC values correlate with grade
- Necrotic component- facilitated diffusion

## MR perfusion

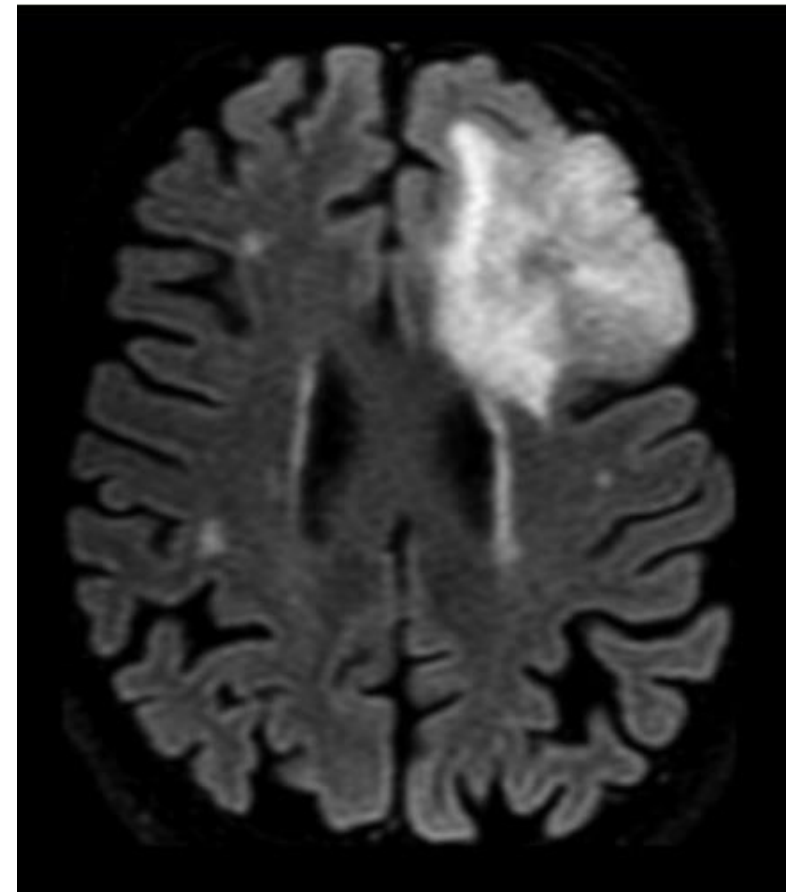
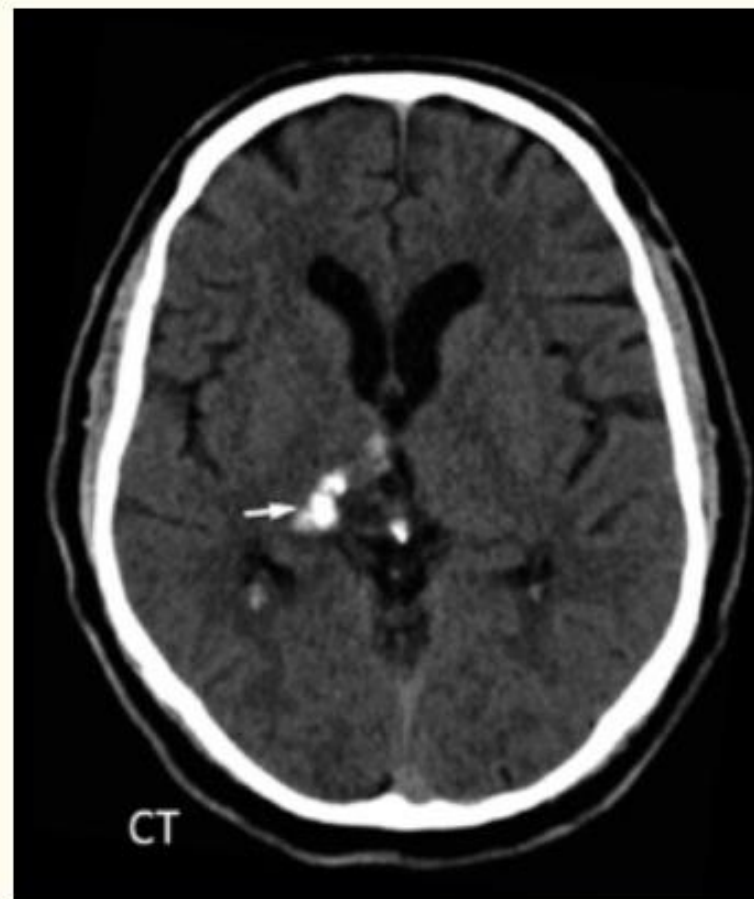## MR spectroscopy

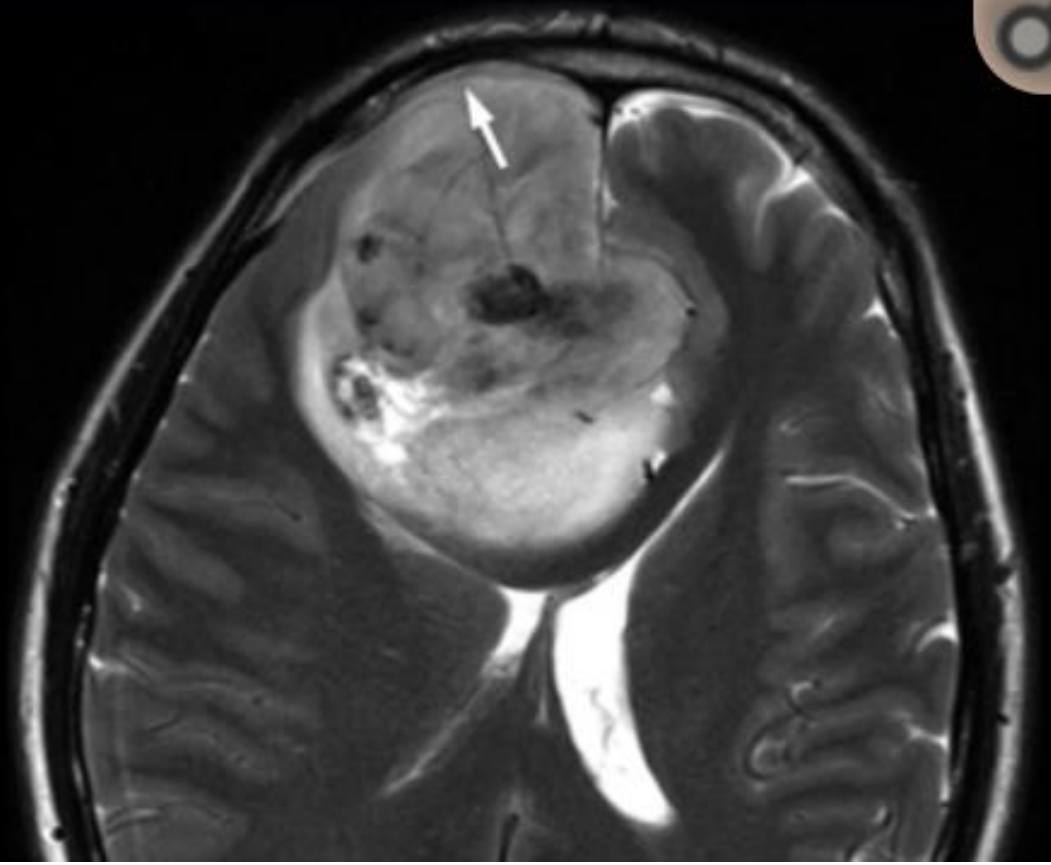
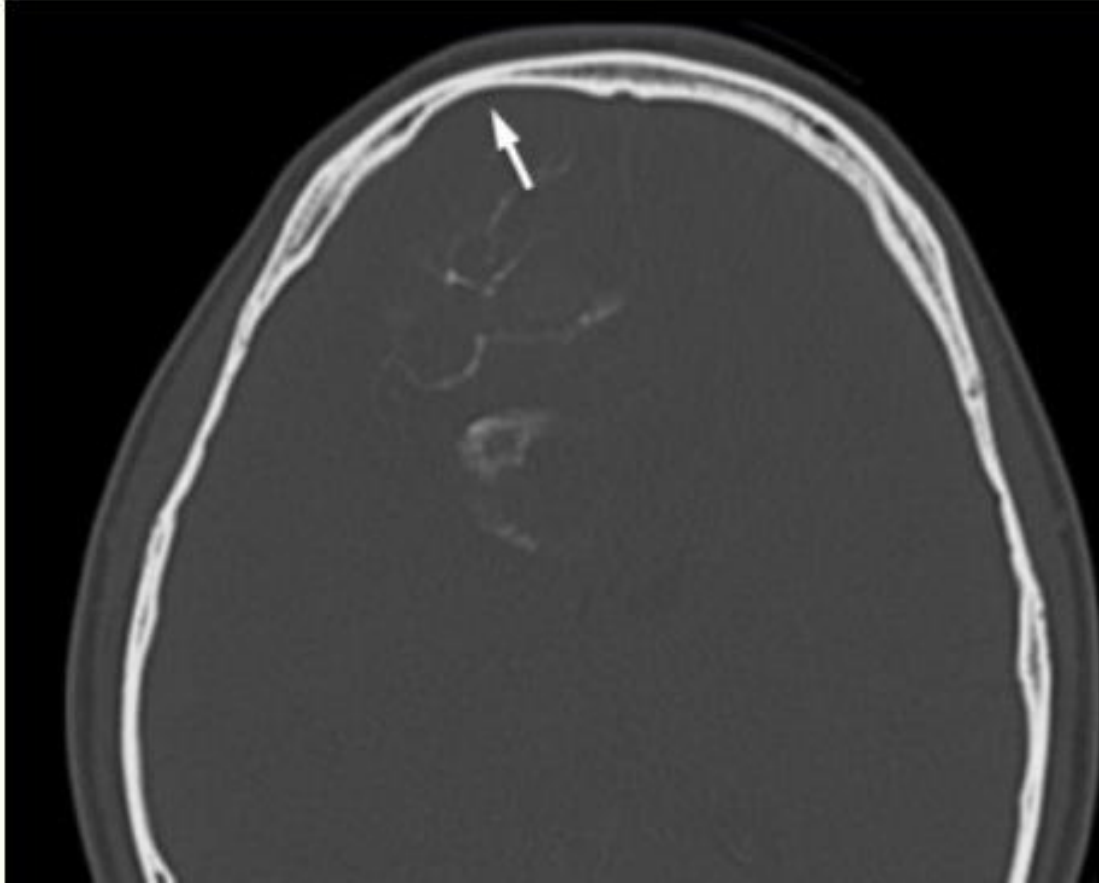


# Oligodendrogliomas vs astrocytomas

Oligodendrogliomas-

- Have cortical preference
- Calcifications



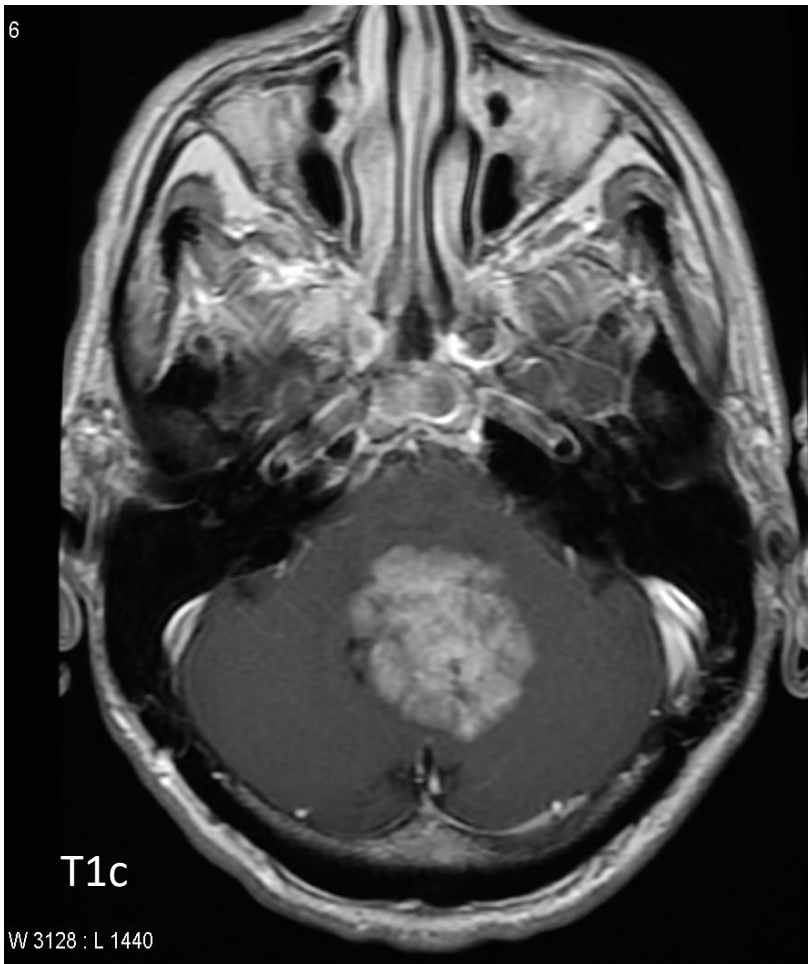


# Ependymoma

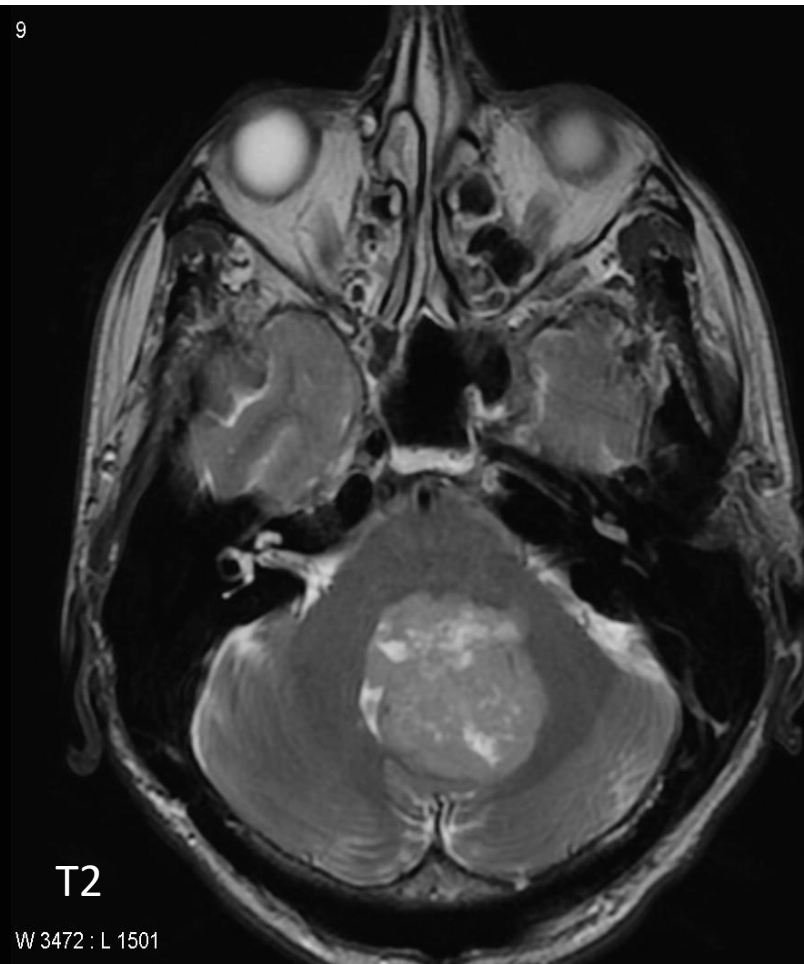
- Infra-tentorial- 60%
- Supra-tentorial- 30%
- Spinal canal- 10%

Posterior fossa ependymomas are apt to extend through the foramina of Luschka and Magendie, hence the term "plastic ependymoma". This is a characteristic feature and can be seen on both CT and MRI.

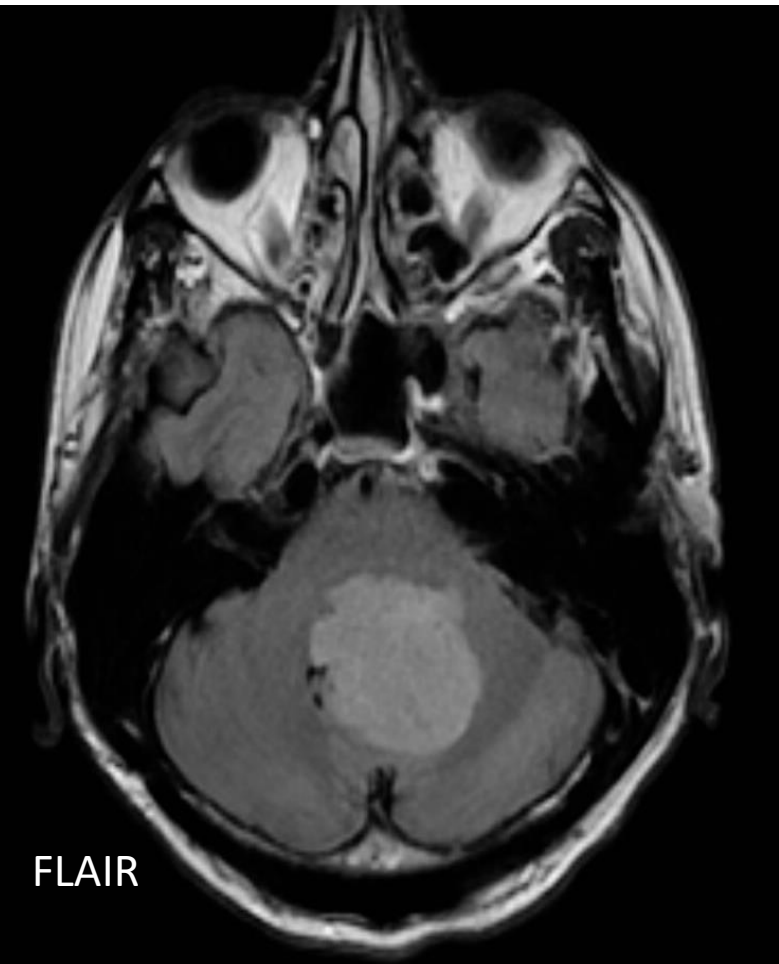
Ependymomas are typically heterogeneous masses with areas of necrosis, calcification, cystic change and hemorrhage frequently seen



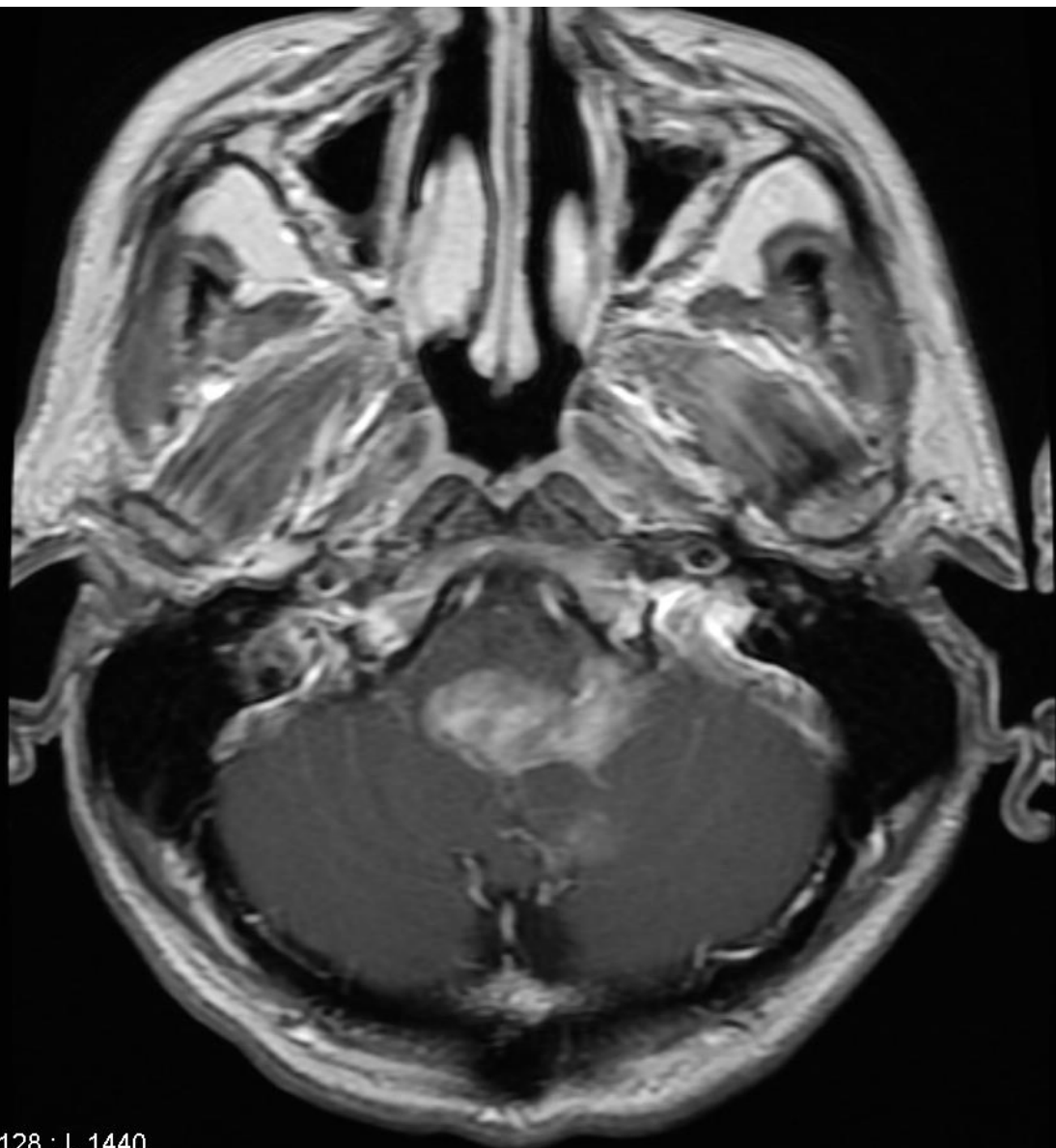
Heterogeneous enhancement



Hyperintense

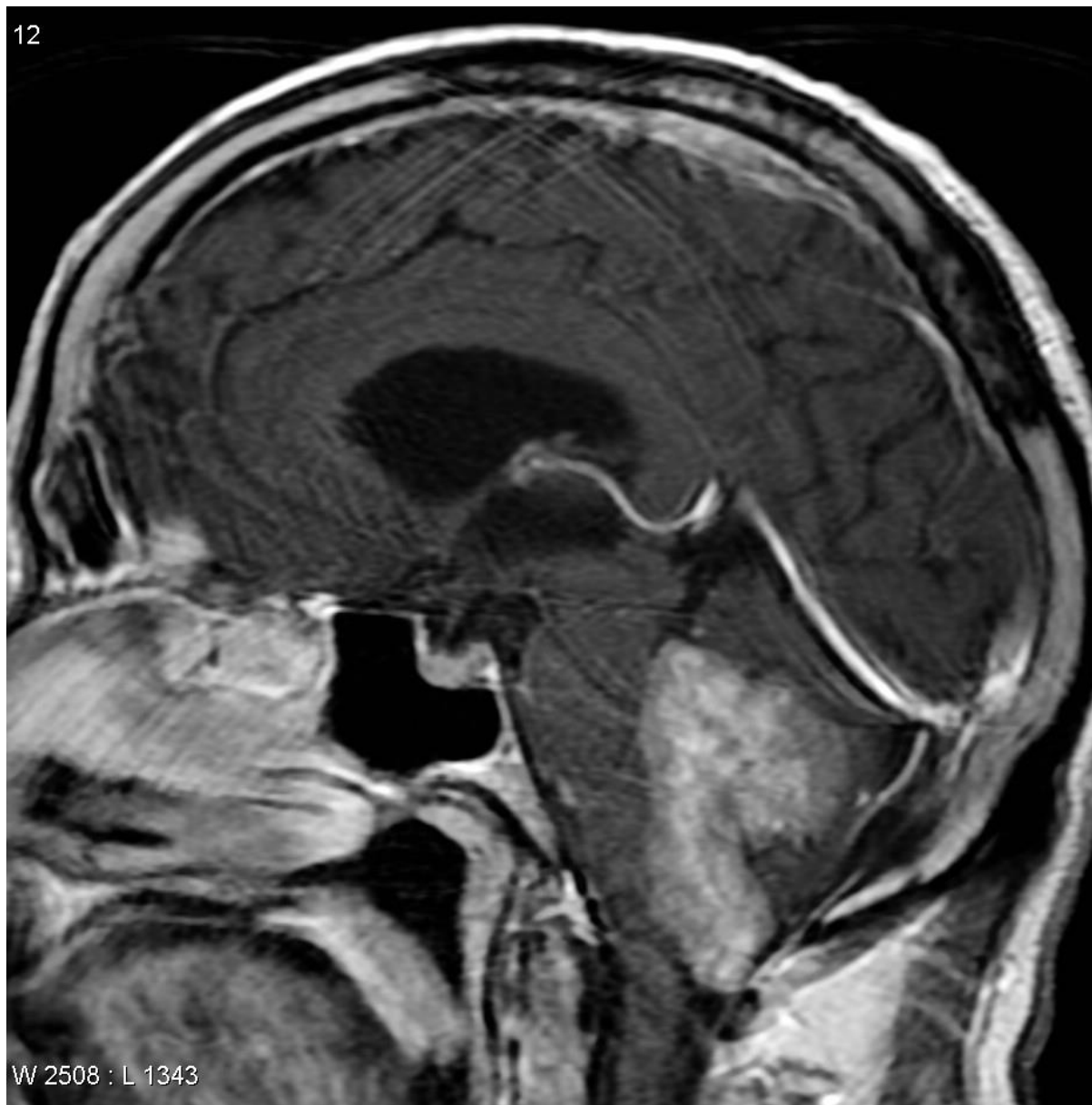

4



W 3128 : L 1440

12



W 2508 : L 1343



## DWI/ADC

- restricted diffusion in solid parts (esp in anaplastic tumour)
- careful in interpretation in presence of calcification/hemorrhage

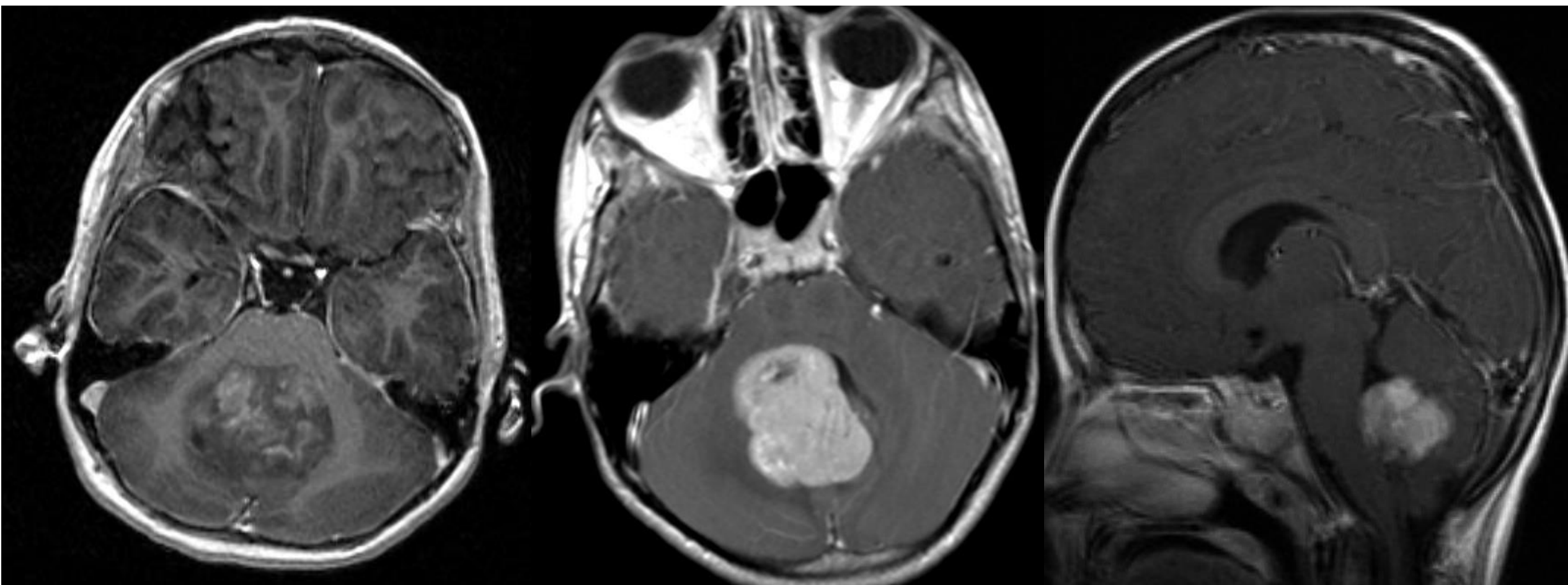
## MRS

- choline peak as per cellularity
- NAA peak reduction
- elevated Choline/Cr ratio
- lipid/lactate increase in degeneration

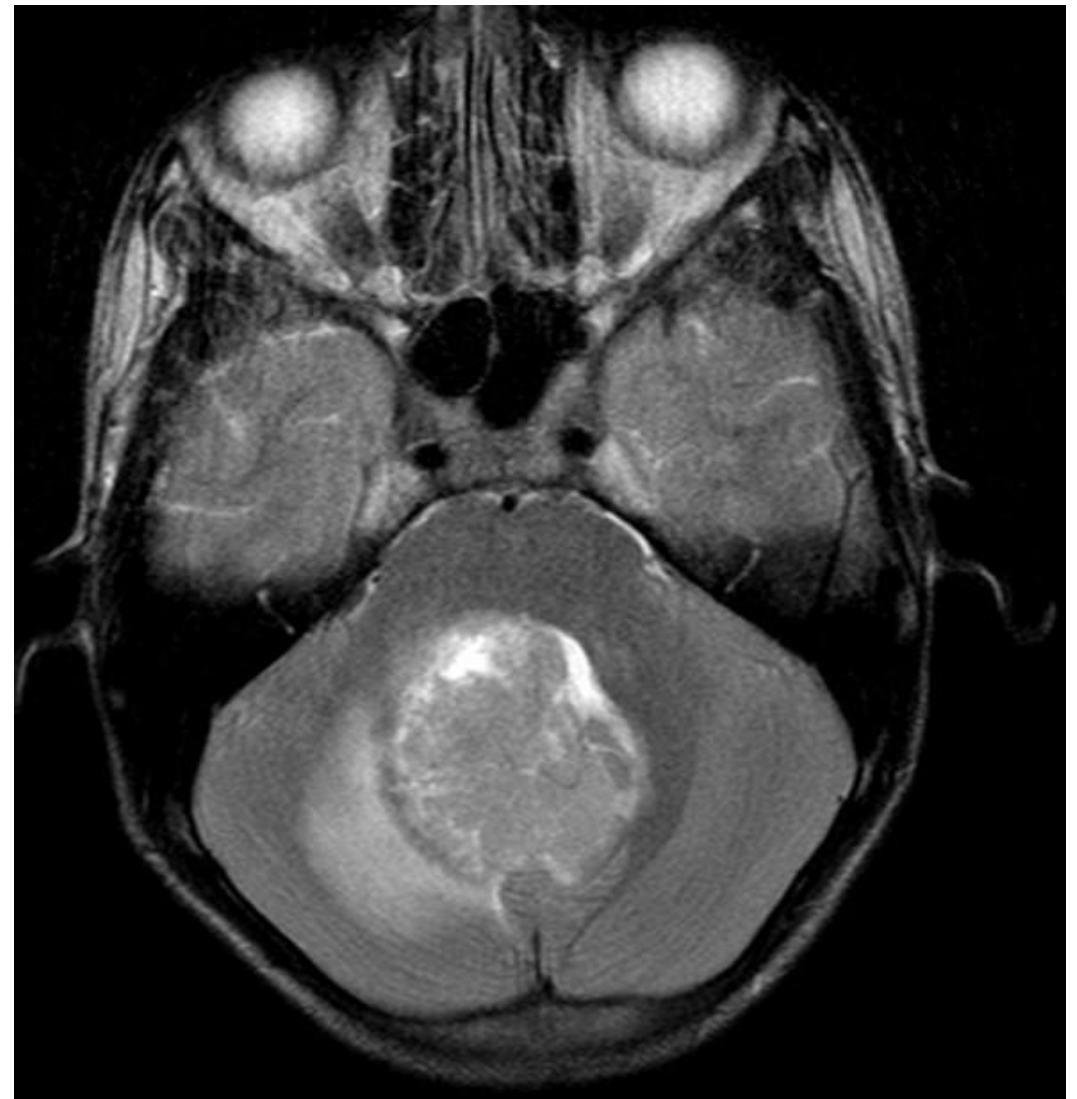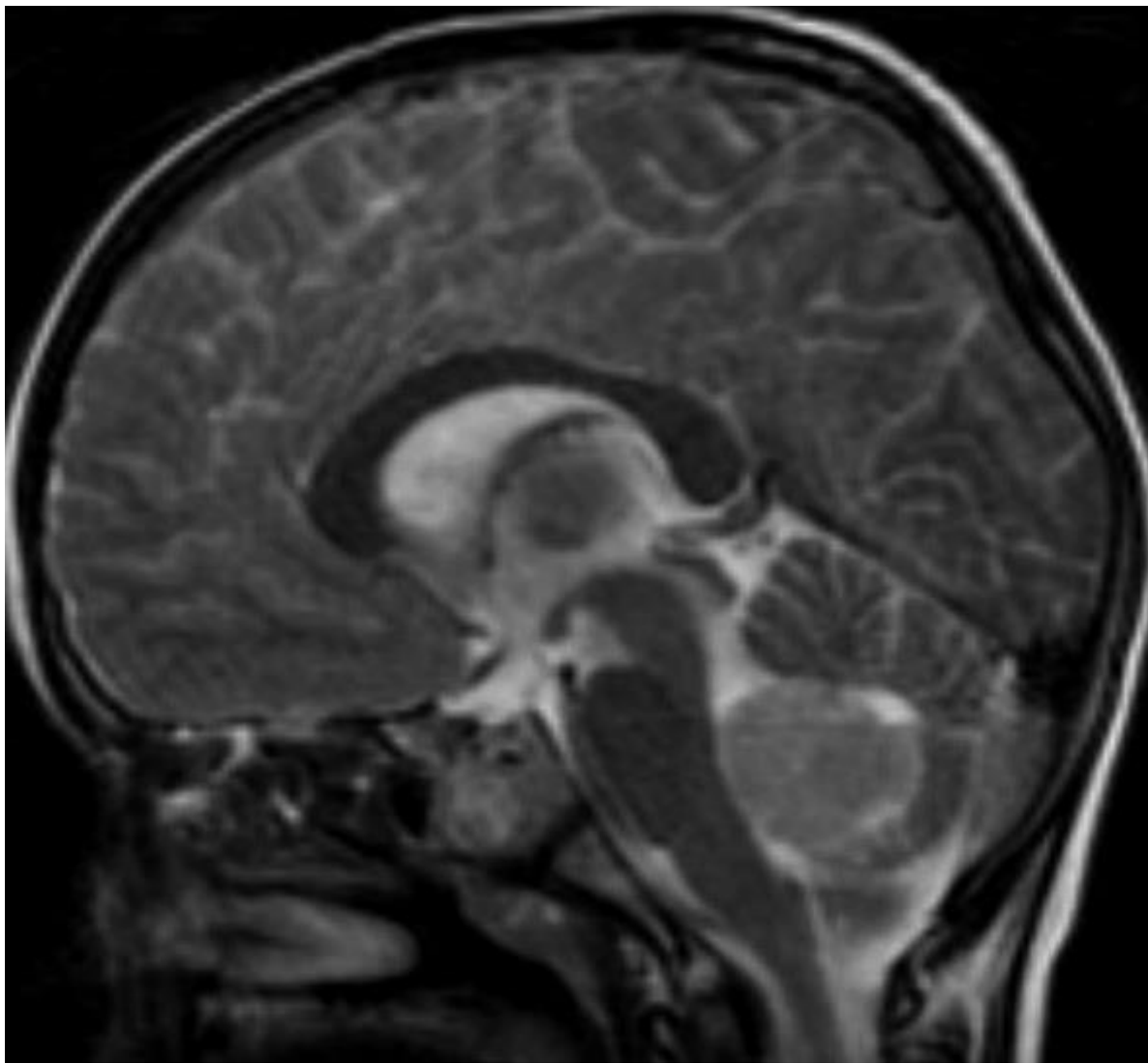
# d/d- Medulloblastoma

- Most common malignant brain tumor of childhood.
- They most commonly present as midline masses in the roof of the 4<sup>th</sup> ventricle with associated mass effect and hydrocephalus.
- The 4 molecular subgroups currently recognized in the WHO classification have been named WNT, SHH, Group 3, and Group 4
- Radiographic features are strongly influenced by the histological type and molecular subtype

- 94% of medulloblastomas arise in the cerebellum and the majority of these, from the vermis (75%). They tend to protrude into the fourth ventricle from its roof, and may even grow directly into the brainstem. This pattern is particularly common in group 3 and group 4 and in some SHH subgroup tumors
- Adults- generally laterally in cerebellar hemispheres (26% in vermis)- MC SHH type
- Cerebellar peduncle epicenter is almost exclusively seen in the relatively indolent WNT subgroup

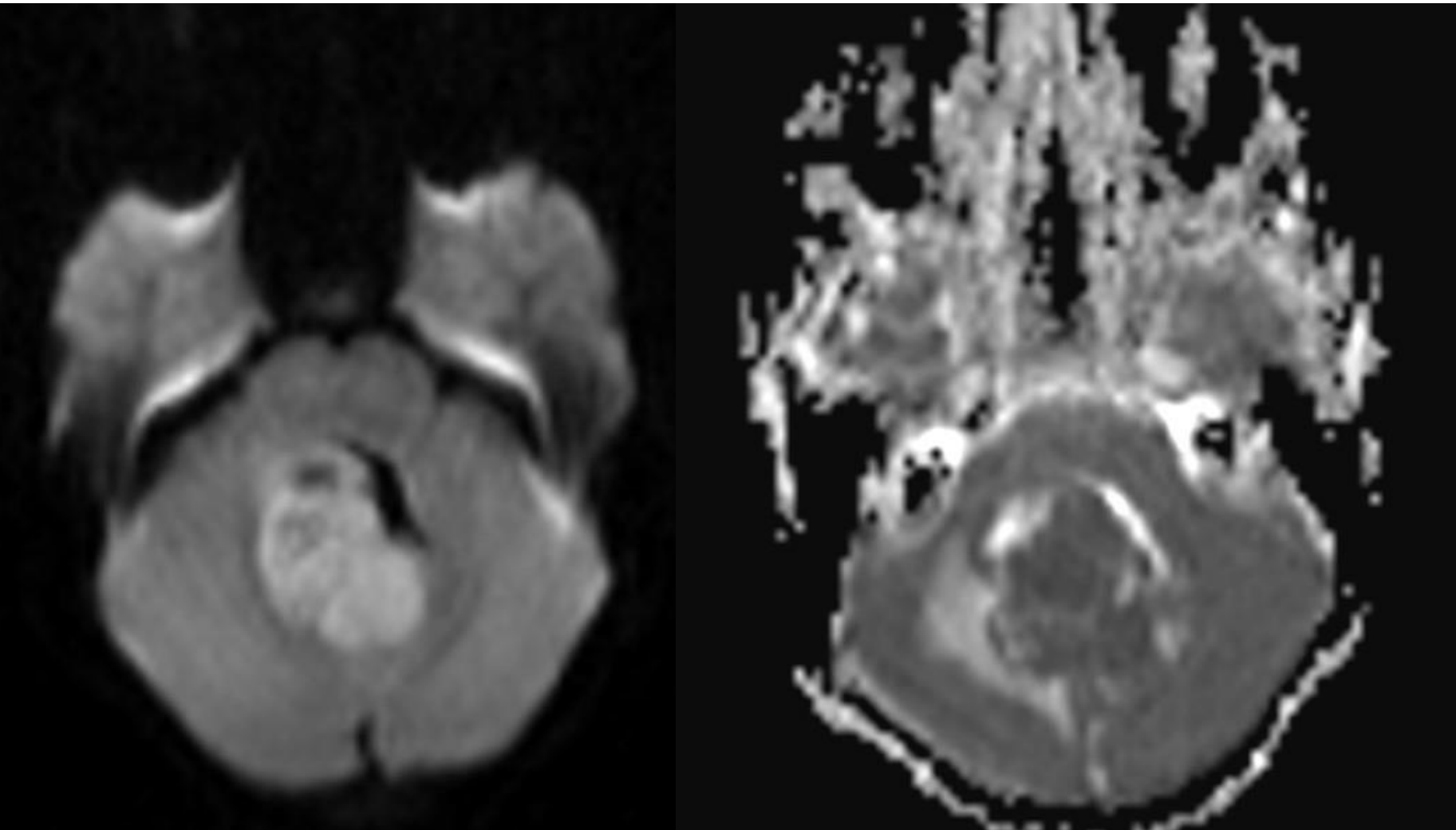


**T1c- 90% enhance, often heterogeneously (Group 4 tend to enhance less)**



### **T2/FLAIR**

- overall are iso to hyperintense to grey matter
- heterogeneous due to calcification, necrosis and cyst formation
- surrounding edema is common



DWI map- restricted diffusion

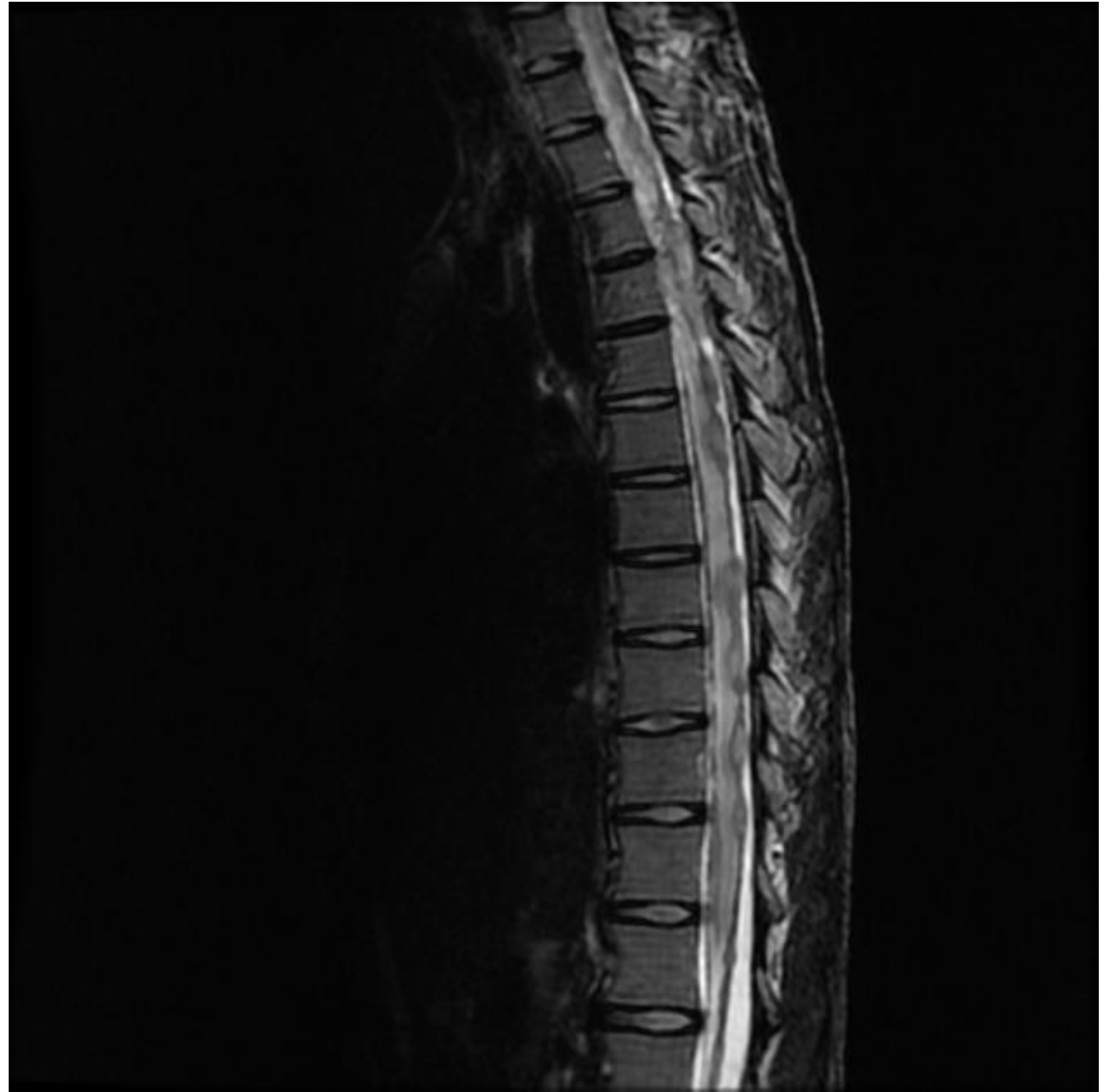ADC map- restricted diffusion

This is a differentiating point from Ependymoma, Significant restricted diffusion as it is a highly cellular tumour

#### MR spectroscopy

- elevated choline
- decreased NAA

As CSF seeding is common at presentation, imaging with contrast of the whole neuraxis is recommended to identify drop metastases and lepto-meningeal spread.





# BASED ON POSITION AND RADIOLOGICAL FEATURES

## Cerebellar peduncle

- very likely WNT subgroup (best prognosis)

## cerebellar hemisphere

- very likely SHH subgroup (intermediate prognosis)
- likely desmoplastic/nodular/medulloblastoma with extensive nodularity (MBEN)

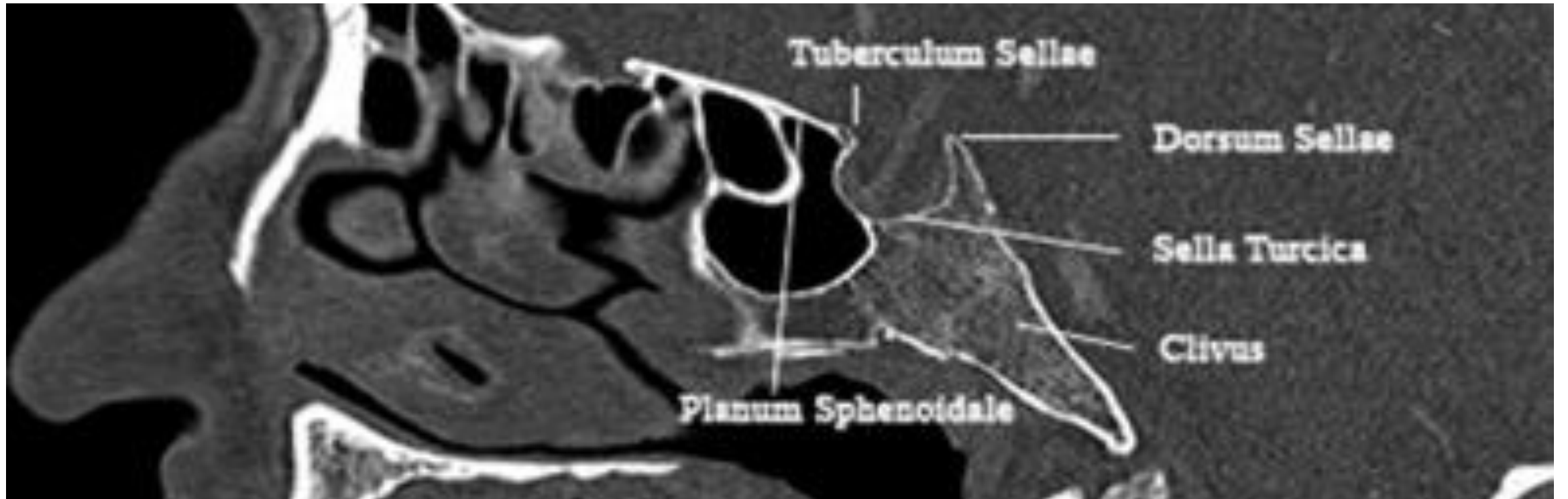
## midline

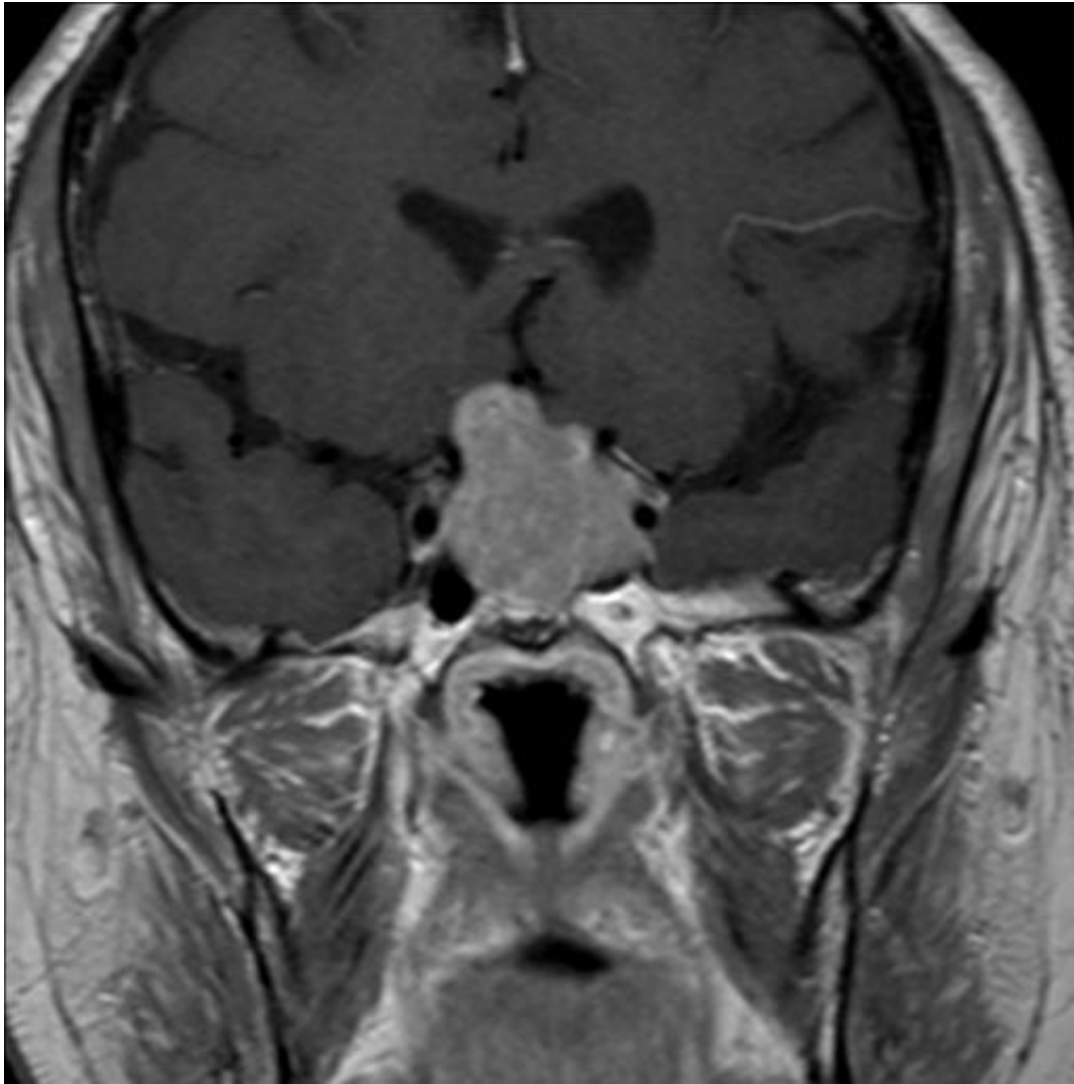
- may be group 3, group 4 or SHH
  - typically infants with a tumor with ill-defined margins but prominent enhancement: likely group 3 (or SHH) (worst prognosis)
  - typically children with a tumor with well-defined margins but mild or no enhancement: likely group 4 (slightly better prognosis)
  - adults with variably defined and variably enhancing tumors: most likely SHH; hemorrhage raises the probability of group 4 <sup>13</sup>

MR spectroscopy may also be distinctive

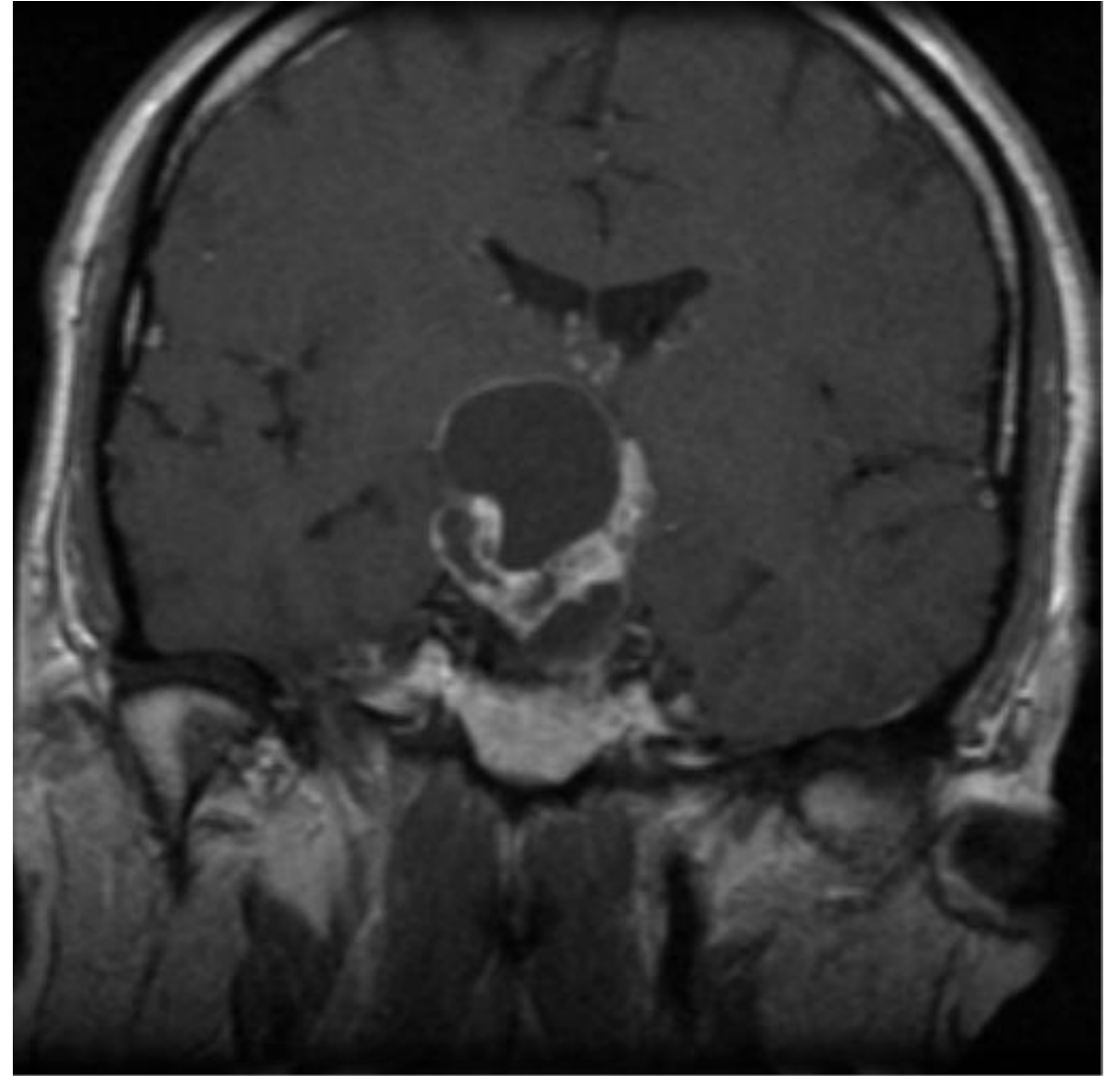
- group 3 or 4
  - taurine peak
  - high creatine
- SHH
  - little or no taurine
  - low creatine

# Sellar tumours





Solid components show moderate to bright enhancement



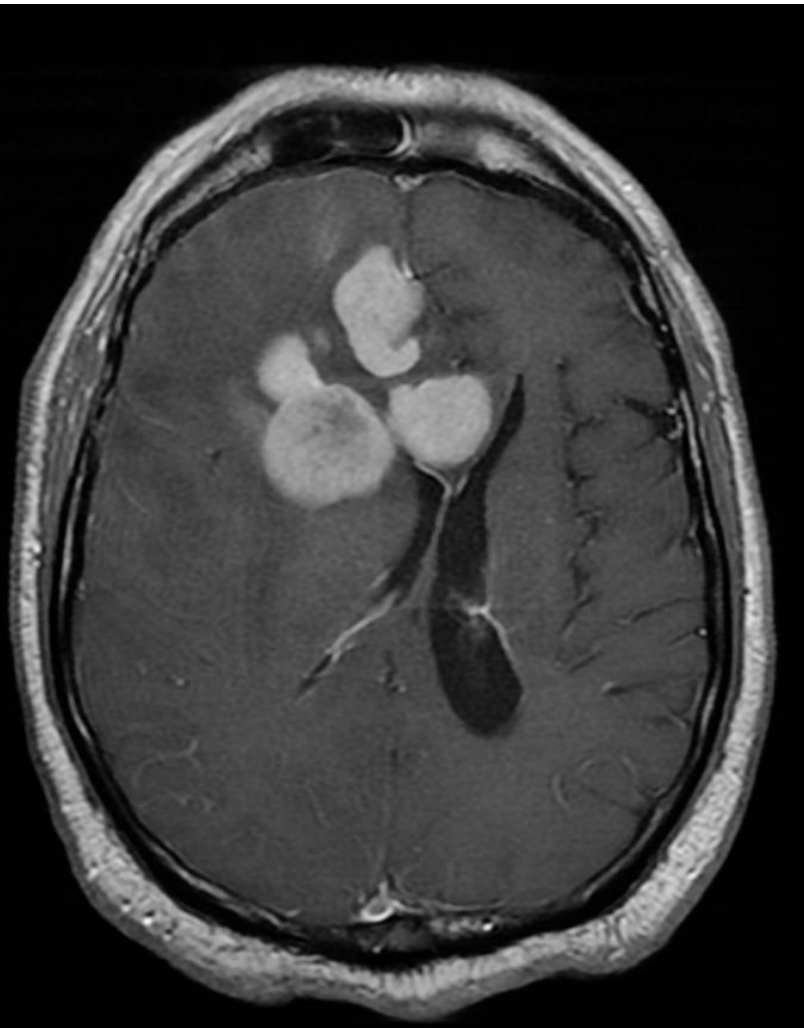Adamantinomas- typically cystic, calcifications+

# Primary CNS lymphoma

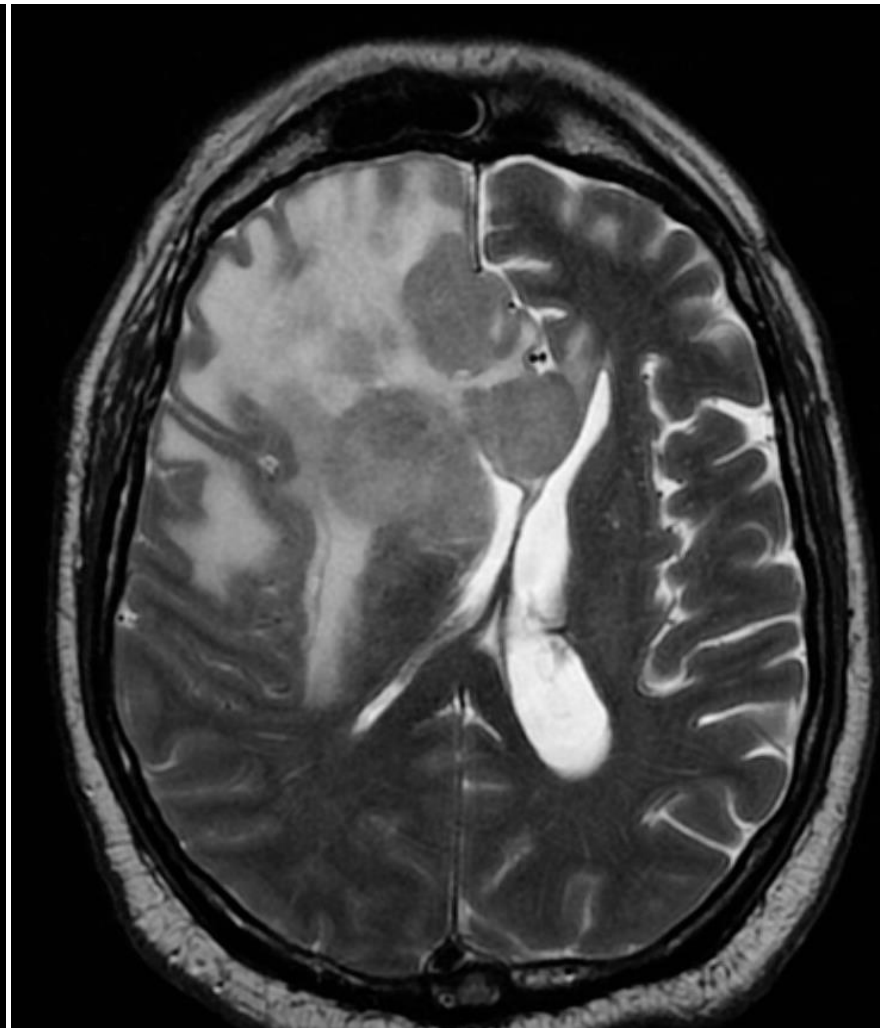- Multicentric involvement of the deepest parts of the hemispheres, around the ventricles( PERI-VENTRICULAR) and in the corpus callosum.
- The tumor tends to disappear rapidly with corticosteroids and/or radiation therapy; hence the name “**ghost tumor.**”
- Imaging studies reveal a well-demarcated mass lesion, which is typically found supratentorially in the paramedian structures
- Contact with an ependymal surface is a characteristic feature

- On MRI, primary CNS lymphoma tends to be iso to hypointense to brain on both T1-WI and FLAIR or T2-WI (in contradistinction to glioma).
- The diminished signal on FLAIR and T2-WI reflect the dense cellularity and relatively decreased water content (high nucleus-to-cytoplasmic ratio) of these tumors.
- On contrast, typically enhances intensely
- Homogeneous enhancement is usually observed in immunocompetent patients. Conversely, in immunocompromised patients, the enhancement pattern tends to be irregular, heterogenous, or ring-like.
- Very high cellularity- Restricted diffusion on DWI/ADC and high choline peak on MRS, markedly decreased NAA

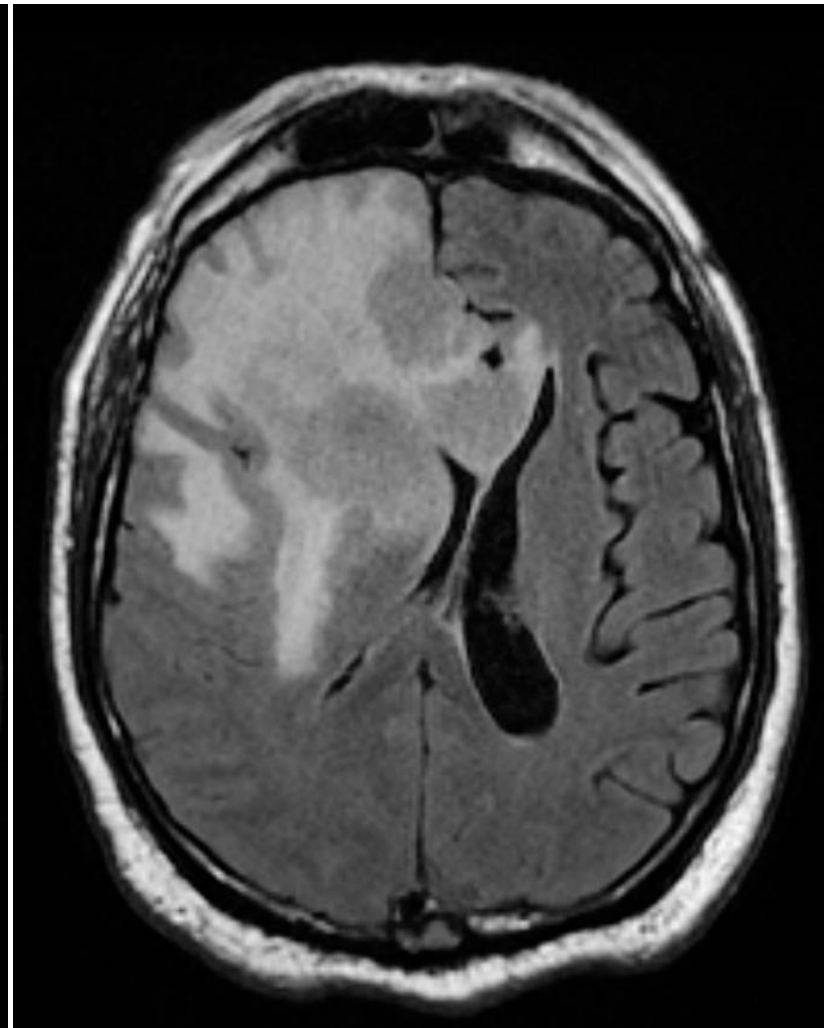




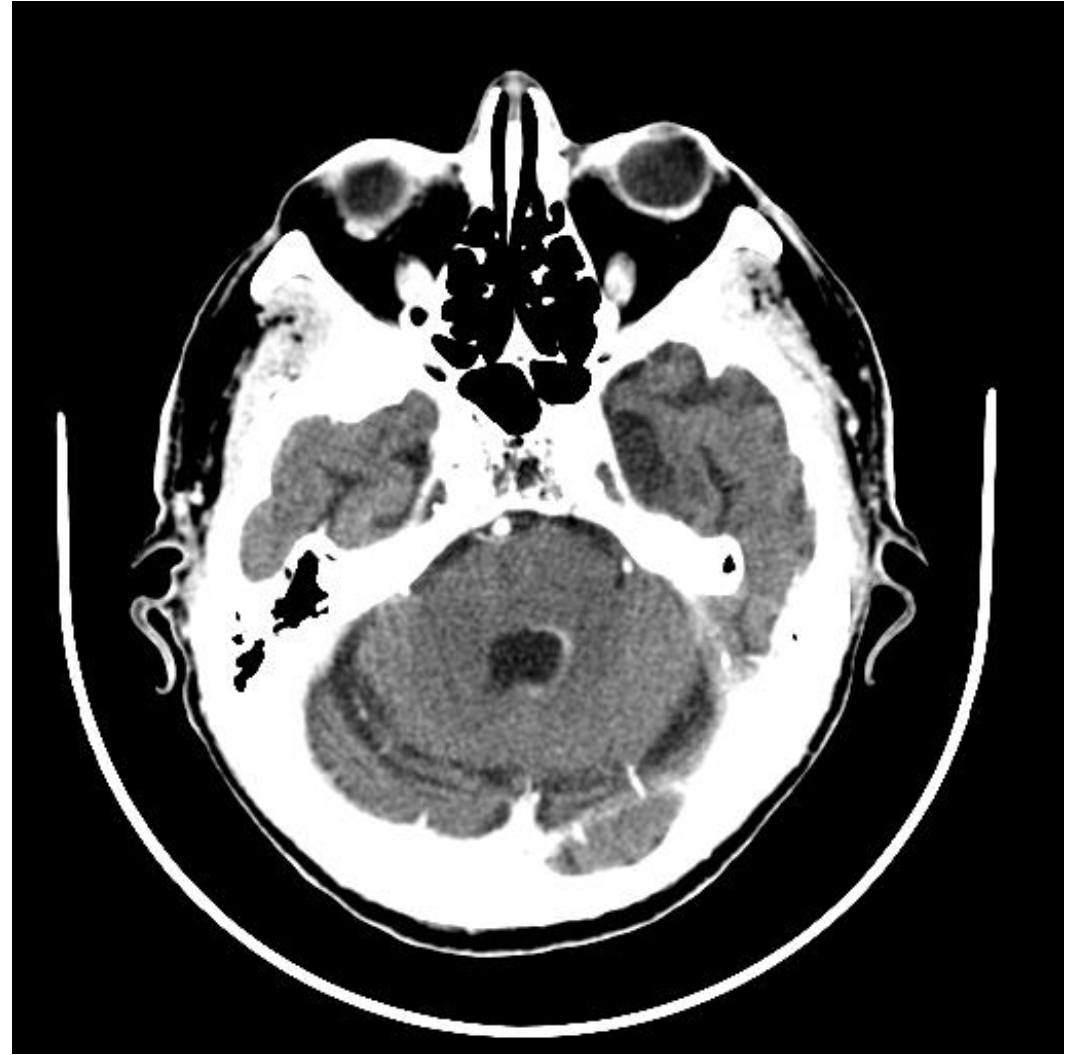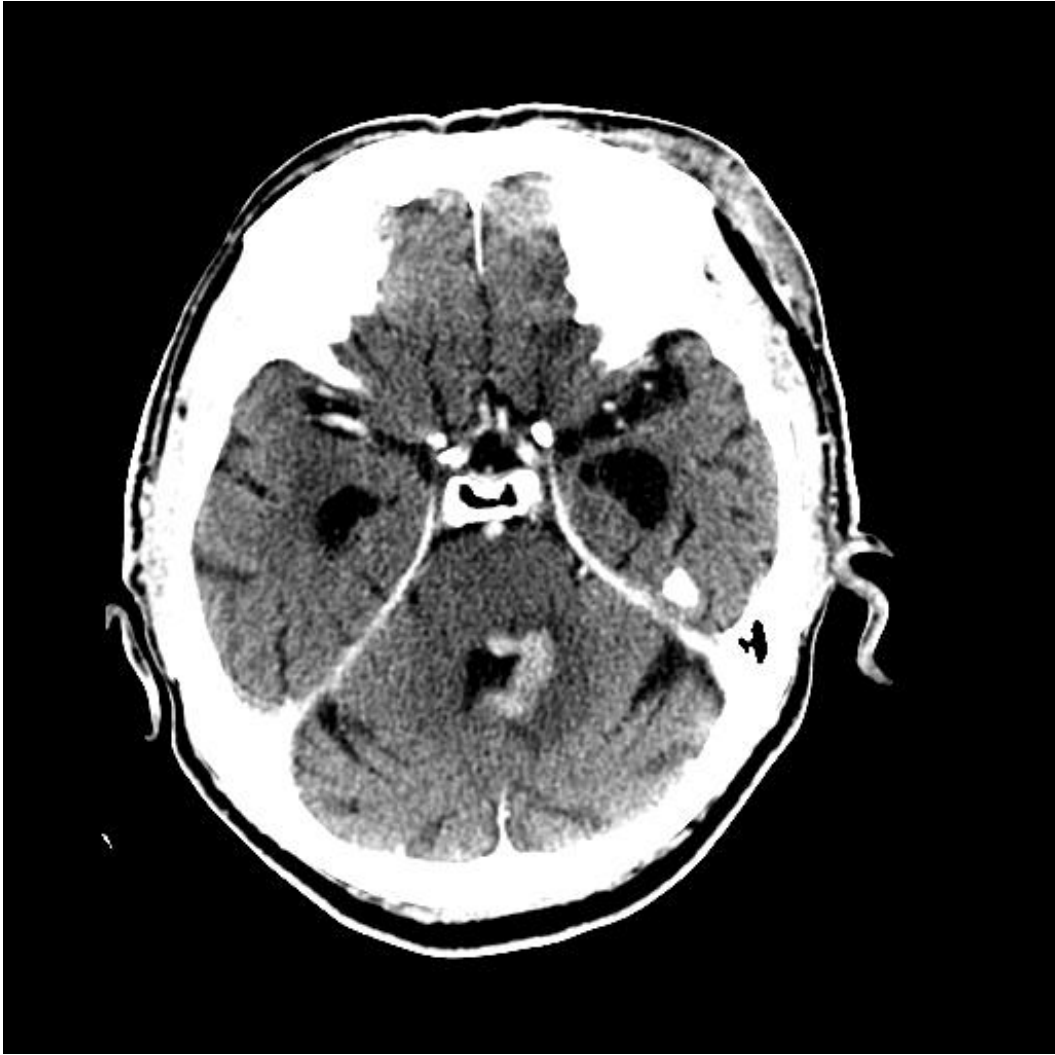
L 971



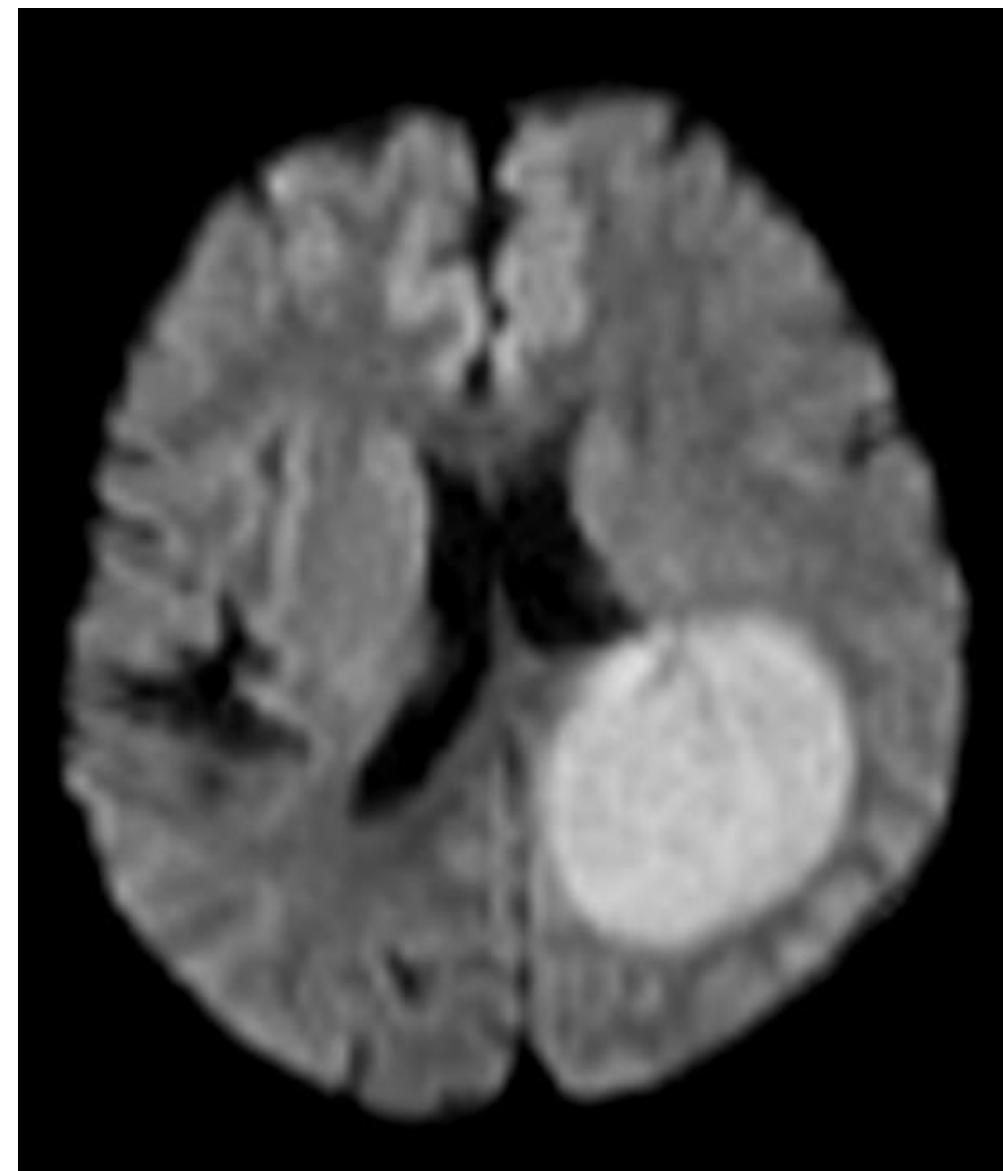
L 974



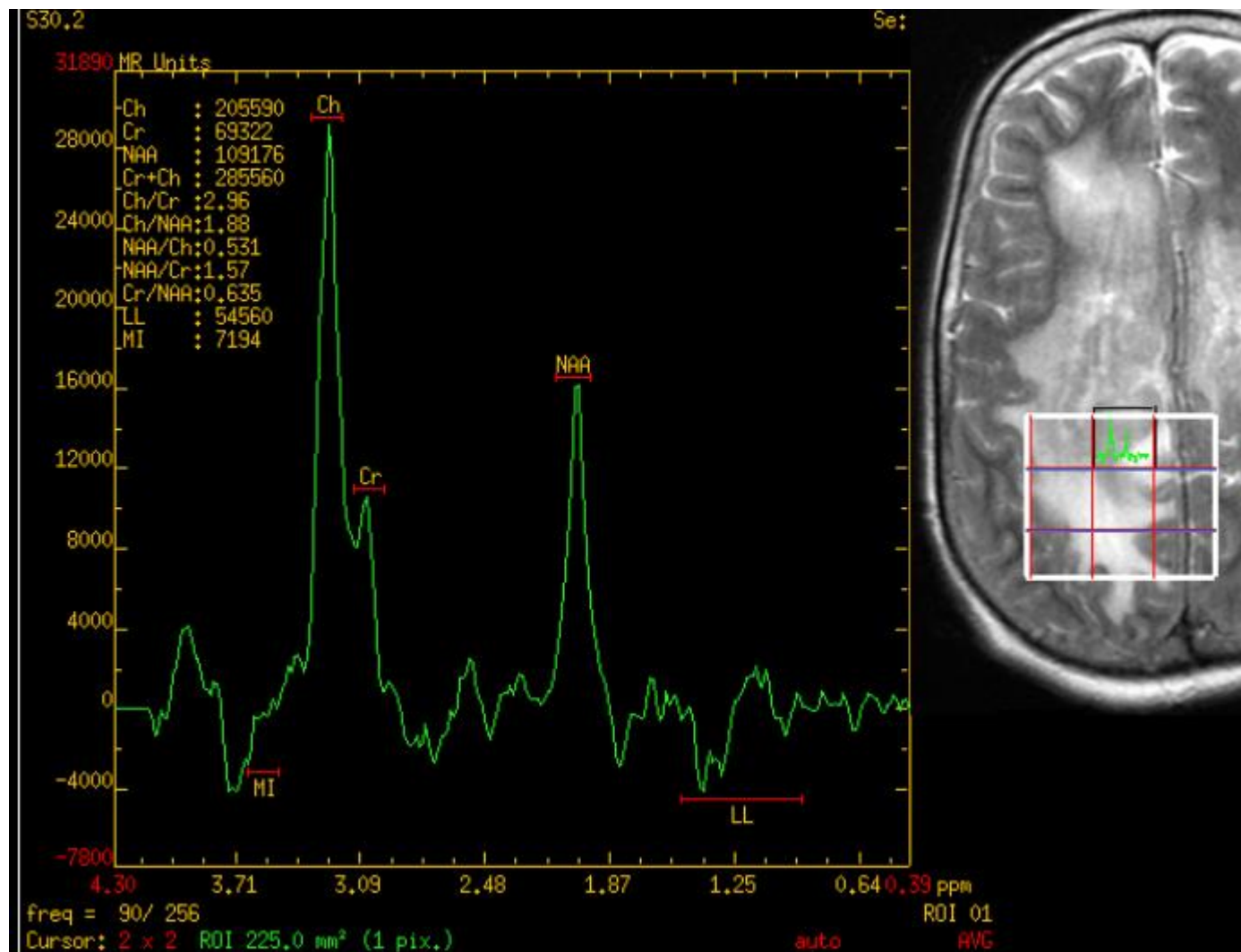
L 504



Pre and post corticosteroids

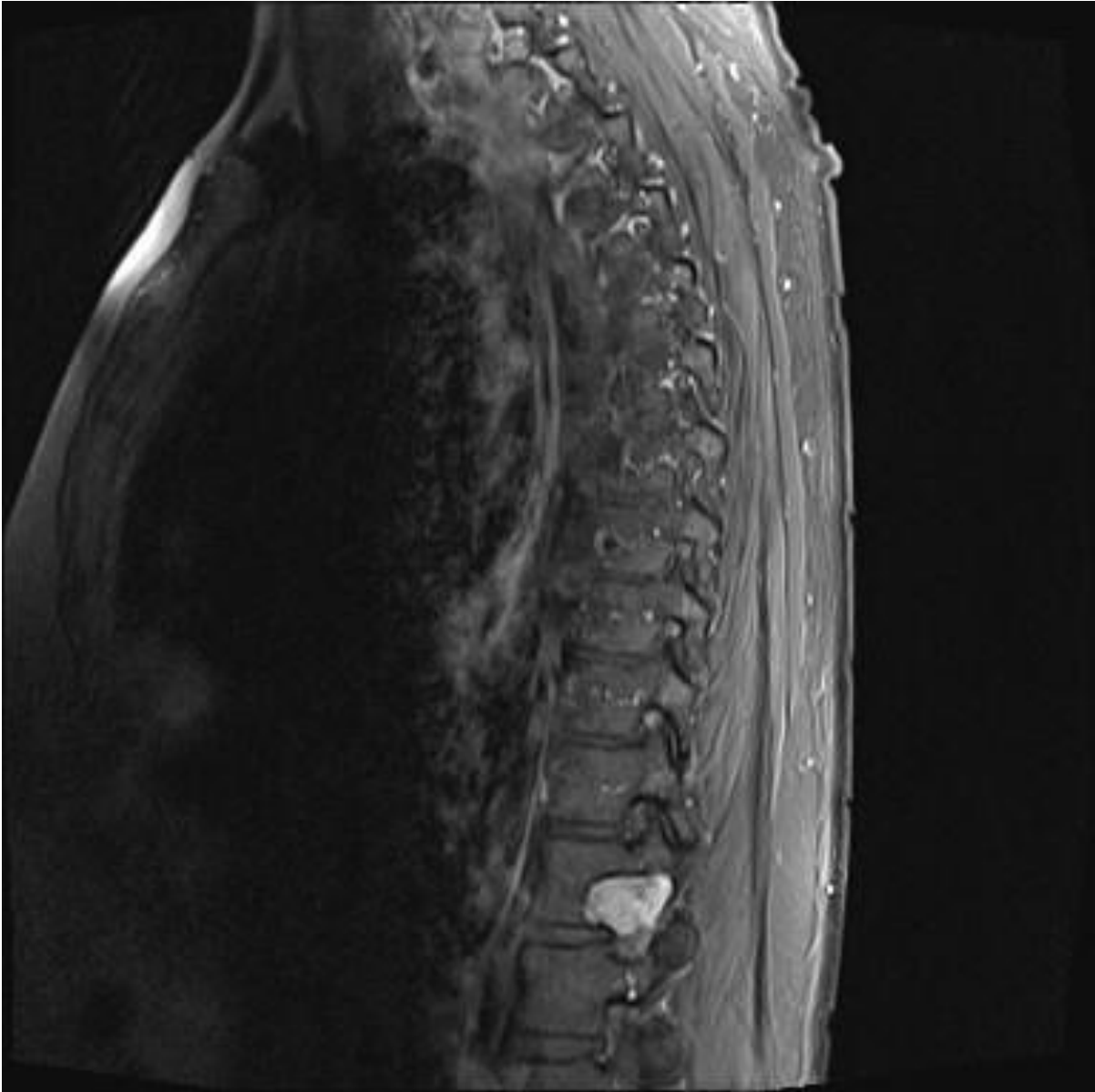
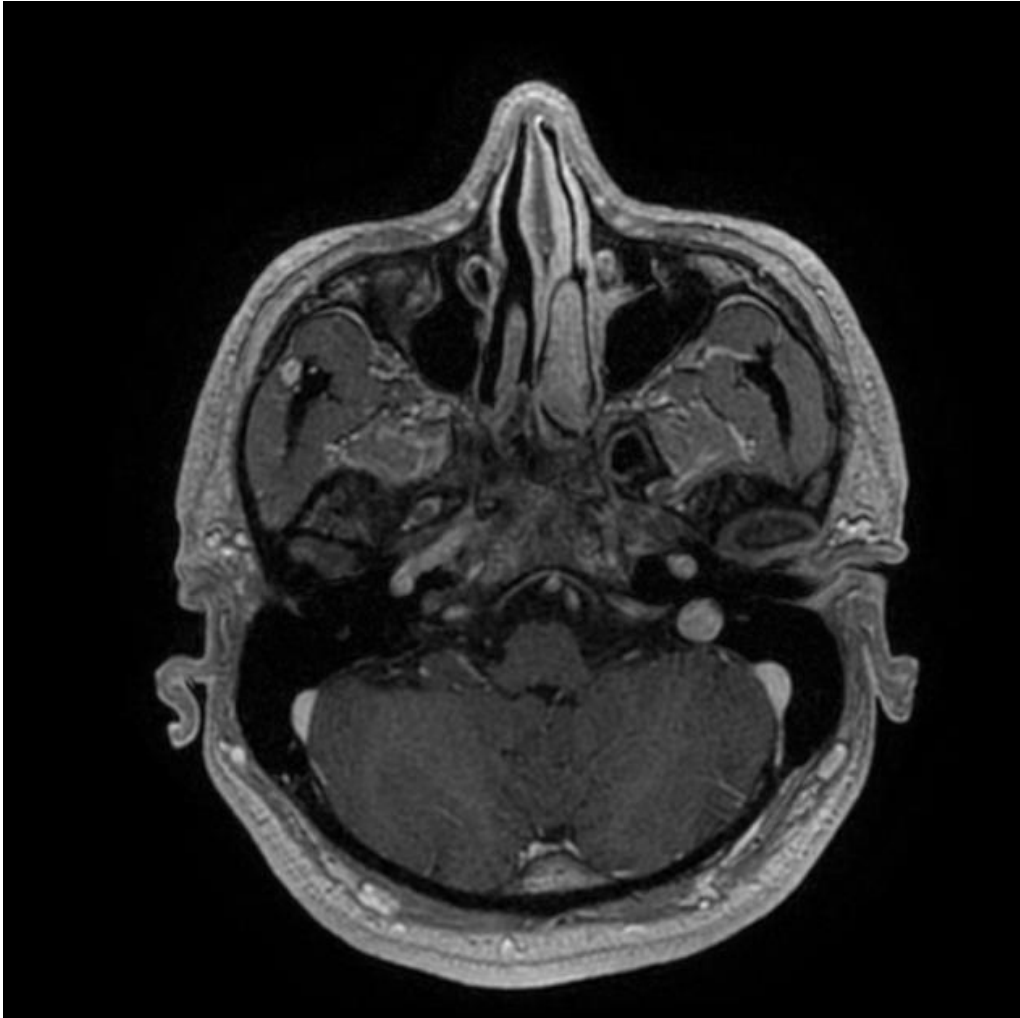


DWI



MRS

# Schwannomas



**T1:** isointense or hypointense

**T1 C+ (Gd):** intense enhancement

**T2:** heterogeneously hyperintense (Antoni A: relatively low, Antoni B: high)  
cystic degenerative areas may be present,  
especially in larger tumors

# Brain metastases

- 80% in cerebral hemispheres
- Hallmark is multiple lesions but may be solitary
- Typically at junction of white and gray matter

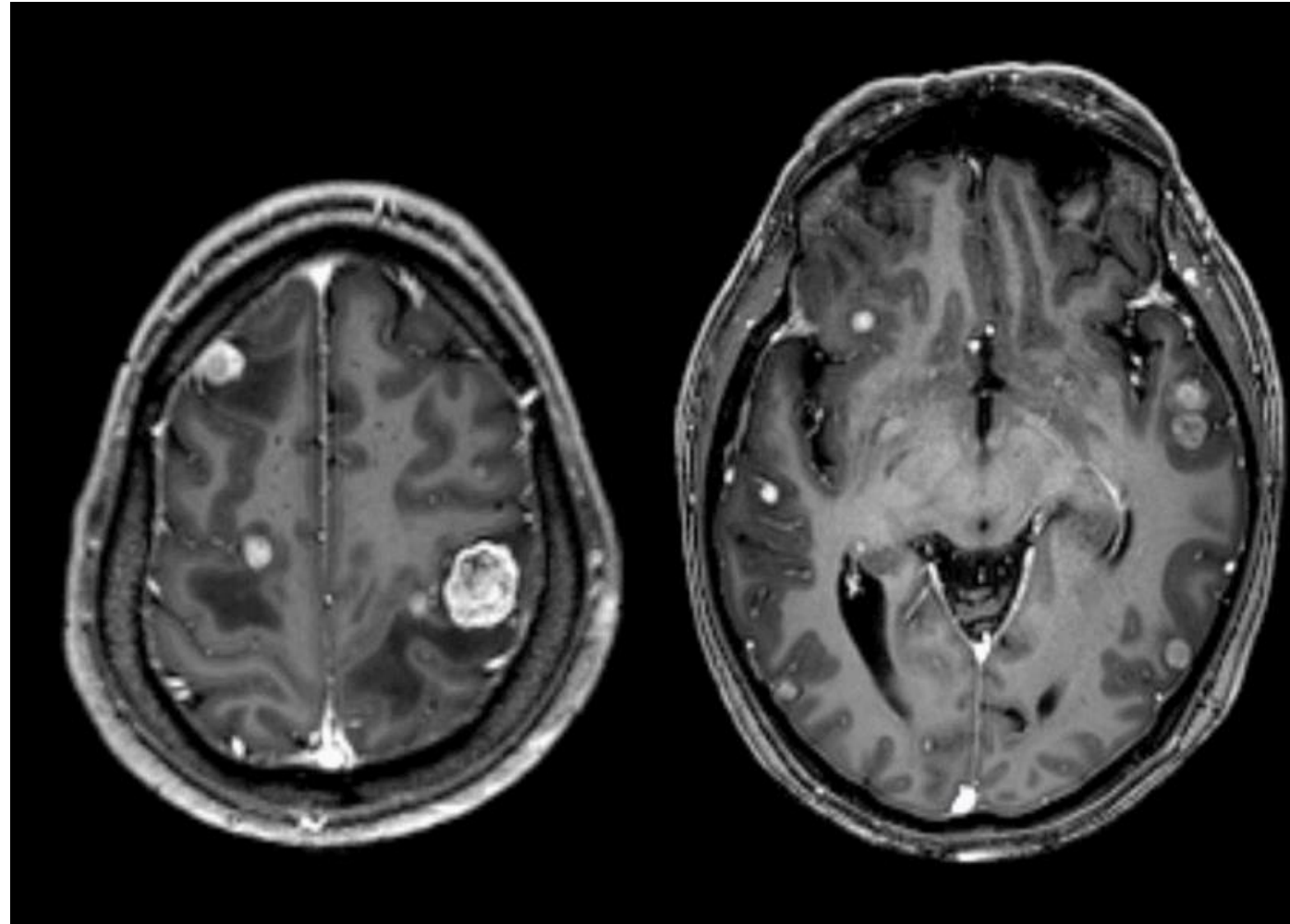
T1 - iso-hypointense

- internal hemorrhage or melanin may show high intrinsic signal

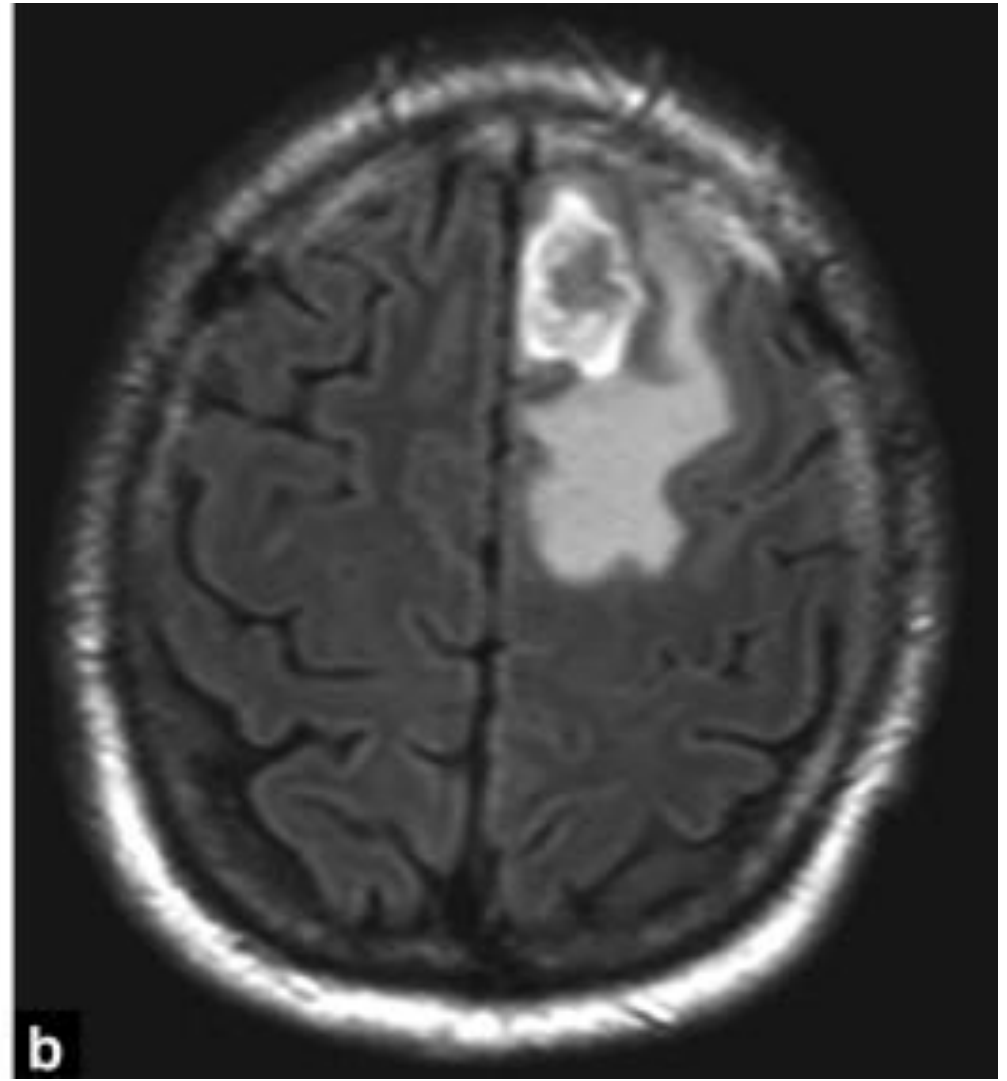
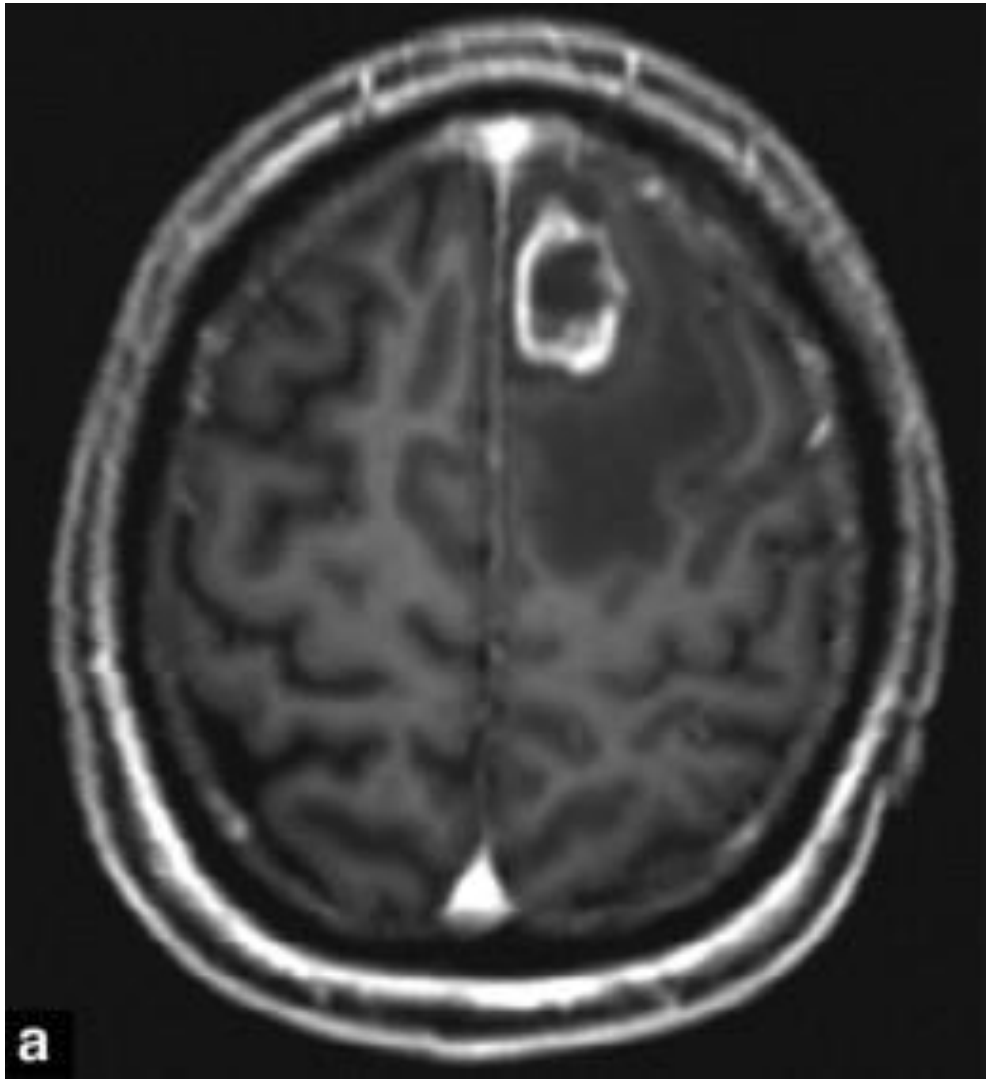
T1c - contrast enhancing, commonly intense, may be uniform/ring enhancing or punctate.

- Delayed images may show additional small metastases

T2/FLAIR- hyperintense , edema may be seen, commonly out of proportion to tumour size



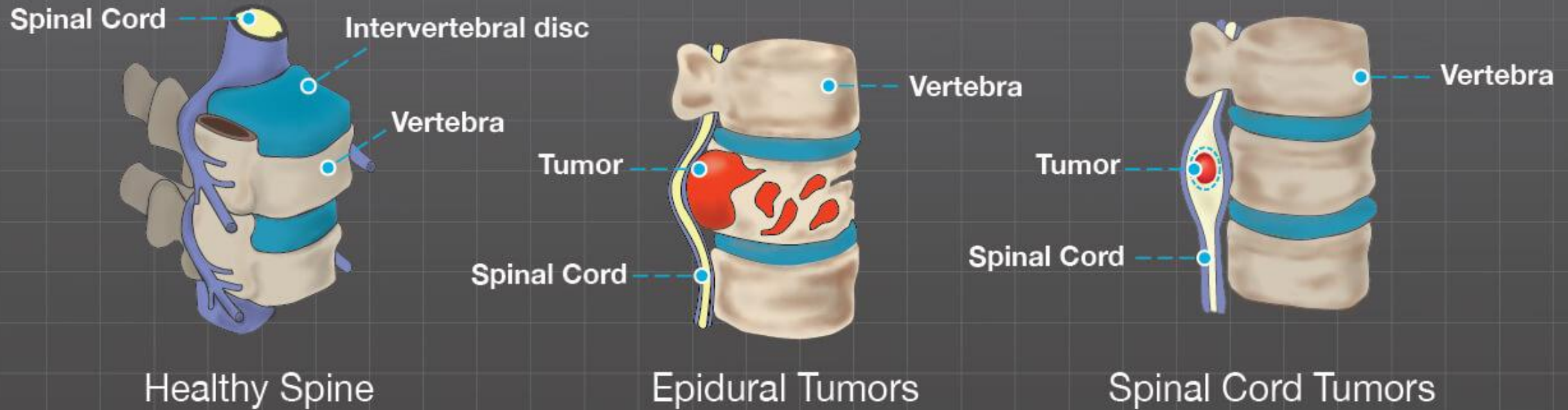


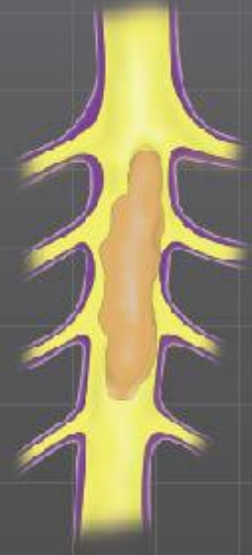

- DWI/ADC- Demonstrate facilitated diffusion in edema
- MR spectroscopy- intra-tumoural choline peak with no choline peak in surrounding edema
  - NAA depleted
  - Tumour necrosis results in lipid peak

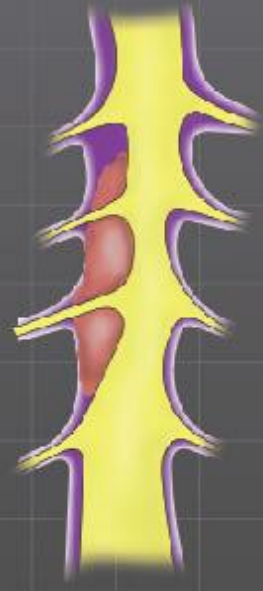
# Spinal tumours

## Where are Spine Tumors Located?

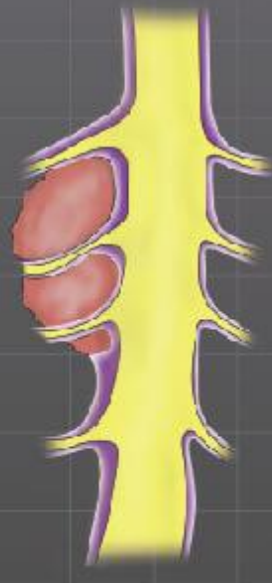



Intramedullary



Intradural-  
Extramedullary



Extramedullary

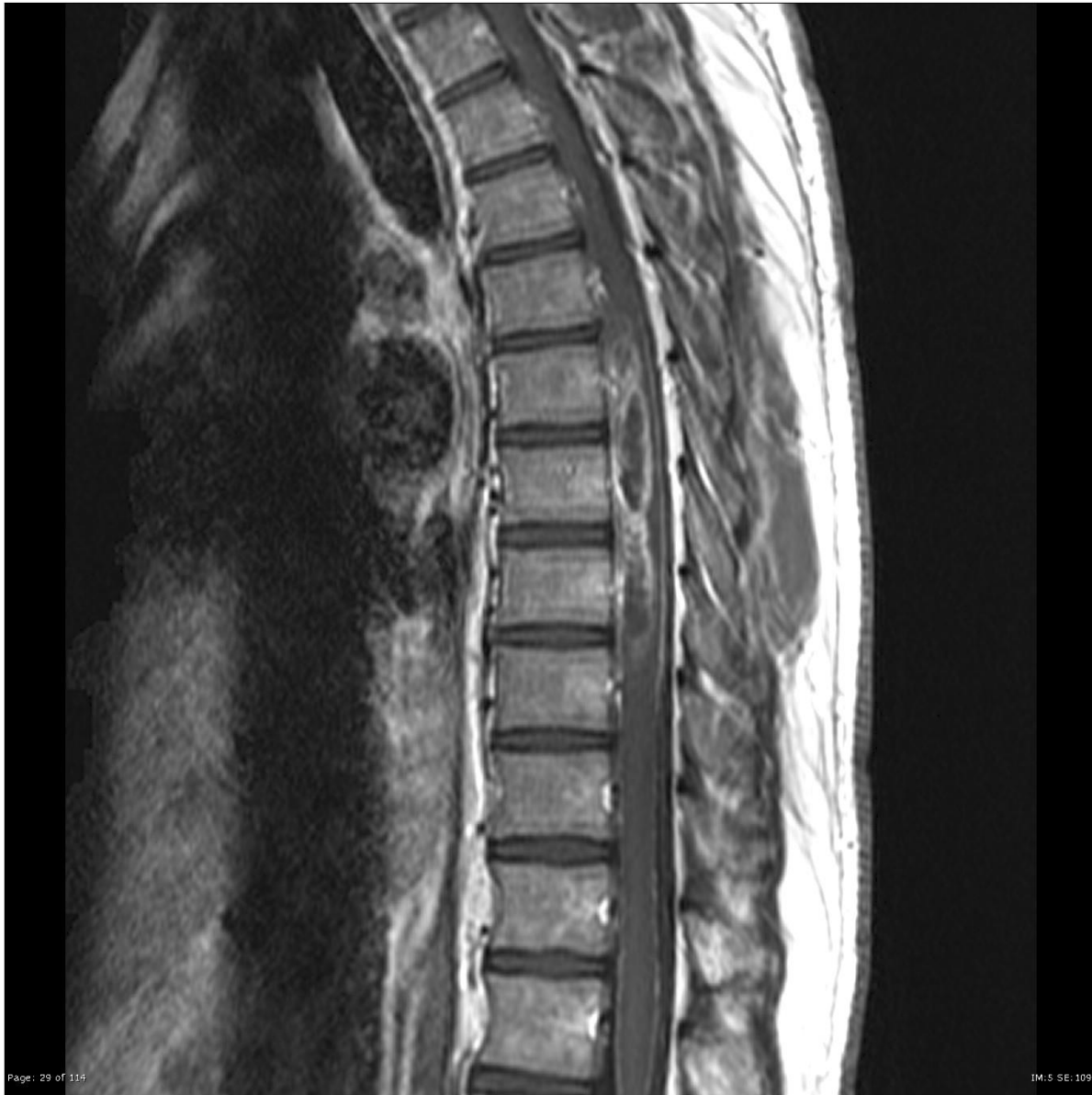**Spinal tumors may occur in any part of the spine and can be categorized by their location**

Intramedullary

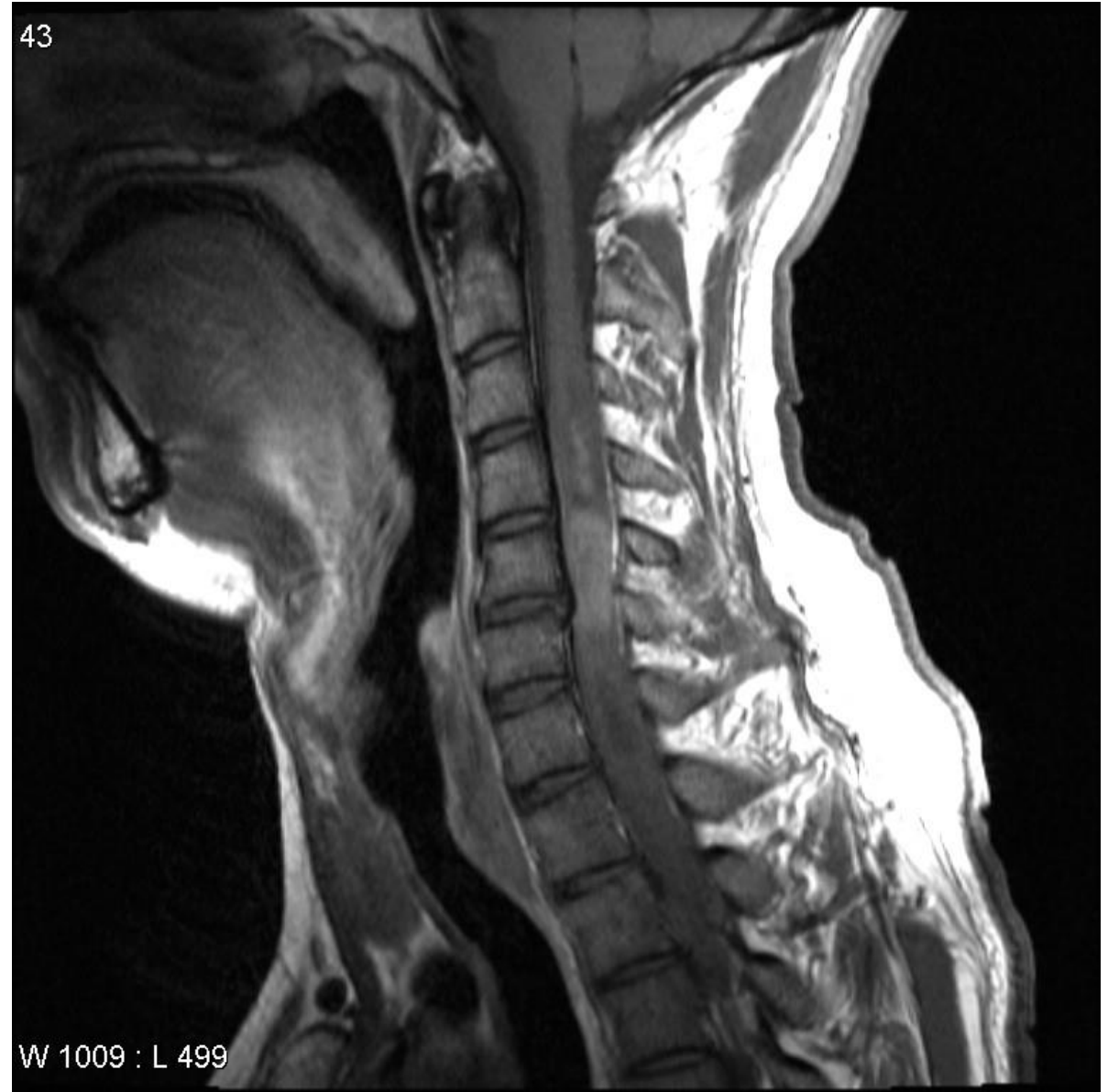Intradural-Extramedullary

Extramedullary or extradural

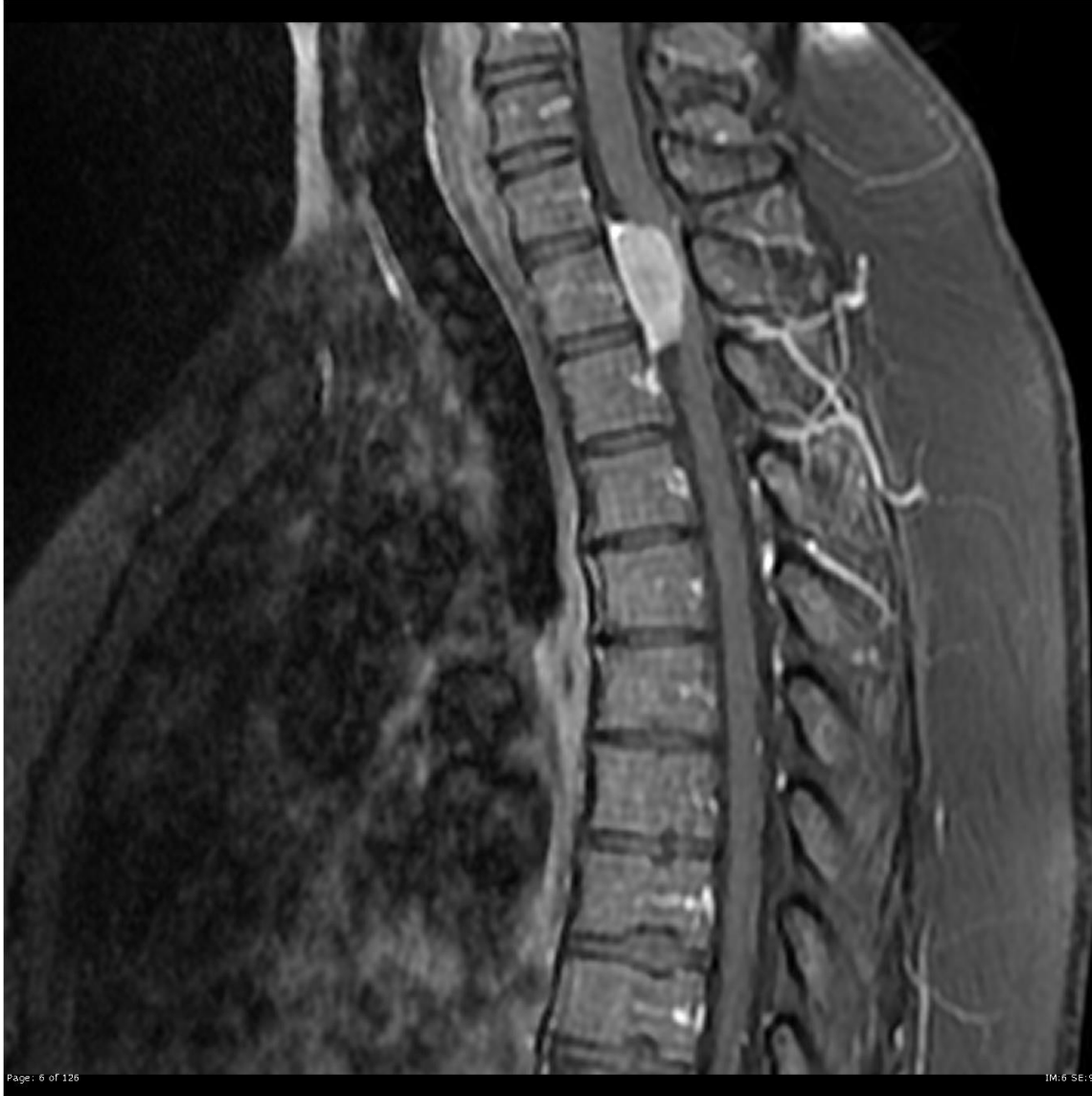- Intramedullary- astrocytomas, ependymomas, hemangiopericytomas
- Intra-dural extramedullary- meningiomas, nerve sheath tumours
- Extramedullary extradural- vertebral tumours



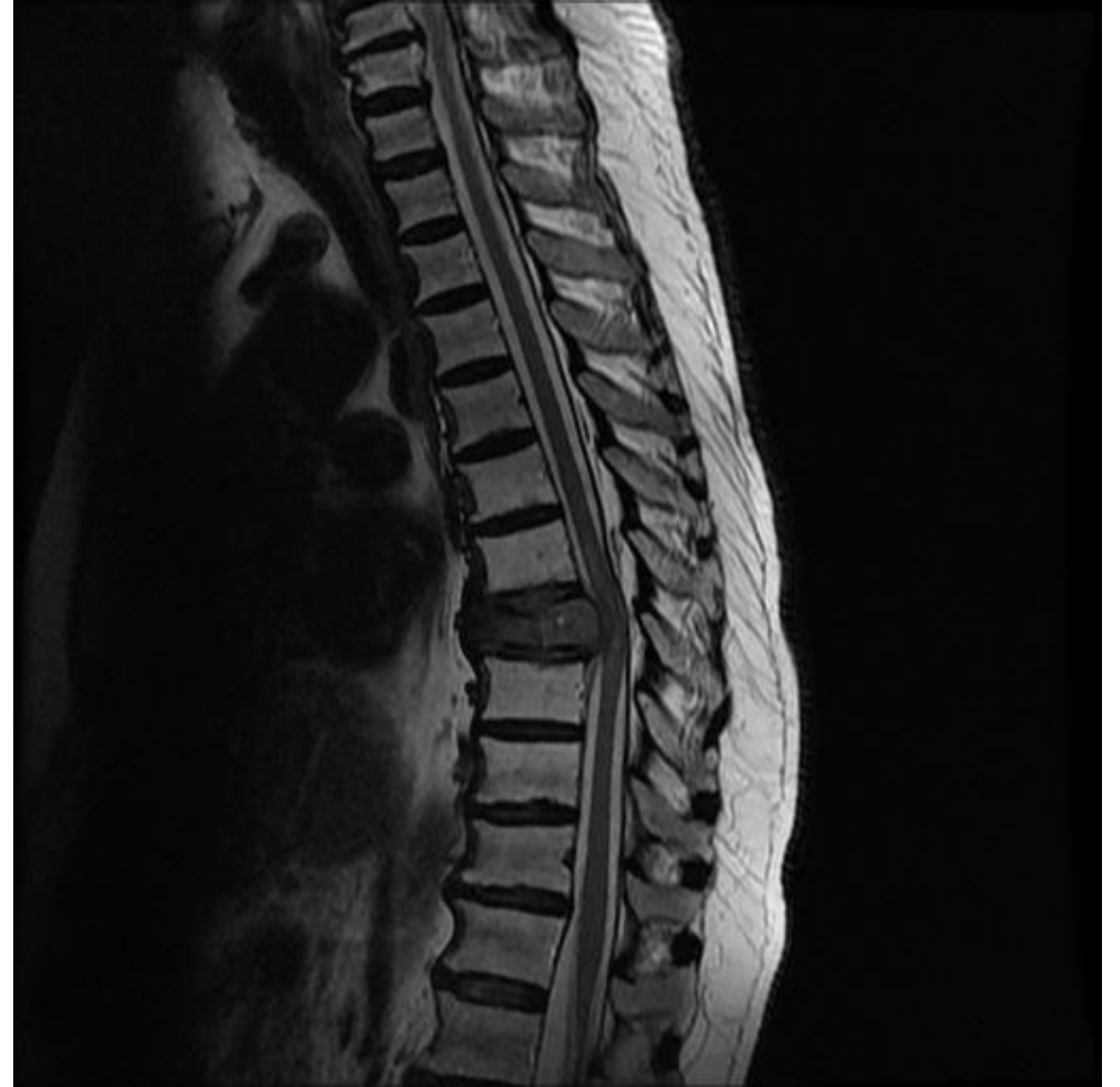Spinal astrocytoma



Spinal ependymoma



Spinal meningioma



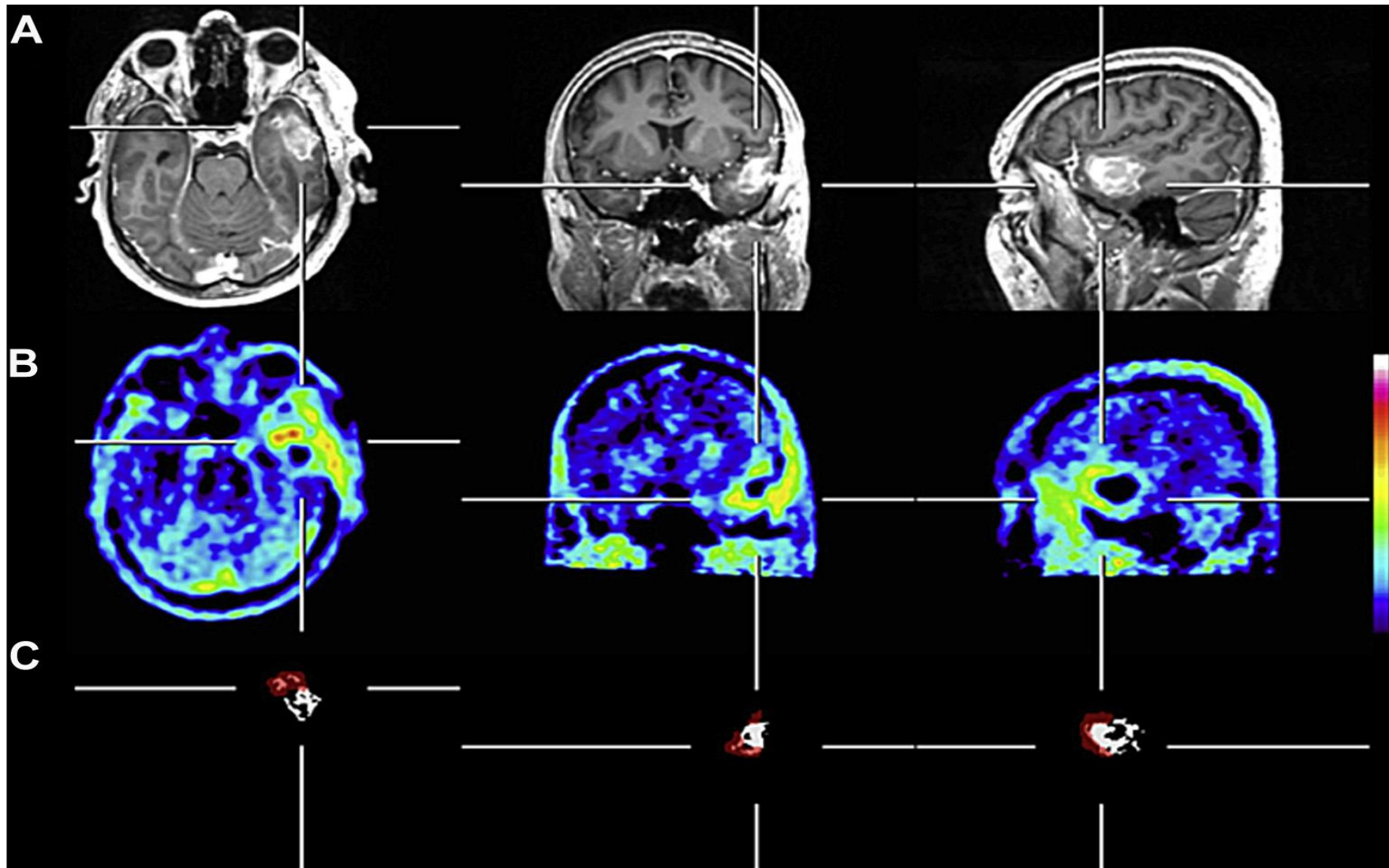
Vertebral metastases



# Nuclear imaging

- PET scan
- High background uptake with FDG
- Radiolabelled amino acids- MET, FET  
MET- methyl-<sup>11</sup>C-Lmethionine  
FET- <sup>18</sup>F-fluoroethyltyrosine

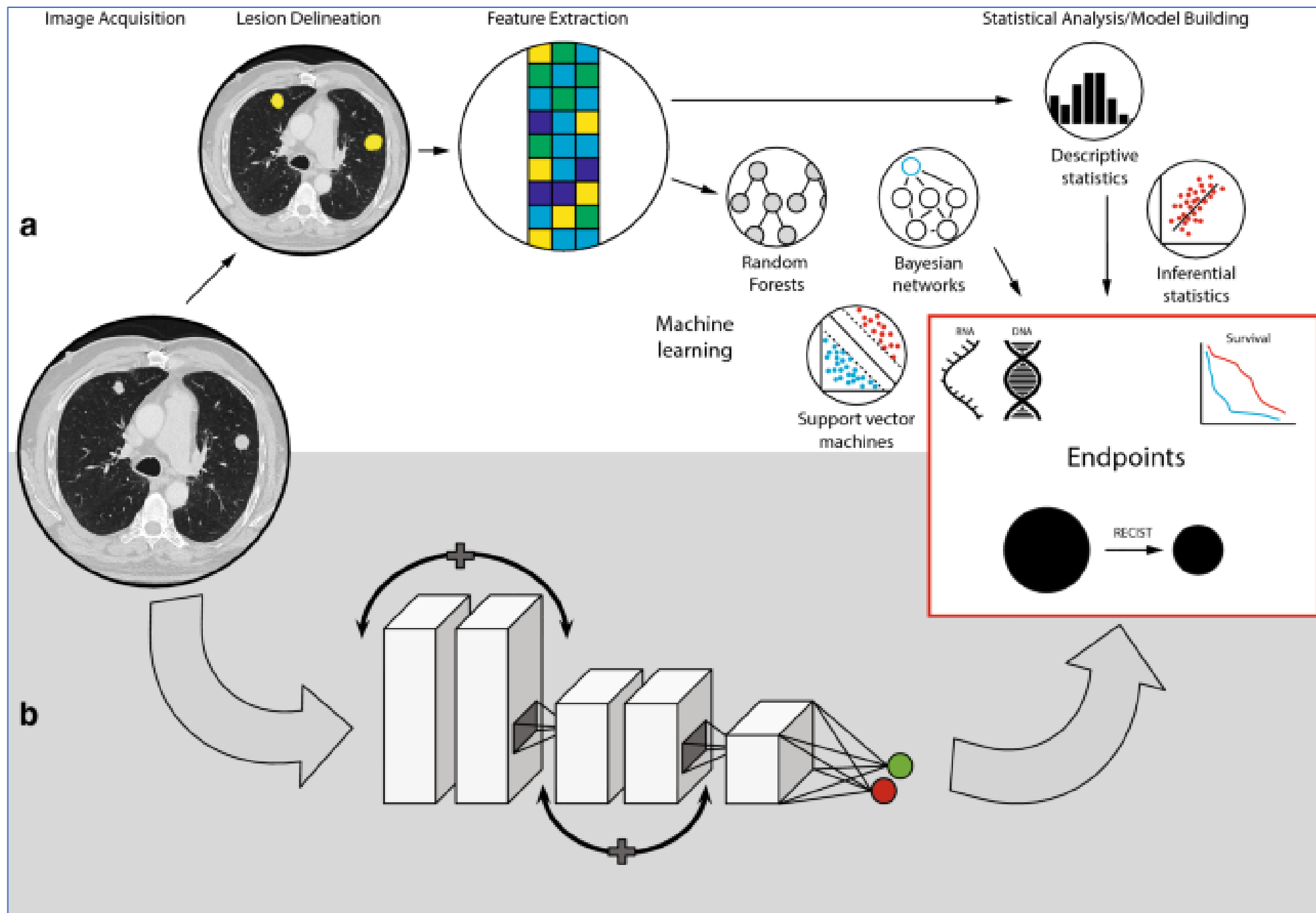
Their uptake correlate with both proliferative potential and microvessel density( neovascularization)



Post- op GBM with recurrence— Only partial congruence between MRI- resection cavity and FET PET recurrence site

# Radiomics & Radiogenomics

- *Radiomics* is the rapidly growing field of radiological research where routine patient images/scans are converted into mineable quantitative data that can then be leveraged to decode the tumor phenotype for applications ranging from improved diagnostics to prognostication to therapeutic response prediction
- *Radiogenomics* is a specific application where imaging features, radiomic or otherwise, are linked to genomic profiles (**VIRTUAL BIOPSY**)

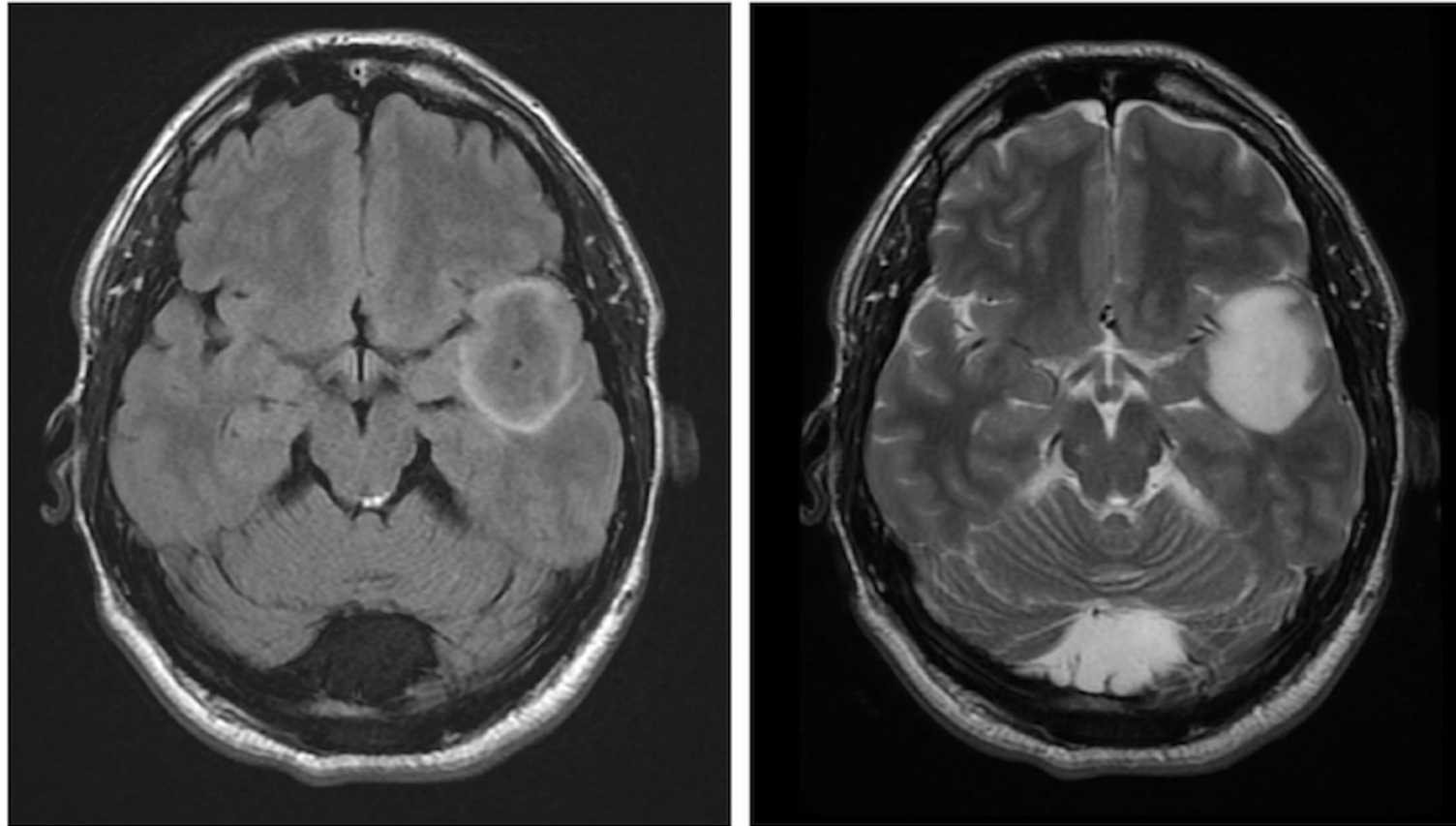


# In Brain

- Used for molecular subtype prediction
- To identify mutational landscape
- DH mutation
- 1p-19q codeletion
- MGMT methylation
- Molecular subtype of medulloblastoma

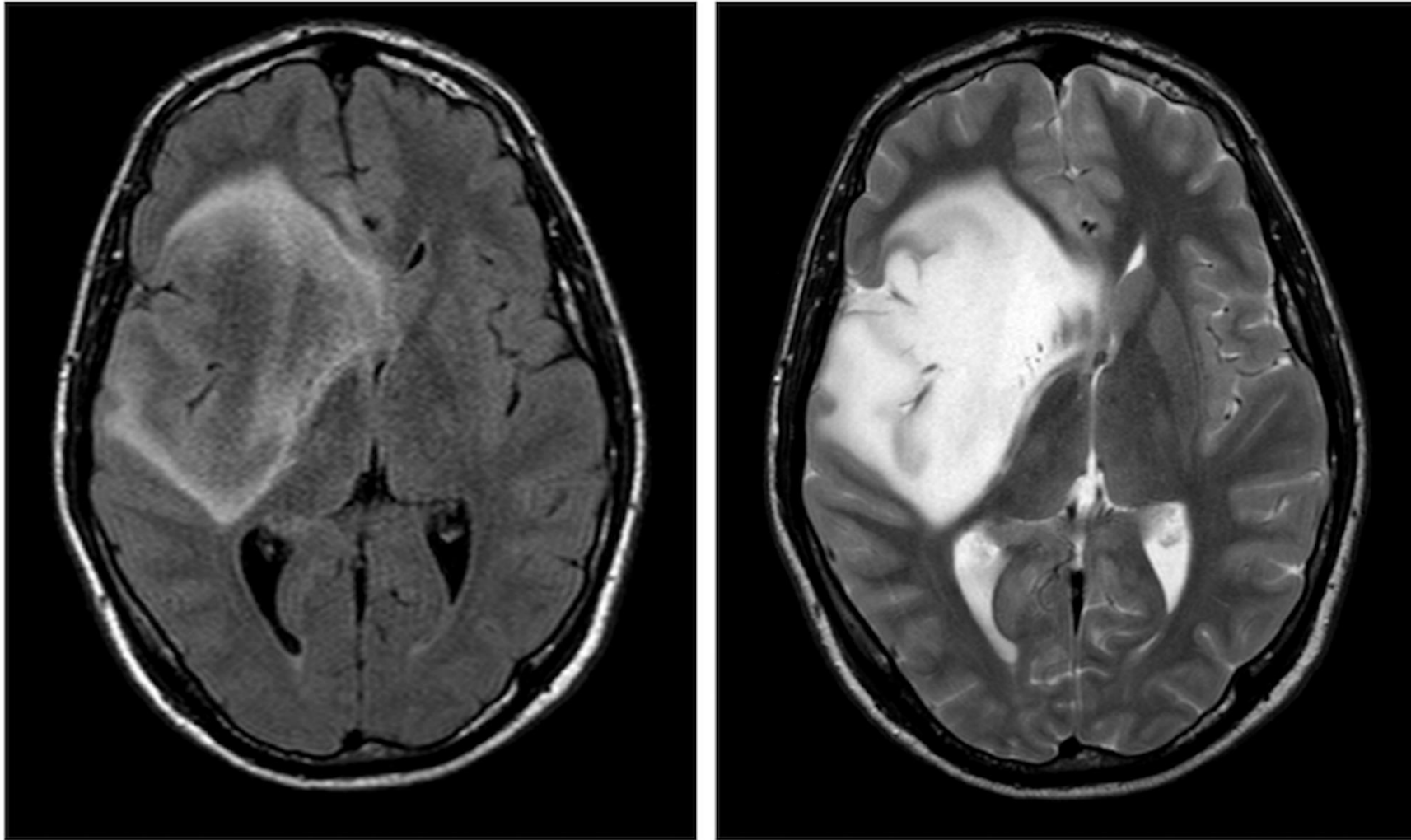
- Software dependent
- Clinically decipherable signs (with semantic data)

# T2-FLAIR mismatch sign

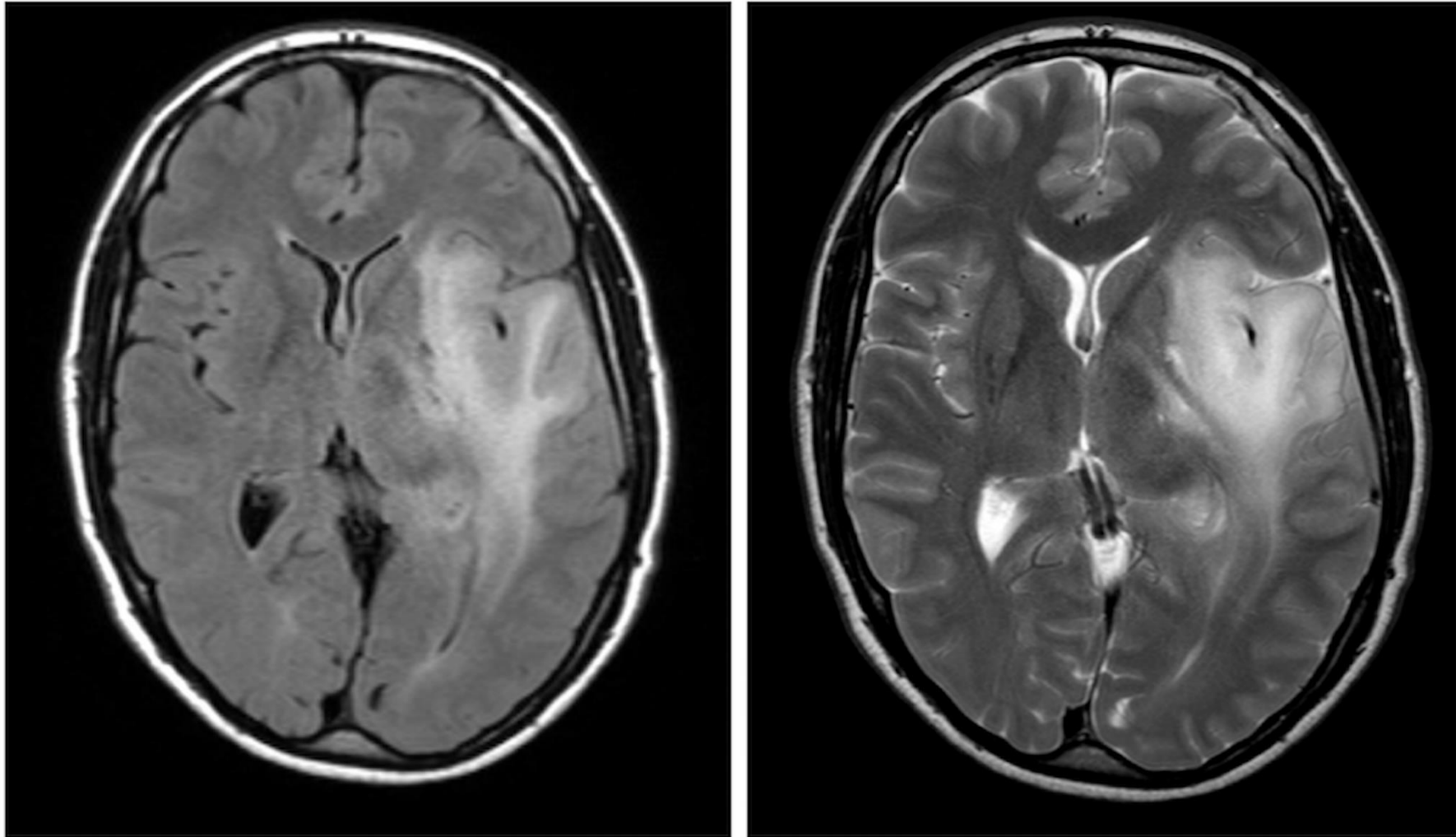


FLAIR sequence demonstrating a relative hypointense signal with the exception of a hyperintense peripheral rim. b) T2W sequence demonstrating homogenous hyperintensive signal with a conspicuous border.





The T2-FLAIR mismatch sign is an imaging finding highly suggestive of isocitrate dehydrogenase mutated (*IDH*-mut) 1p19q non-codeleted (non-codel) gliomas (astrocytomas). False positivity can also occur



No mismatch

- High ADC value, limited surrounding edema and low CBV is a predictor of MGMT methylation

THANK YOU

A watercolor illustration featuring the words "THANK YOU" in a black, serif, all-caps font. The text is centered and surrounded by a delicate arrangement of autumn-themed elements. Two thin, brown stems branch out from behind the letters, adorned with several leaves in shades of red, pink, and orange. Some leaves have white vein patterns. Small clusters of green berries are also scattered among the foliage. The entire composition is set against a plain white background.