

Prostate Cancer: Diagnosis and workup

Dr Rambha Pandey
Associate Professor
AIIMS, New Delhi

Introduction

- Second commonest cancer among male worldwide(accounting for 13.5% of all cancer among male)
- Among 10 leading cancer in male accounting for 4% of all cancer among male in India.
- Median age at diagnosis is 68yrs and disease incidence escalates sharply with increasing age
- According to autopsy data, 70% of men older than 80 yrs of age and 40% of men older than 50yrs of age have pathologic evidence of prostate cancer

Risk Factors for prostate cancer

Factor	Effect on Prostate Cancer Risk
Age	Increase
African American race	Increase
Geography	Scandinavia, high; Asia, low
Family history	Increase
Dietary fat	Increase
Agent Orange	May increase
Vasectomy	No effect
Benign prostatic conditions	No effect
Sexually transmitted diseases	No effect
Tobacco	Inconclusive data
Androgens	Inconclusive data

Nutritional Risk Factors for Prostate Cancer

Food or Nutrient	Direction of Association with Prostate Cancer Risk	Direction of Association with Prostate Cancer Recurrence or Mortality	Overall Quality of Evidence
Selenium	Inverse		Strong
Tomato and lycopenes	Inverse	Inverse ^a	Good
Other carotenoids	Inverse	Inverse ^a	Good ^a
Vitamin E	Inverse (seen in smokers)	Inverse ^a	Good
Vitamin D	Inverse		Good
Calcium and dairy	Null to positive		Good
Red meat	Positive		Good
Fish/omega-3	Inverse	Inverse ^a	

Anatomy

- Lobar Anatomy:

Anterior, posterior, lateral and median lobe

- Zonal Anatomy:

- Peripheral zone(PZ): palpated on DRE and most common site of carcinoma
- Central zone(CZ)
- Transitional zone(TZ): commonest site for BPH
- Anterior fibromuscular Stroma(AFS)

Anatomy

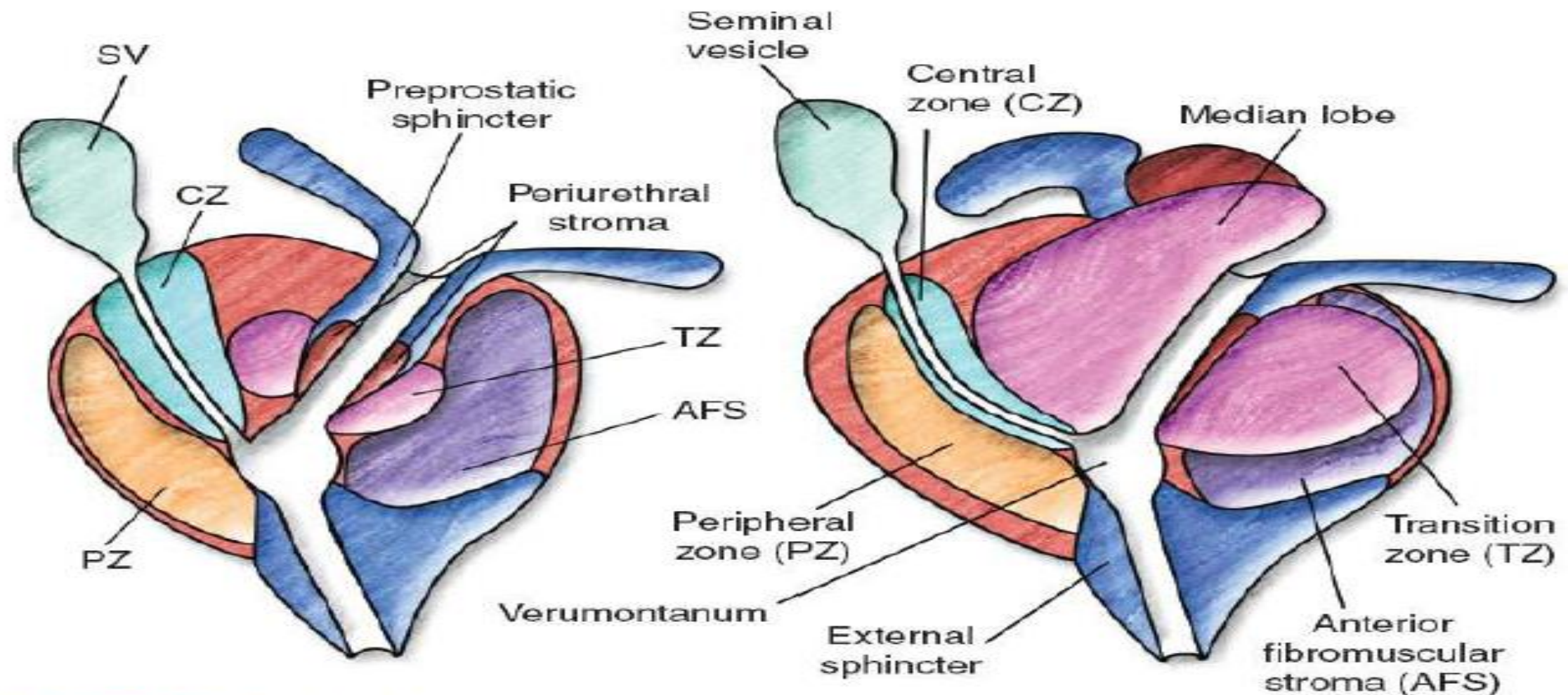


FIGURE 69.1. Zonal anatomy of the prostate. On the left, a young man with minimal transition zone (TZ) hypertrophy. Note that the preprostatic sphincter and periejaculatory duct zone (central zone of McLean) are clearly defined. On the right, an older man with TZ hypertrophy, which effaces the preprostatic sphincter and compresses the periejaculatory duct zone. AFS, anterior fibromuscular stroma; CZ, central zone; PZ, peripheral zone; SV, seminal vesicle. (Reprinted from McLaughlin PW, Troyer S, Berri S, et al. Functional anatomy of the prostate: implications for treatment planning. *Int J Radiat Oncol Biol Phys* 2005;63[2]:479–491. Copyright © 2005 Elsevier. With permission.)

Histology

- Adenocarcinoma (commonest comprising of 95% of prostate cancer)
- **Other Histological subtypes are:**
 - Periurethral duct carcinoma
 - Transitional cell carcinoma
 - Ductal adenocarcinoma
 - Neuroendocrine tumors
 - Mucinous carcinoma
 - Sarcomatoid carcinoma
 - Endometroid tumors
 - Adenoid cystic carcinoma
 - Small cell carcinoma

Sign/symptoms

Early Stage:

- Asymptomatic diagnosed during Screening

Locally advanced disease:

- Symptom of Bladder outflow obstruction
 - Hesitancy
 - Urgency
 - Dysurea
 - Decreased force of stream
 - Retention of urine
- Hematuria
- Hematospermia
- Renal failure
- Pelvic pain

Advanced disease(invovement of regional lymphnodes)

- Pelvic and perineal discomfort
- Edema of lower limb

Metastatic Disease:

Bone pain

Symptoms due to involvemnet of vertebrae: such as spinal cord compression

Symptoms related to metastases to different organ

Diagnostic work up

◆ **Routine:**

- Clinical History and clinical Examination
- Rectal Examination

◆ **Laboratory-**

- Complete blood count, LFT, KFT
- Serum PSA(Total,free, percentage free)
- Plasma acid phosphatase(prostatic/total)

Radiological Imaging

- Transrectal ultrasonography
- Chest radiograph
- Computed tomography of abdomen and pelvis
- Bone scan(PSA>20)
- MRI with endorectal coil
- PET CT

Prostate Specific Antigen

- ◆ Initially identified and purified from prostatic tissue by Wang et al in 1979
- ◆ It is a Serine protease glycoprotein secreted by prostatic epithelium
- ◆ It is organ specific and not prostate cancer specific
- ◆ Historically the Normal value: 0.4-4ng/ml for white males younger than 70 yrs of age
- ◆ However recently upper limit has been adjusted to 2.6ng/ml
- ◆ Half life-2.2 days
- ◆ Mild elevation 4-10ng/ml
- ◆ Significant elevation >10 ng/ml
- ◆ Sensitivity -85% and specificity 65-70%
- ◆ Positive predictive value for PSA >4ng/ml ranges from 31% to 54%
- ◆ Estimated rate of cancer detection by PSA screening ranges from 1.8% to 3.3%
- ◆ Carcinoma with normal PSA-25%

- **Age specific PSA:**

➤ Age	PSA
➤ 40-50	0-2.5
➤ 60-70	0-4.5
➤ 70-80	0-6.5

- **Pretreatment serum PSA is also predictor of EPE and SVI**

➤ PSA	Rate of organ confined disease
➤ -4-10ng/ml	53-70%
➤ 10-20ng/ml	31%-56%

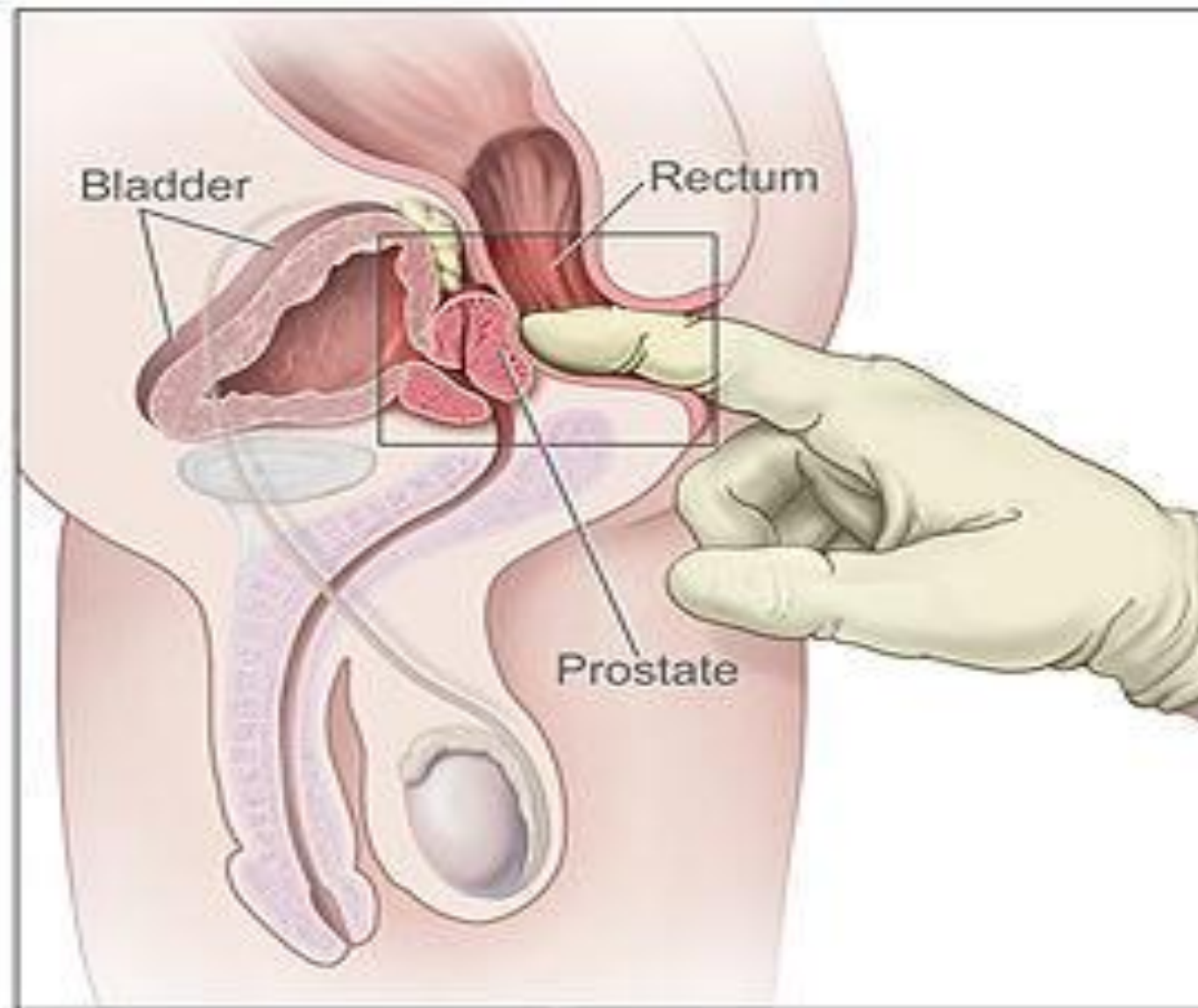
- **Roach's probability of ECE,SVI and LNI**

- $ECE+ = 3/2 \times PSA + (GS-3) \times 10$
- $SVI++ = PSA + (GS-6) \times 10$
- $LNI+ = 2/3 \times PSA + (GS-6) \times 10$

Digital Rectal Examination

- Essential element in screening and staging of prostate cancer
- Only 25-50% of men with an abnormal DRE have cancer on Biopsy.
- Sensitivity of 70% and specificity of 50%
- DRE+ PSA specificity 87%
- DRE Method: Should be done in Sim's lateral position
- Organ is palpated in craniocaudal and transverse Direction.
- look for consistency of the gland, and fixity to adjacent structures and any firm/elevated area and its size
- Typical finding of prostate cancer: Hard nodular, asymmetrical, surrounded by compressible prostatic tissue
- Prostatic induration - BHP nodule/calculi/infection/granulomatous prostatitis/infarction

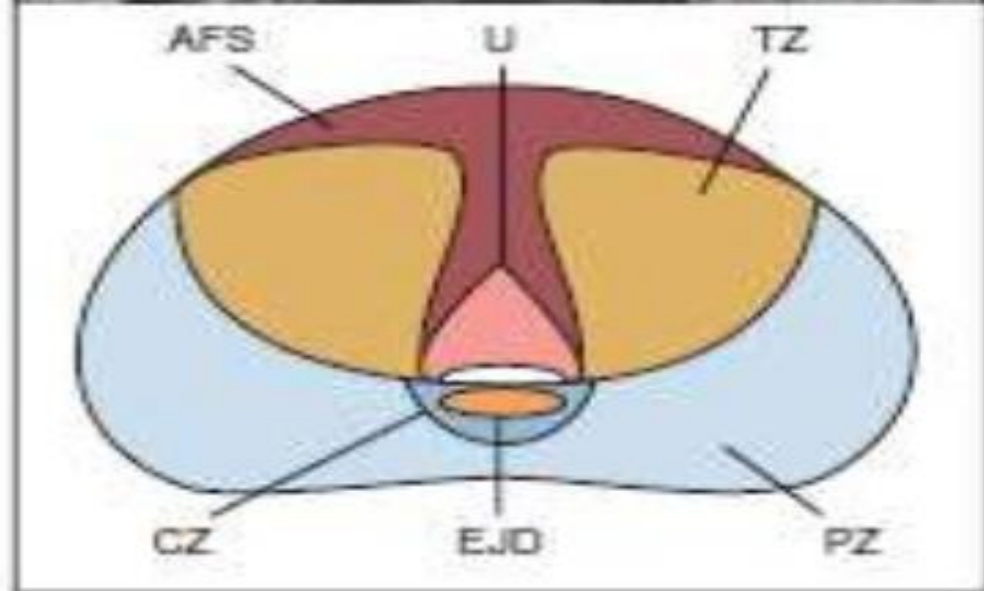
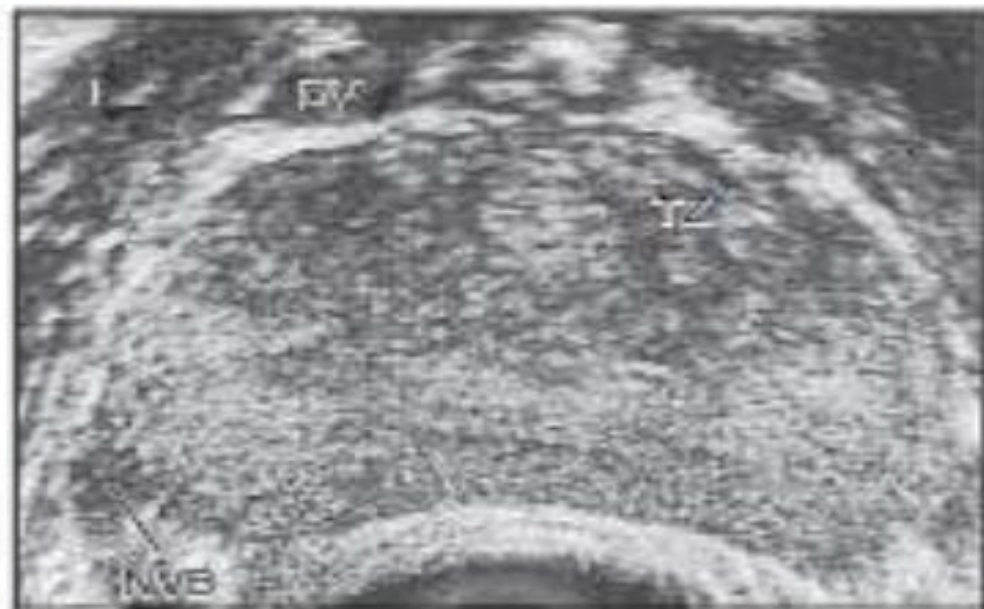
DRE



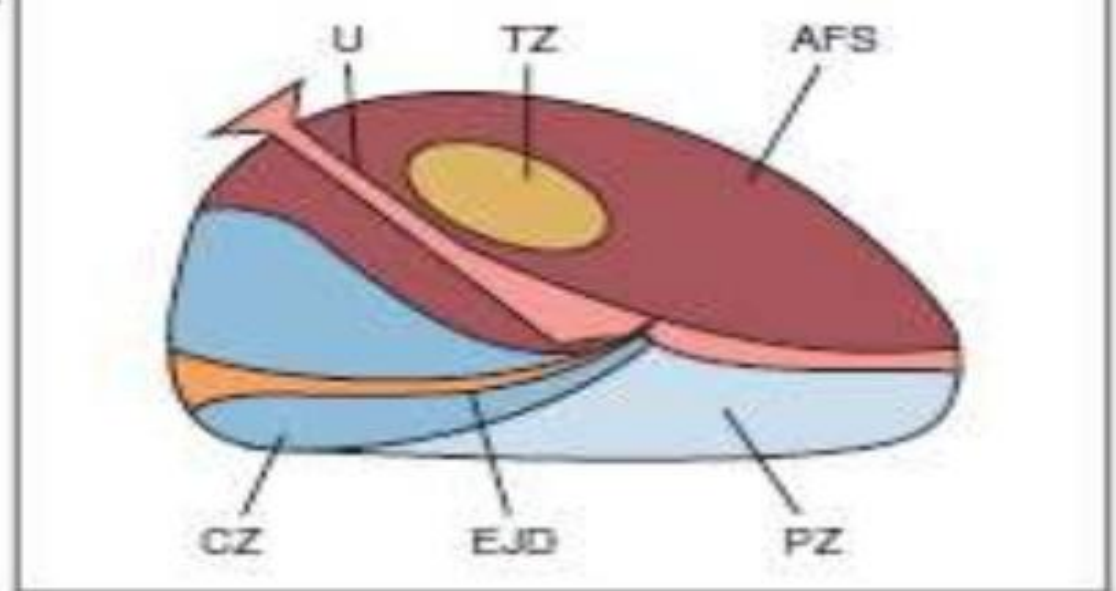
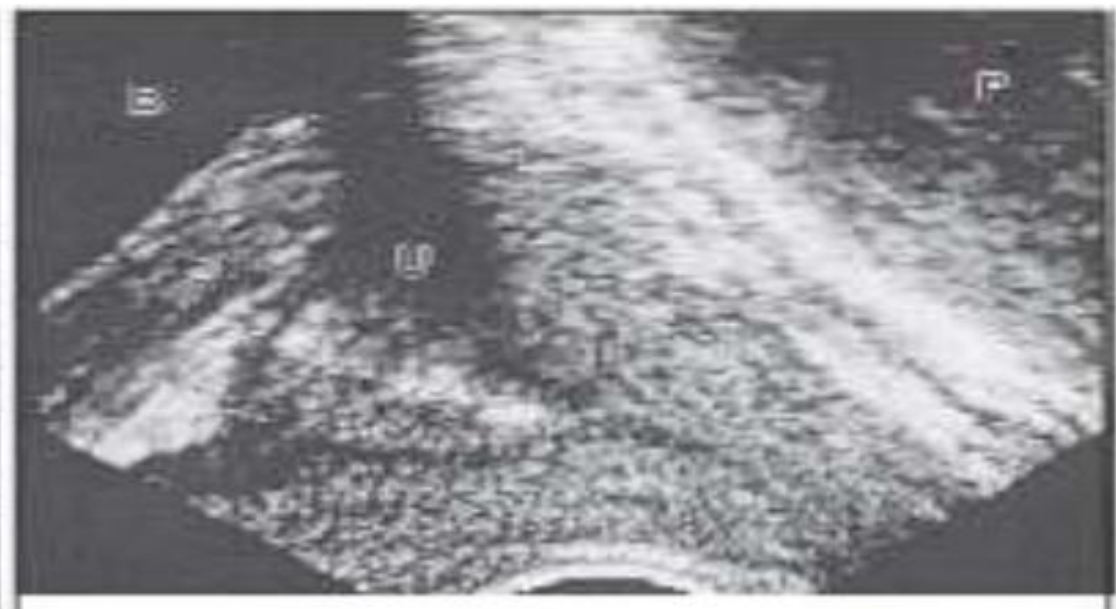Transrectal Ultrasonography and Biopsy

- TRUS of the prostate: first described by *Watanabe* et al(1968)
- TRUS Guided Systematic sextant biopsy protocol: introduced by *Hodge et al* (1989)
- Normal adult prostate imaged by TRUS appear as symmetric, triangular, relatively homogeneous structure with an echogenic capsule
- TRUS is routinely used for guidance during transrectal biopsy and prostate brachytherapy
- TRUS guided biopsy is the gold standard for prostate cancer diagnosis

TRUS

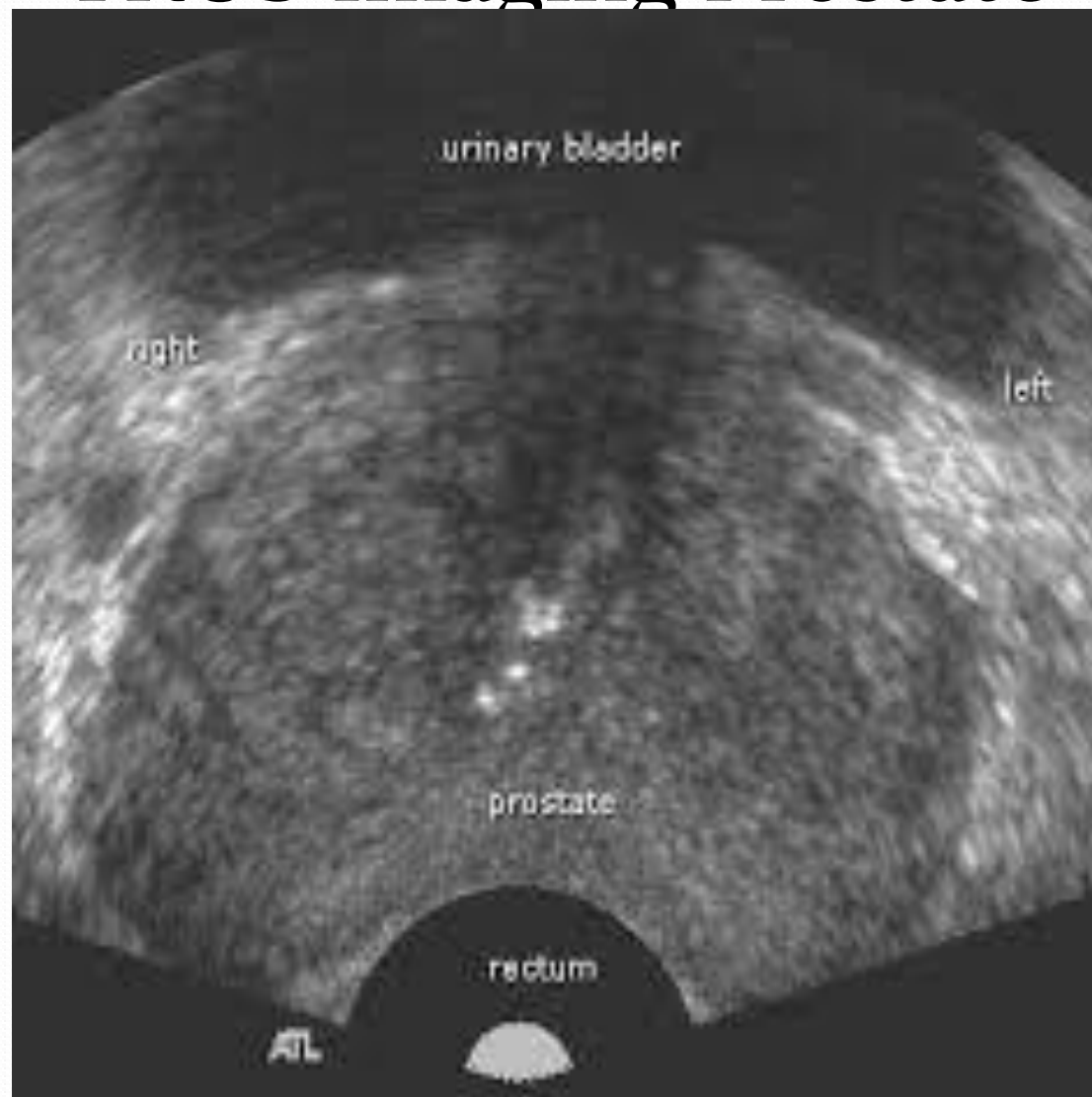


A

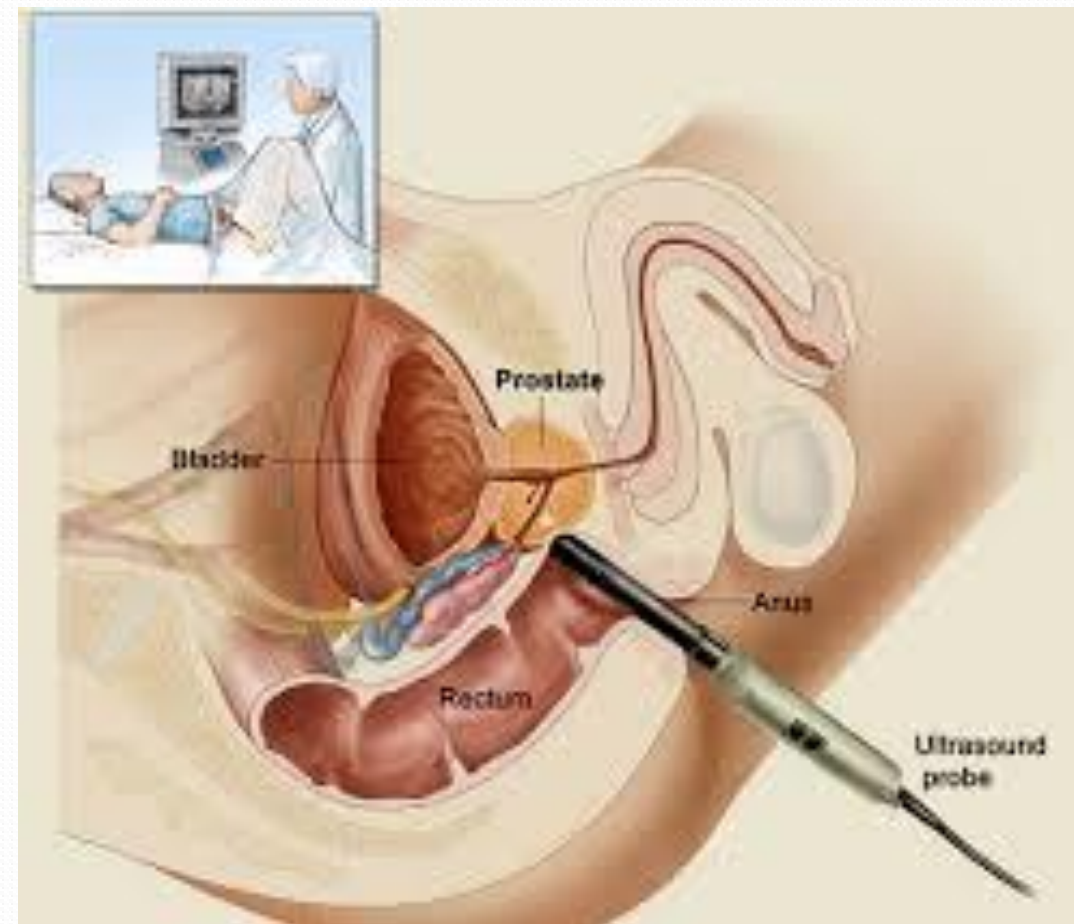


B

- TRUS Imaging Prostate

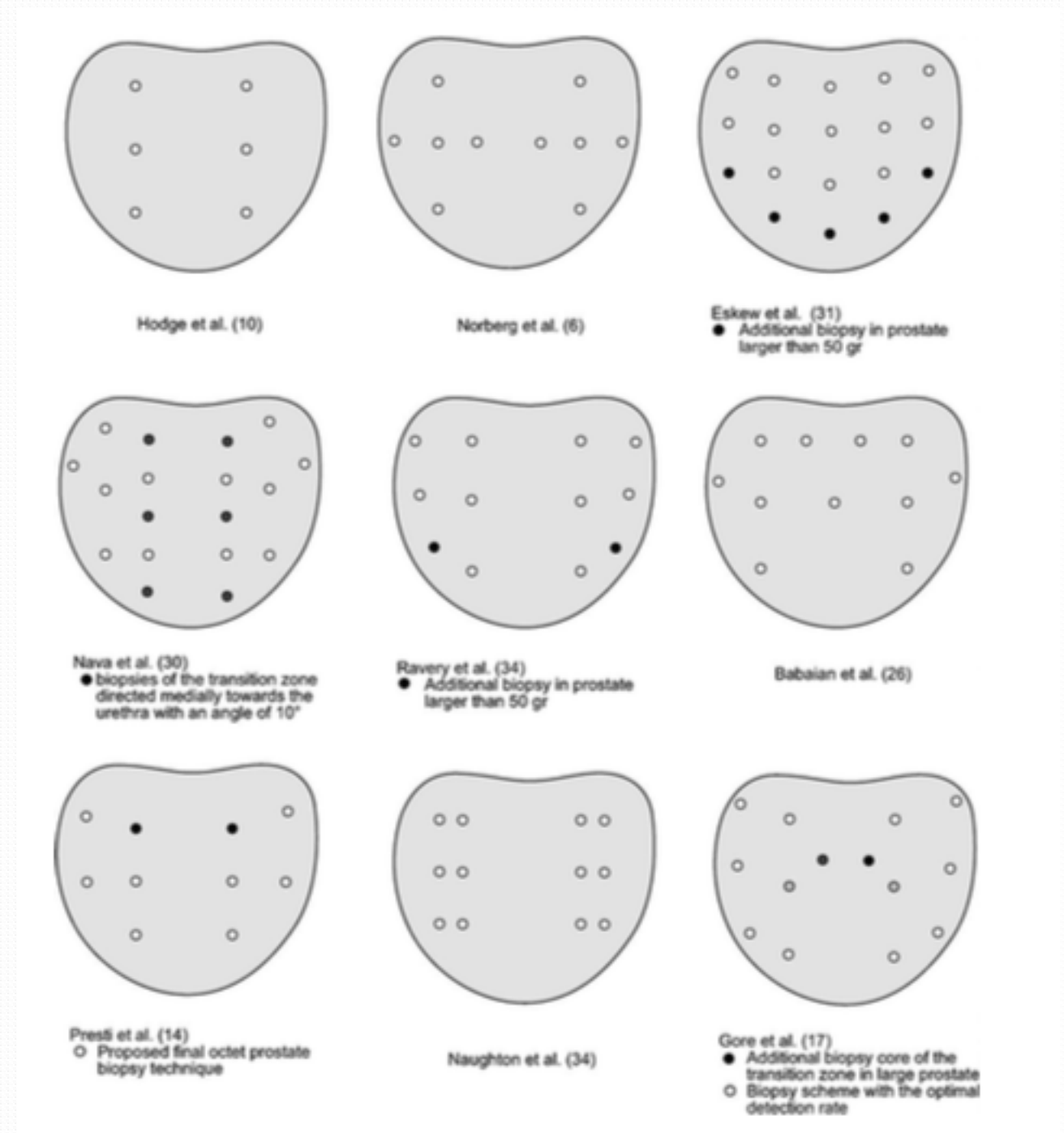


- TRUS Guided Biopsy



Prostate Biopsy

- In Early 1990s, 6 core biopsy was recommended but now 12 core biopsy is standard
- There are no “absolute” prostate biopsy guideline
- Cores from all major region of prostate should be taken so that complete geographic coverage is done
- Cores from any region of prostate that felt suspicious on DRE or TRUS should be done
- Biopsy Sites include:
 - Midlobe parasagittal plane at the apex
 - The midland
 - Base bilaterally



Gleason's Score

- ◆ Donald F. Gleason and Gleason and Mellinger proposed a prognostic classification System based on the clinical stage and the degree of differentiation of primary and secondary morphologic pattern of tumor: each graded from 1-5
- ◆ Later only pathologic features were scored resulting in Gleason score that sums grades to yield nine discrete scores
- ◆ It is one of the strongest predictors of biologic behaviour in prostate cancer, including invasiveness and metastatic potential.

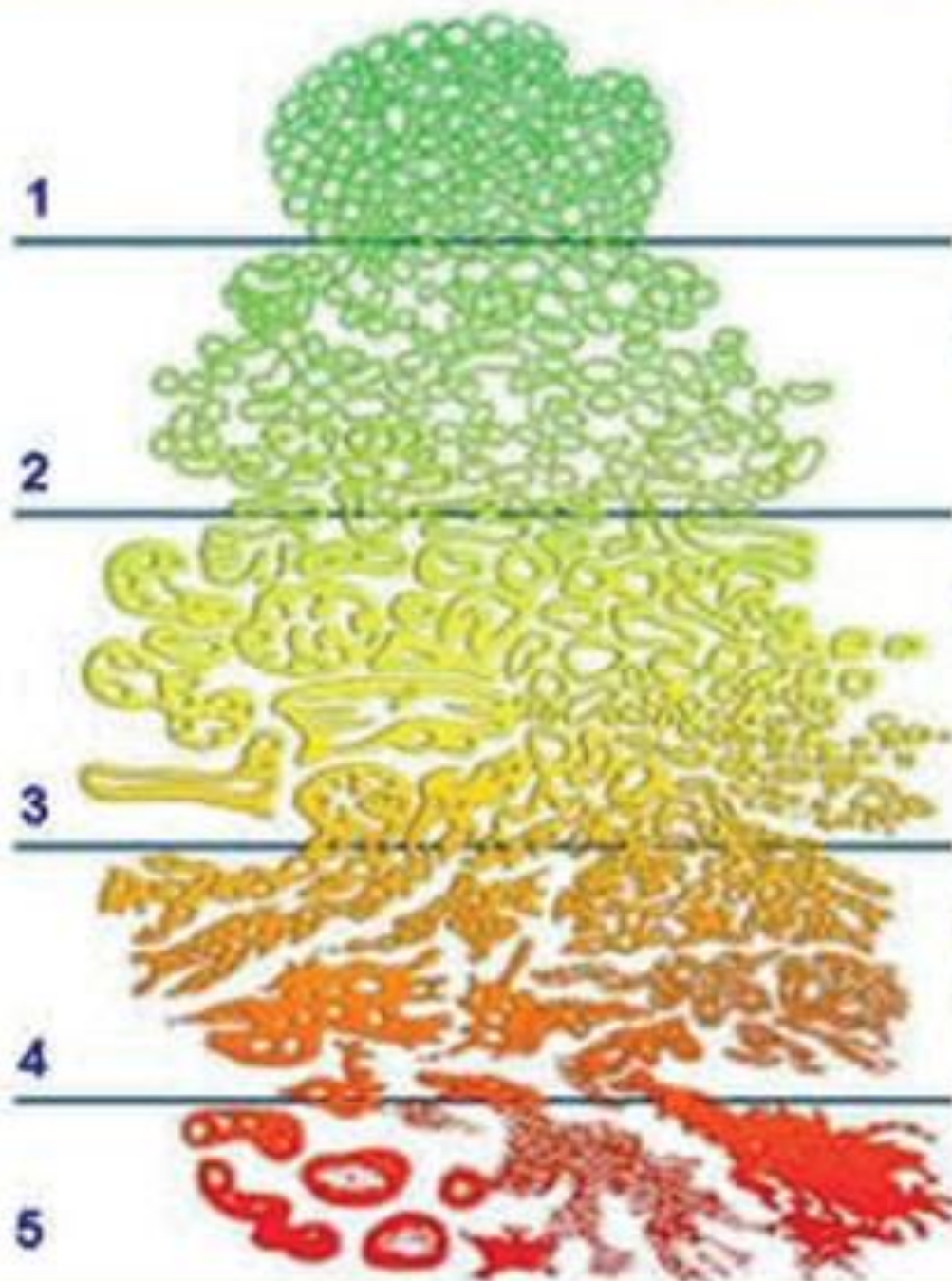
Gleason Score

- Prostate cancer has pronounced morphological heterogeneity and usually more than one histological pattern is present.
- The primary and secondary pattern, i.e. the most prevalent and second most prevalent pattern are added to obtain a Gleason score or sum
- It is recommended that the primary and secondary pattern as well as the score be reported, e.g. Gleason Score 3+4
- If the tumor has only one pattern, Gleason score is obtained by adding the sum($3+3=6$)

Grades

- Primary Grade: assigned to the dominant pattern of the tumor(has to be greater than 50% of the total pattern seen)
- Secondary Grade- assigned to the next most frequent pattern(has to be less than 50%, but at least 5% of the pattern of the total cancer observed)
- Gleason Score= predominat pattern(1-5)+ secondary pattern(1-5)
- Best score=2, worst score=10.

Gleason's Pattern Scale



1. Small, uniform glands.

2. More space (stroma) between glands.

3. Distinctly infiltration of cells from glands at margins.

4. Irregular masses of neoplastic cells with few glands.

5. Lack of or occasional glands, sheets of cells.

Well differentiated

Moderately differentiated

Poorly differentiated
Anaplastic

New Histologic Grade and Gleason Score.

TRADITIONAL GLEASON SCORE	NEW GRADING SYSTEM GROUP 1
GLEASON 3+3=6 Only individual discrete well-formed glands	GRADE 1
GLEASON 3+4=7 Predominantly well-formed glands with a lesser component of poorly-formed/fused/cribriform glands.	GRADE 2
GLEASON 4+3=7 Predominantly poorly-formed/fused/cribriform glands with a lesser component of well-formed glands.	GRADE 3
GLEASON 4+4=8 Only poorly-formed/fused/cribriform glands or -Predominantly well-formed glands with a lesser component lacking or -Predominantly lacking glands with a lesser component of well-formed glands.	GRADE 4
GLEASON 9-10 Lacks gland formation (or with necrosis) with or without poorly-formed/fused/cribriform gland.	GRADE 5

Imaging

- Chest X ray- pulmonary metastasis
- Bone Scan: For detecting bone metastases.

Computed Tomography

◆ Primary role of CT in prostate cancer is

- Size determination of prostate gland,
- radiation therapy treatment planning
- assessment of pelvic lymph node
- CT guided FNAC of LN

◆ Limitation of CT :

- CT lacks the soft tissue resolution needed to detect intraprostatic disease, capsular extension or seminal vesicle involvement.
- For most of newly diagnosed prostate cancer, the incidence of positive lymph node is <5% and thus there is little role of CT as a routine staging procedure

MRI

- ◆ MRI is superior to CT in defining the zonal anatomy, NVB, and periprostatic infiltration.
- ◆ There has been significant improvements in MR Technique and performance for imaging the prostate
- ◆ Recent advances in MRI include:
 - MP-MRI: Improves spatial resolution
 - Analytic image correction software to eliminate artifacts
 - Fast spin-echo imaging to reduce image acquisition time and provide higher signal-to- noise ratio.

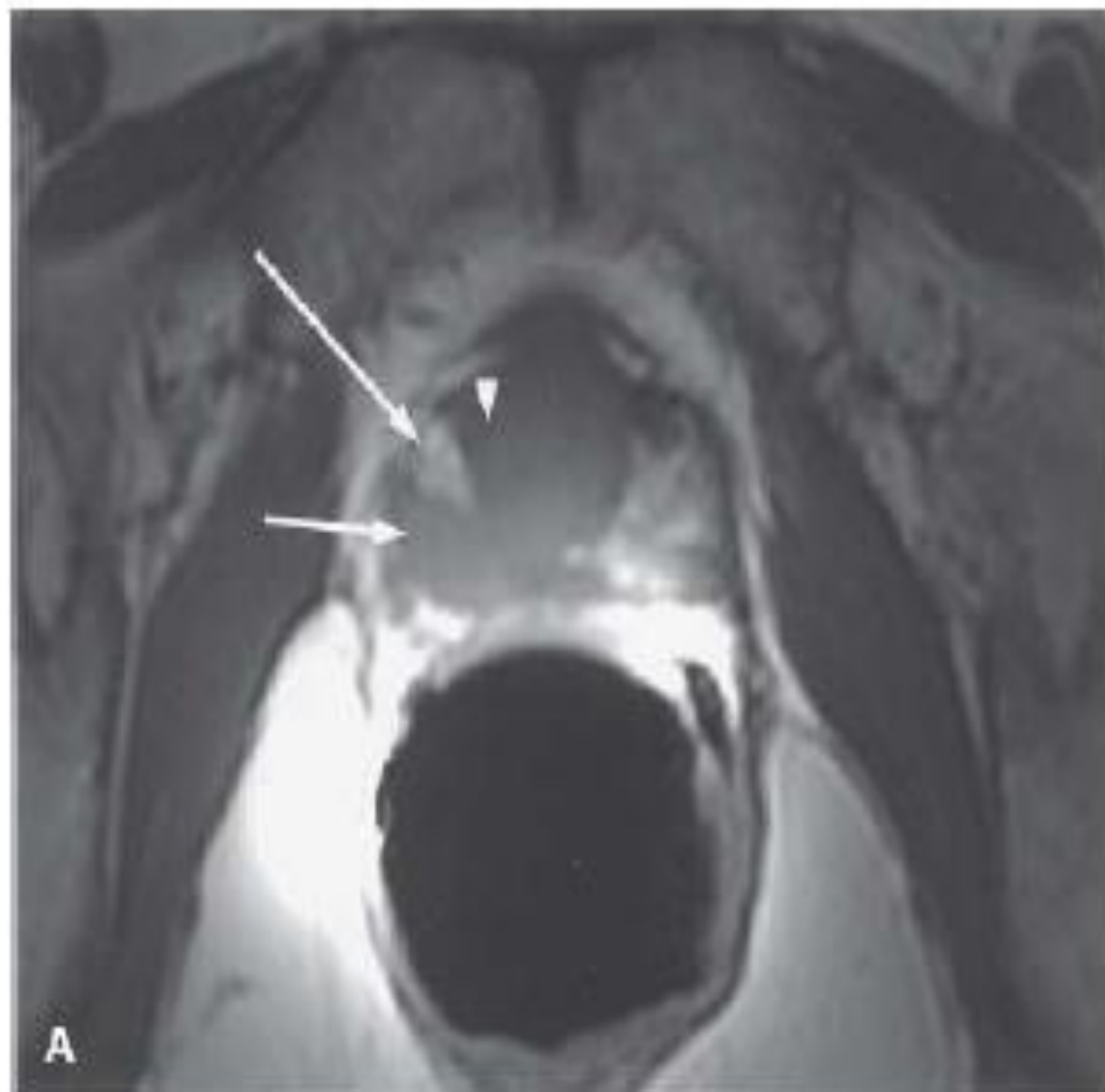
MRI

- T1-weighted images:
 - Prostate gland appears homogeneous and the zonal anatomy is not well appreciated.
 - However, there is a larger field of view, allowing for detection of locoregional adenopathy and suspected bony lesions.
 - Postbiopsy hemorrhage is evident on T1-weighted images as high T1 signal intensity, which may be in the prostate, seminal vesicles, or both.
 - This is an important observation because hemorrhage may mimic tumor on T2-weighted images and because hemorrhage greatly limits the accuracy in the assessment of extracapsular extension

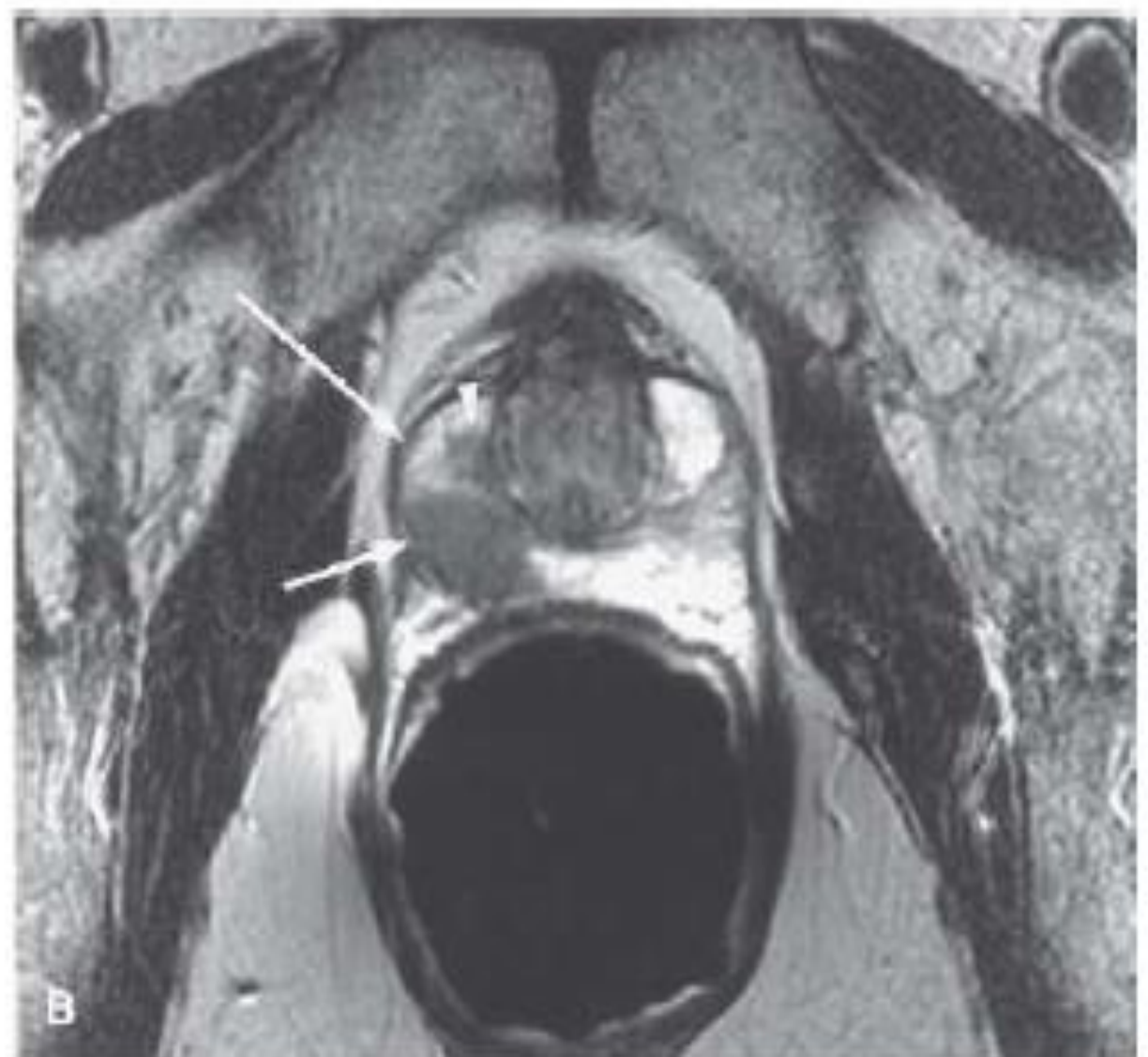
MRI

- T2 weighted images:
 - Zonal Anatomy of prostate is clearly depicted
 - The Vas deferens and seminal vesicles also clearly discernible on axial and coronal images
 - Neurovascular bundle is best seen on axial images
 - Penile bulb is best seen in coronal images
 - PZ is normally of high signal intensity and tumor appears as low signal intensity
 - Signs of extracapsular extension are a focal irregular capsular bulge, asymmetry and invasion of retroprostatic angle.

T-1 weighted image



T-2 weighted images showing prostate cancer



Magnetic Resonance Spectroscopy Imaging

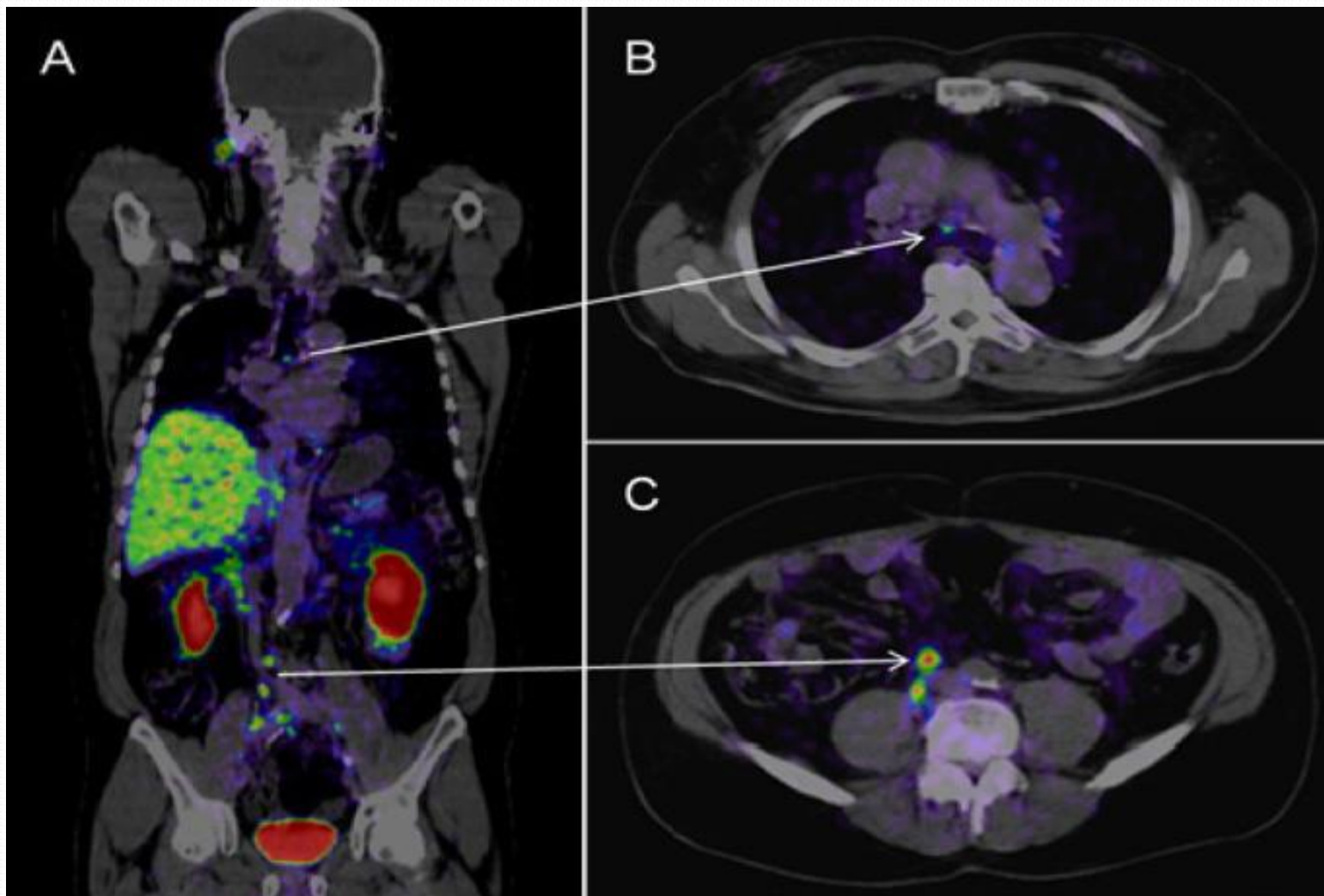
- Prostate cancer can be identified by difference in level of Citrate and Choline.
- A significant reduction in prostate citrate and significant increase in Choline level relative to normal PZ have been observed.
- Combined MRI and MRSI for tumor location has specificity of 91% and sensitivity of 95%.
- MRSI is extremely useful for:
 - accurate localization of prostate cancer
 - Distinguishing between tumor and postbiopsy hemorrhage
 - Follow up after treatment
 - Development of more focused therapy
 - May also be predictive of tumor aggressiveness

PSMA PET(Prostate specific membrane antigen PET)

- Done in newly diagnosed case to know the extent of disease
- The most updated guideline released by European Association of Urology suggests its use in any case of biochemical recurrence post prostatectomy(PSA level>0.2ng/ml)
- PSMA is a membrane glycoprotein upregulated on prostate cancer.
- It has been seen that this upregulation is present in 90-100% of prostate cancer cells making PSMA a reliable tissue biomarker for PCa functional imaging.
- This expression increases with tumor aggressiveness, androgen independence, metastatic disease and disease recurrence.

- ^{68}Ga -PSMA PET, Gallium 68 is the radioactive carrier and PSMA 11 is the small molecule that binds to the receptor
- PSMA PET has a high sensitivity and specificity compared to conventional imaging and thus can identify lesions as small as 3mm which may remain unidentified on conventional imaging.
- As the radiotracer is taken up by the prostate cancer, the tumor cells light up on scan and allow us to identify the disease
- PSMA is also an excellent theragnostic agent offering the possibility to highlight Pca by PET/CT imaging and subsequently to irradiate metastatic site with personalized doses by use of high energy beta or alpha particle emitters

PSMA PET Imaging



Images from a Ga-68 PSMA PET-CT in a man with prostate cancer shows tumors in lymph nodes in the chest and abdomen. Adapted from Int J Mol Sci. July 2013.

Staging and risk Stratification

AJCC Prostate Cancer Prognostic Stage Groups

(8th edition, 2017)

When T is...	And N is...	And M is...	And PSA is...	And Grade Group is...	Then the stage group is...
cT1a-c, cT2a	N0	M0	<10	1	I
pT2	N0	M0	<10	1	I
cT1a-c, cT2a	N0	M0	≥10 <20	1	IIA
cT2b-c	N0	M0	<20	1	IIA
T1-2	N0	M0	<20	2	IIB
T1-2	N0	M0	<20	3	IIC
T1-2	N0	M0	<20	4	IIC
T1-2	N0	M0	≥20	1-4	IIIA
T3-4	N0	M0	Any	1-4	IIIB
Any T	N0	M0	Any	5	IIIC
Any T	N1	M0	Any	Any	IVA
Any T	Any N	M1	Any	Any	IVB

NOTE: When either PSA or Grade Group is not available, grouping should be determined by T category and/or either PSA or Grade Group as available.

Risk Stratification

- Depends on Stage
- PSA
- Gleason's Score

ESMO Guideline for risk stratification

- Low Risk: T₁-T_{2a} and gleason score ≤ 6 and PSA ≤ 10
- Intermediate risk: T_{2b} and /or Gleason score 7 and or PSA 10-20
- High Risk: \geq T_{2c} or Gleason score 8-10, or PSA > 20

D'Amico risk stratification of Prostate cancer

	PSA ng/mL	Gleason sum	Clinical stage
Low risk	≤ 10	≤ 6	$\leq T2a$
Intermediate risk	10–20	7	T2b
High risk	≥ 20	8–10	$\geq T2c$

TABLE. Risk Stratification and Staging Workup of Prostate Cancer¹

Risk Group	Clinical/Pathologic Features	Imaging	Molecular Testing of Tumor	Genetic Testing of Tumor
Very low	All of the following: <ul style="list-style-type: none">• T1c• Gleason score ≤6/grade group 1• PSA <10ng/mL• <3 prostate biopsy fragments/cores positive, ≤50% cancer in each fragment/core• PSA density <0.15 ng/mL/g	Not indicated	Not indicated	Consider if there's a strong family history
Low	All of the following: <ul style="list-style-type: none">• T1-T2a• Gleason score ≤6/grade group 1• PSA <10ng/mL	Not indicated	Consider if life expectancy is ≥10 years	Consider if there's a strong family history
Intermediate-favorable	Any of the following: <ul style="list-style-type: none">• T2b-T2c• Gleason score 3+4=7/grade group 2• PSA 10-20 ng/mL PLUS percentage of positive biopsy cores <50%	<ul style="list-style-type: none">• Bone imaging: not recommended for staging• Pelvic ± abdominal imaging: recommended if nomogram predicts >10% probability of pelvic lymph node involvement	Consider if life expectancy is ≥10 years	Consider if there's a strong family history
Intermediate-unfavorable	Any of the following: <ul style="list-style-type: none">• T2b-T2c• Gleason score 3+4=7/grade group 2 or Gleason score 4+3=7/grade group 3• PSA 10-20 ng/mL	<ul style="list-style-type: none">• Bone imaging: recommended if T2 and PSA >10 ng/mL• Pelvic ± abdominal imaging: recommended if nomogram predicts >10% probability of pelvic lymph node involvement	Not routinely recommended	Consider if there's a strong family history
High	Any of the following: <ul style="list-style-type: none">• T3a• Gleason score 8/grade group 4 or Gleason score 4+5=9/grade group 5• PSA >20 ng/mL	<ul style="list-style-type: none">• Bone imaging: recommended• Pelvic ± abdominal imaging: recommended if nomogram predicts >10% probability of pelvic lymph node involvement	Not routinely recommended	Consider
Very high	Any of the following: <ul style="list-style-type: none">• T3b-T4• Primary Gleason pattern 5• >4 cores with Gleason core 8-10/grade group 4 or 5	<ul style="list-style-type: none">• Bone imaging: recommended• Pelvic ± abdominal imaging: recommended if nomogram predicts >10% probability of pelvic lymph node involvement	Not routinely recommended	Consider
Regional	Any T, N1, M0	Already performed	Consider tumor testing for: <ul style="list-style-type: none">• homologous recombination gene mutations• MSI/dMMR	Consider
Metastatic	Any T, any N, M1	Already performed	Consider tumor testing for: <ul style="list-style-type: none">• homologous recombination gene mutations• MSI/dMMR	Consider

dMMR indicates mismatch repair deficiency; MSI, microsatellite instability; PSA, prostate-specific antigen.

Summary

- Prostate cancer is the leading cause of cancer among male worldwide with median age of onset at 68 yrs.
- PSA along with DRE aid in screening of prostate cancer
- TRUS Guided Biopsy remains the gold standard for diagnosing prostate cancer
- MRI with MRSI help in staging local disease.
- PSMA PET has a significant role in initial staging, detecting the recurrence in case of biochemical failure post radical prostatectomy, and in follow up.



Thank You