



# RADIOLOGY OF PELVIS IN LIGHT OF GENITOURINARY MALIGNANCIES

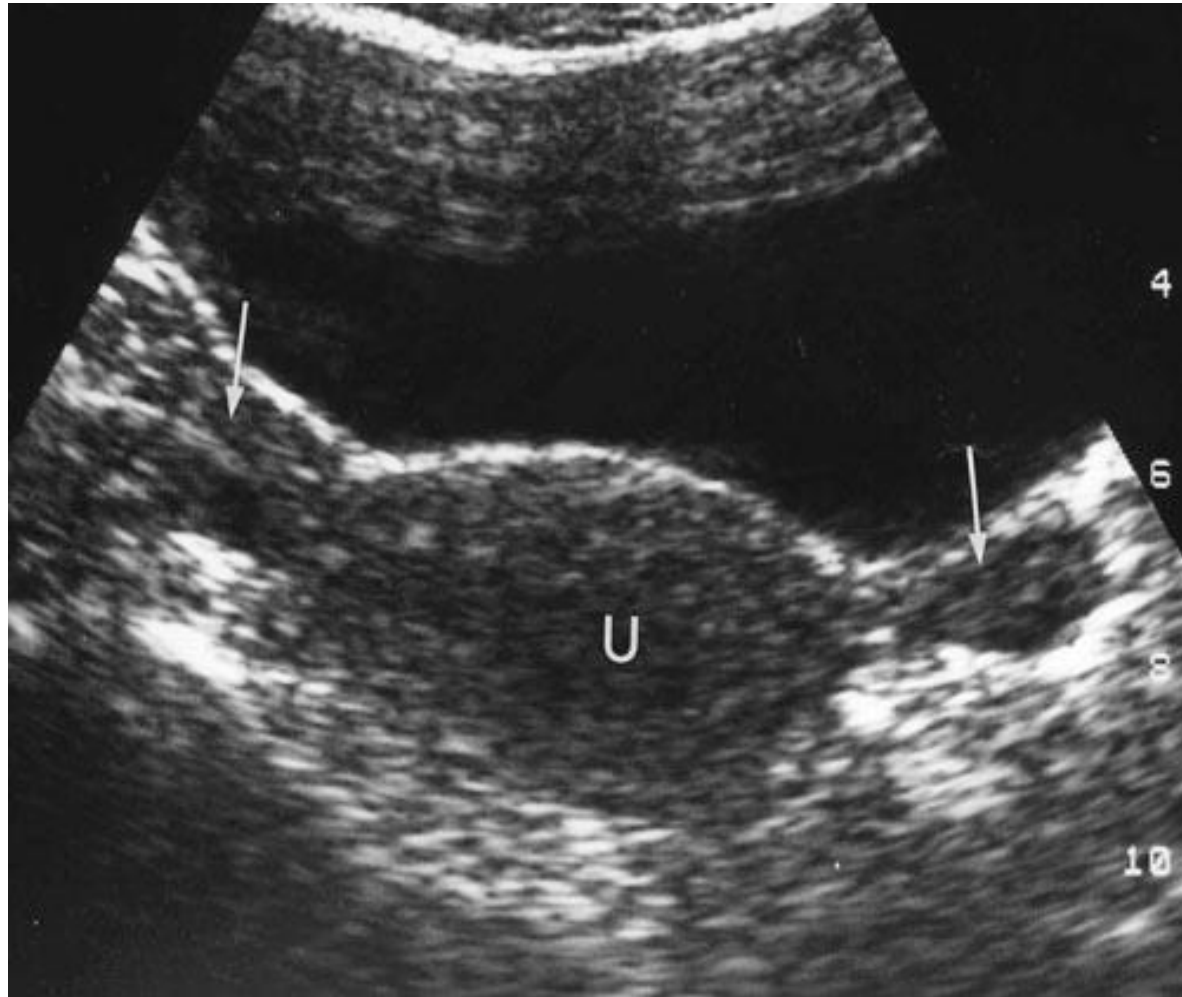


**Dr Pankaj Sharma**

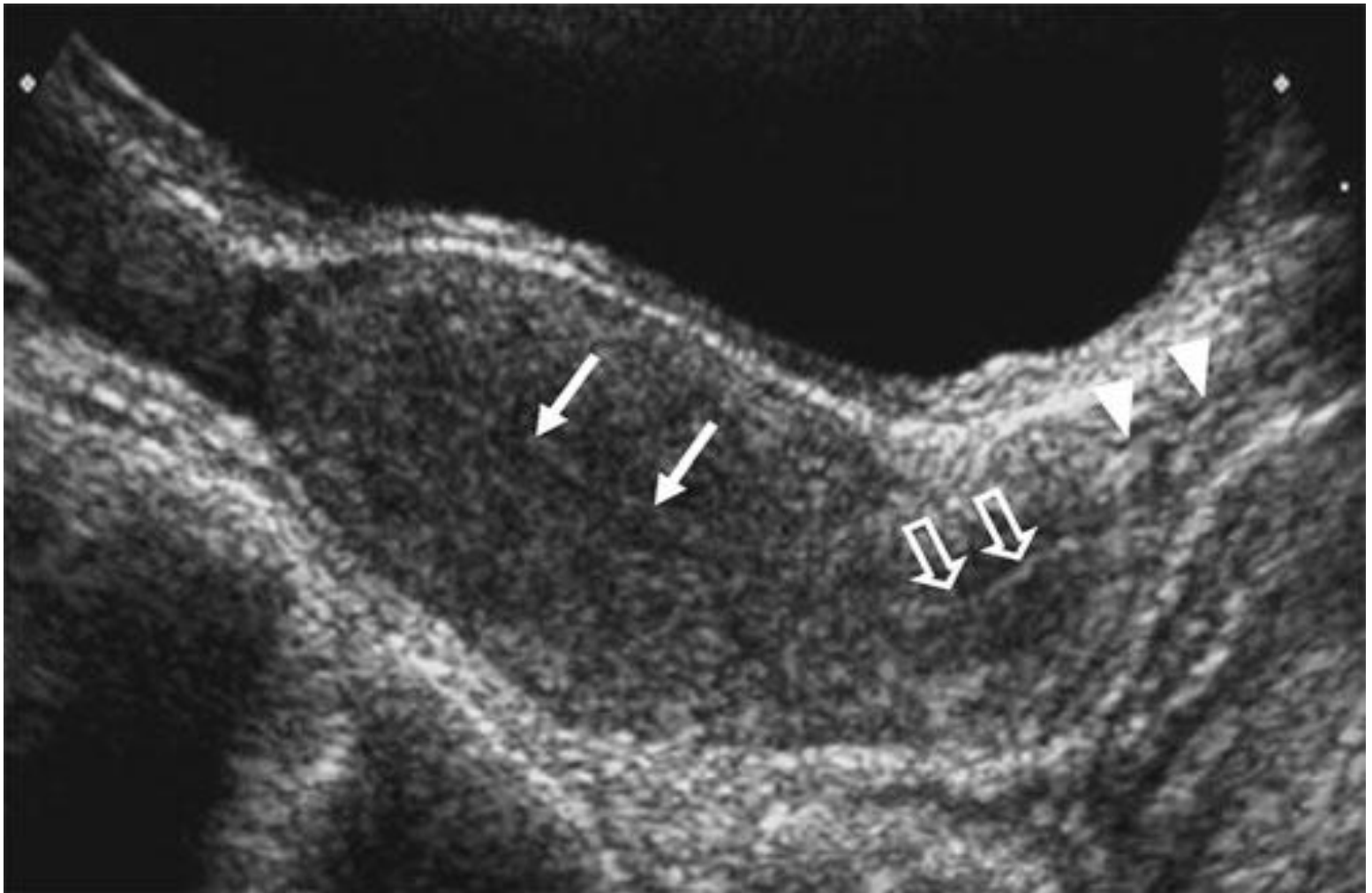
**Associate Professor, Department of Radiodiagnosis  
and Imaging, AIIMS Rishikesh**

**FEMALE**

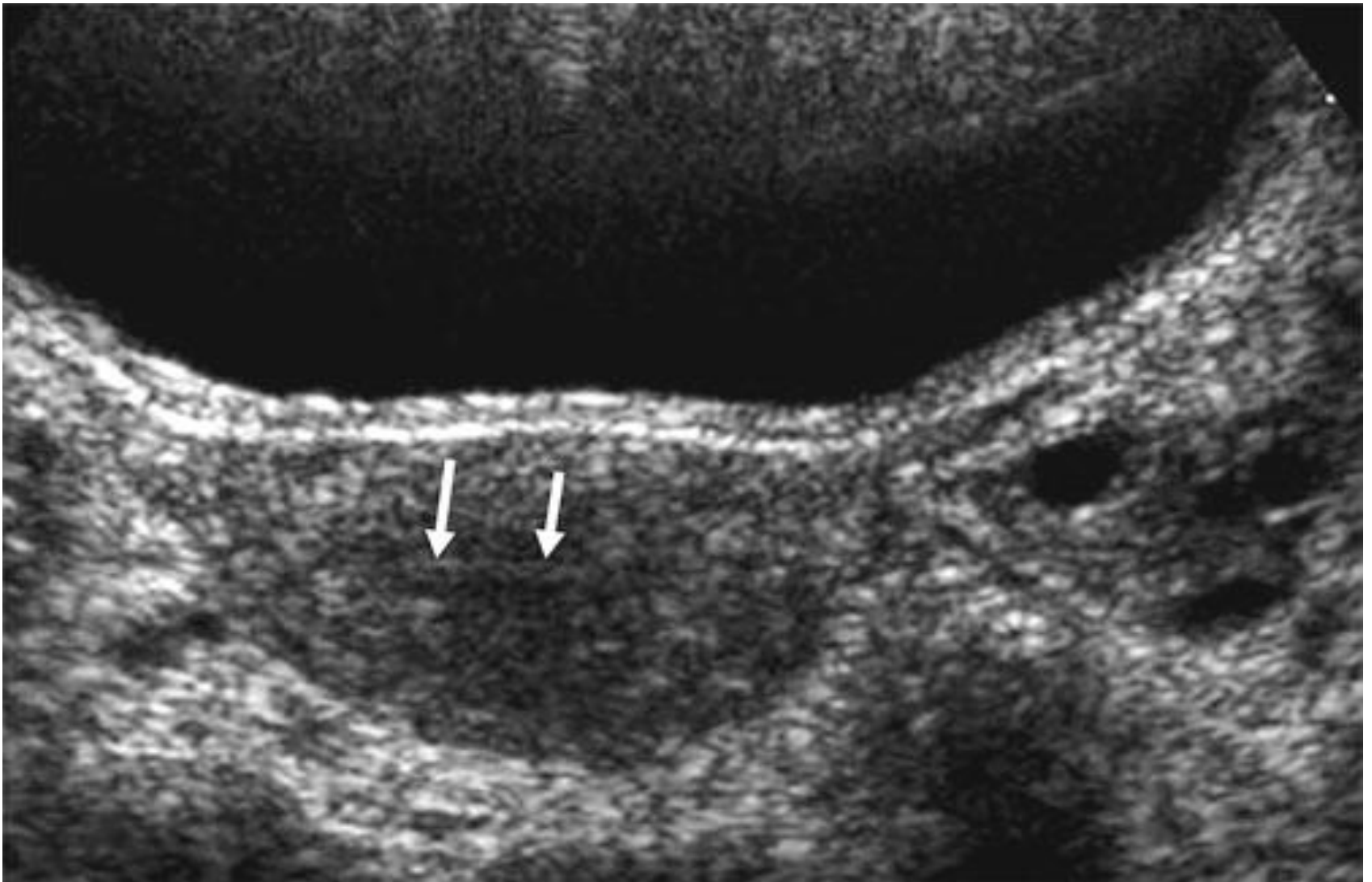
# Transabdominal Ultrasound



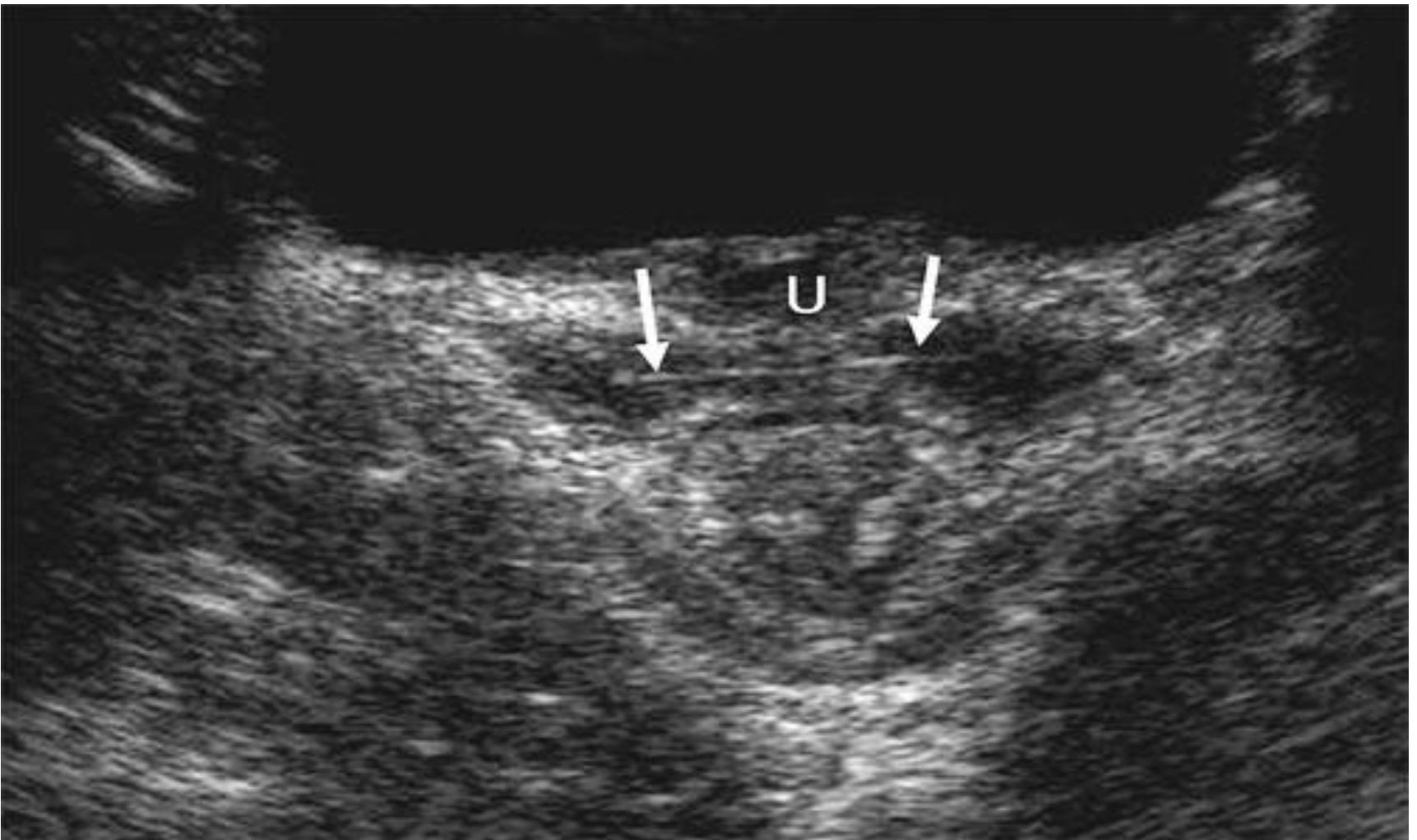
The US of the pelvis in the transverse plane shows a normal uterus ( *U* ) and ovaries ( *arrows* )



Longitudinal US of the uterus shows a pear-shaped uterus with homogeneous medium-level echogenicity of the myometrium and a thin echogenic line of the endometrium (*arrows*), which is continuous with an echogenic line of the mucosa in uterine cervix (*open arrows*) and that of the vagina (*arrowheads*).

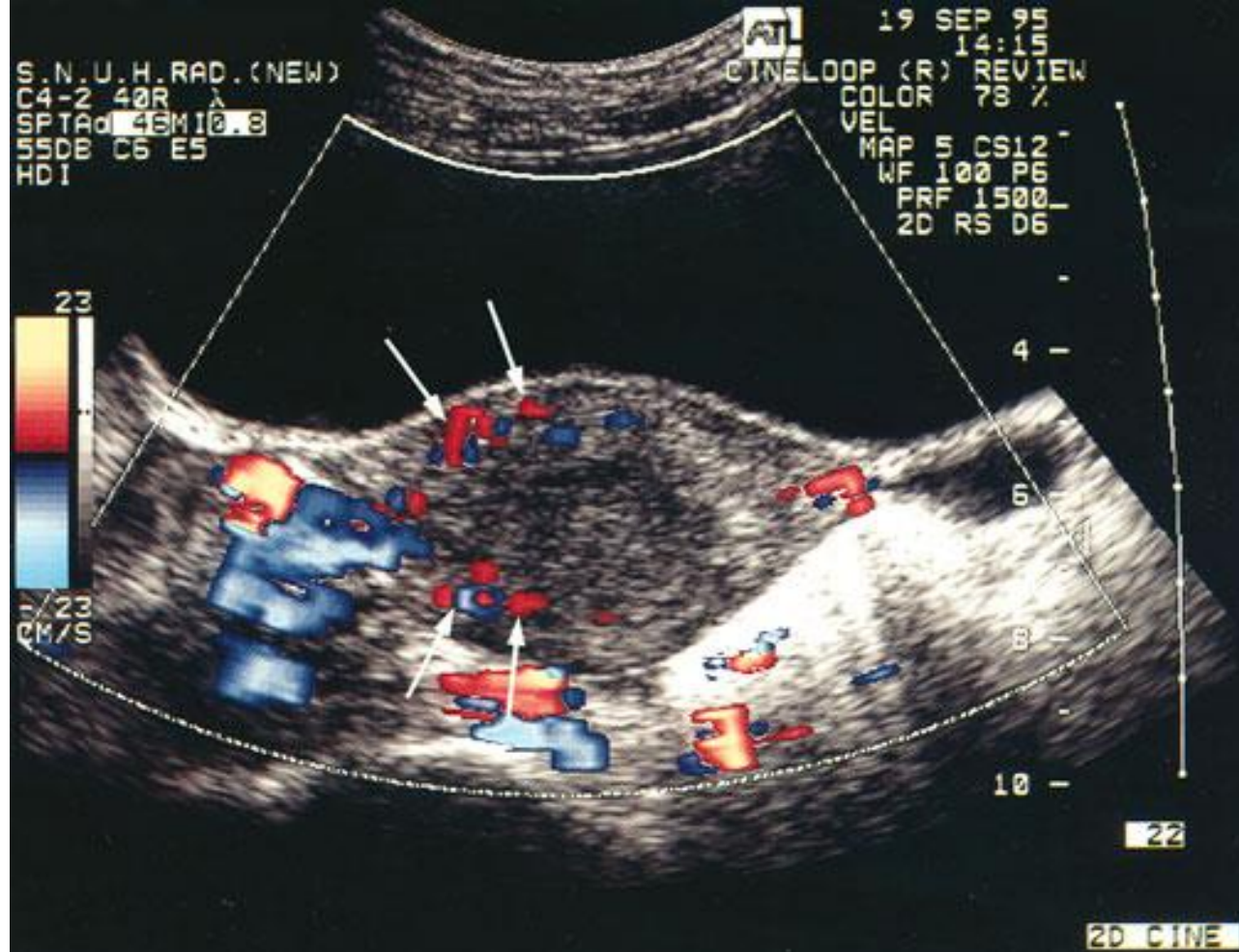


Transverse US of the uterus shows the midline location of the uterus with a transversely oriented echogenic endometrial line ( *arrows* ). The left ovary with small follicles is located in the left adnexa.

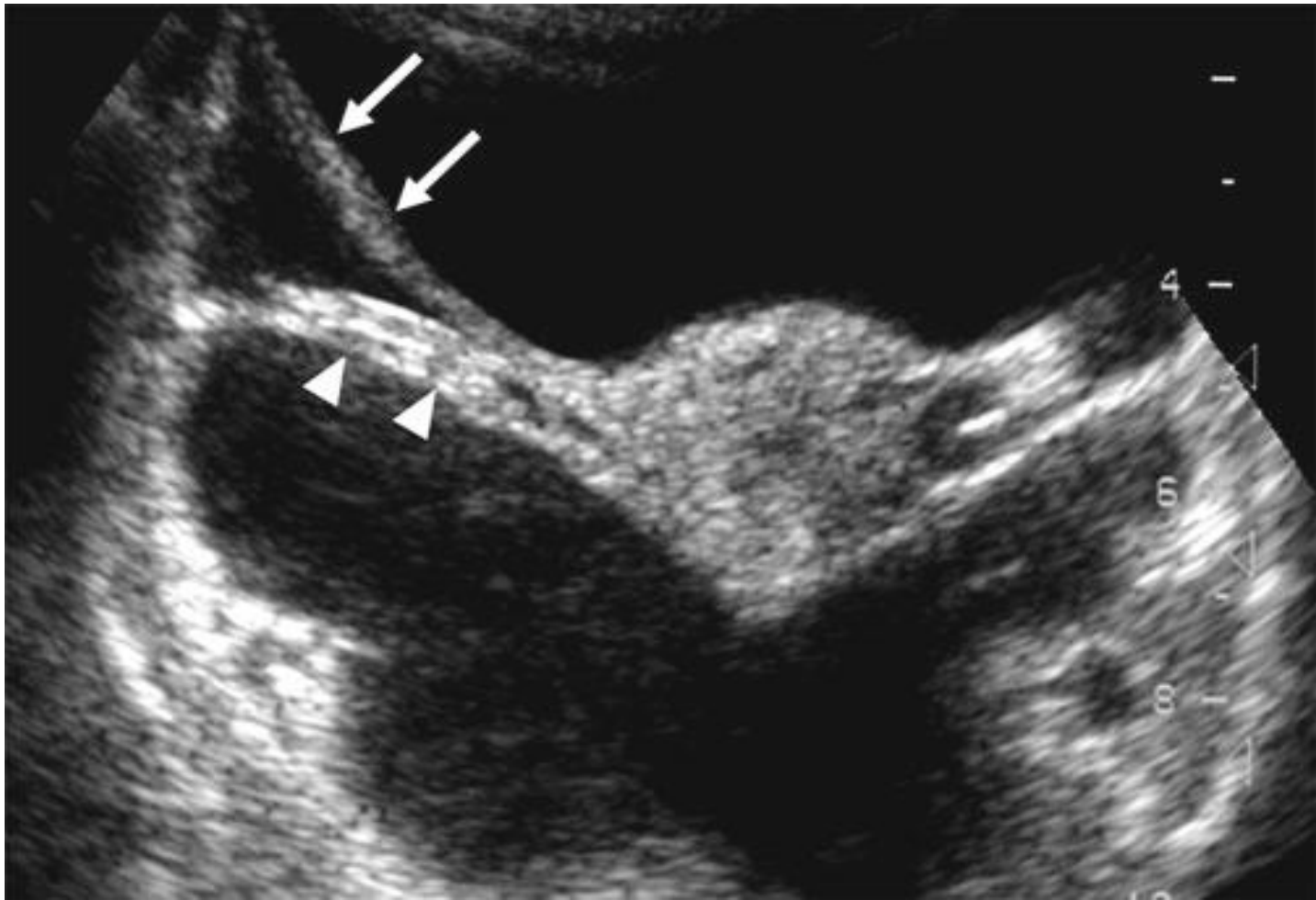


Transverse US of the vagina shows a transversely oriented vagina with the central linear echogenic mucosa ( *arrows* ) located between the urethra ( *U* ) and rectum ( *R* )



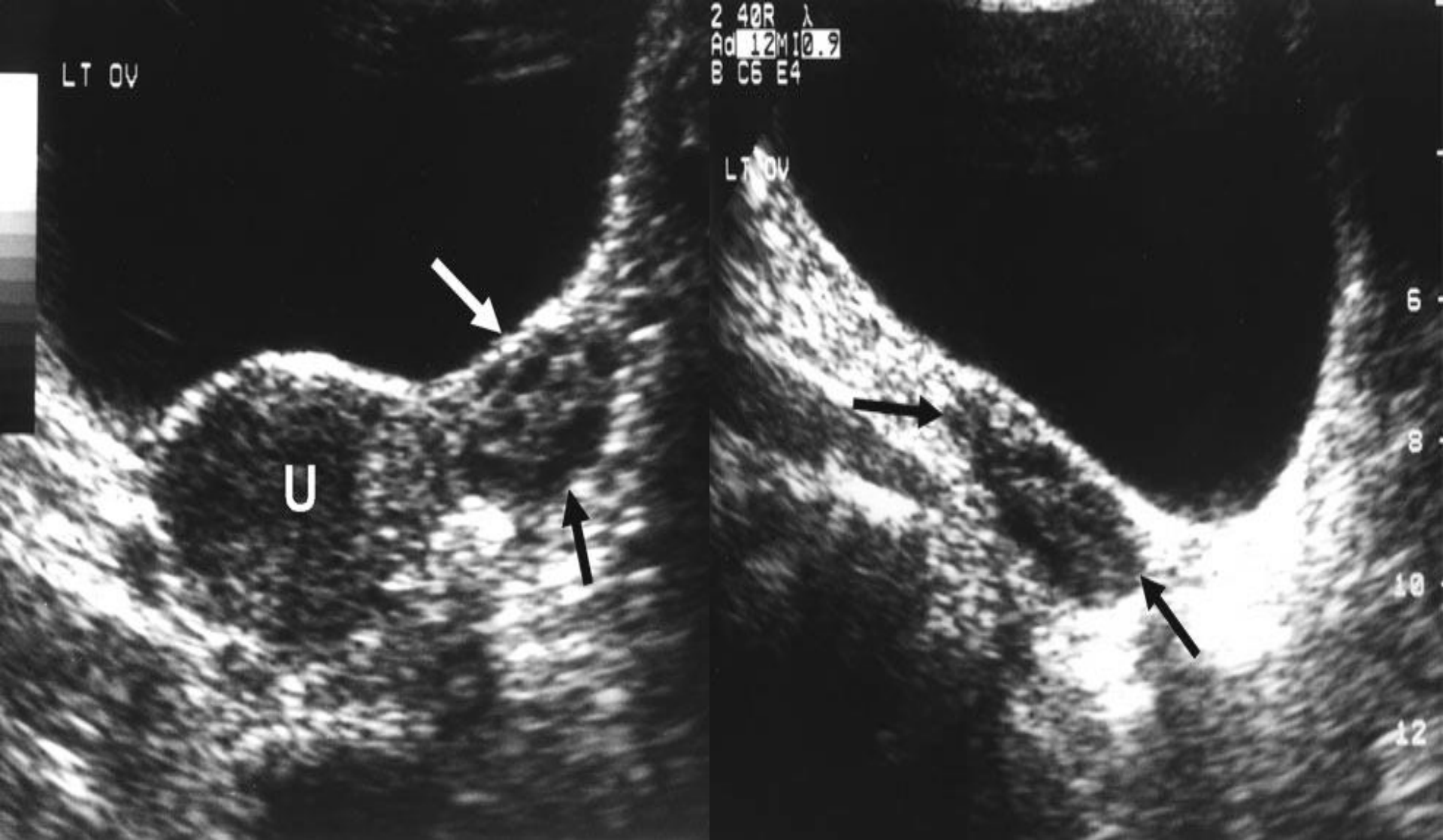


Color Doppler US findings of the normal uterus in the axial plane shows flow signals from the uterine vessels, which are more prominent on the right side. Note the arcuate vessels (*arrows*) along the outer one third of the myometrium

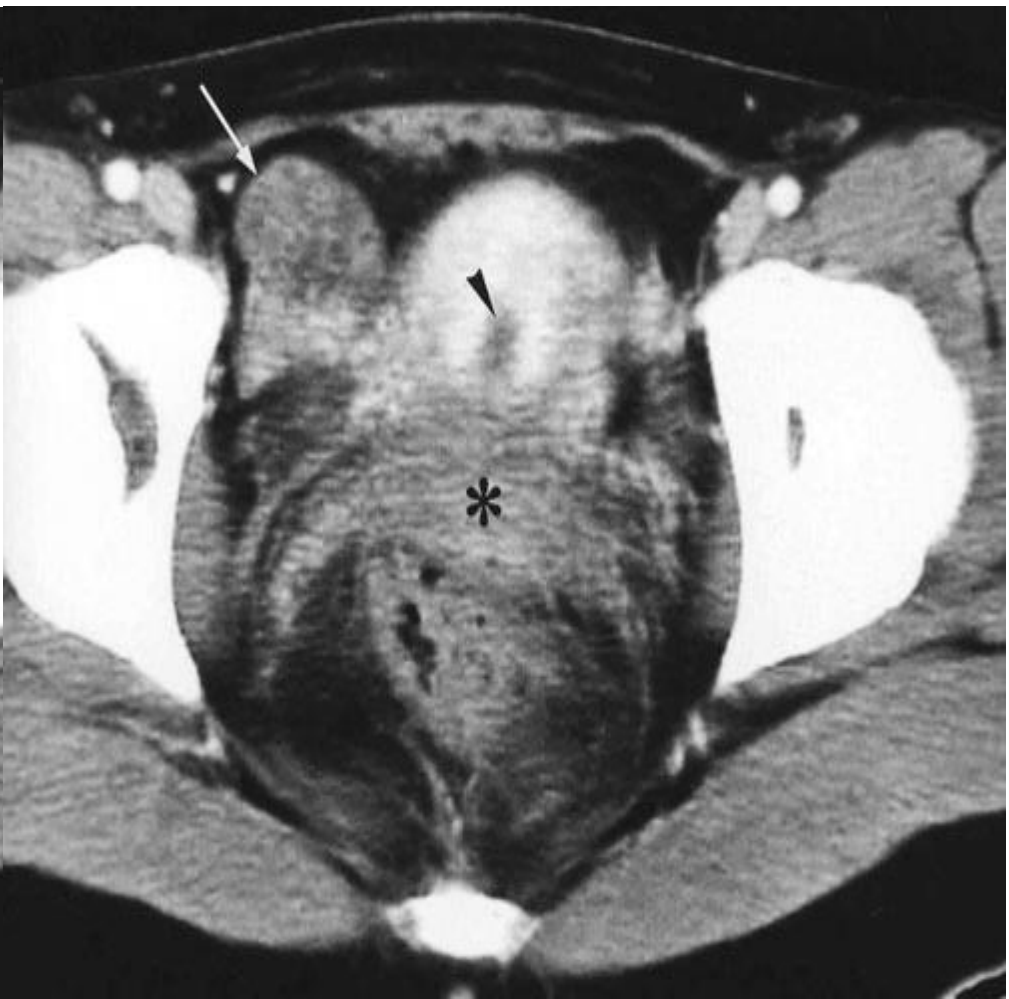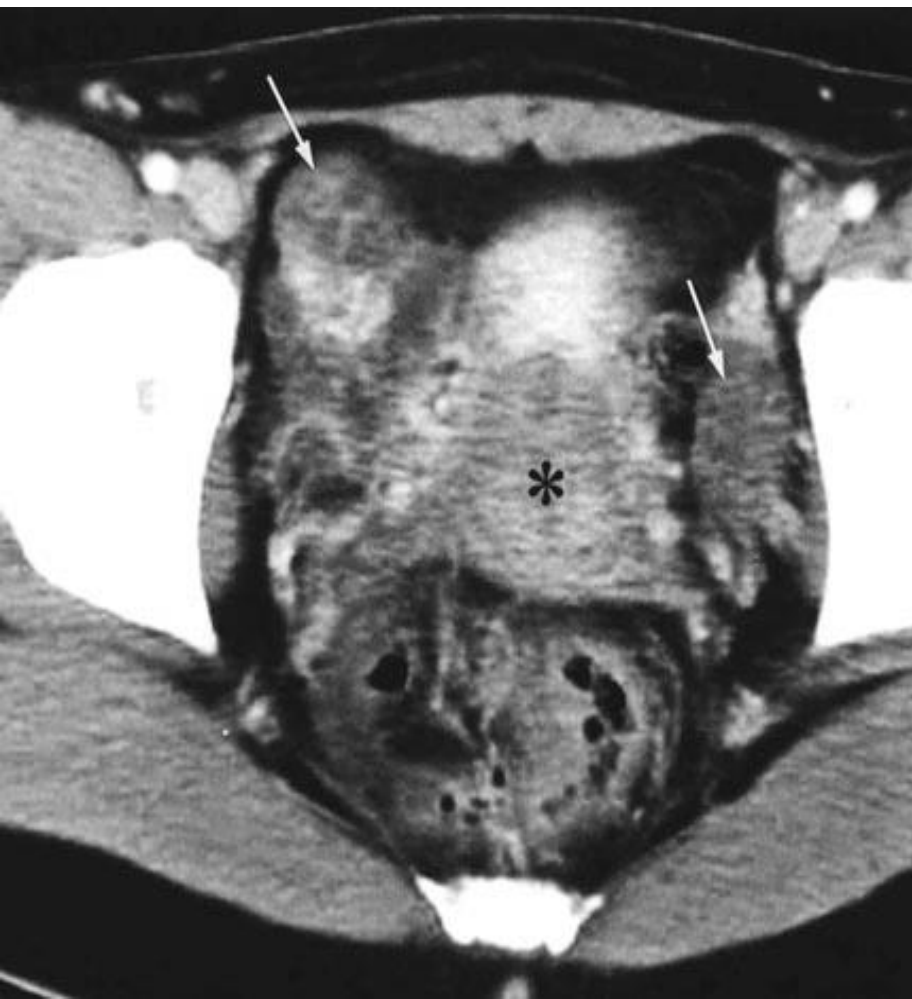


Uterine ligaments demonstrated on US of the pelvis in the transverse plane shows uterus suspended in the ascites by the broad ligament (*arrows*) and infundibulo-pelvic ligament (*arrowheads*) containing ovarian vessels





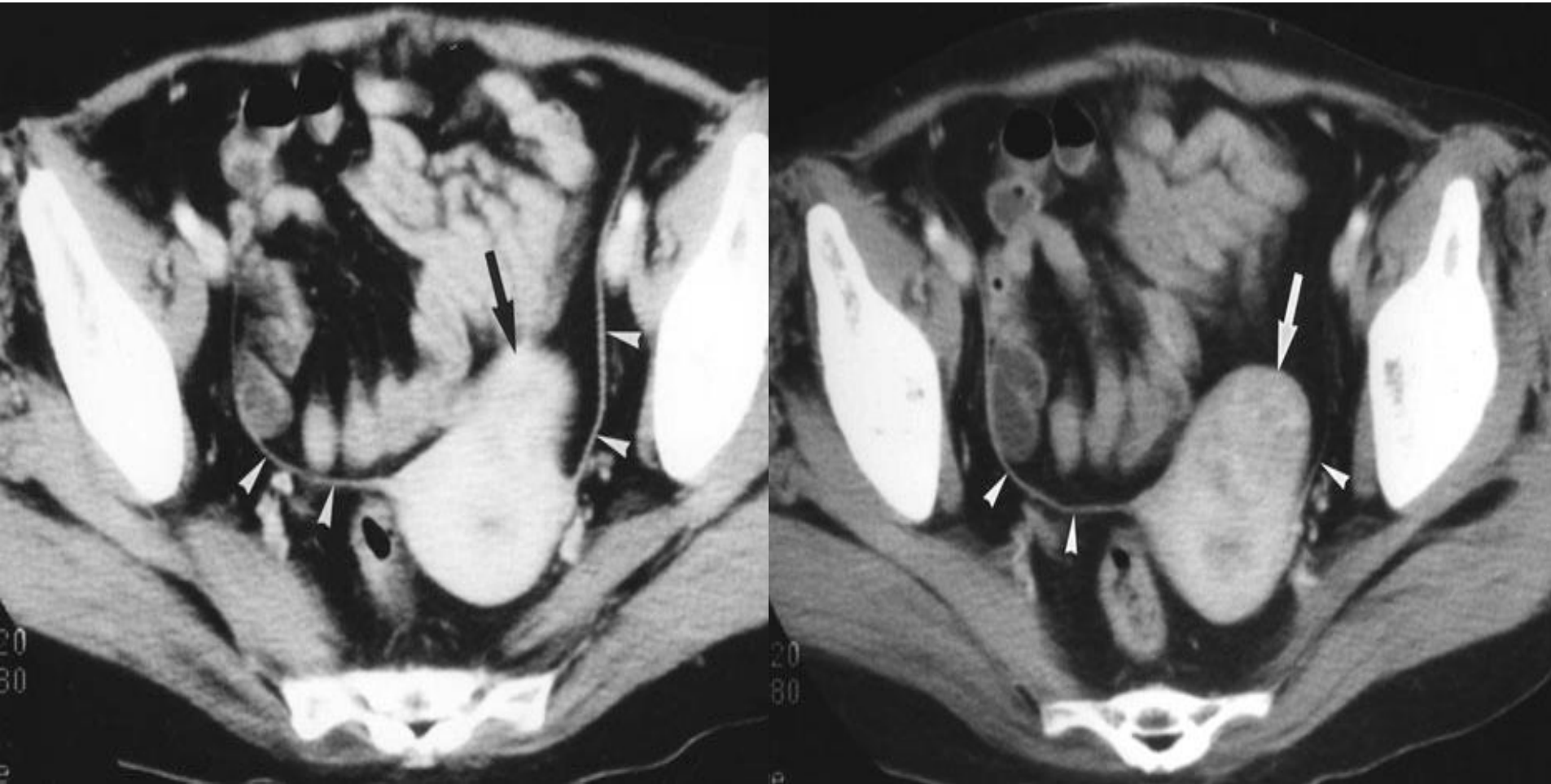
US findings of the normal ovary in transabdominal US of the pelvis in transverse (**A**) and longitudinal (**B**) planes show an ellipsoid ovary (*arrows*) containing multiple, small, anechoic follicles in the left adnexa.



Normal enhancement of the uterine cervix on contrast enhanced CT.  
(**A** and **B**) Note the low attenuated endometrium (*arrowhead*).  
*Arrows* indicate ovaries

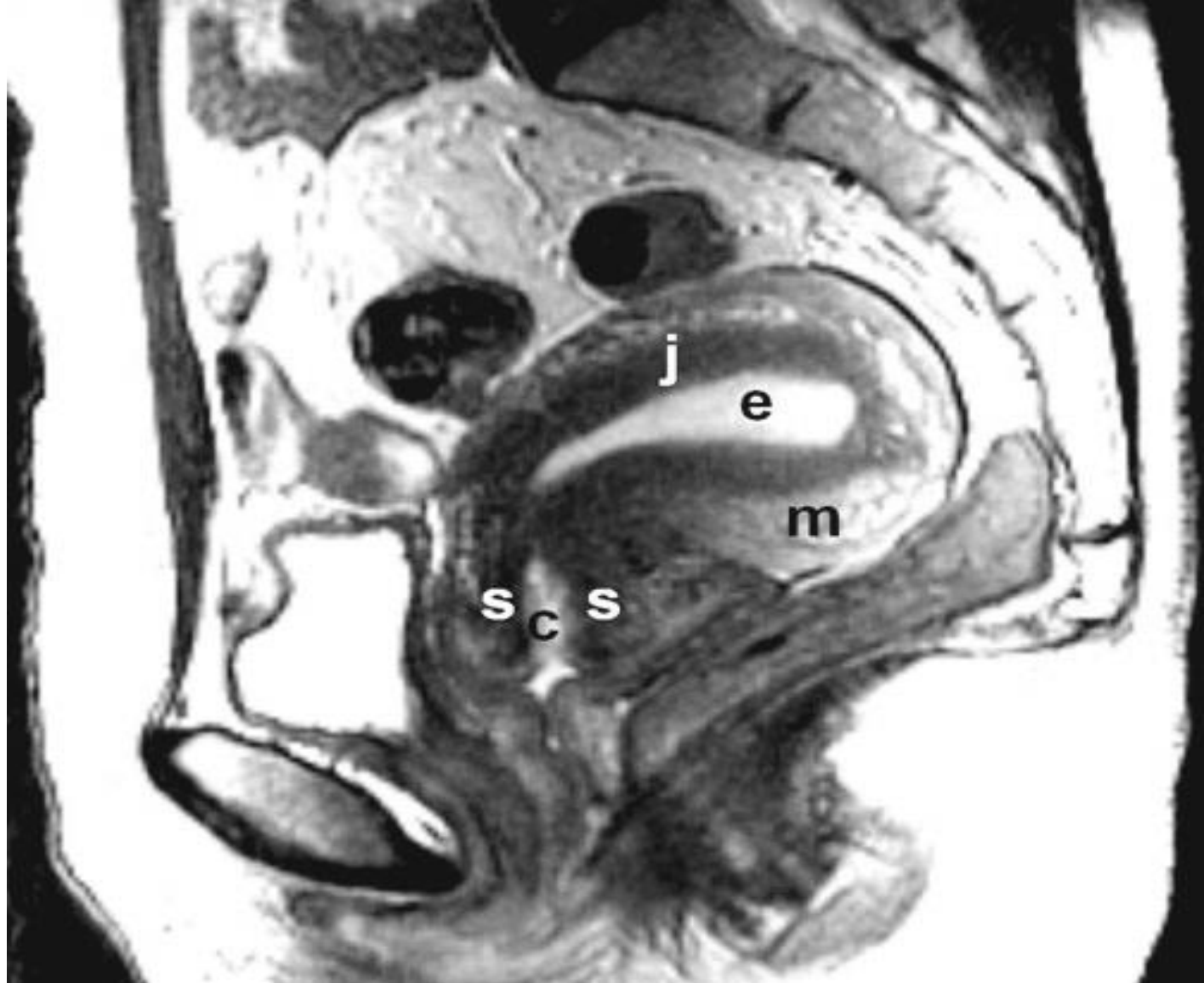# CT Anatomy

# LIGAMENTS

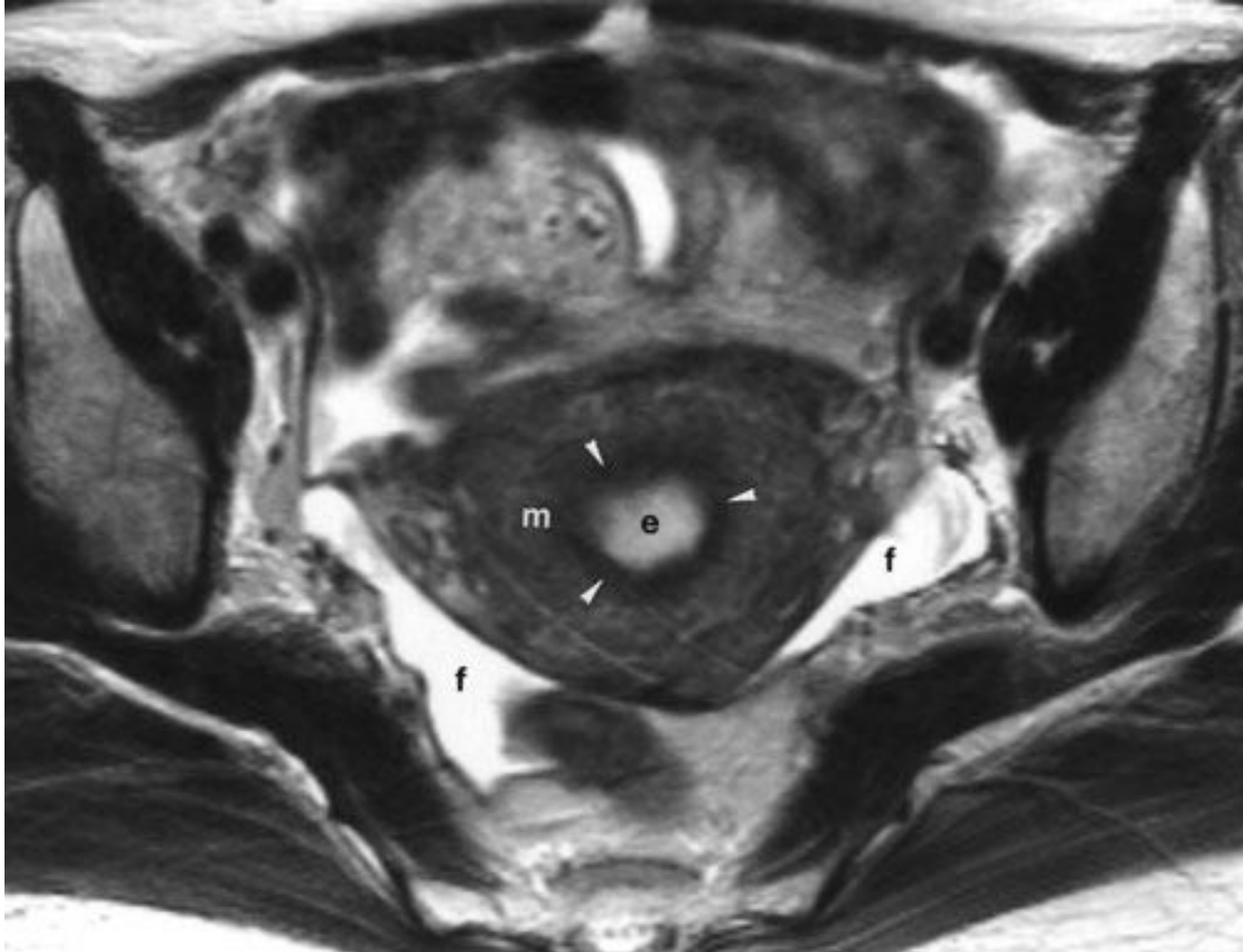


These contrast-enhanced CT scans show round ligaments ( *arrowheads* ) arising in the cornuae of the uterus. Note a subserosal uterine myoma ( *arrow* ) in the anterior aspect of the uterus.

# MRI

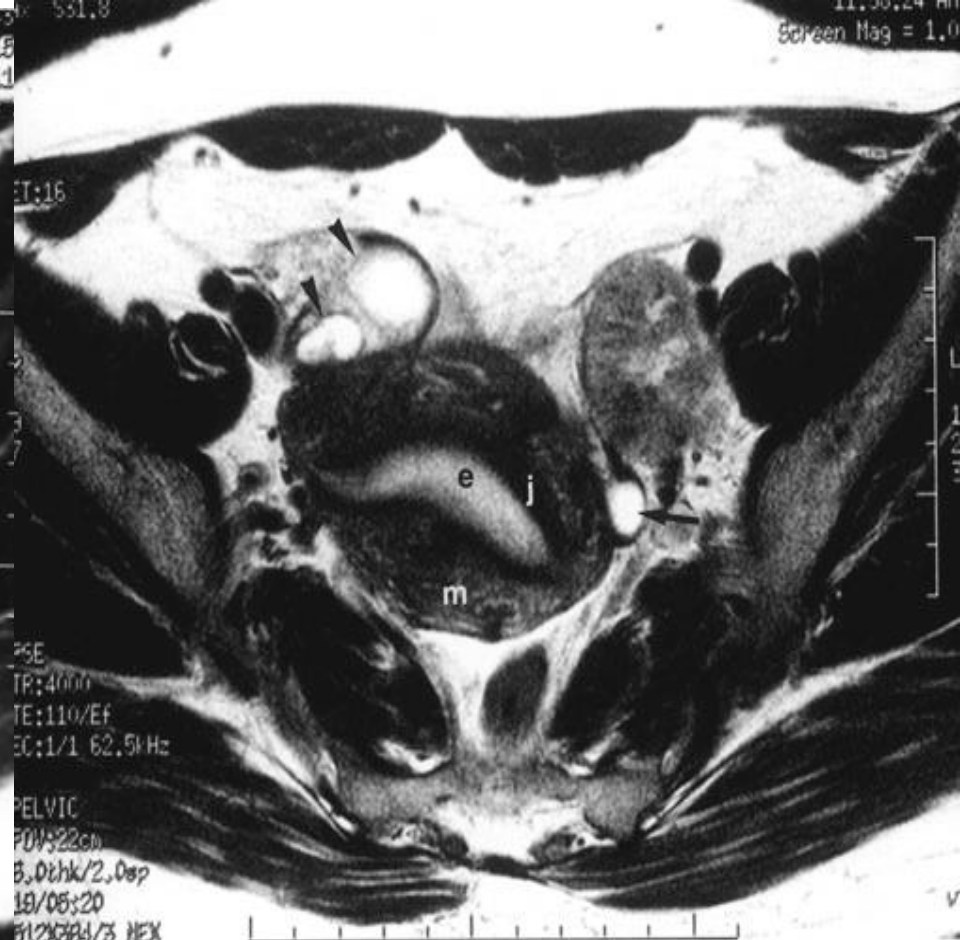
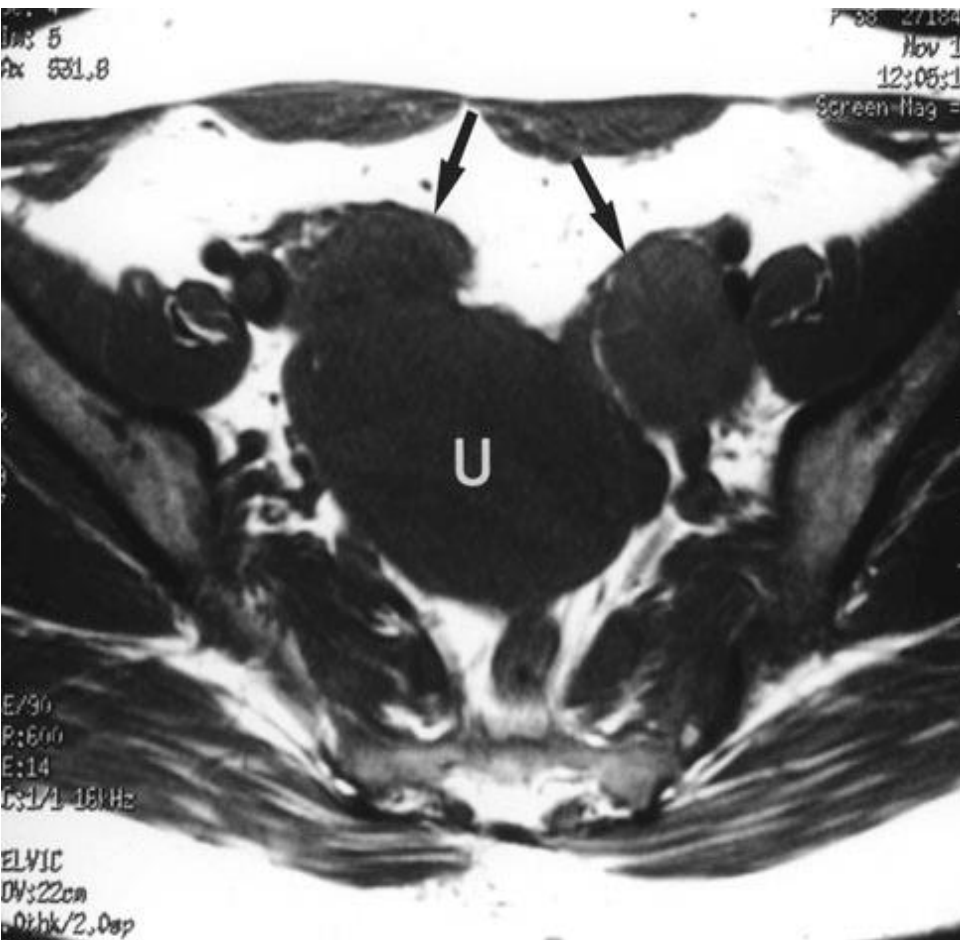

T2-weighted sagittal MR image shows a retroflexed uterus with high-intensity endometrium (*e*) and cervical canal (*c*), low intensity junctional zone (*j*), and inner cervical stroma (*s*), as well as intermediate-intensity myometrium (*m*) and the outer cervix.

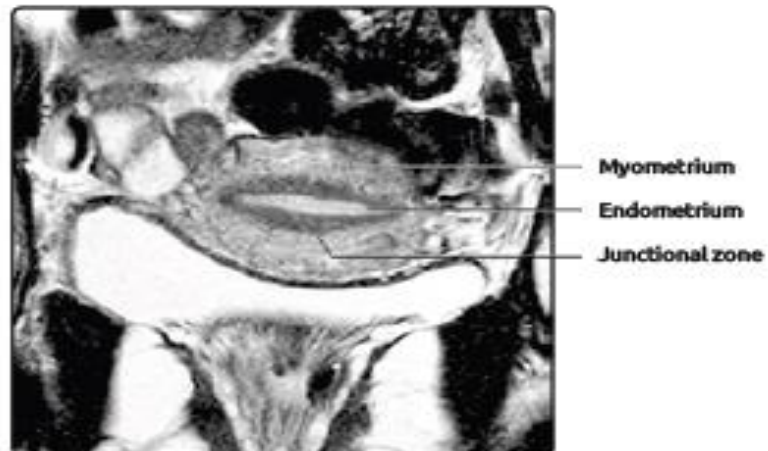
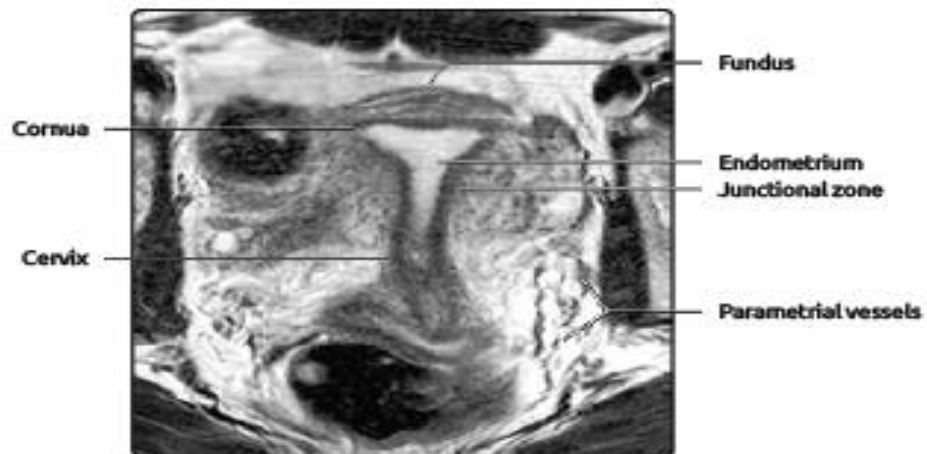
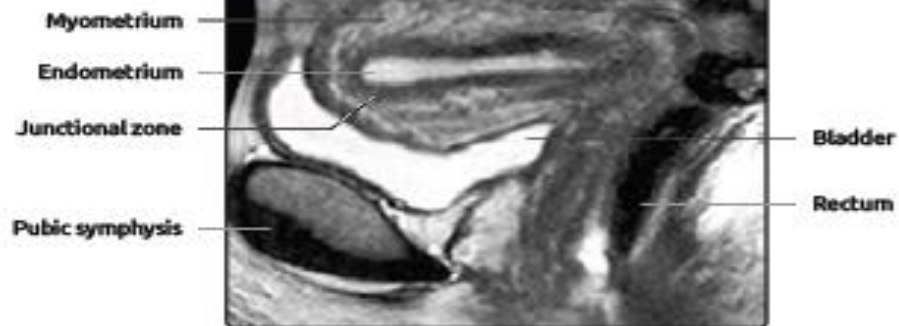


T2-weighted axial MR image shows high-intensity endometrium, intermediate intensity myometrium(*m*), and the low-intensity junctional zone (*arrowheads*). Note a small amount of fluid in the cul-de-sac

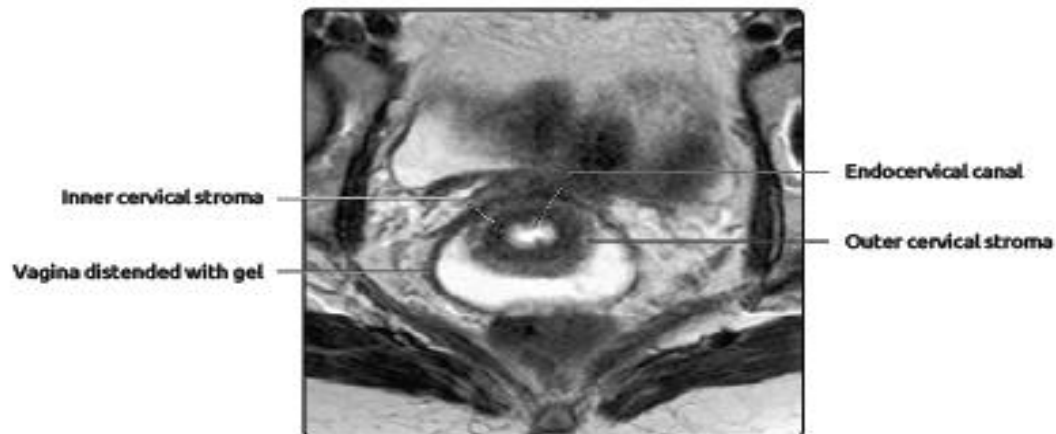
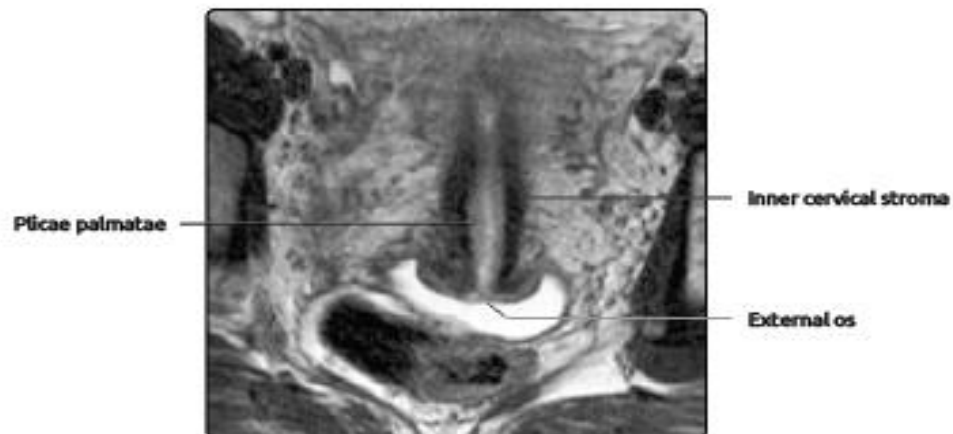
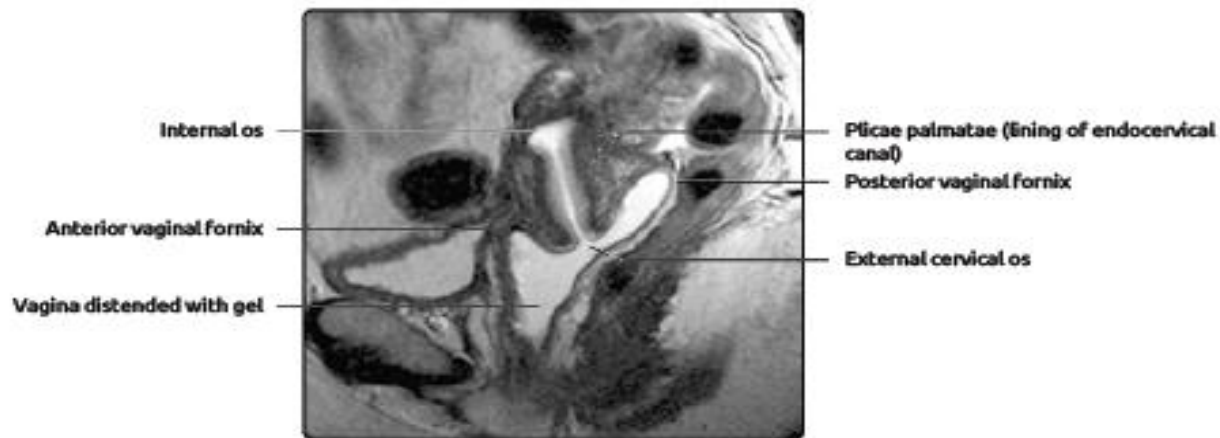




( **A** ) This T1-weighted axial MR image shows homogeneous intermediate signal intensity of the uterus (U) and ovaries (*arrows* ). ( **B** ) This T2-weighted image shows high-intensity endometrium (*e*), a low intensity junctional zone (*j*), and intermediate intensity of the myometrium (*m* ). Note the small high-intensity cysts (*arrowheads* ) in the right ovary and the small left paratubal cyst (*arrow*).

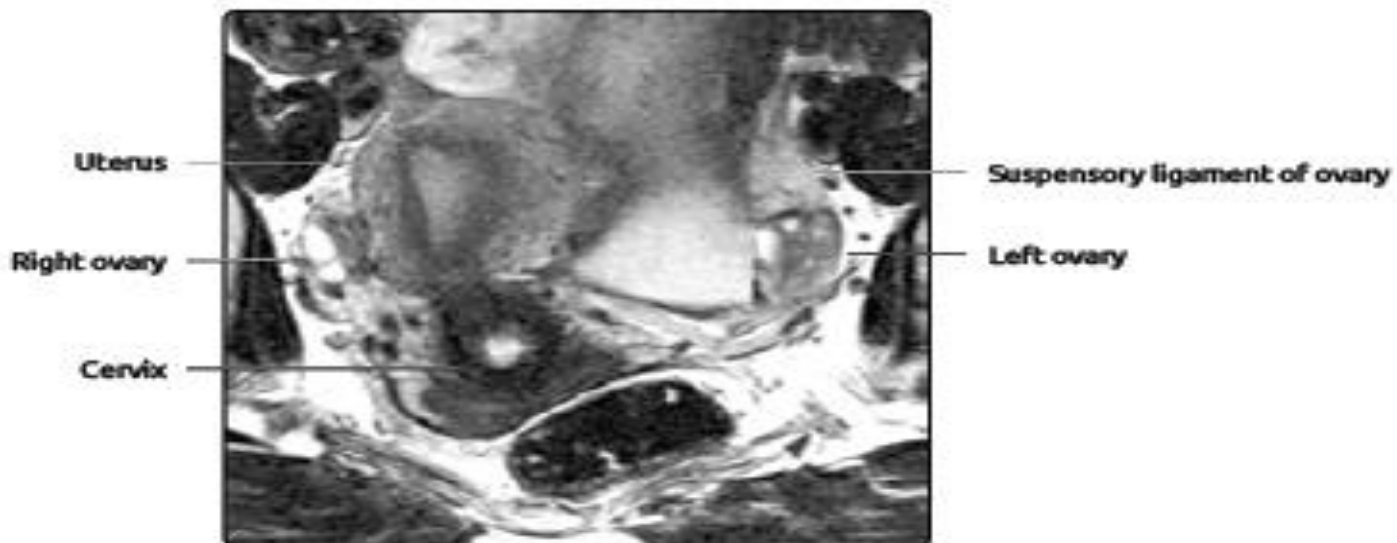
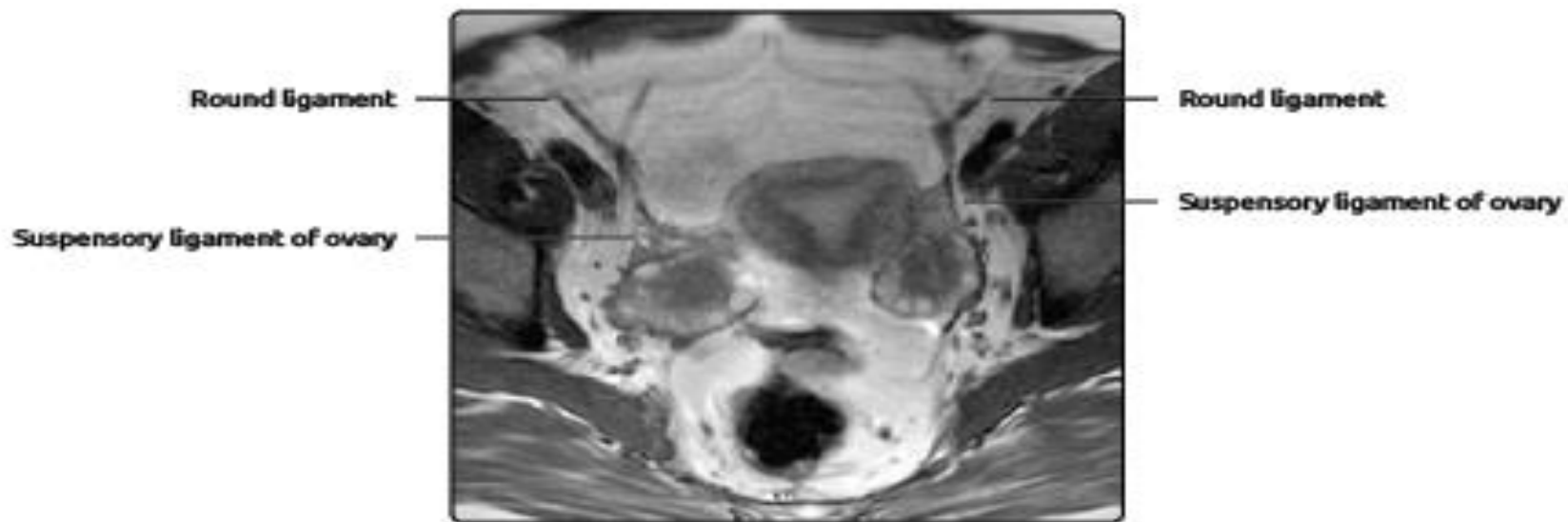


## MR, CERVIX

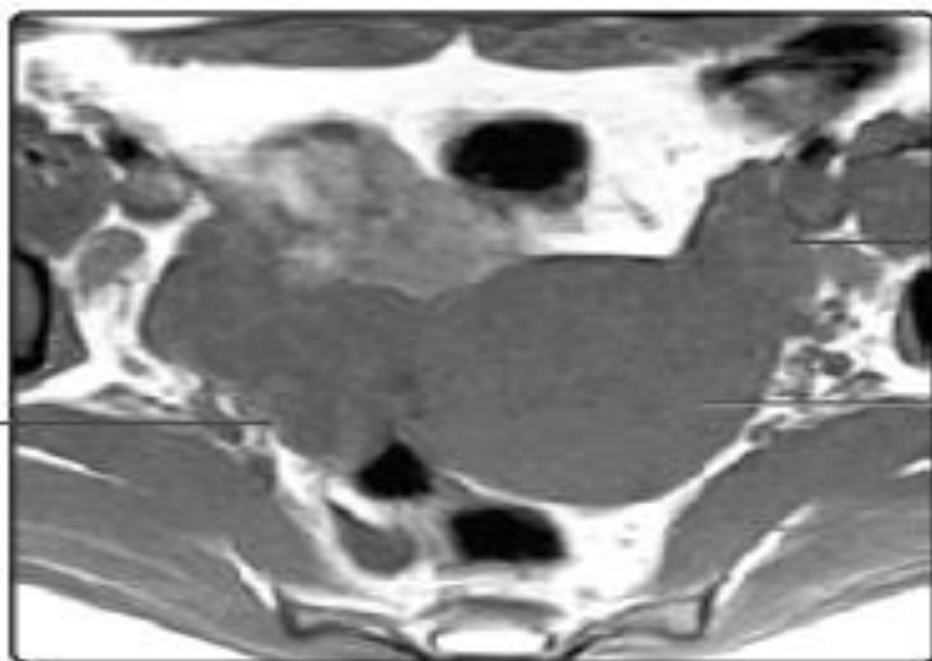

# Ovaries

## OVARY AND LIGAMENTS



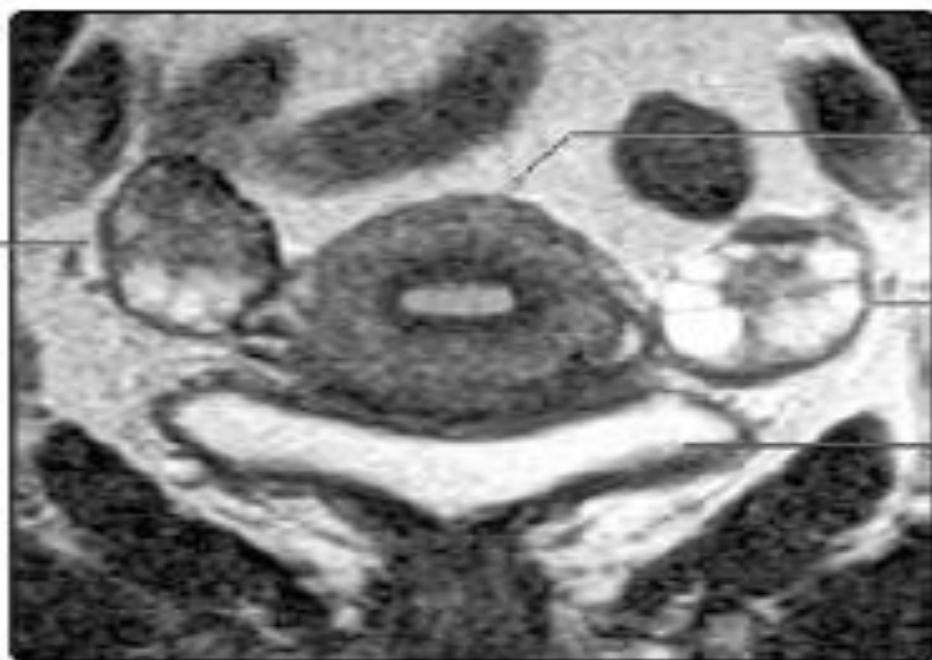Follicle in right ovary



Left ovary

Uterus

Ovary

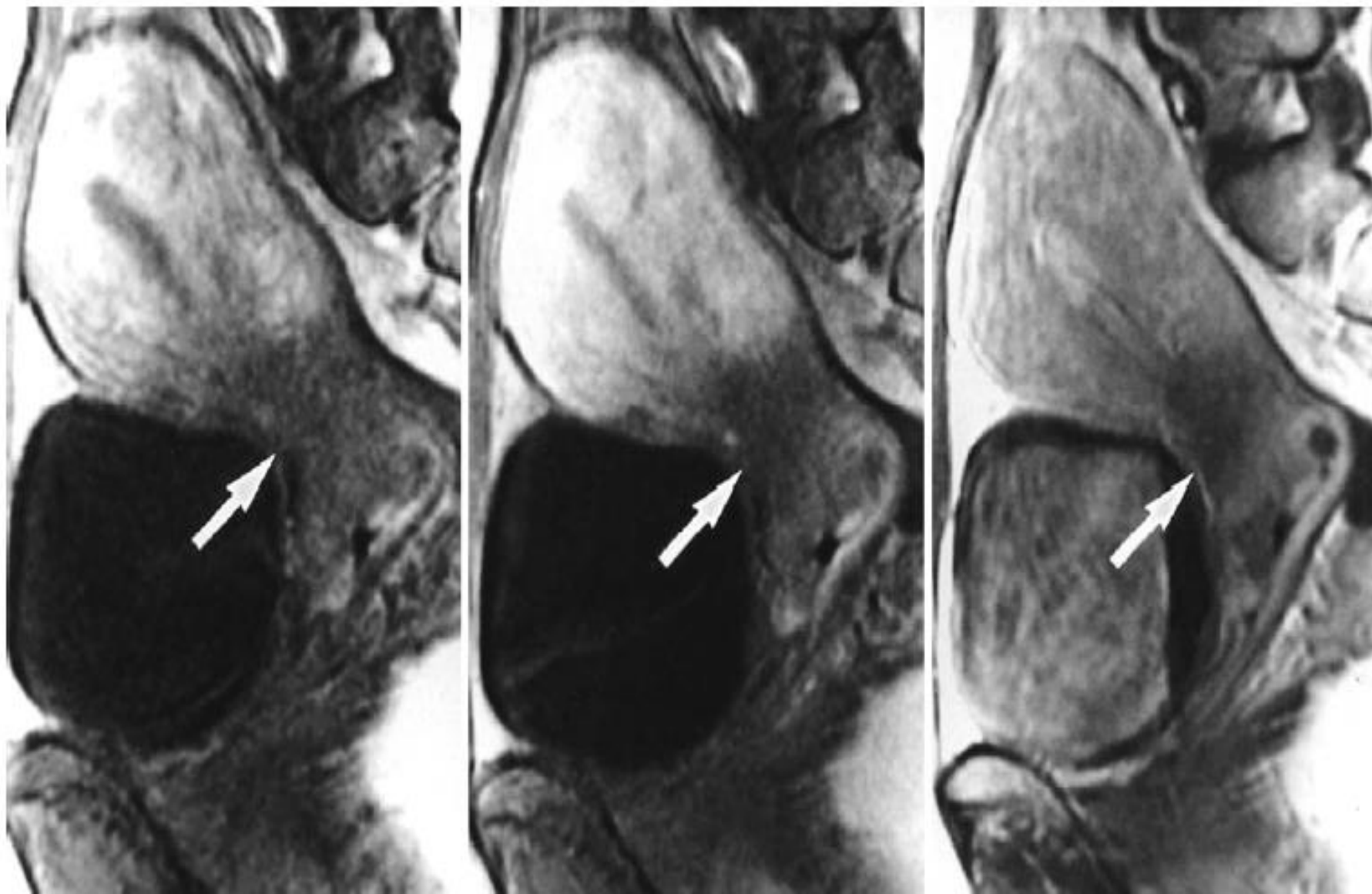


Uterus

Ovary

Bladder

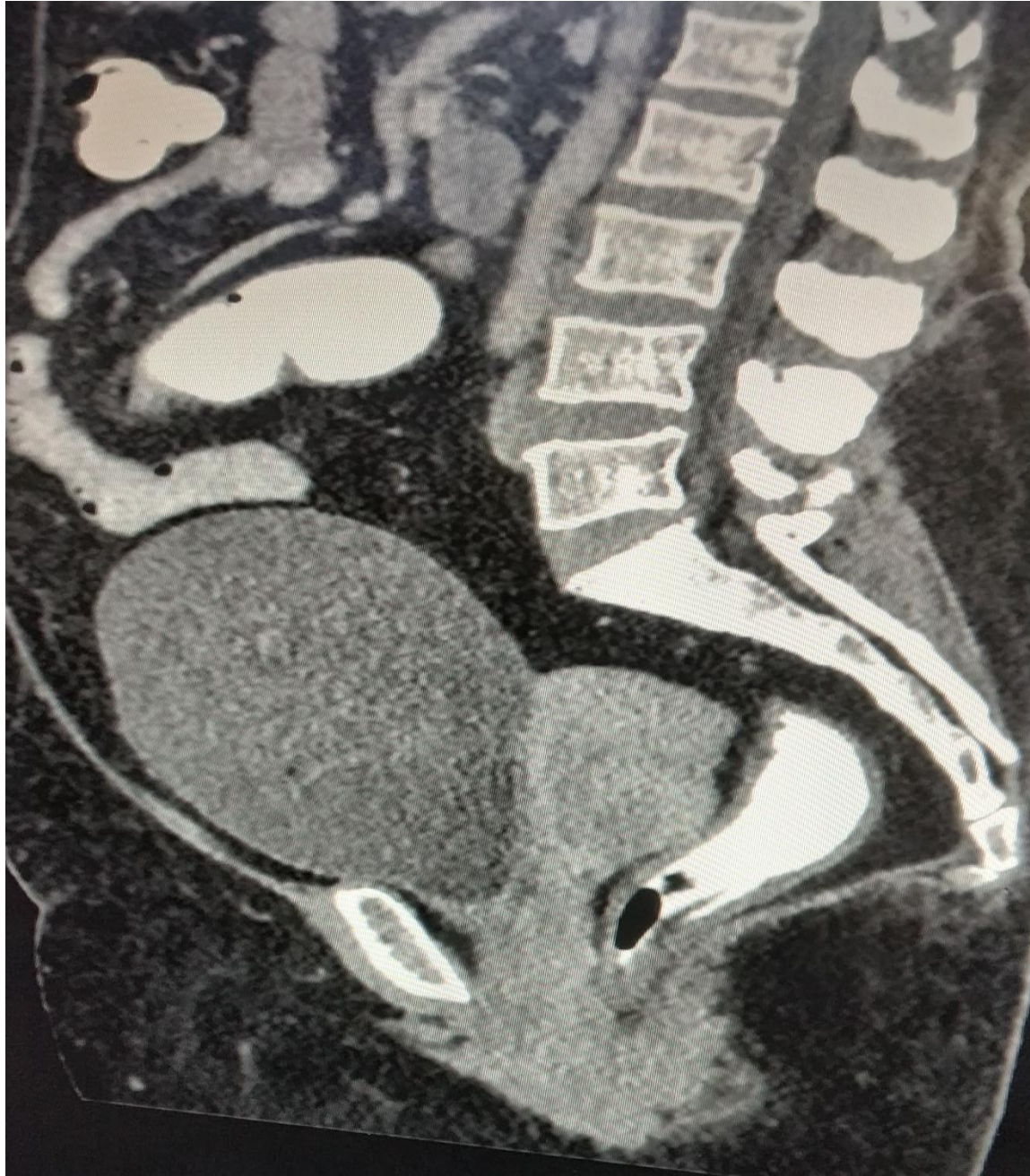



**Fig. 5.2** Normal uterine and cervical enhancement on MRI. Consecutive dynamic contrast-enhanced studies obtained at 1 min (*left*), 2 min (*middle*), and 3 min (*right*) following contrast administra-

tion demonstrate a relative lack of enhancement in the cervix (*arrows*) compared to that of the myometrium

# CASES





NTI DEVI 70Y/F  
0000208  
02-1949, F, 70Y  
RENT  
-2019

Abdomen 1.0 I26f 3 [5]  
:00.27  
21.9

HYDROMETRA

SOMA

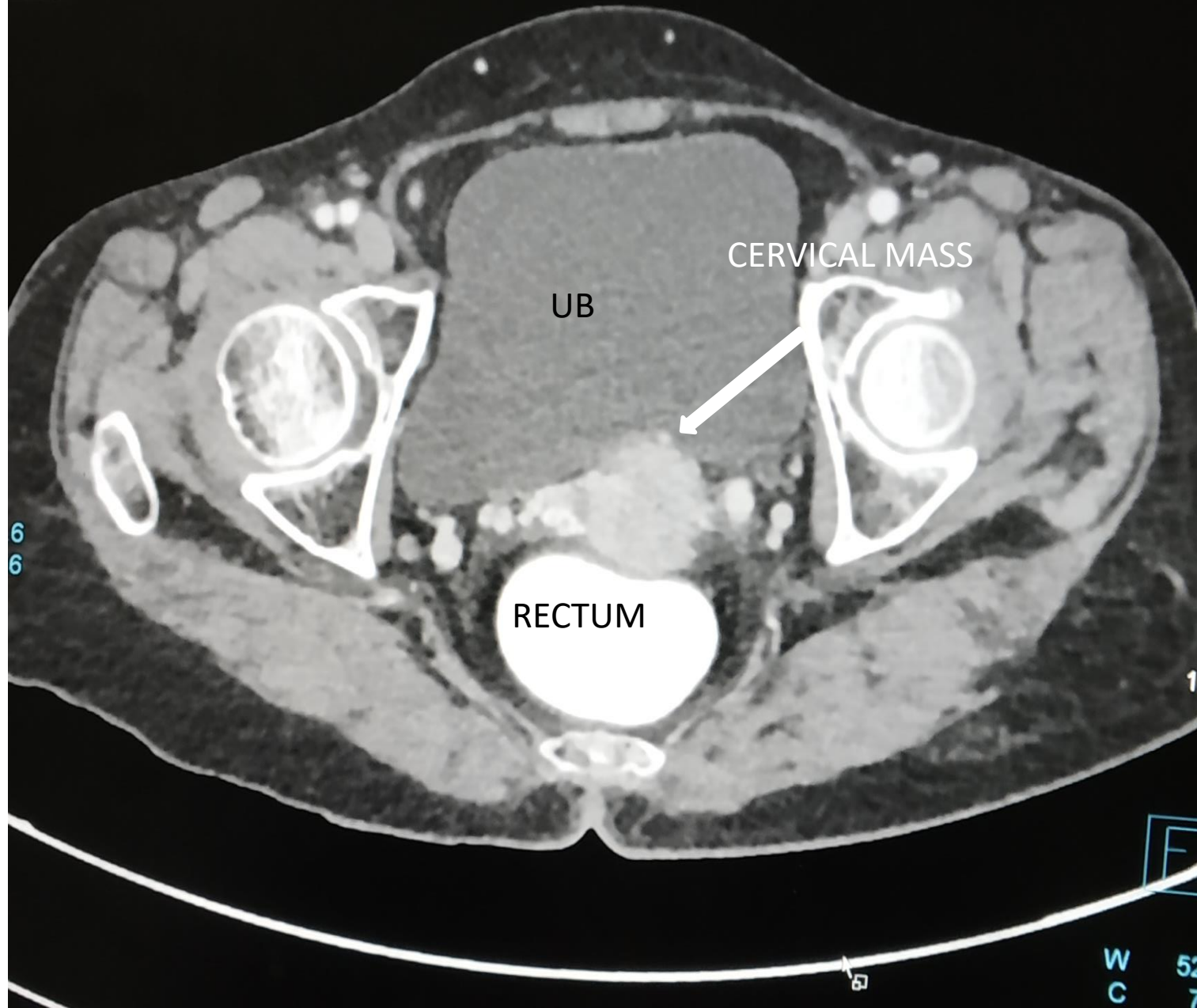
UB

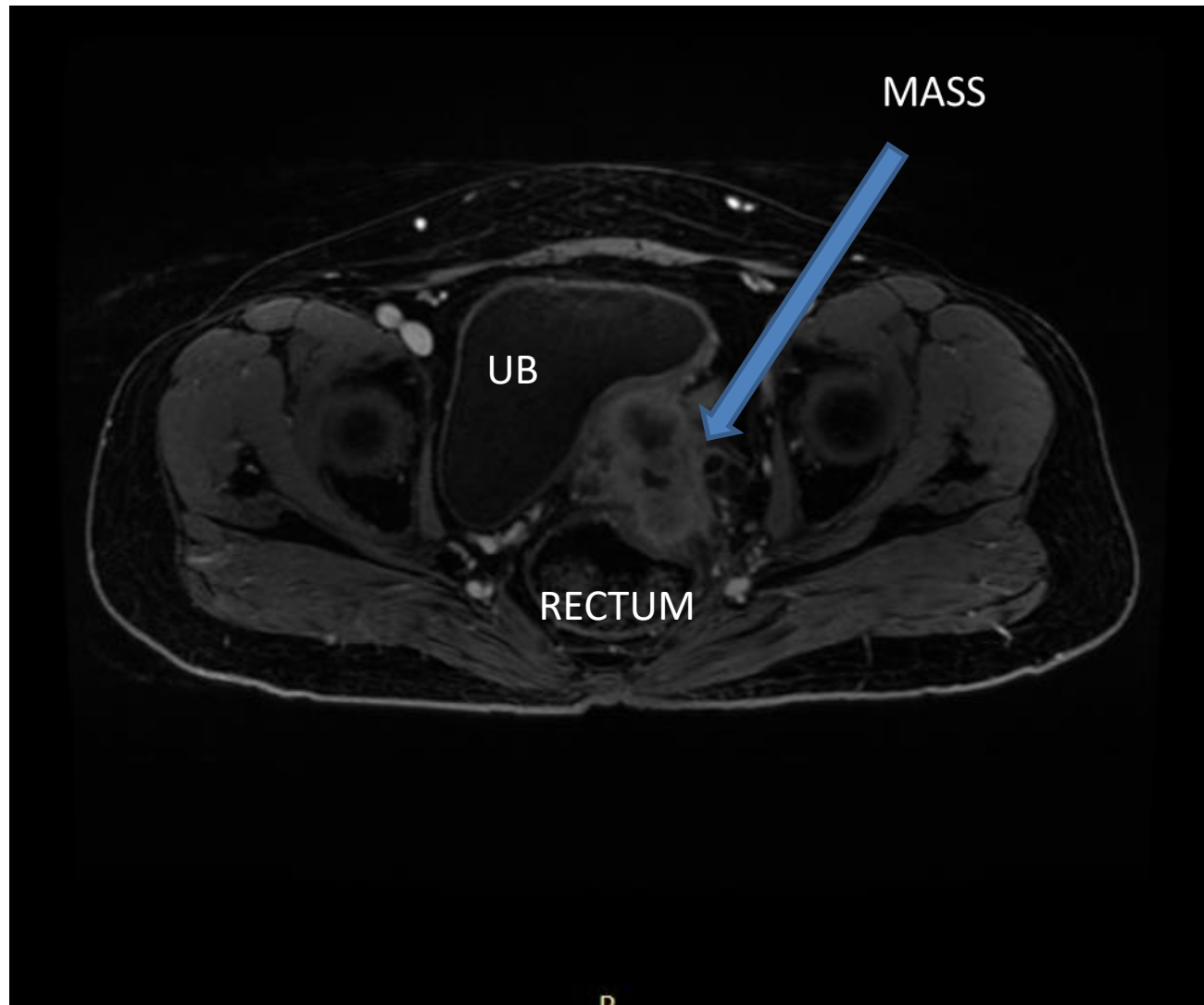
RECTUM

CERVICAL MASS

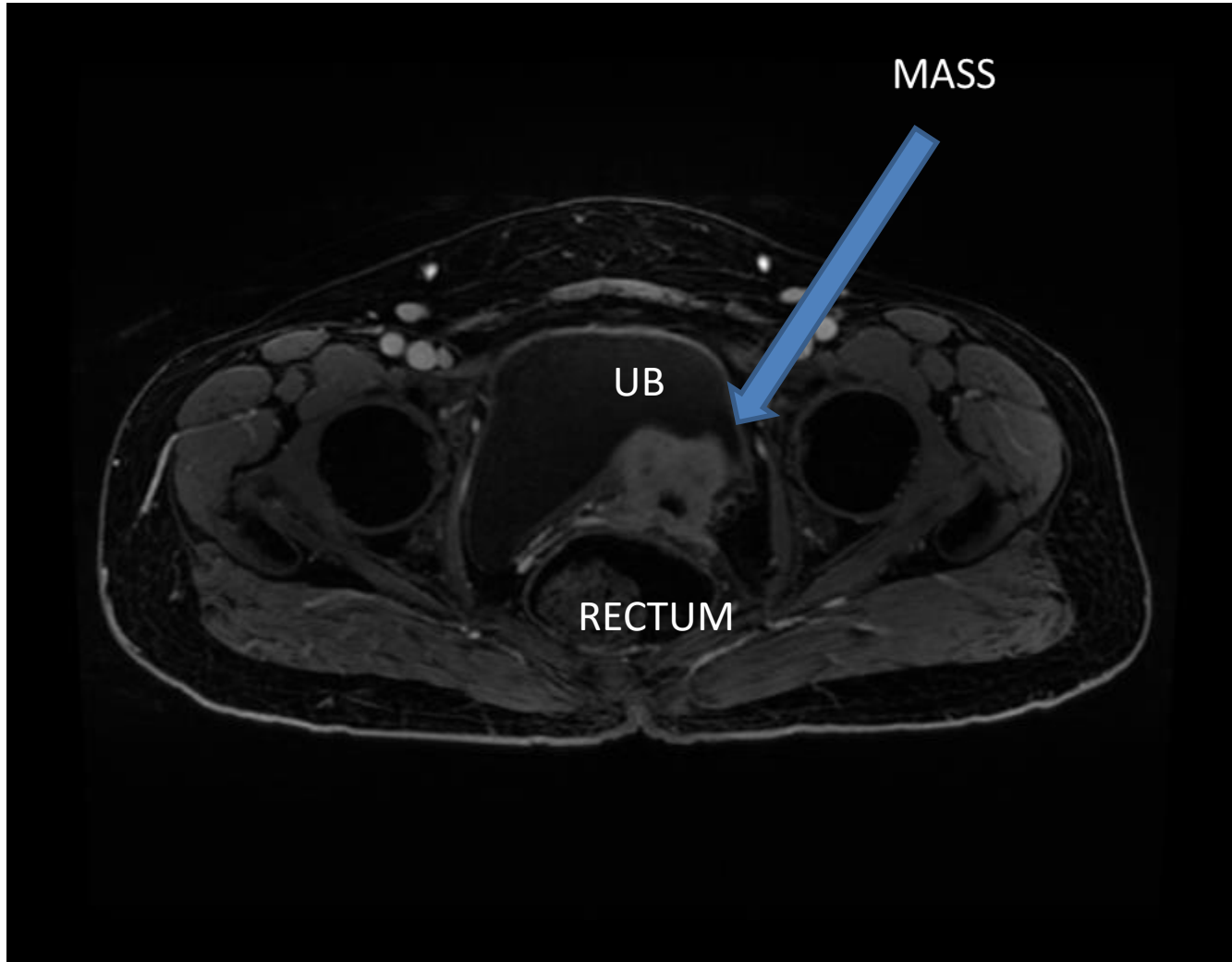
0.6  
0.6

2-2019  
Abdomen 1.0 I26f 3 [5]  
:00.27  
367.4

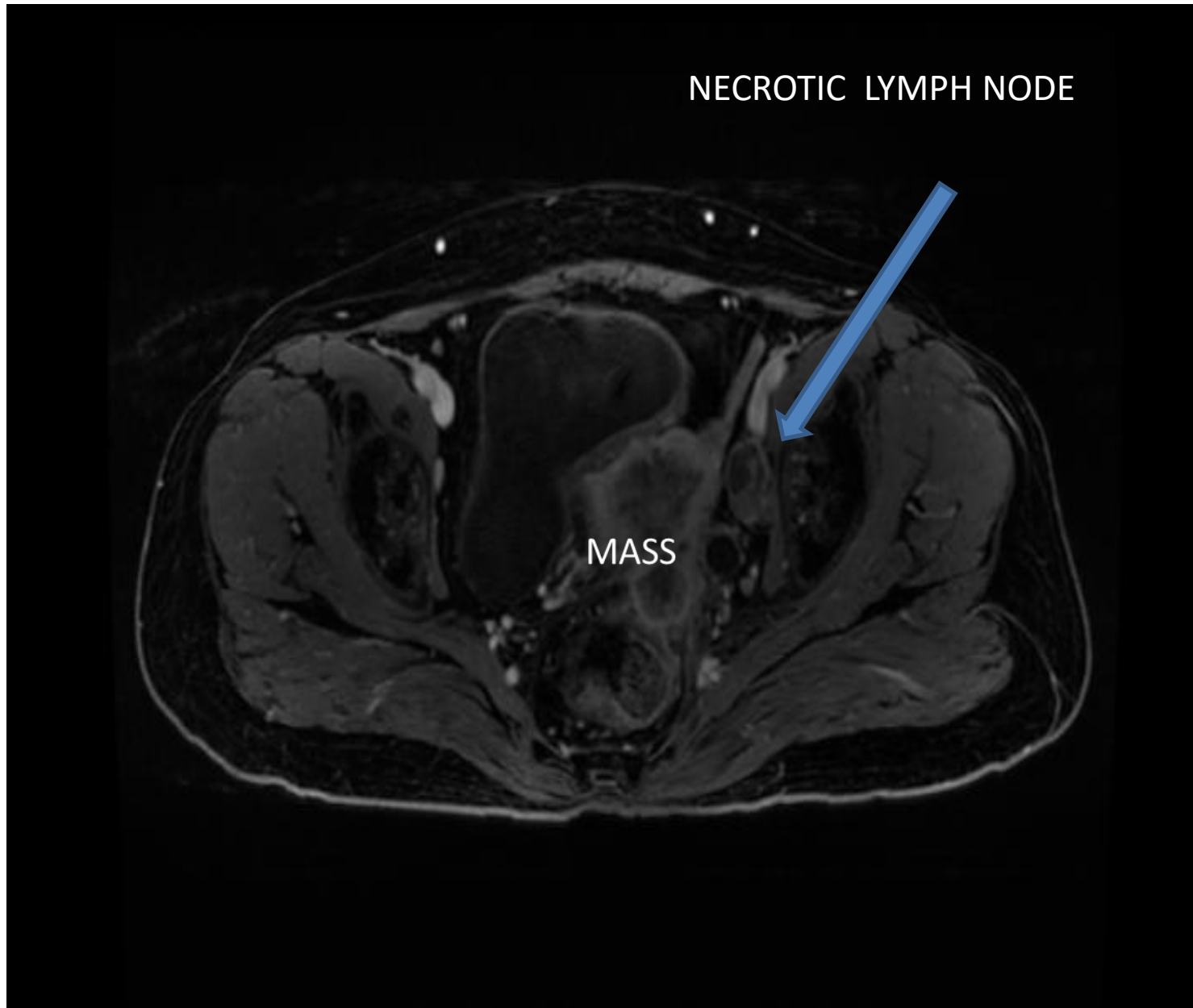


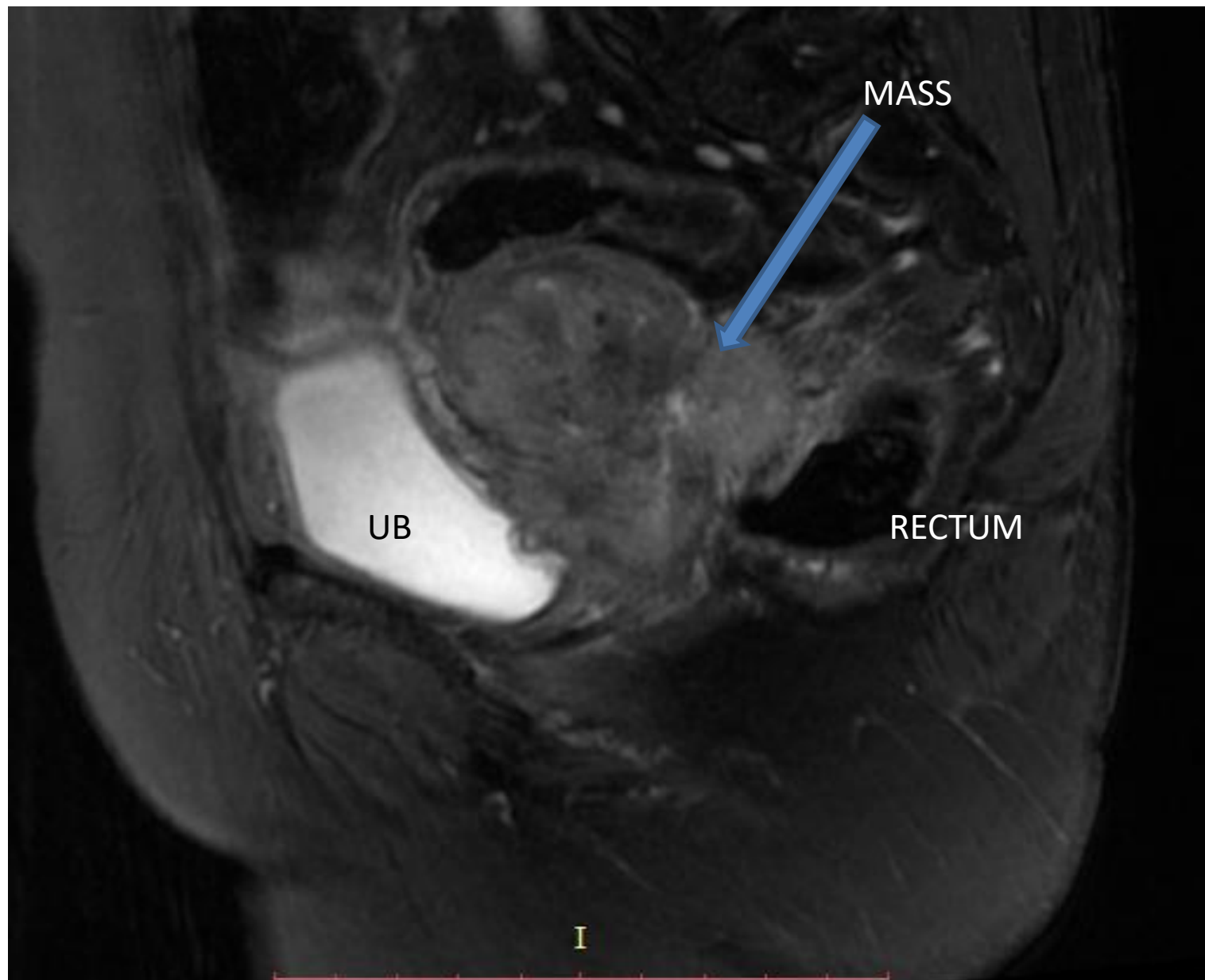


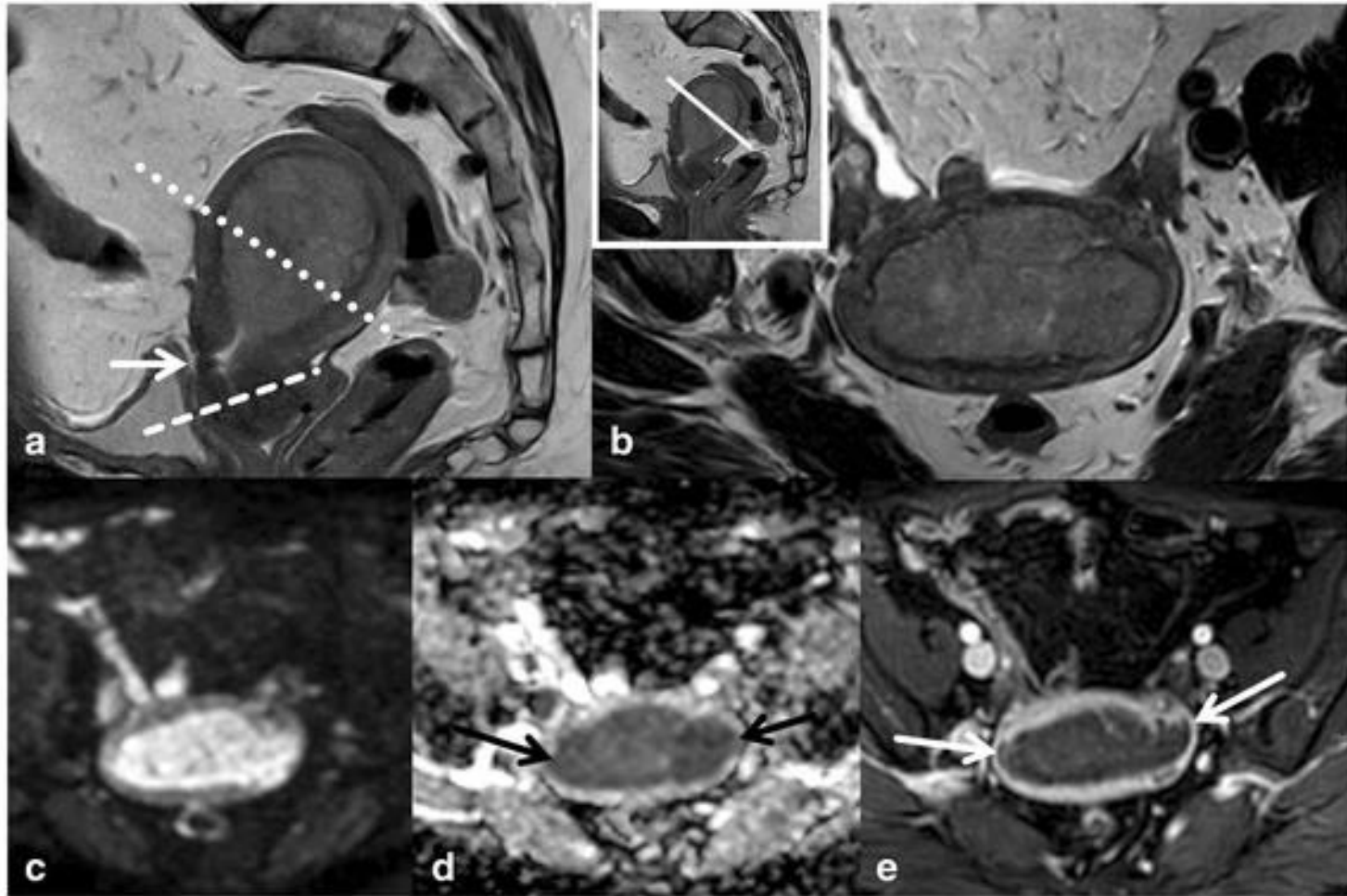




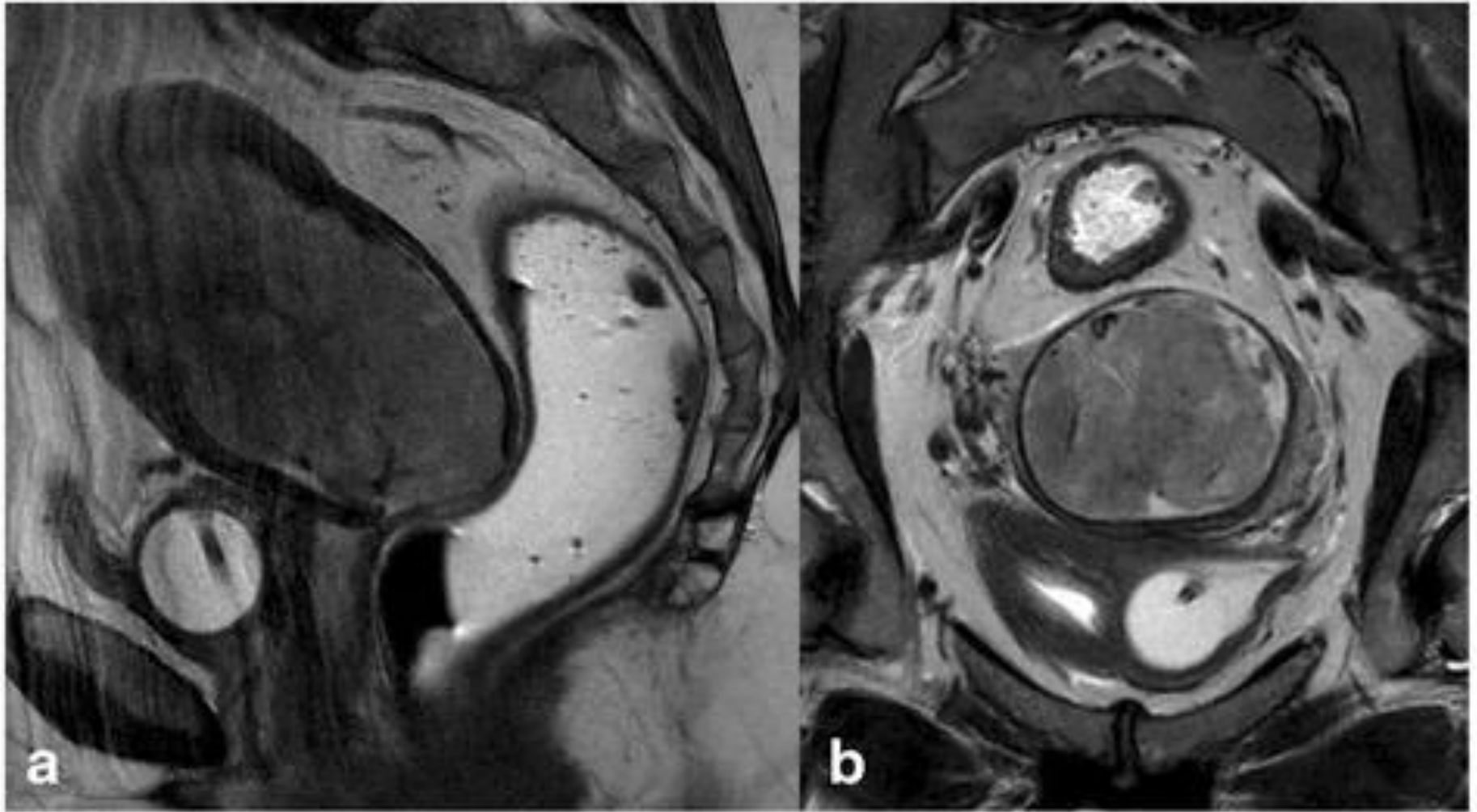NECROTIC LYMPH NODE







Endometrial cancer expanding the uterine cavity and extending to the upper cervix (arrow) is seen on sagittal T2WI (a). The planes for assessing myometrial and cervical invasion are perpendicular to the long axis (dotted and dashed lines, a). T2WI perpendicular to the uterine cavity (b) demonstrates thinning of the myometrium. Deep myometrial invasion can be confirmed by DWI (b = 1000) (c) and (d) and by Gd T1 FS (e)

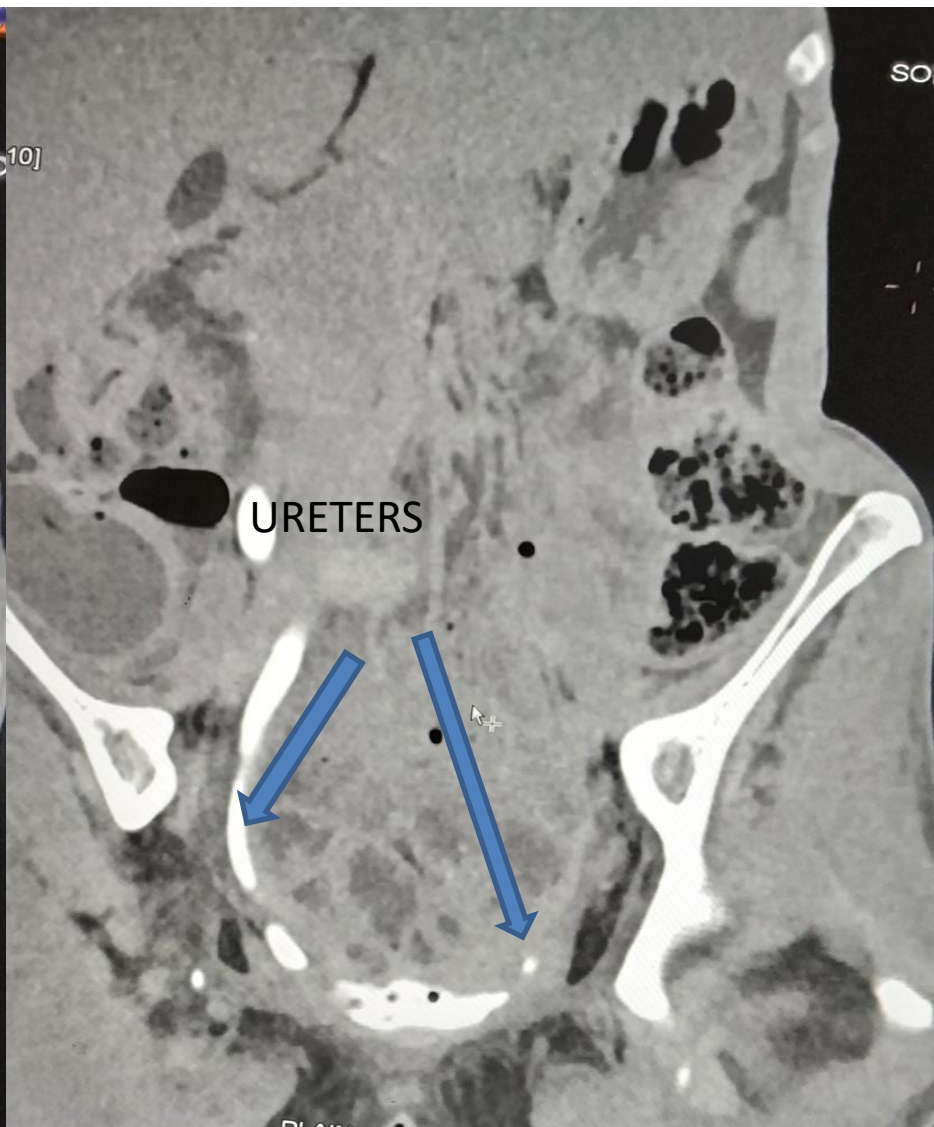
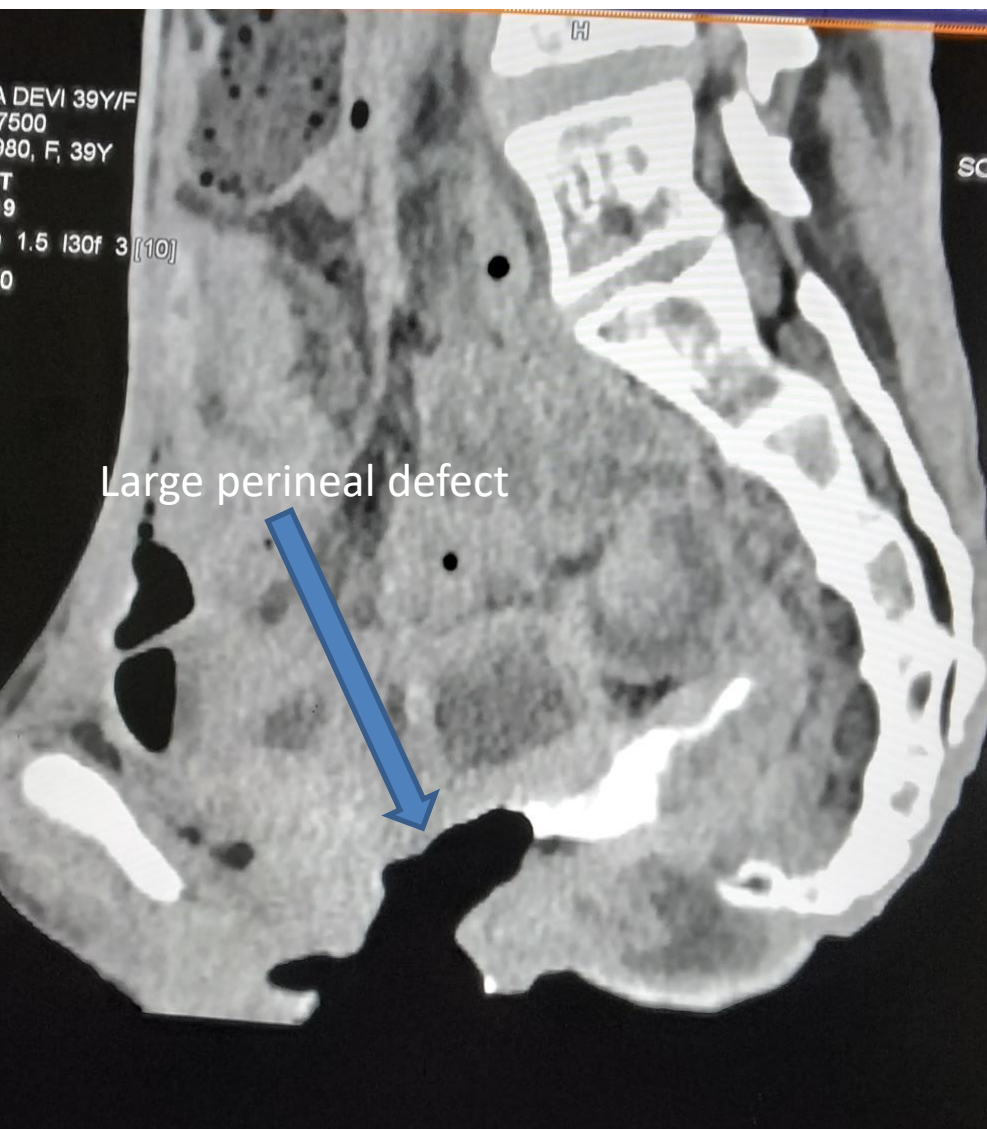
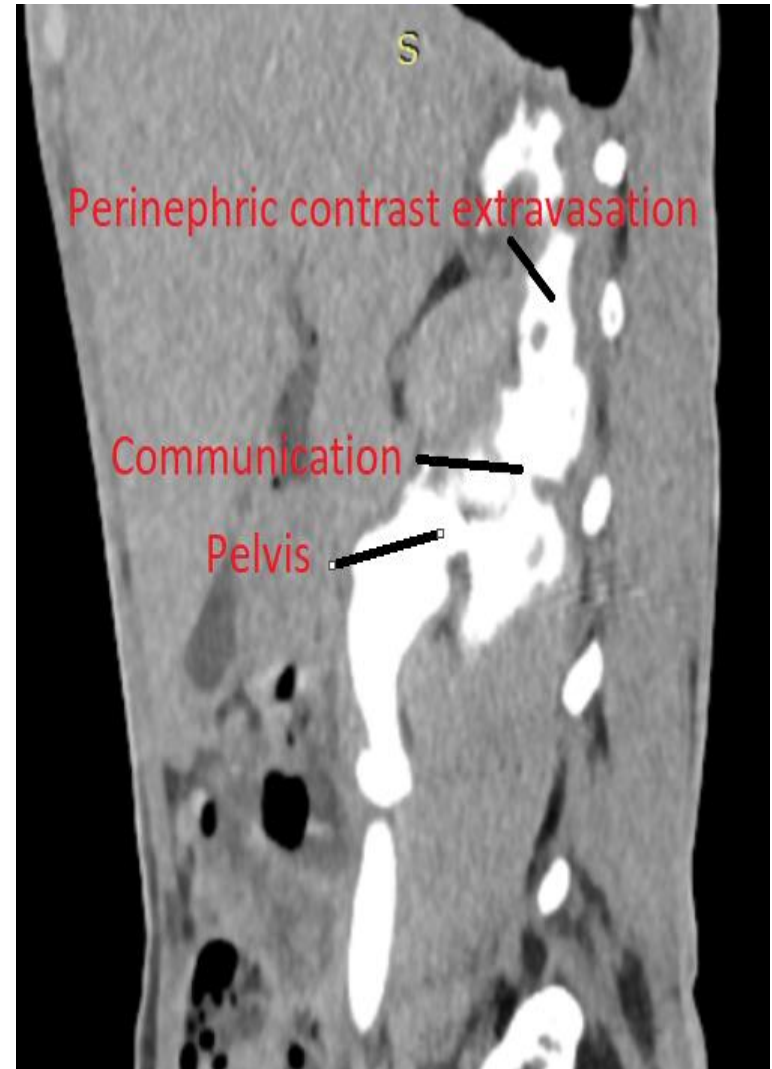
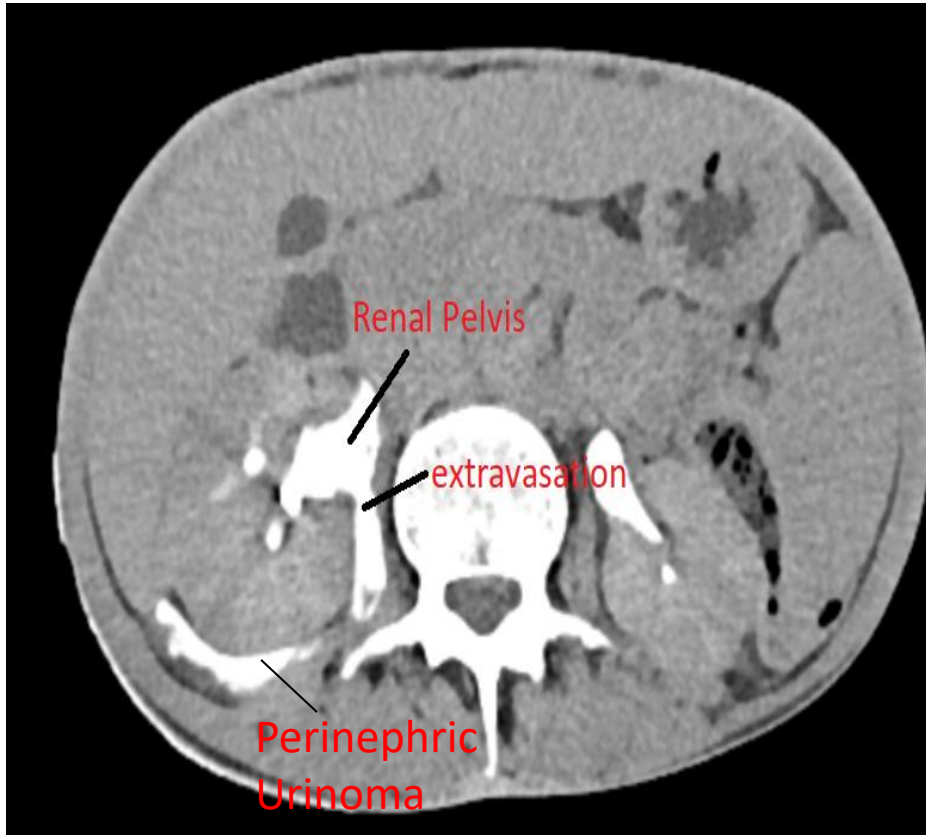
Clinically adenocarcinoma of unknown origin. Sagittal T2WI (**a**) shows a large tumour with the epicenter in the uterine corpus extending to the external cervical os. Circumferential thinning of the cervical stroma is seen on the oblique transaxial section (**b**). There is no evidence of involvement of the uterovesical ligaments or the bladder wall. All these findings favour the diagnosis of endometrial rather than cervical cancer



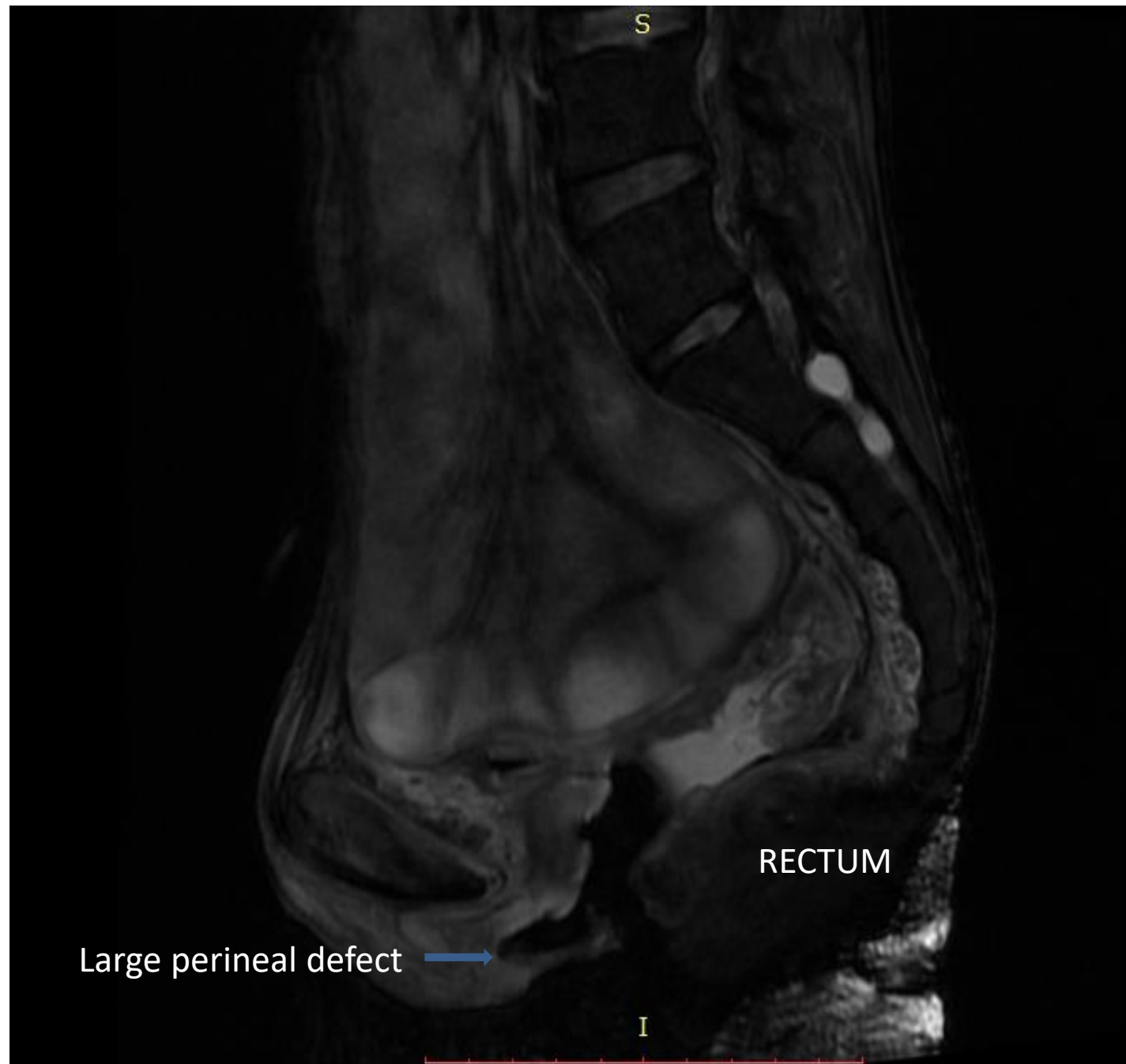# Why Staging is important

39 year female operated for Ca cervix 1 year back. Complains of urine leak through perineum



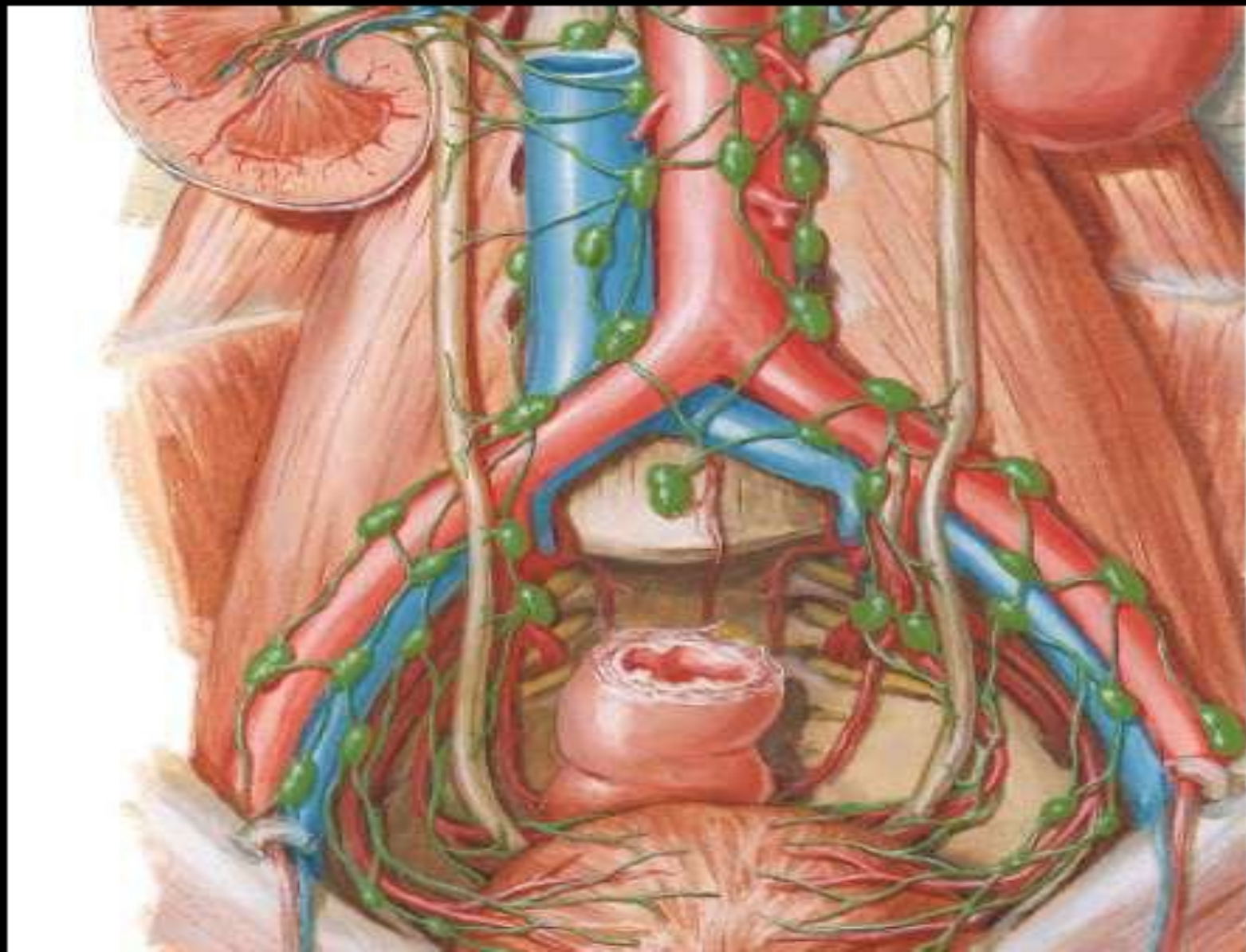


A collection was present in the right posterior para-renal space with contrast extravasation into the collection through a rent in the right renal pelvis.

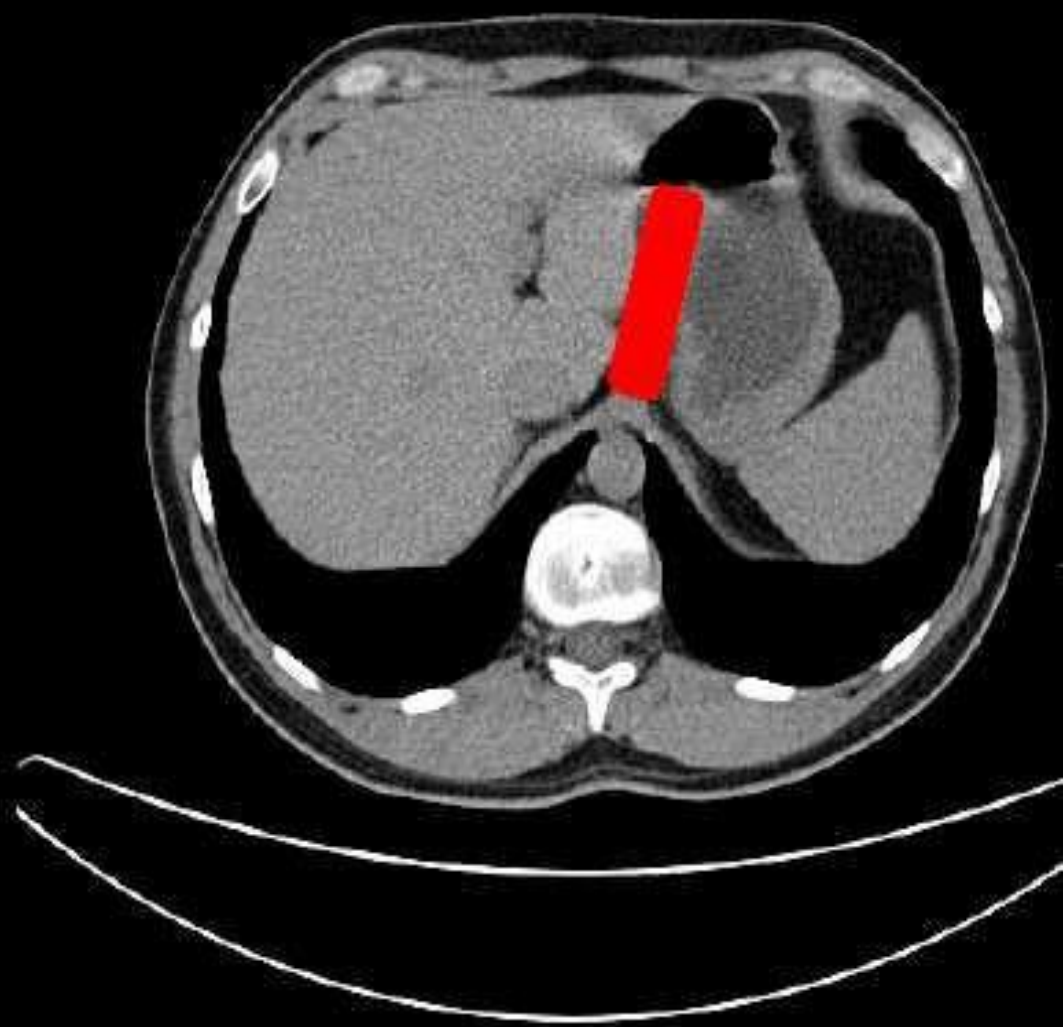




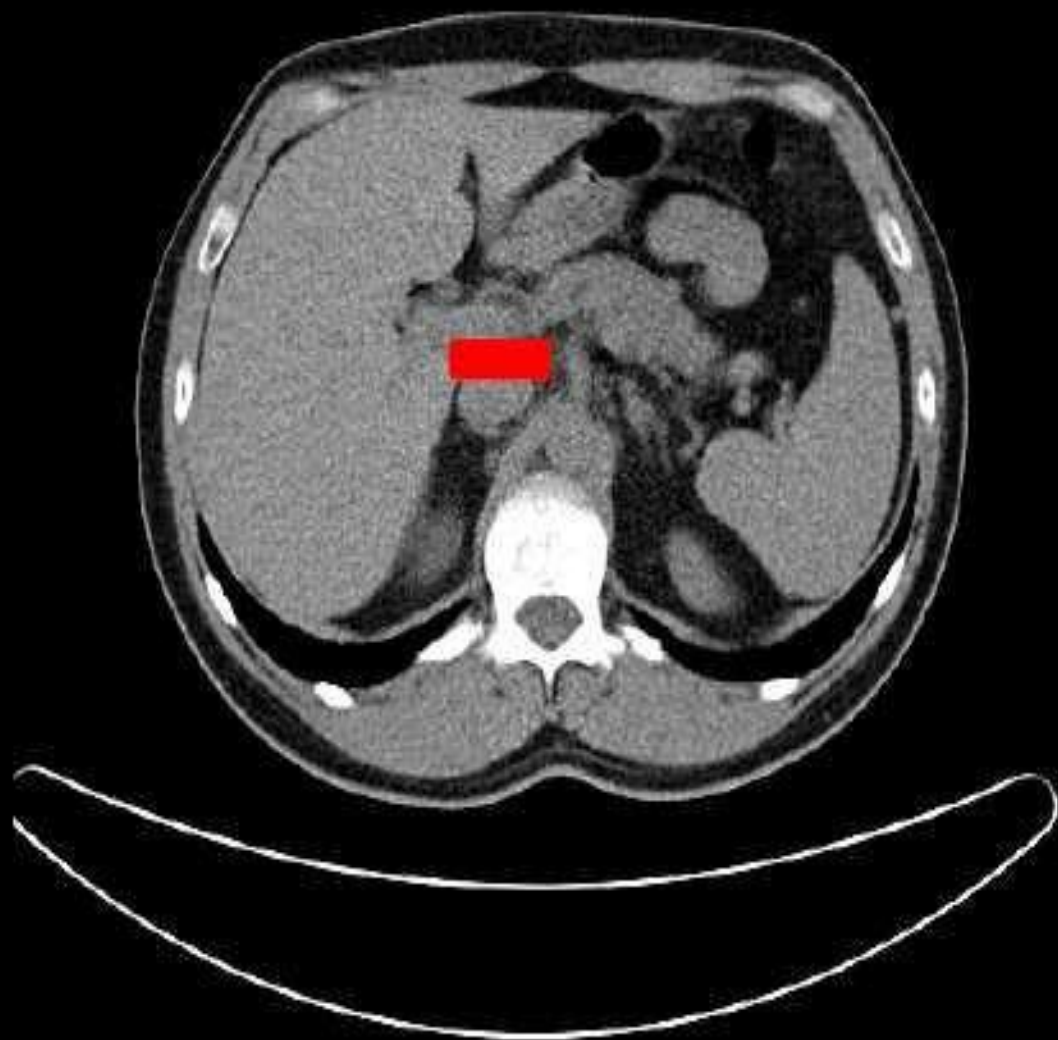
# Lymph Node Groups



- Abdominal groups
  - Gastrohepatic

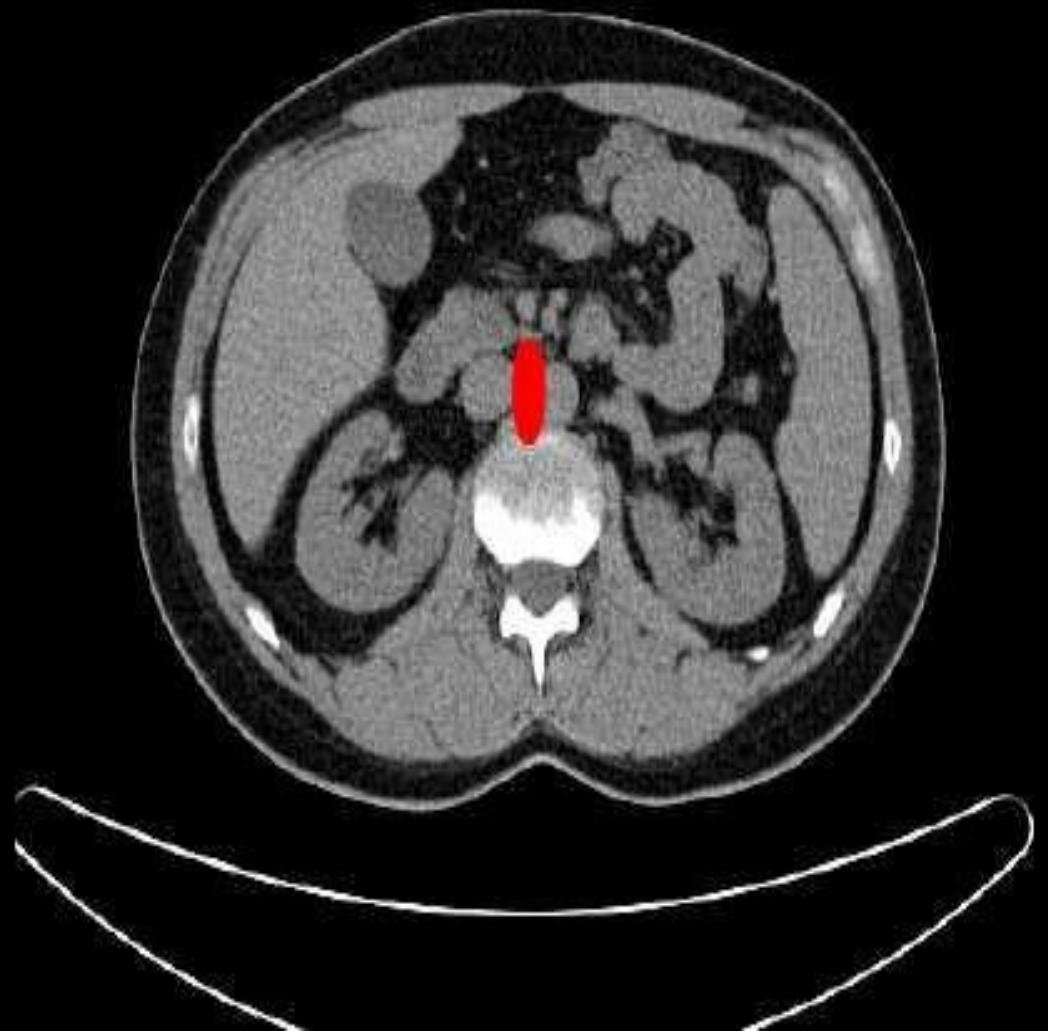


- Abdominal groups
  - Gastrohepatic
  - Portocaval

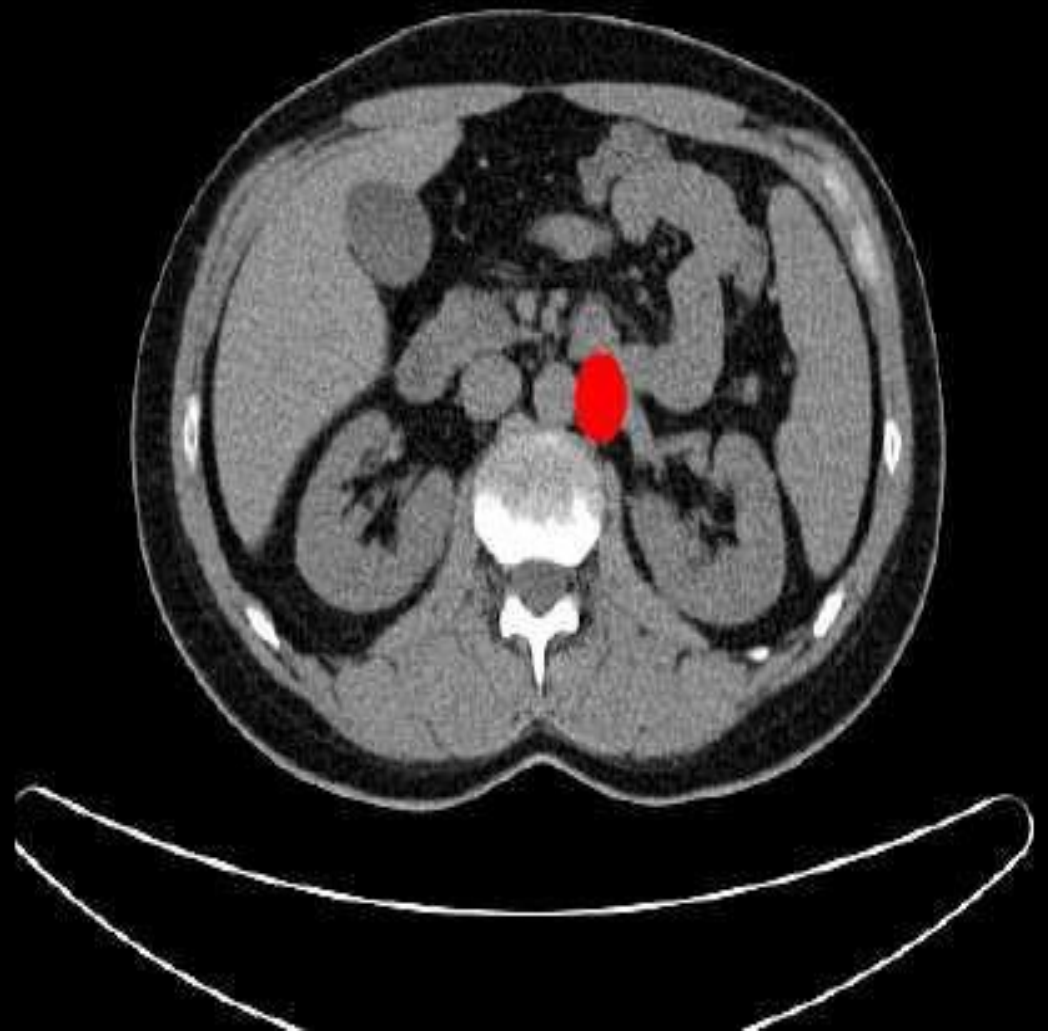



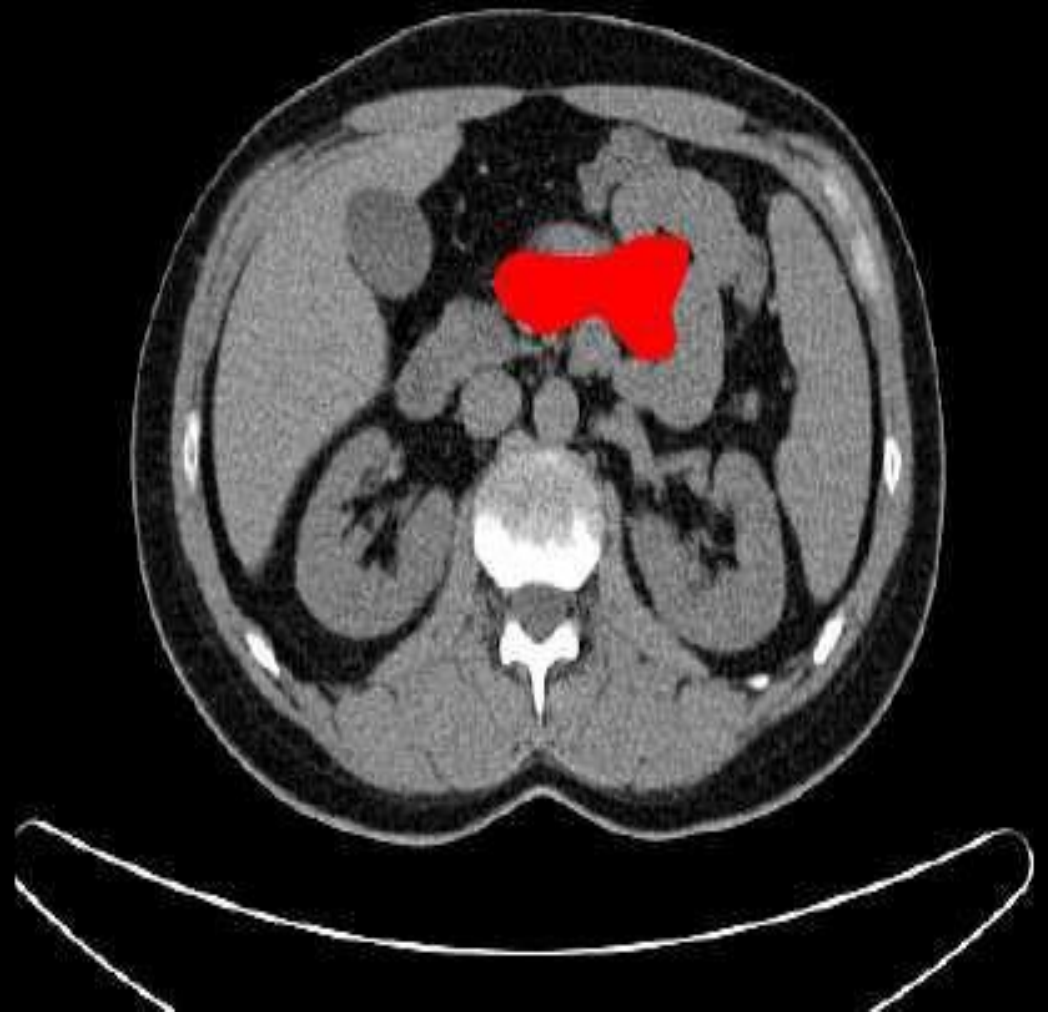
- Abdominal groups
  - Gastrohepatic
  - Portocaval
  - Aortocaval



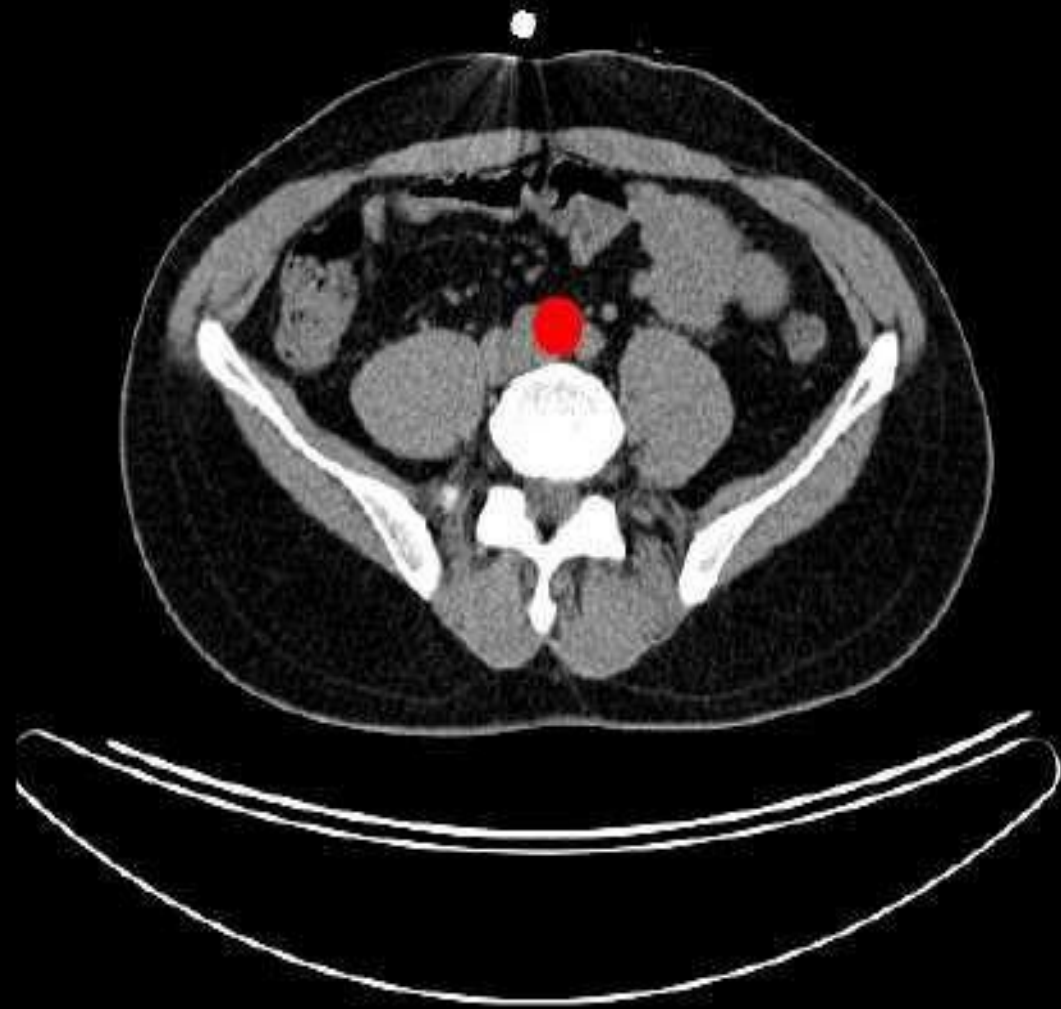
- Abdominal groups
  - Gastrohepatic
  - Portocaval
  - Aortocaval
  - Left paraaortic



- Abdominal groups
  - Gastrohepatic
  - Portocaval
  - Aortocaval
  - Left paraaortic
  - Mesenteric

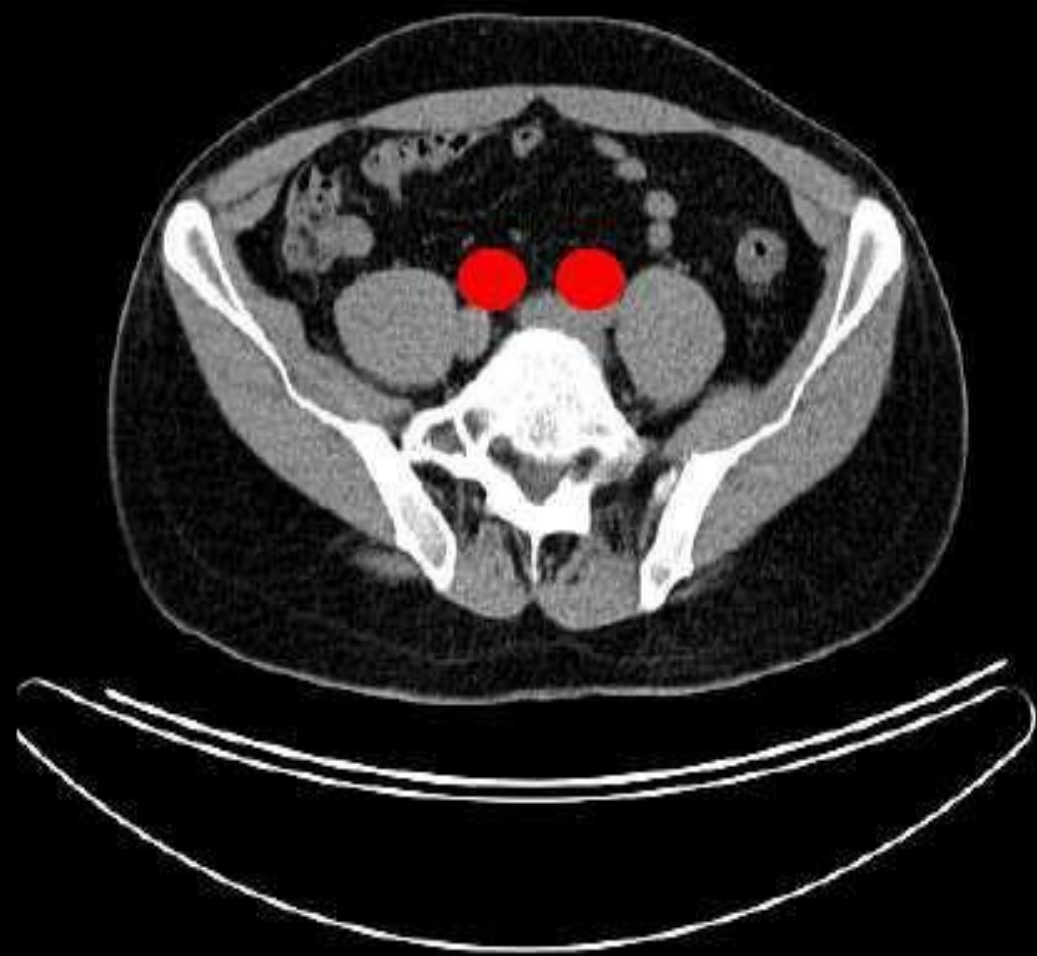

- Abdominal groups
  - Gastrohepatic
  - Portocaval
  - Aortocaval
  - Left paraaortic
  - Mesenteric
  - **Aortic bifurcation**



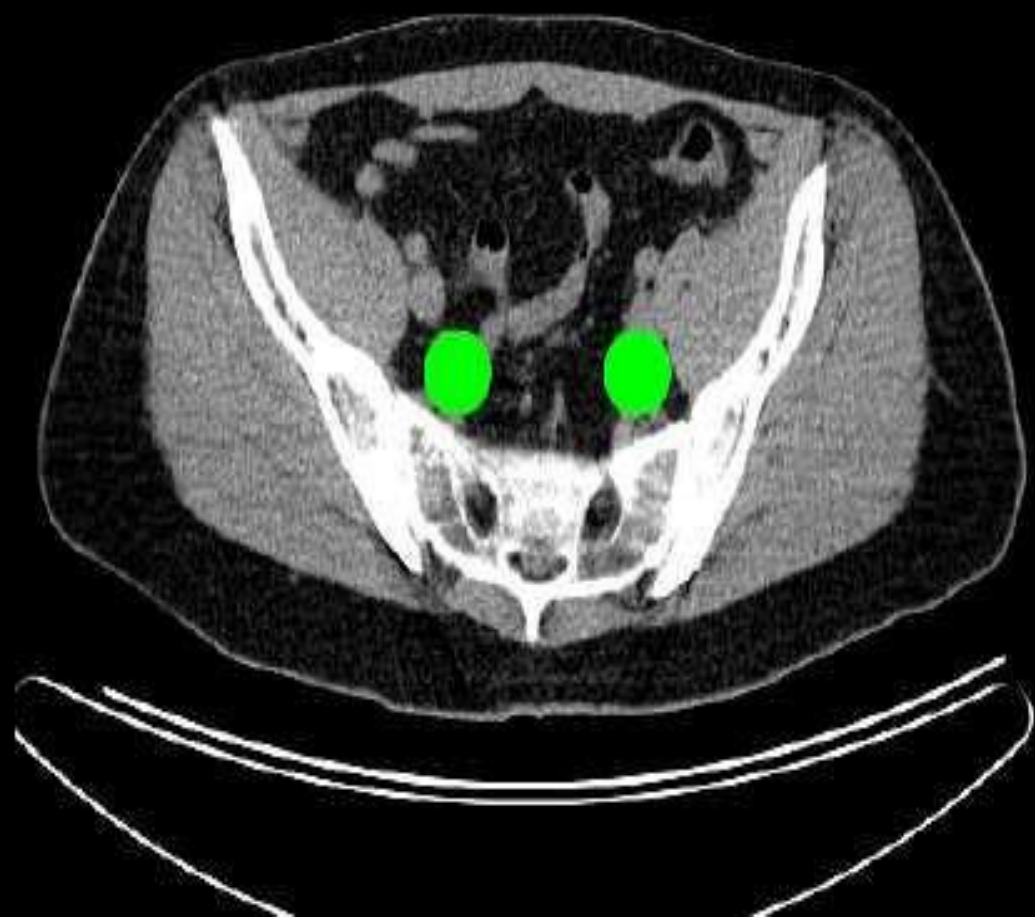

- Pelvic groups
  - Common iliac

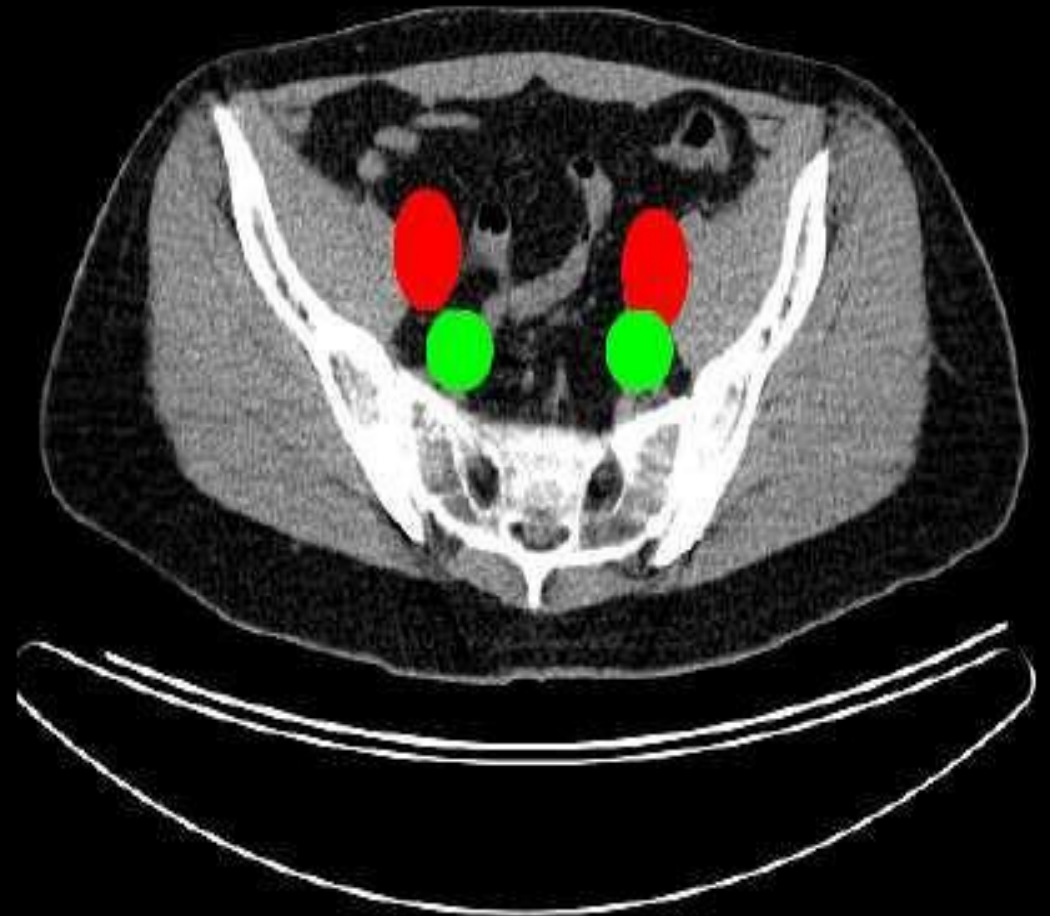




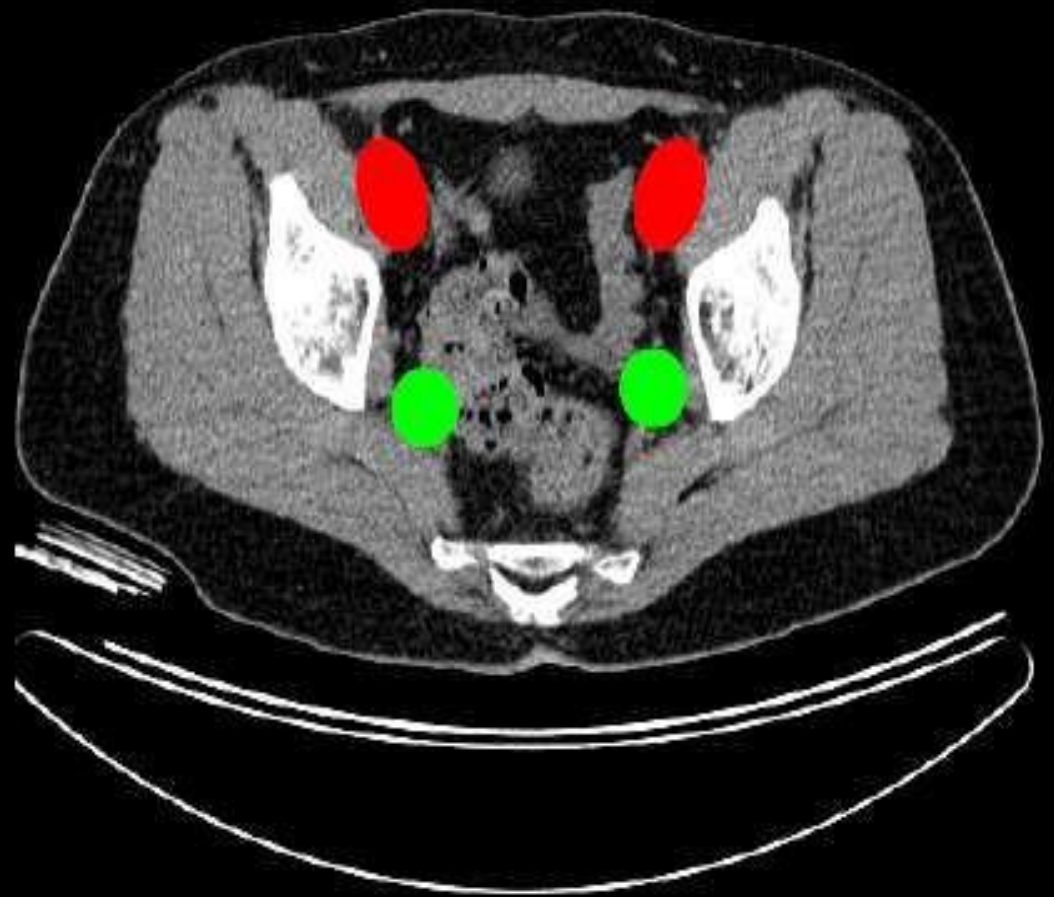
- Pelvic groups
  - Common iliac
  - Internal iliac



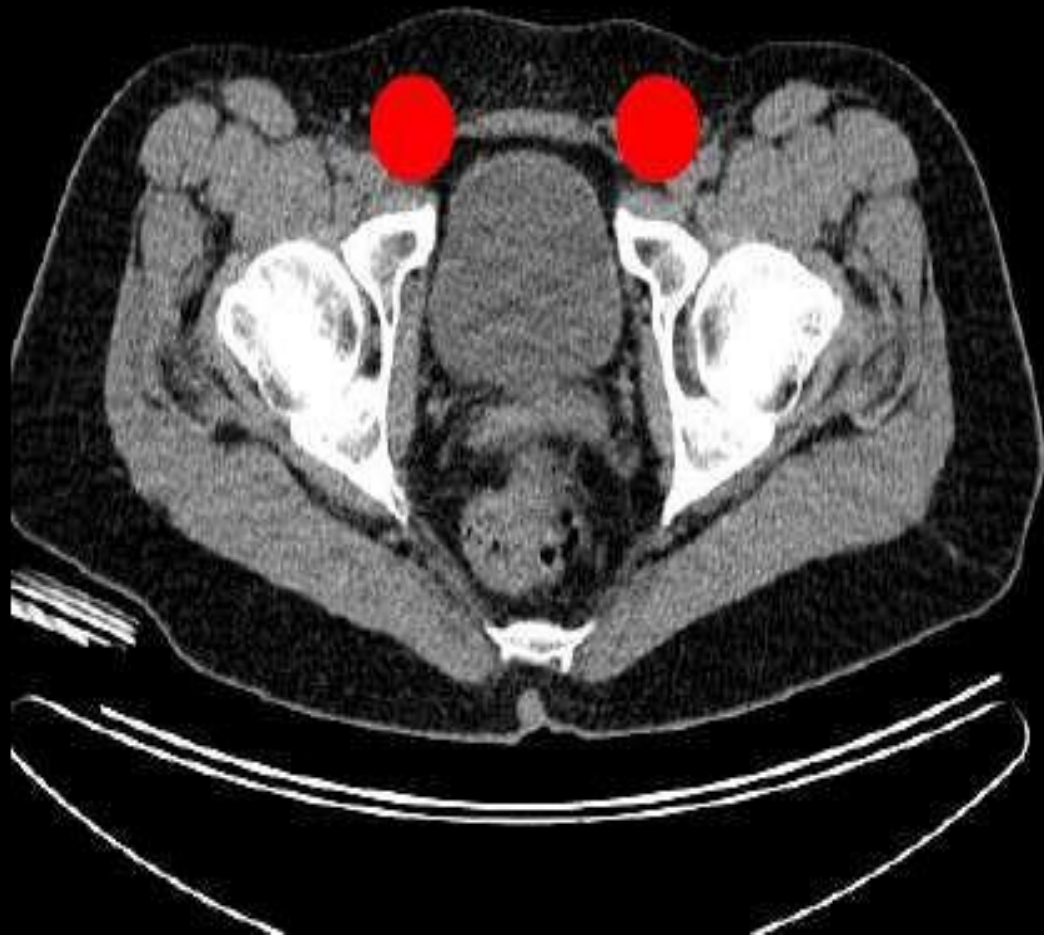- Pelvic groups
  - Common iliac
  - Internal iliac
  - External iliac



- Pelvic groups
  - Common iliac
  - Internal iliac
  - External iliac

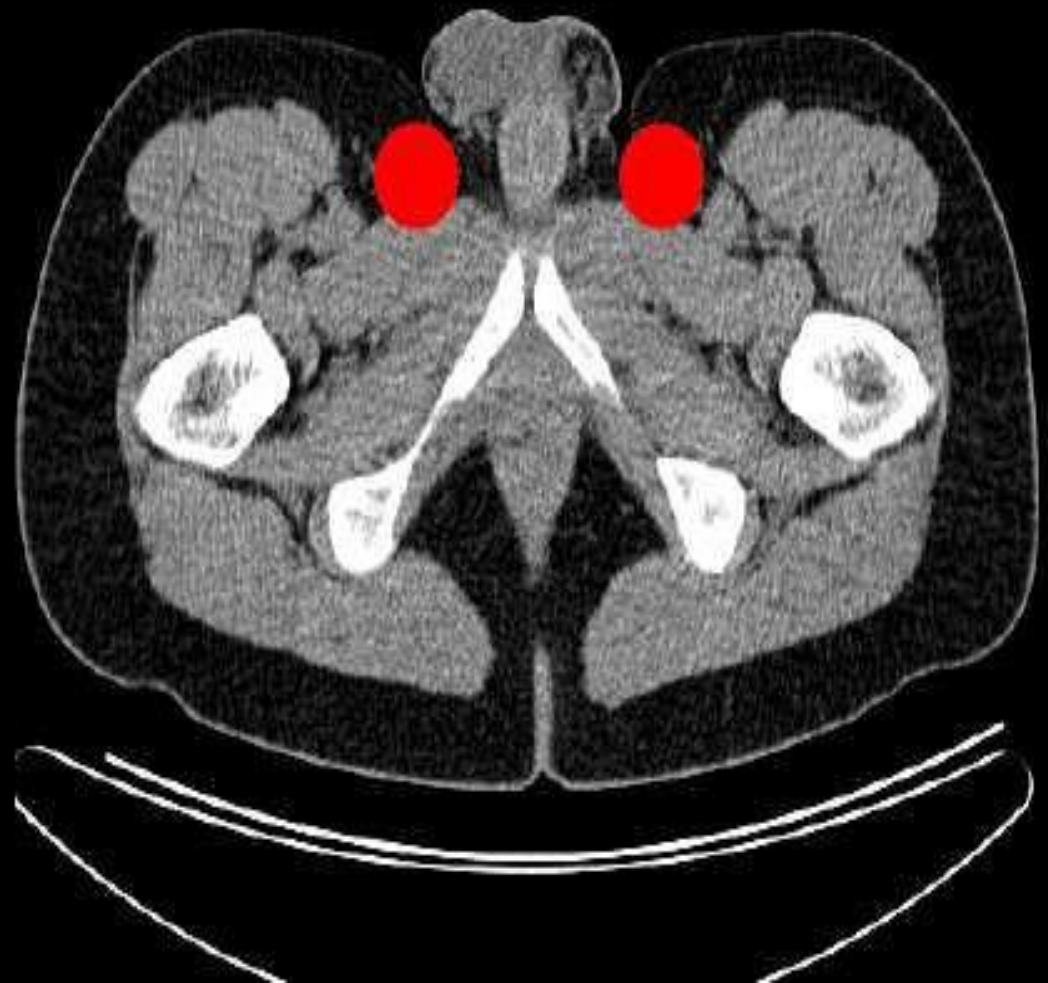

- Pelvic groups
  - Common iliac
  - Internal iliac
  - External iliac
  - Inguinal



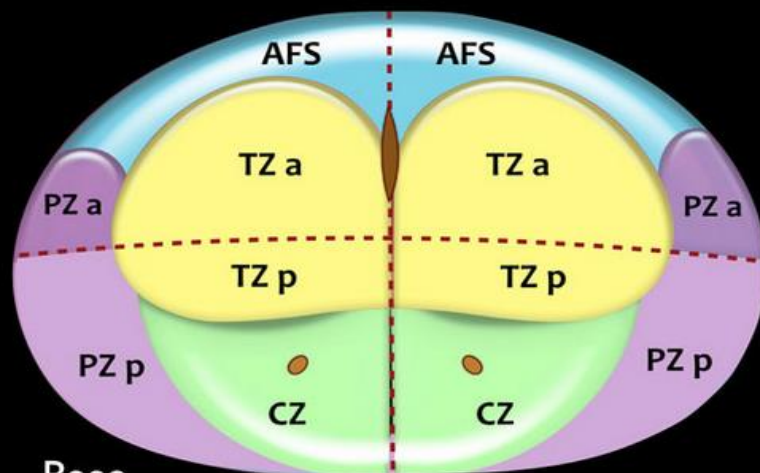


- Pelvic groups
  - Common iliac
  - Internal iliac
  - External iliac
  - Inguinal

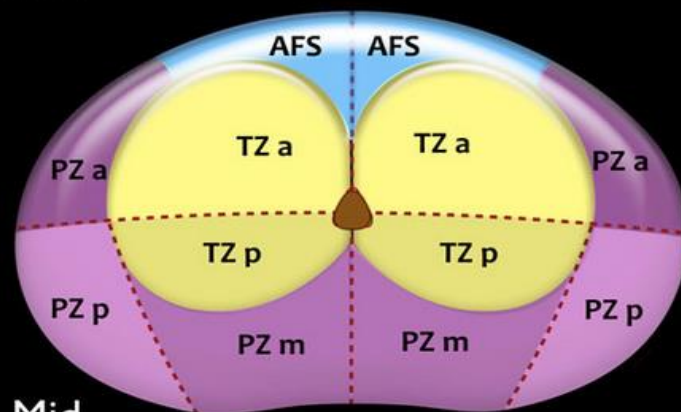




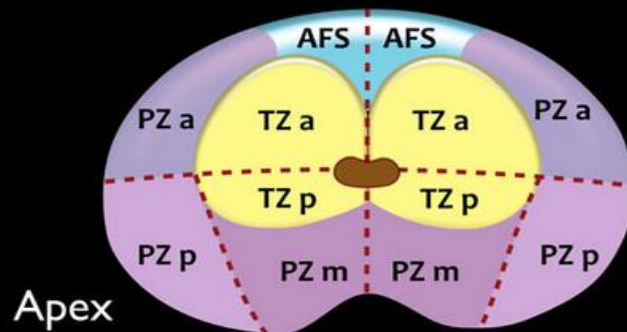
**MALE**



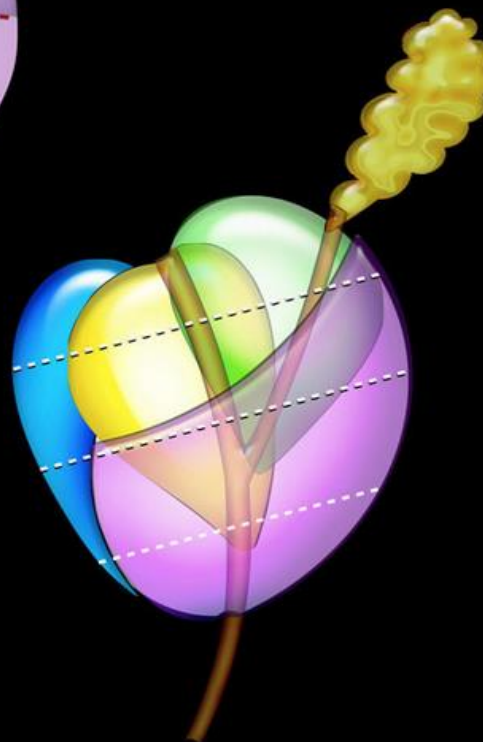
Base



Mid

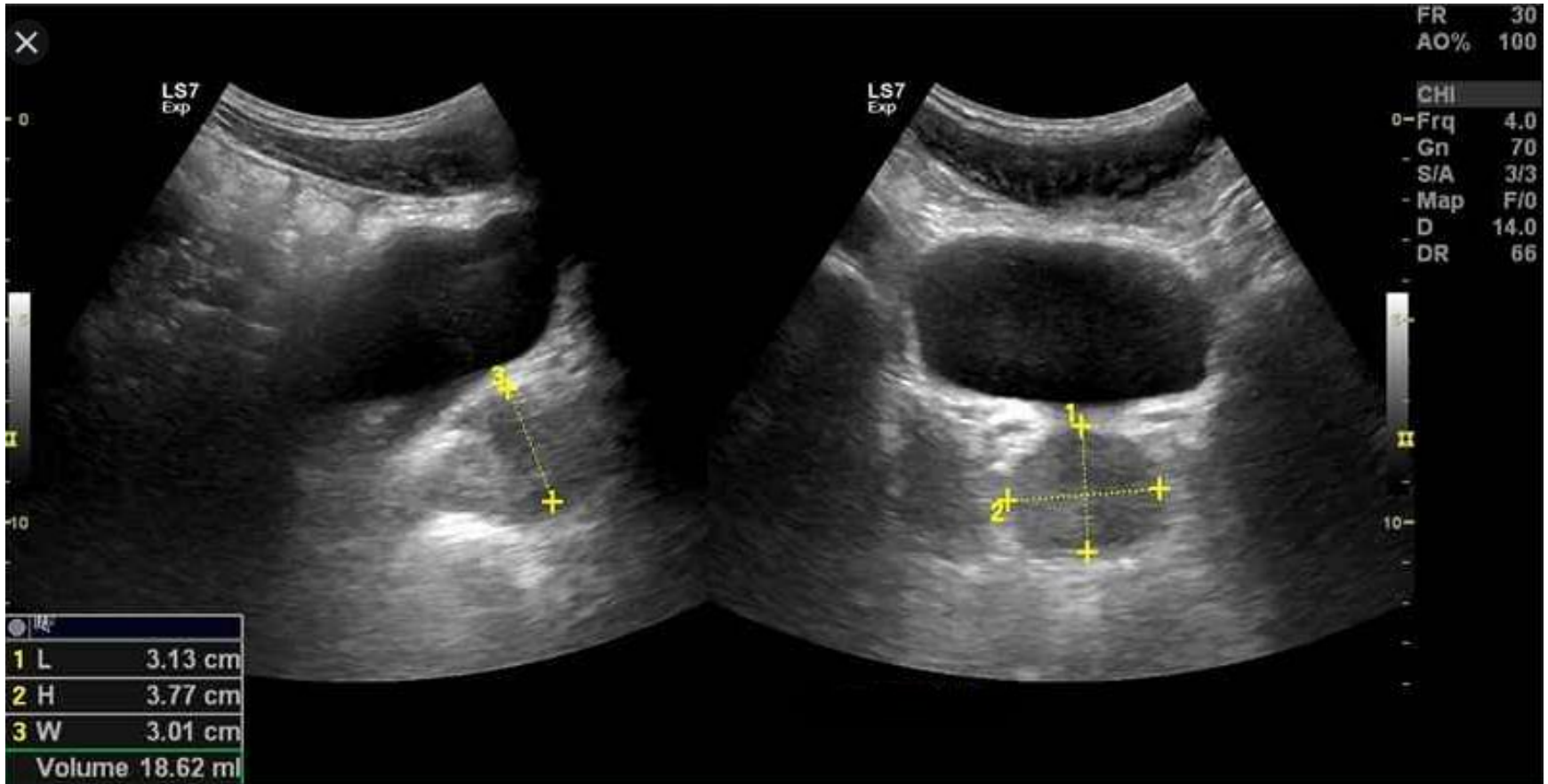


Apex



ULTRASOUND

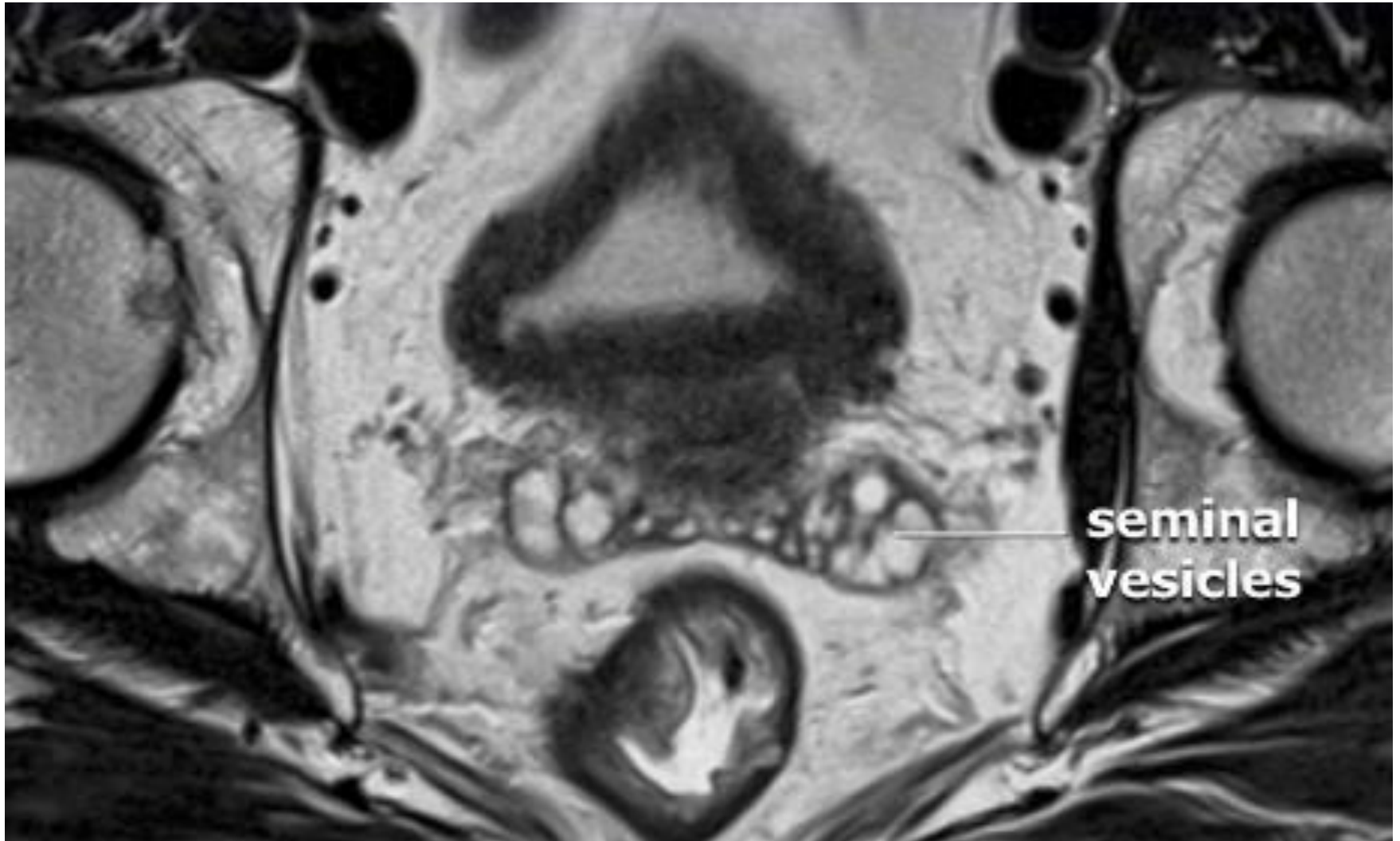
# TRANSABDOMINAL USG



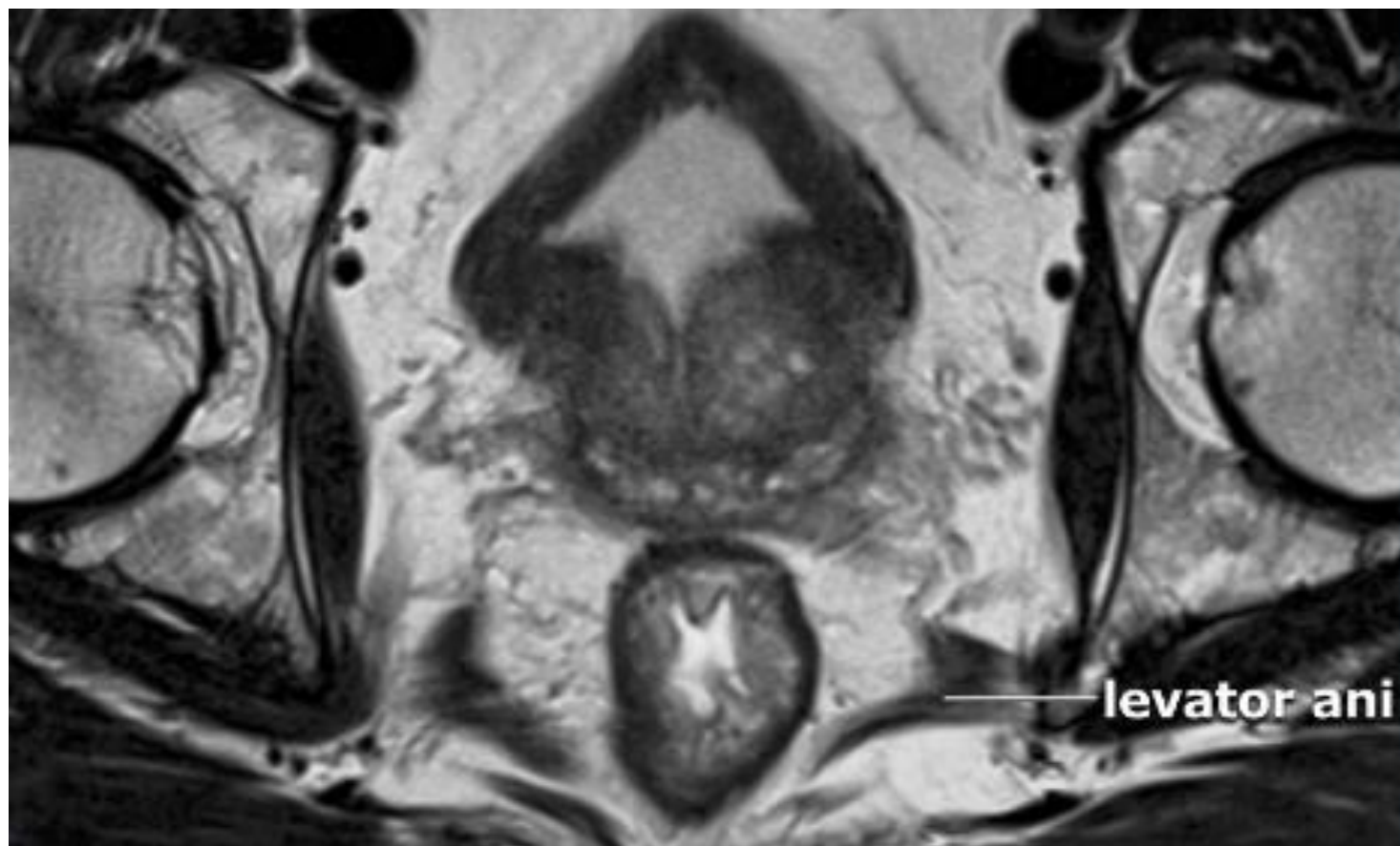
# MRI - ANATOMY



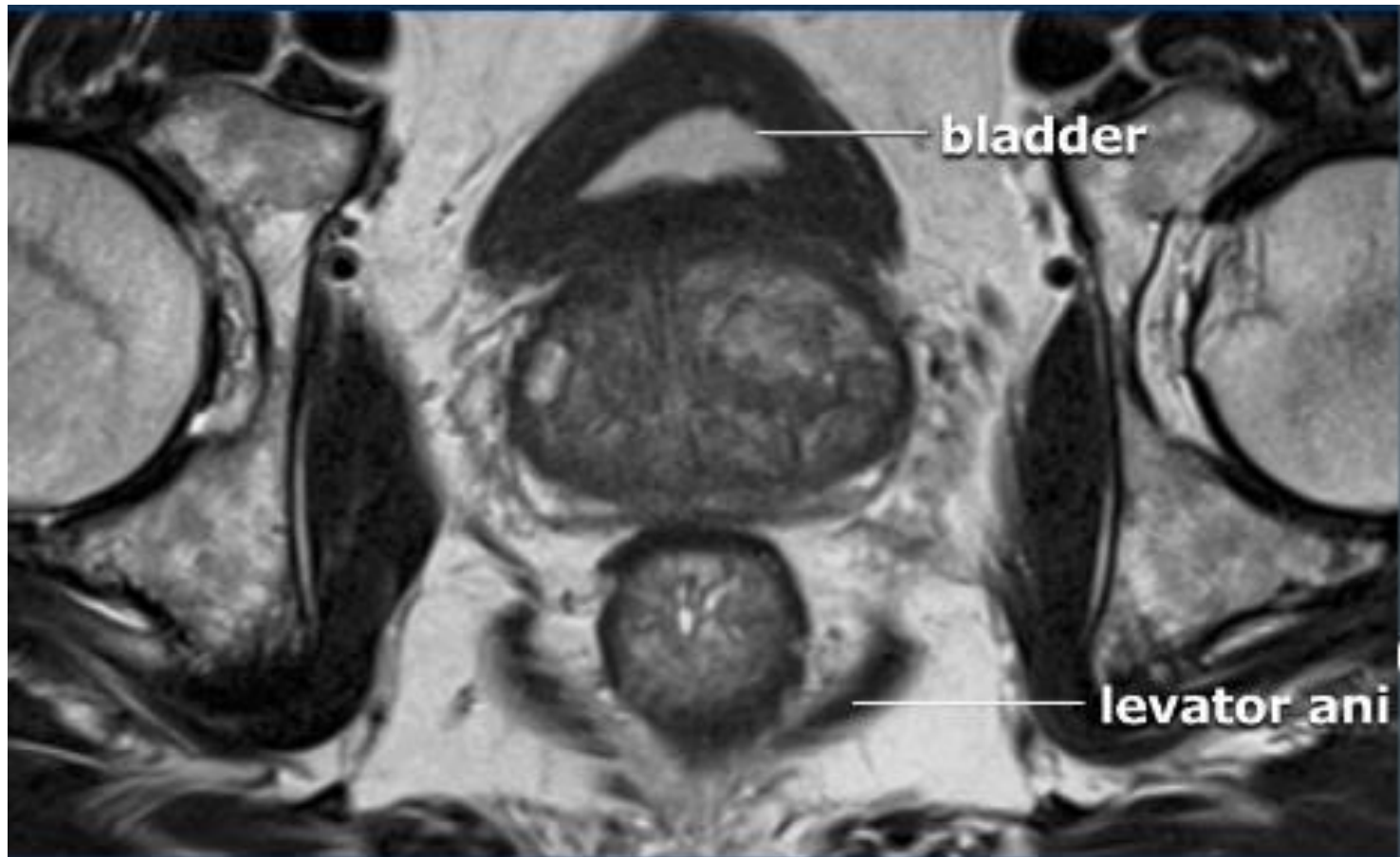
# MRI - AXIAL



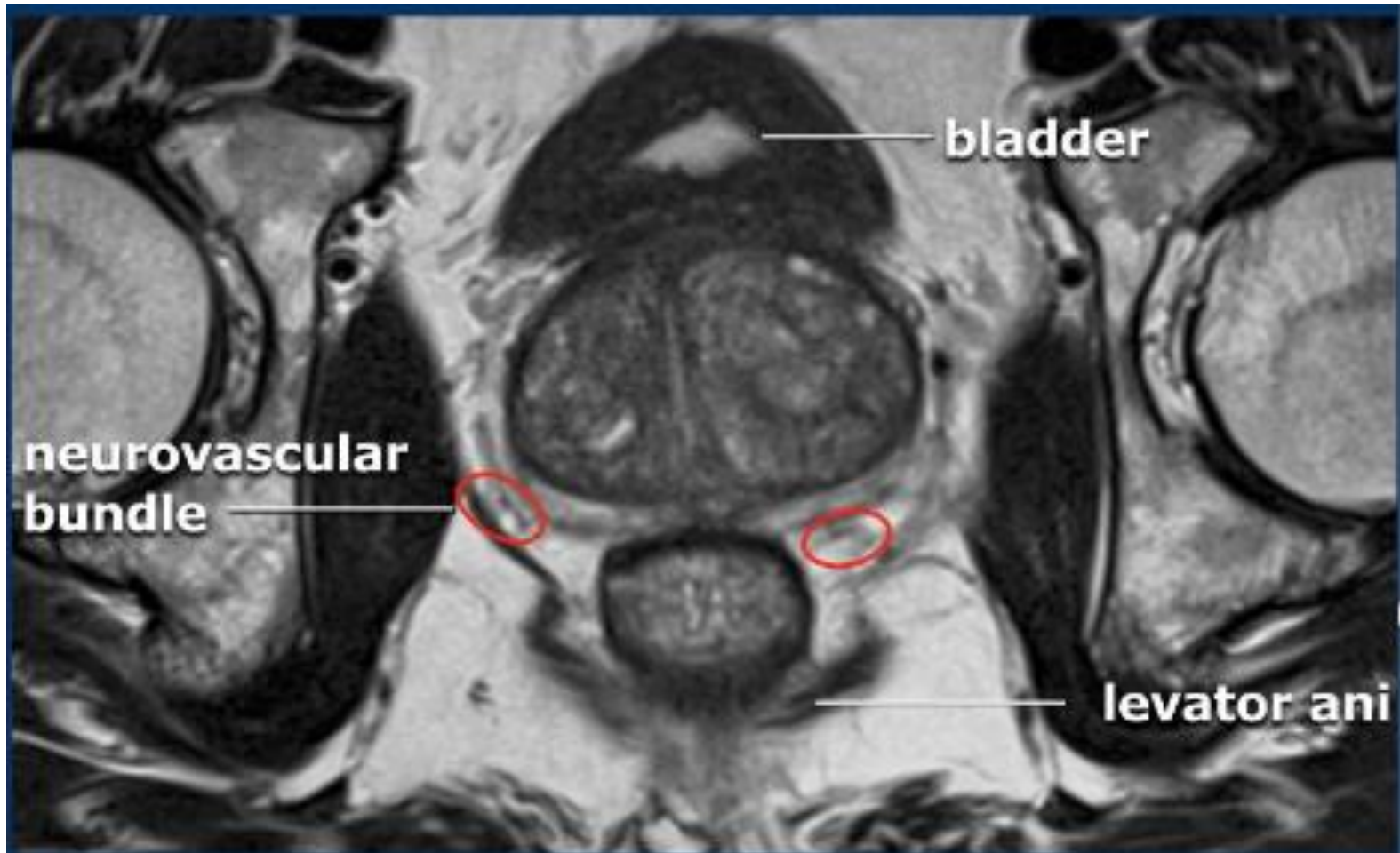
# MRI



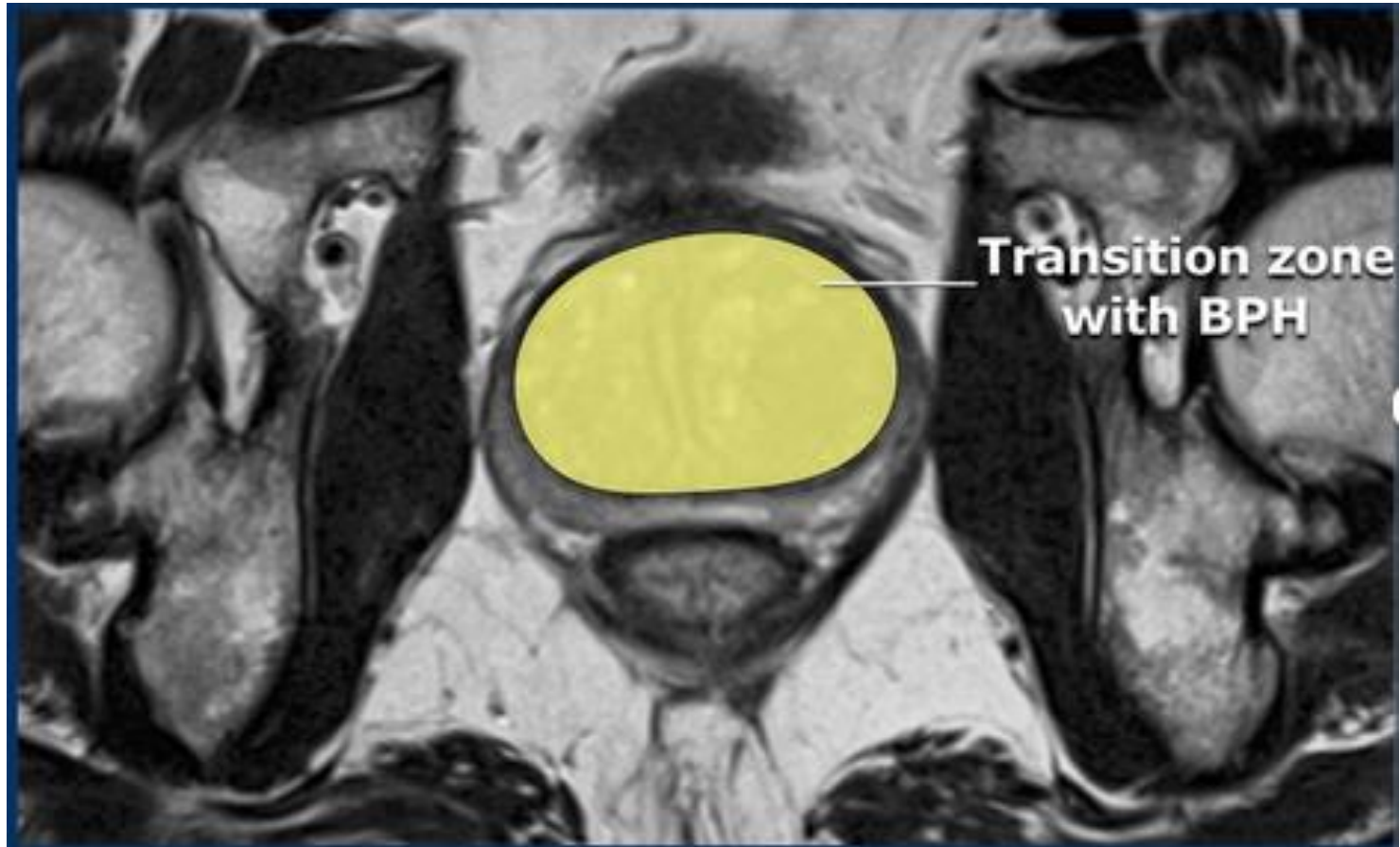
# MRI



# MRI

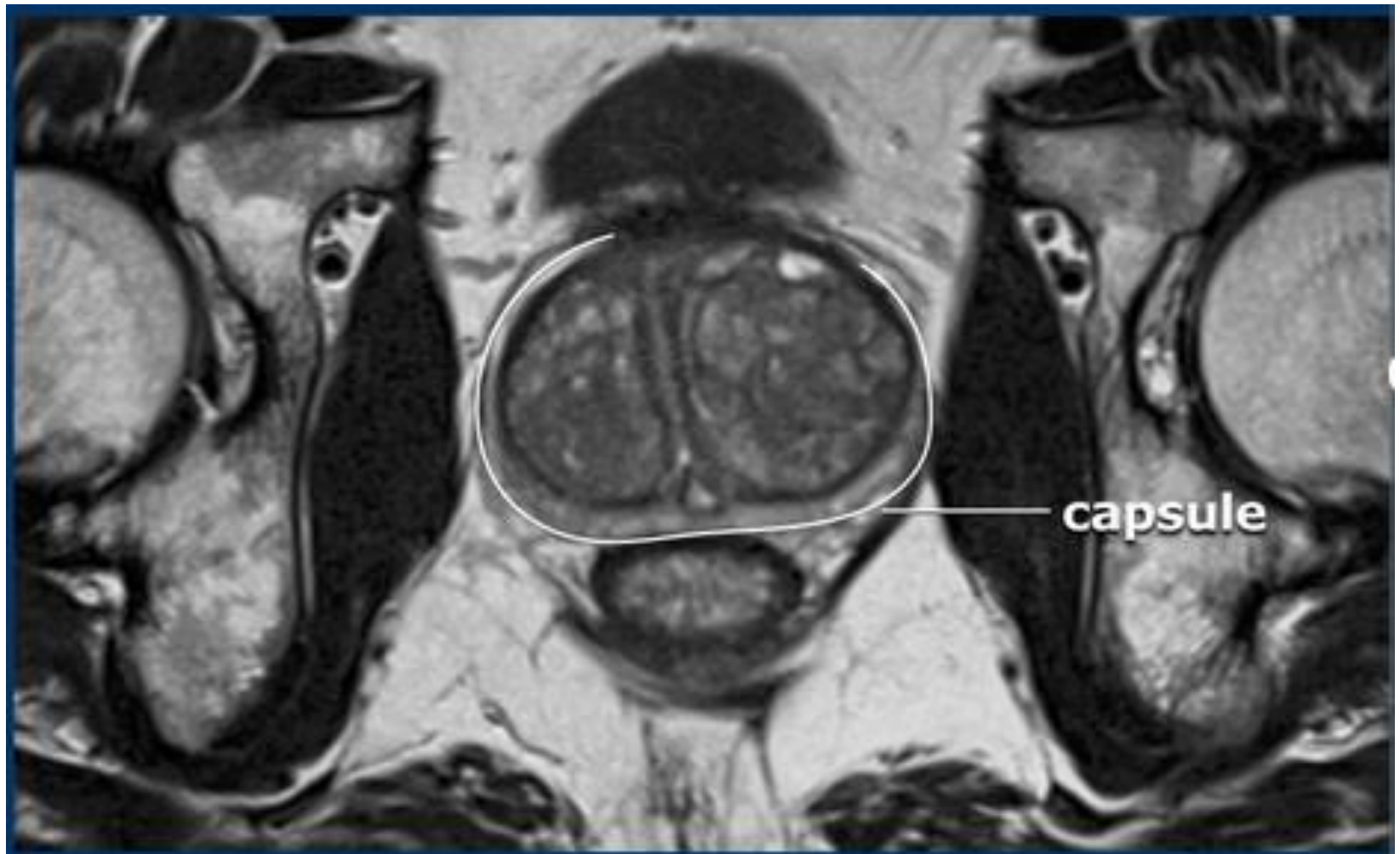


# MRI

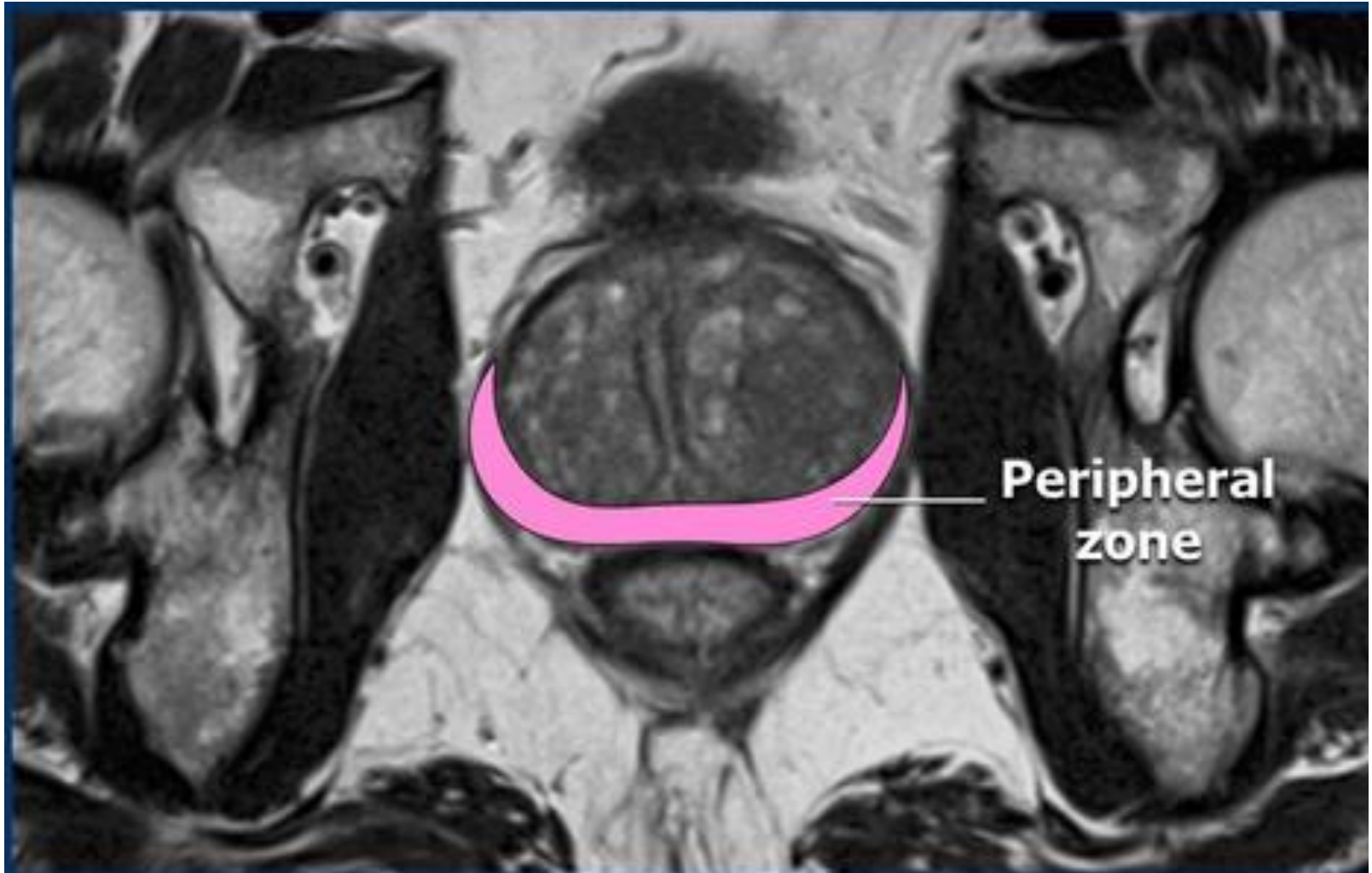




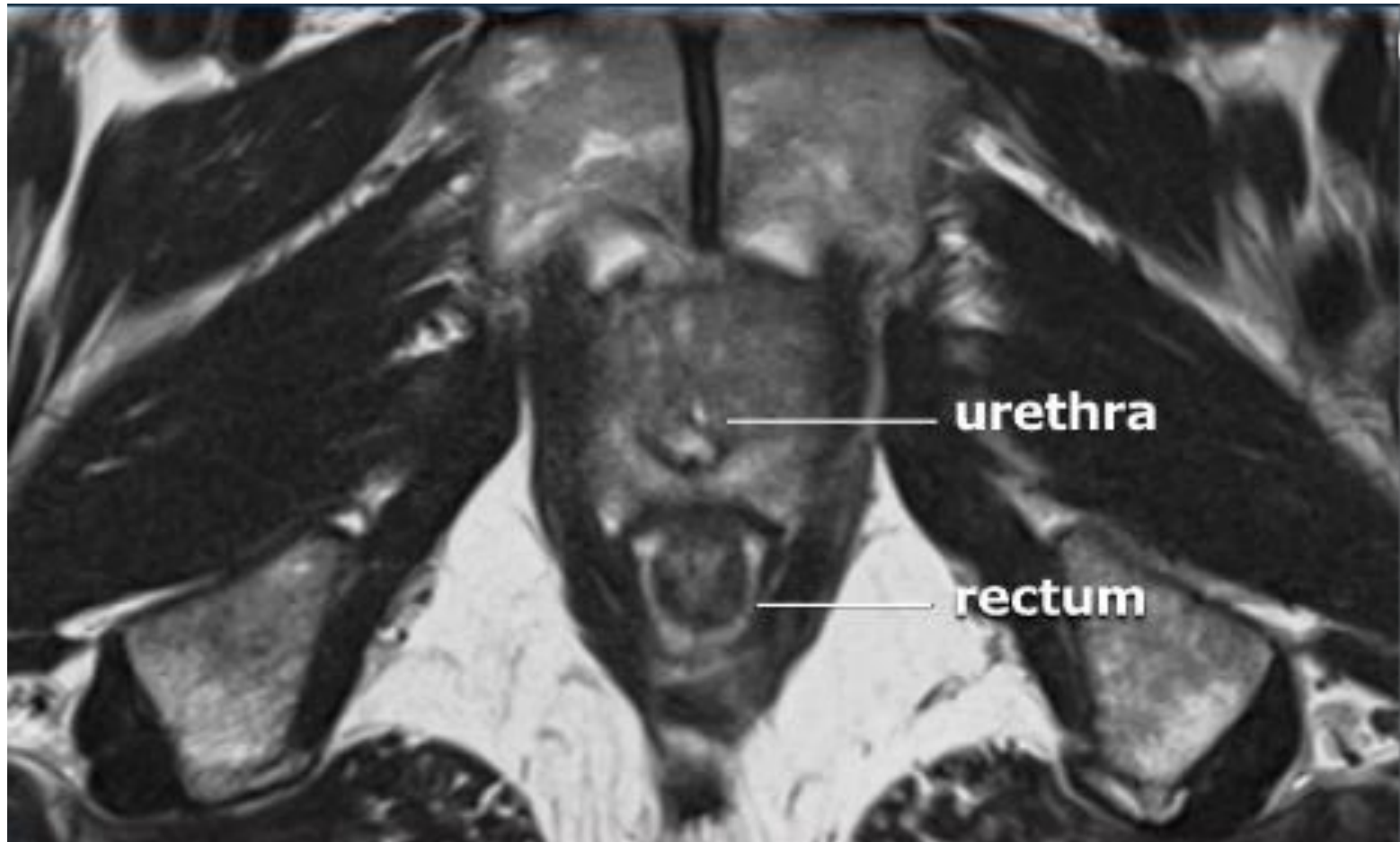
# MRI



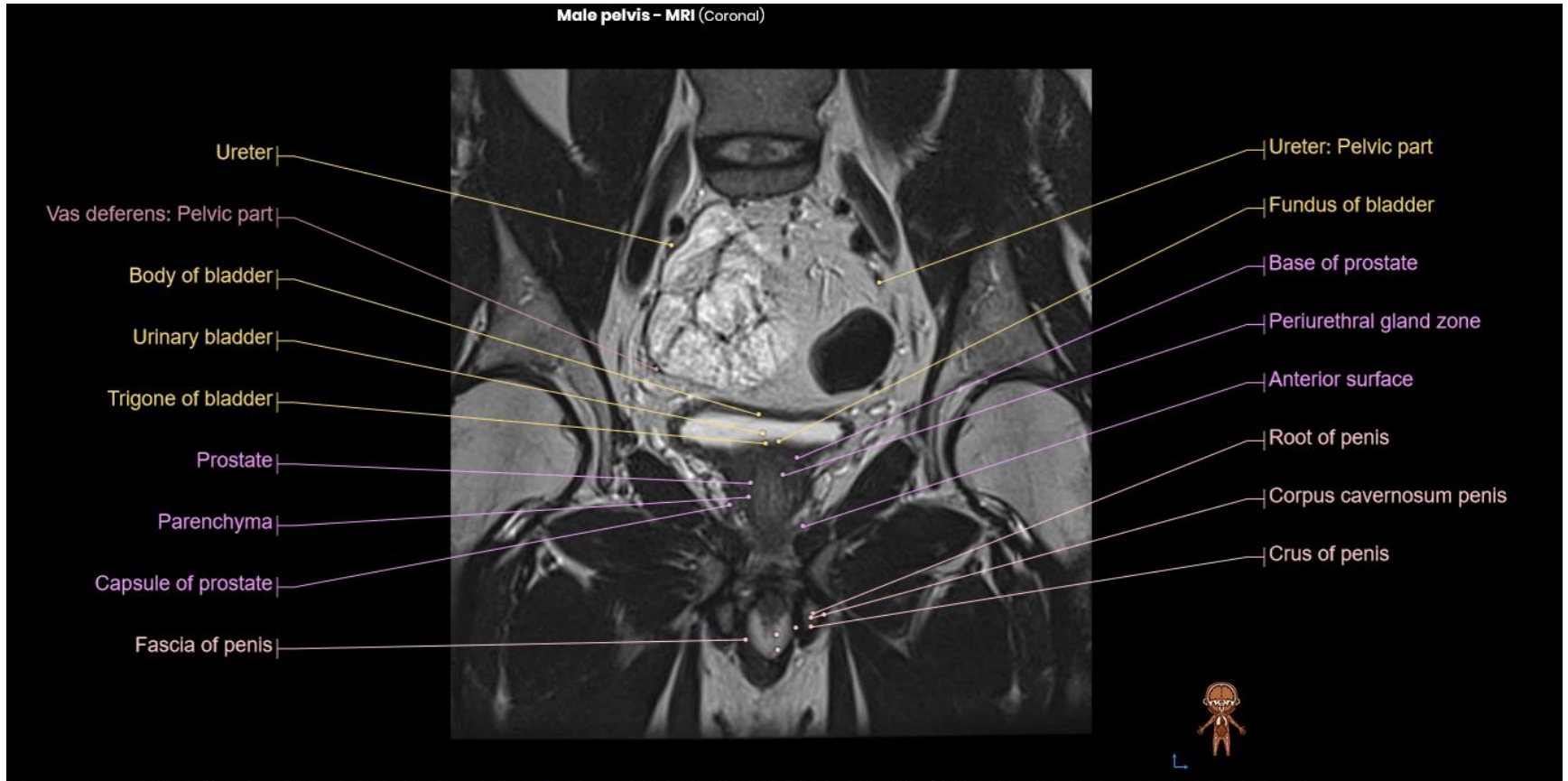
# MRI



# MRI

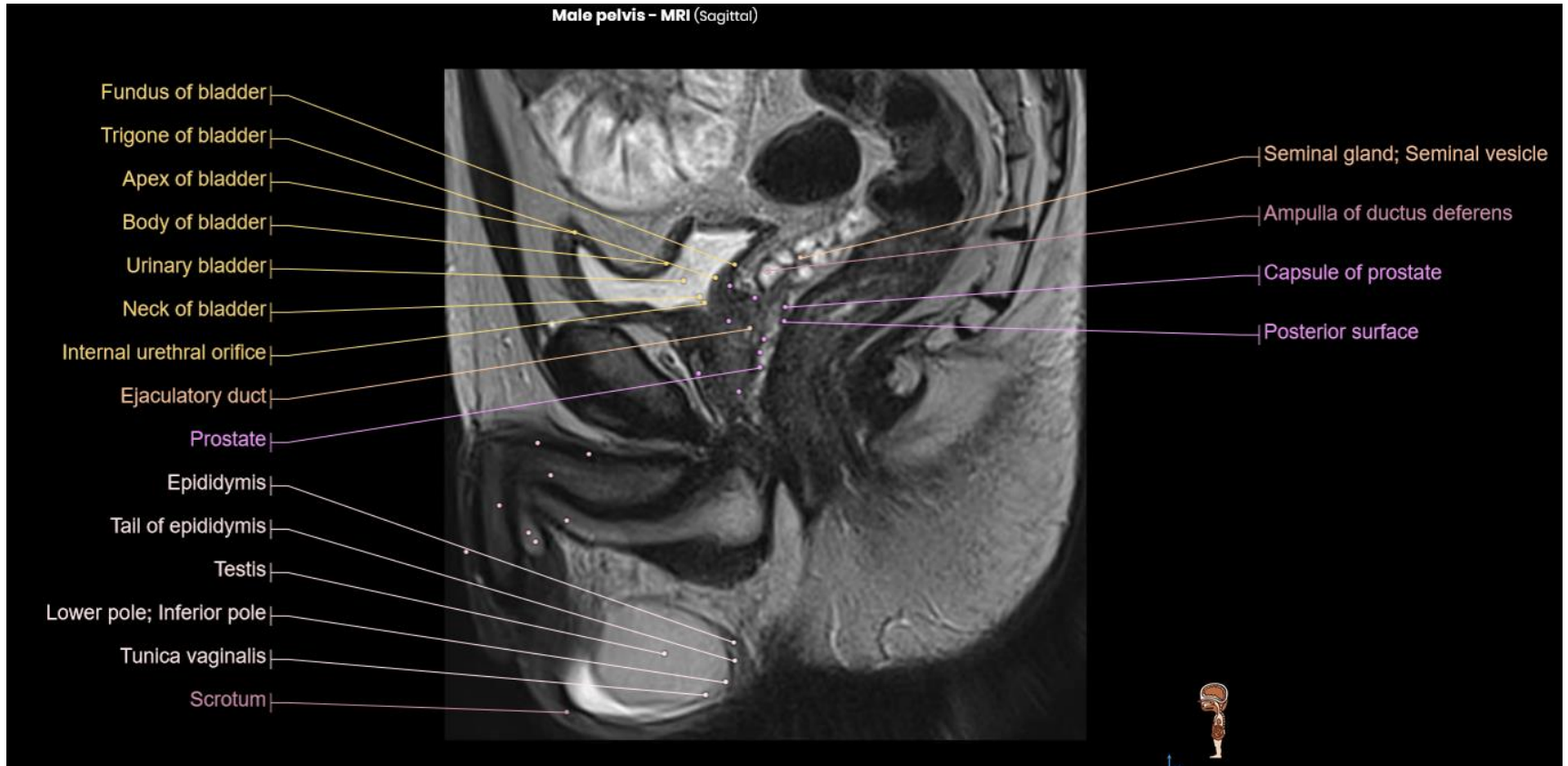


# MRI - CORONAL





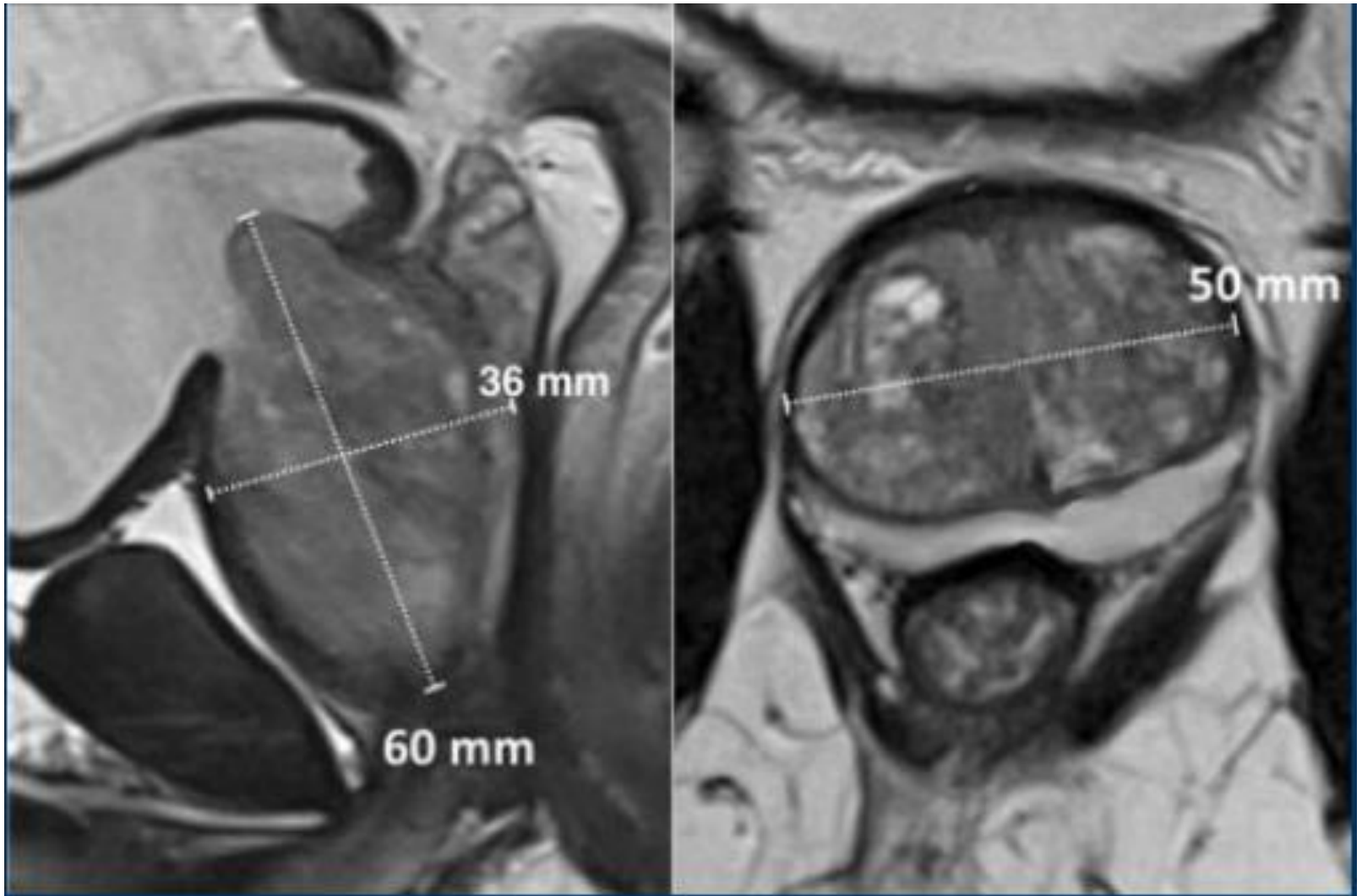
# MRI - SAGITTAL





# PROSTATE VOLUME

# PROSTATE VOLUME



# PSA DENSITY

## PSA density

Prostate volume = Length x Width x Height x 0.52

$$\text{PSA density} = \frac{\text{PSA value}}{\text{Prostate volume}}$$

# PIRADS

## PI-RADS

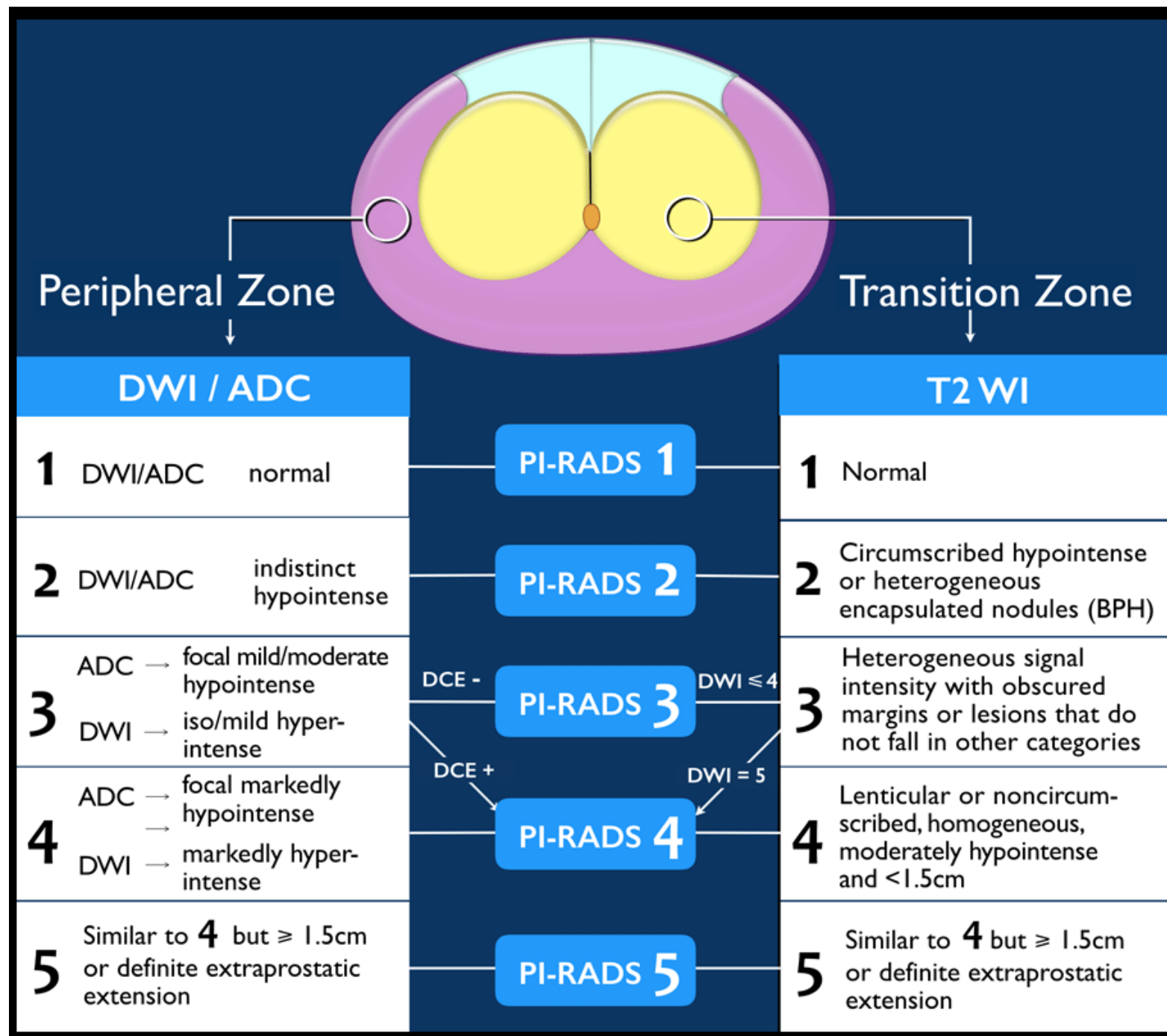
PI-RADS 1 = Very low (clinically significant cancer highly unlikely)

PI-RADS 2 = Low (clinically significant cancer unlikely)

PI-RADS 3 = Intermediate (clinically significant cancer equivocal)

PI-RADS 4 = High (clinically significant cancer likely)

PI-RADS 5 = Very high (clinically significant cancer highly likely)





**PERIPHERAL ZONE**

# Peripheral Zone

ADC

ADC

DWI

T2WI

1

Normal

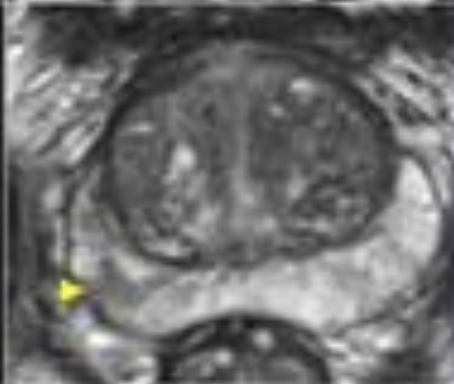
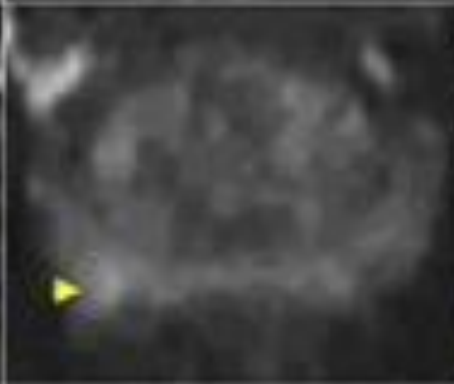
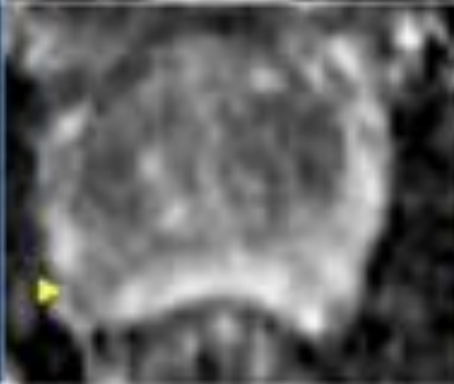
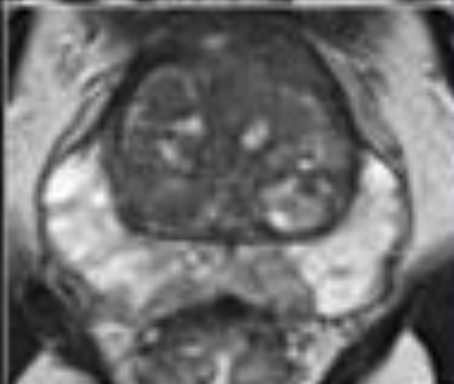
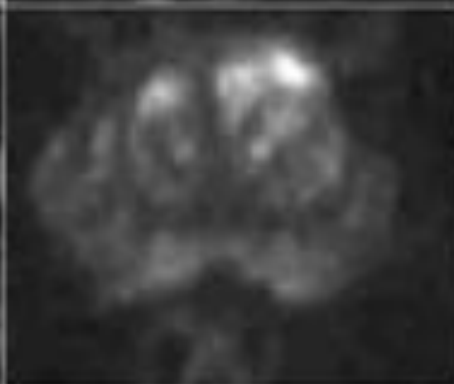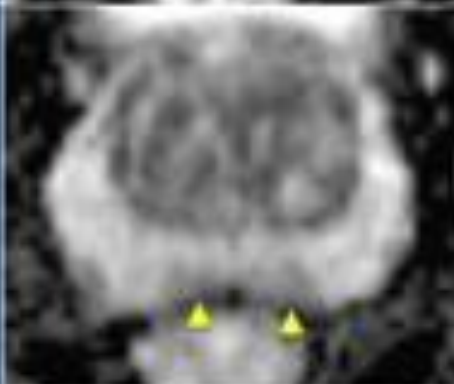
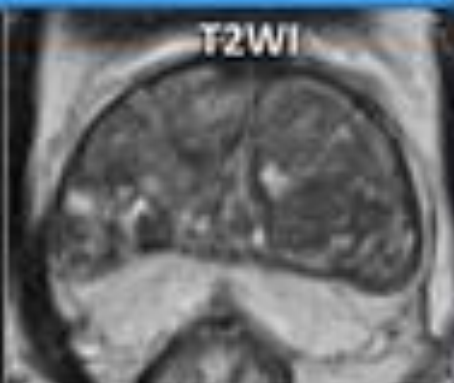
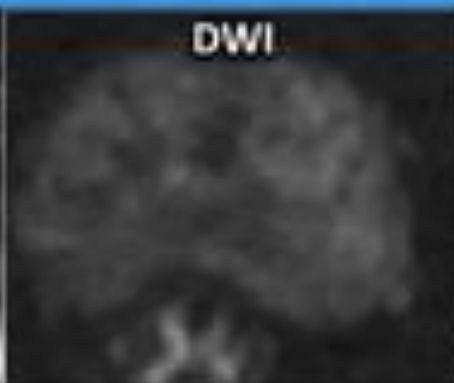
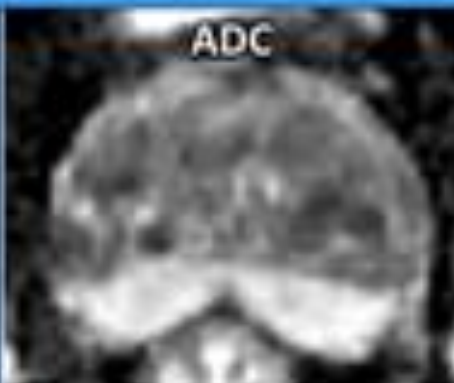
2

ADC: Indistinct  
hypointense

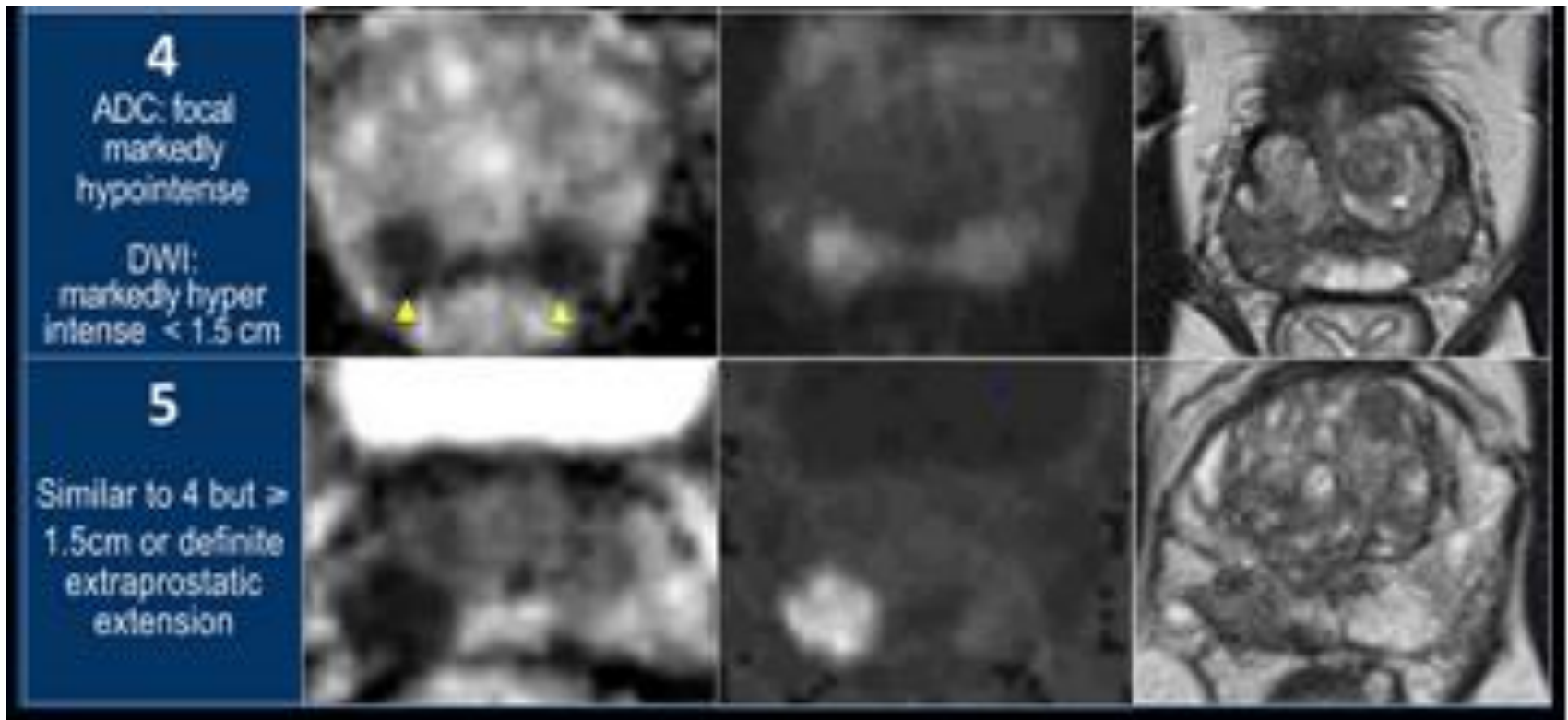
3

ADC: focal  
mild/moderate  
hypointense

DWI:  
iso/mild hyper  
intense < 1.5 cm


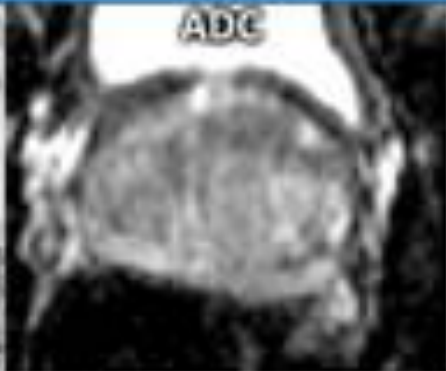
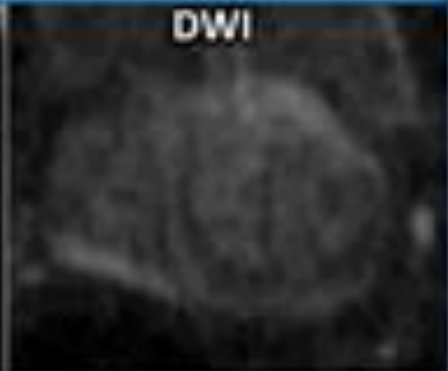
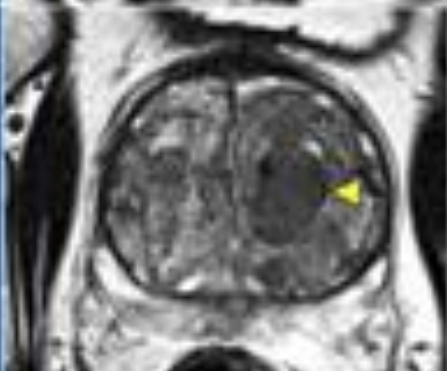


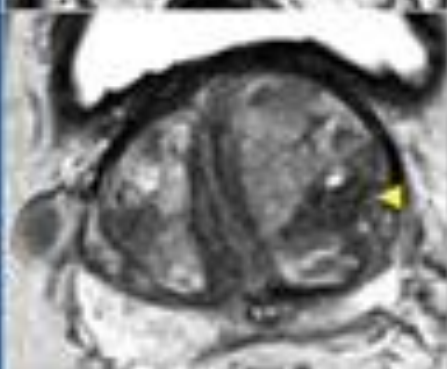
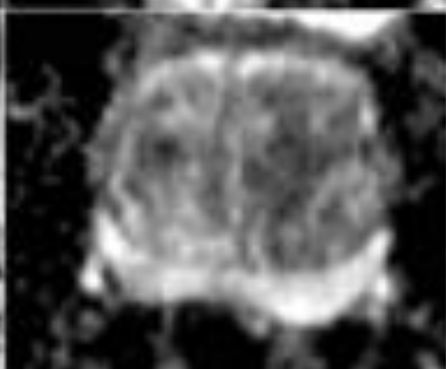



# PERIPHERAL ZONE



TRANSITION ZONE

# Transition Zone

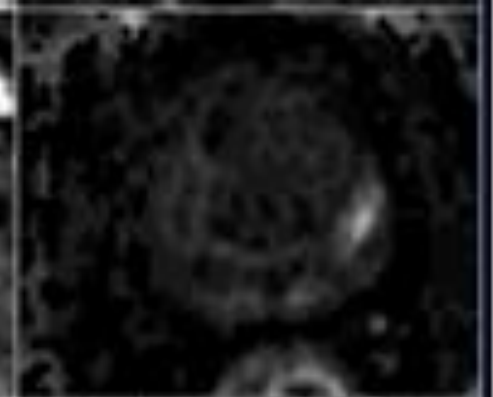
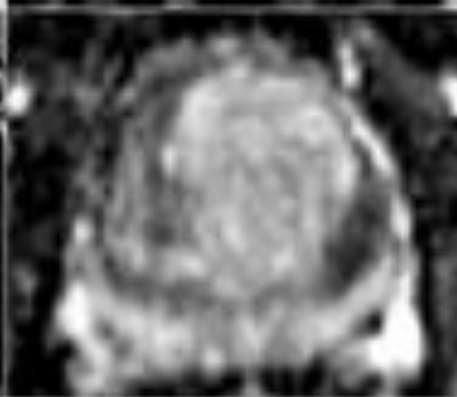
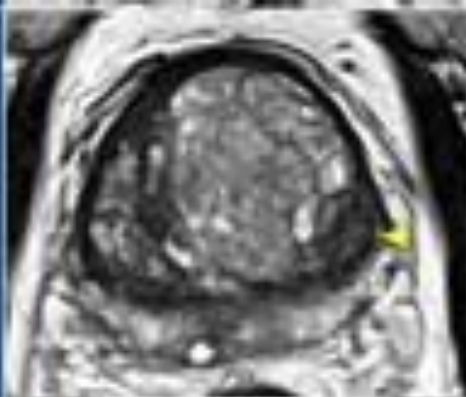
T2WI	T2WI	ADC	DWI
<b>1</b> Normal			
<b>2</b> Circumscribed hypointense or heterogeneous encapsulated nodules (BPH)			
<b>3</b> Heterogeneous signal intensity with obscured margins or lesions that do not fall in other categories			



# TRANSITION ZONE

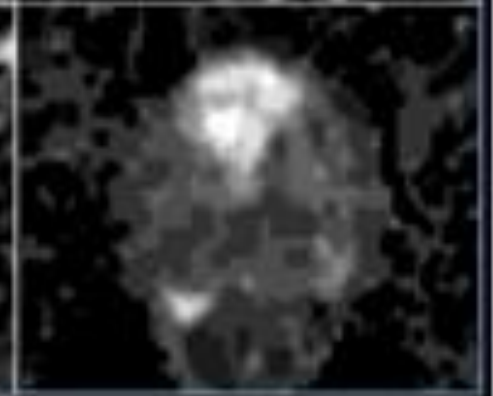
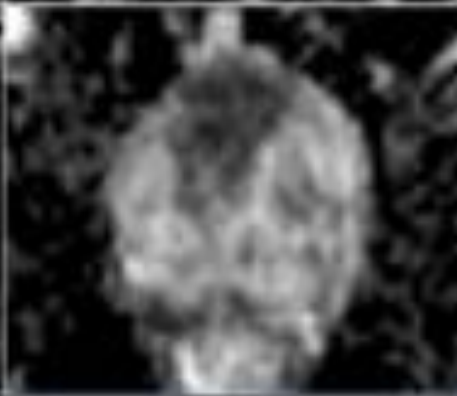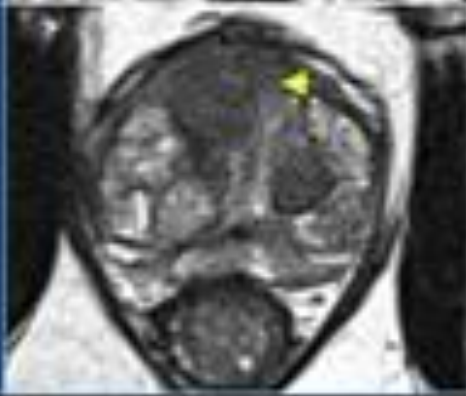4

Lenticular or noncircum-scribed, homogeneous, moderately hypointense and <1.5cm



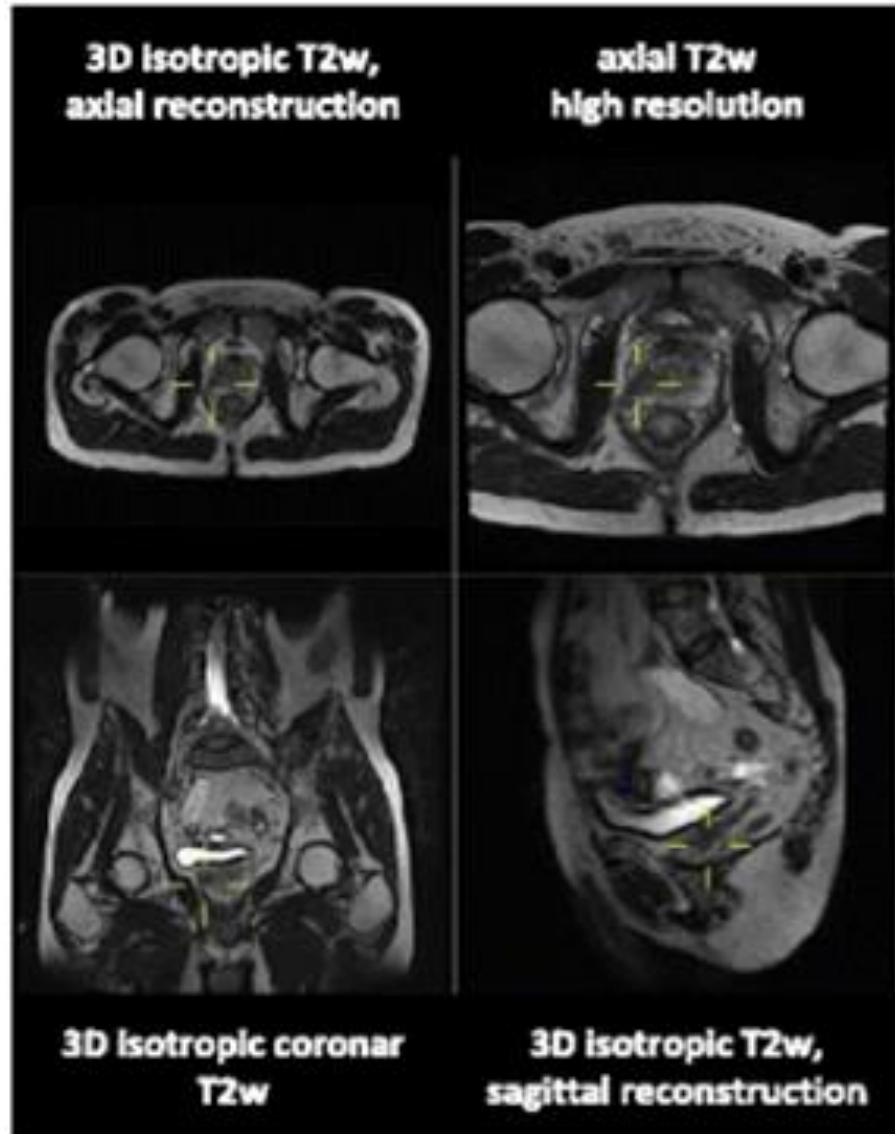
5

Similar to 4 but  $\geq$  1.5cm or definite extraprostatic extension

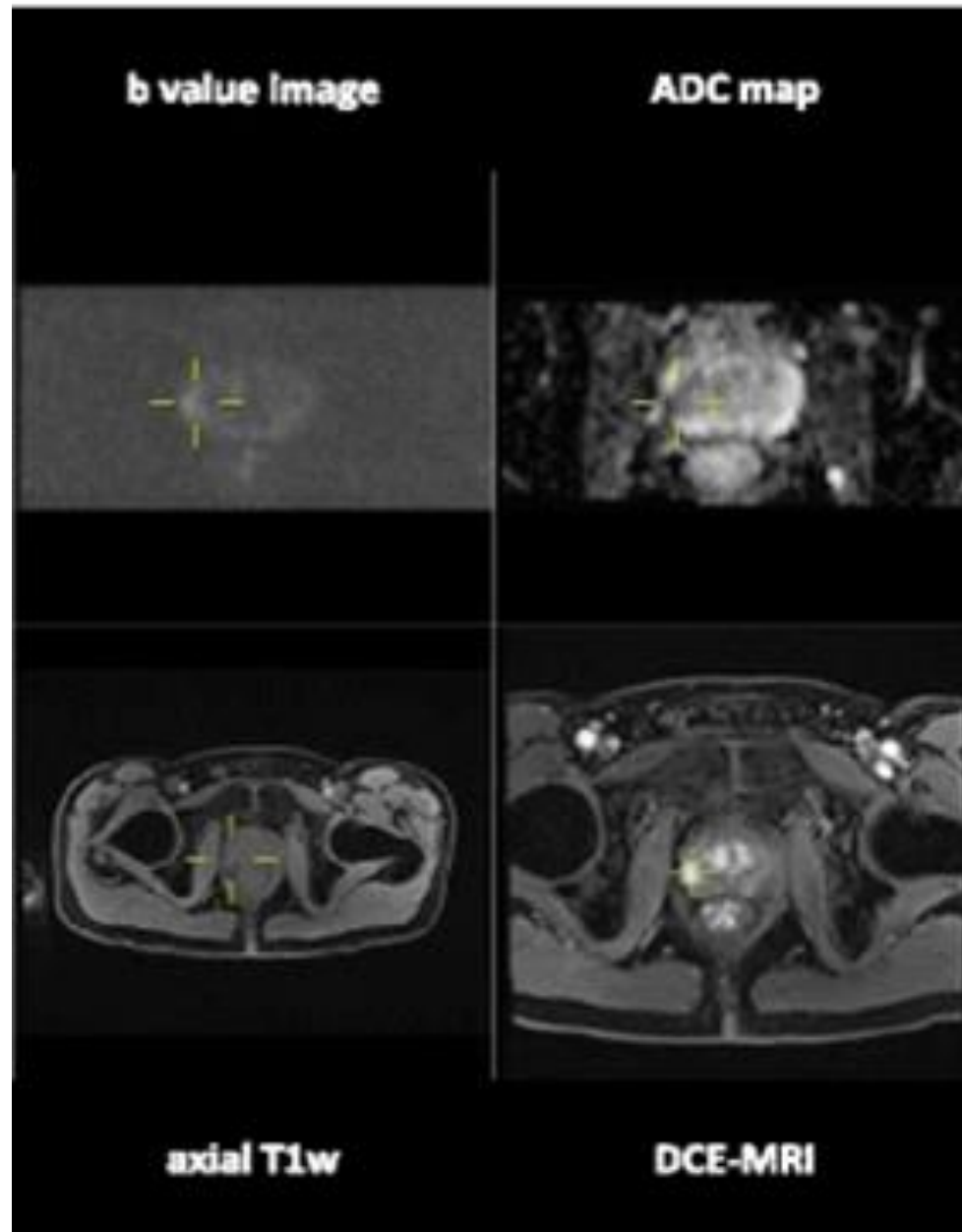


# **PROSTATE MRI BASED ON PI-RADS VERSION 2: HOW WE REVIEW AND REPORT**

# PROSTATE MRI BASED ON PI-RADS VERSION 2: HOW WE REVIEW AND REPORT

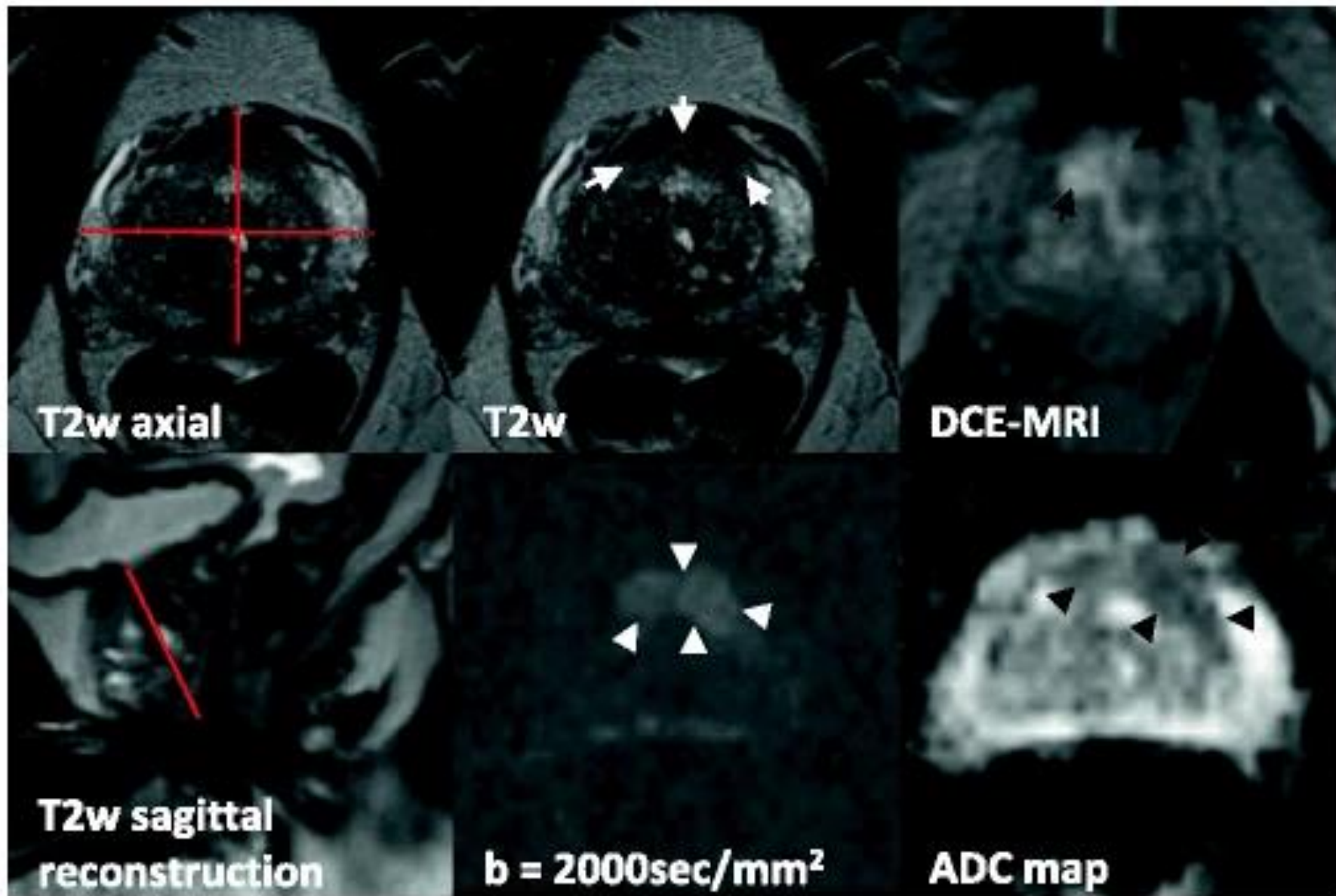


# PROSTATE MRI BASED ON PI-RADS VERSION 2: HOW WE REVIEW AND REPORT



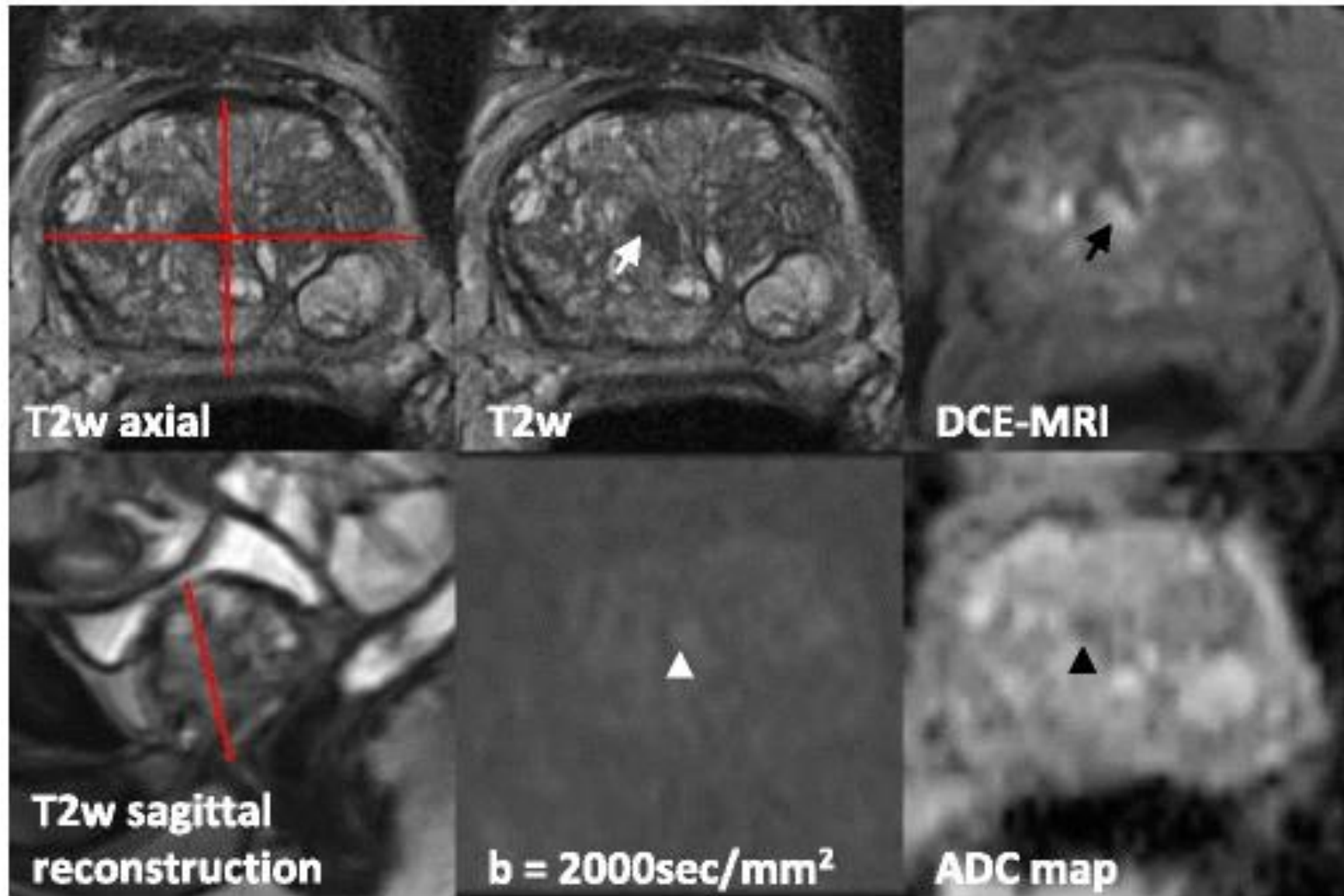
# RELEVANT CASES





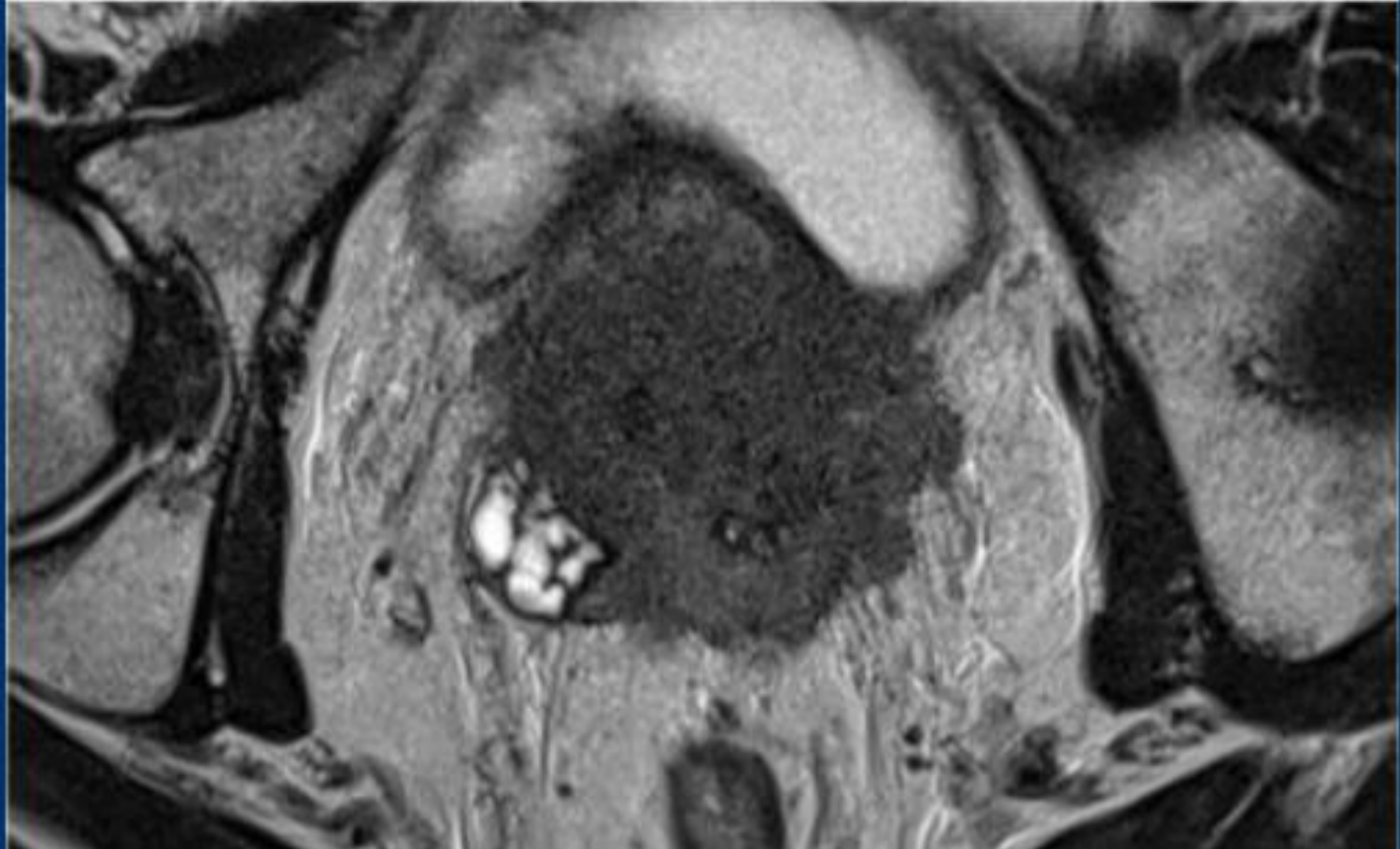
Enlarged prostate of circa 43 ml (44 mm × 51 mm × 37 mm × 0.52).

Peripheral zone: Midlevel on T2w image depicts a focal lesion of 20 mm maximal extension (PI-RADS 5) (white arrows). The lesion shows a high signal intensity in the anterior fibromuscular stroma and in the left peripheral anterior zone on the high b-value DW image (white arrowheads) with corresponding low signal intensity on the ADC map (black arrowheads) ( $ADC \sim 580 \times 10^{-6} \text{mm}^2/\text{s}$ ) (PI-RADS 5). DCE-MRI is rated positive, showing a focal enhancement, earlier than adjacent prostate tissue (black arrows). Transition zone: Circumscribed hypointense encapsulated nodules (BPH) (PI-RADS 2). No suspicious locoregional or pelvic lymph nodes. No suspicious bone lesions. No additional findings.

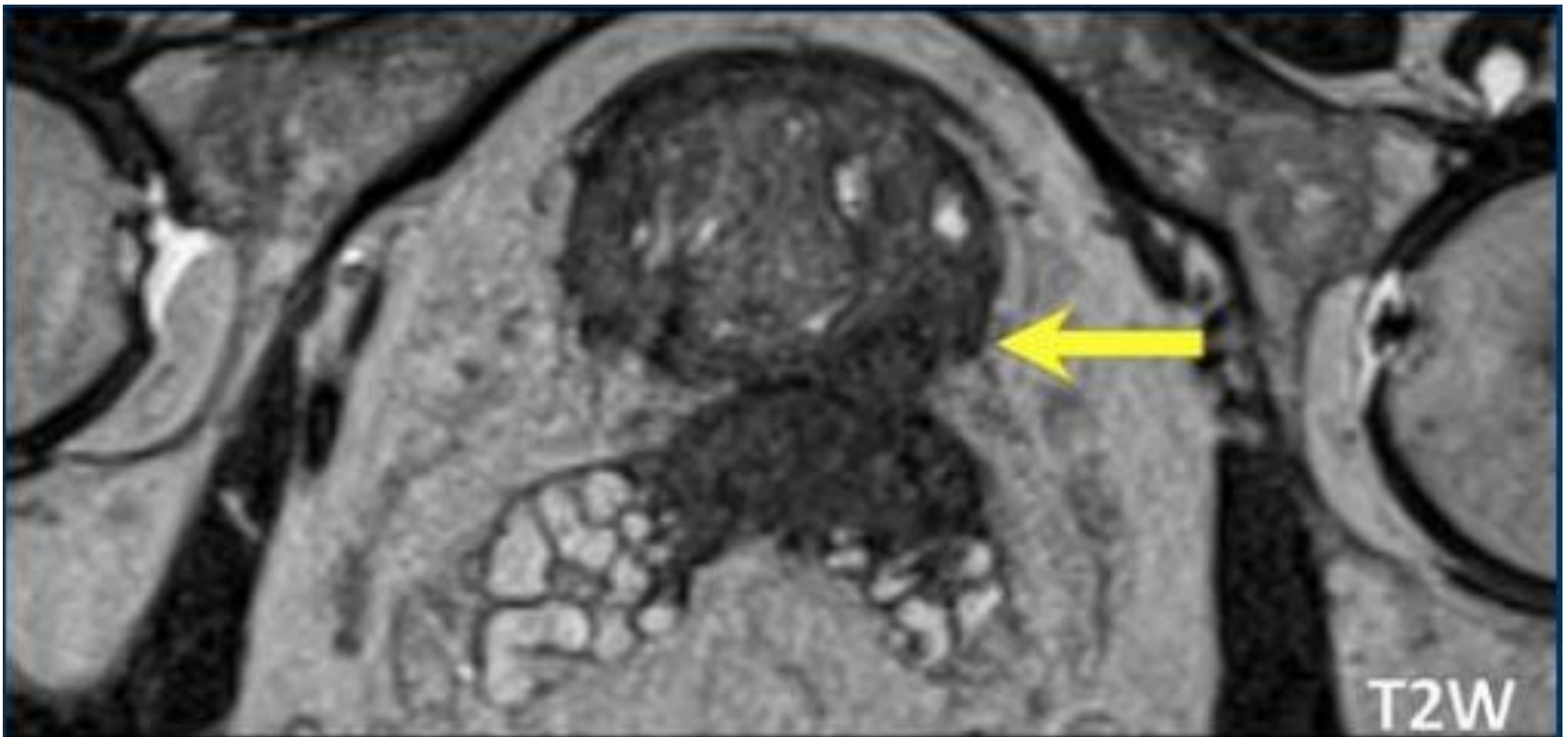


Enlarged prostate of circa 48 ml (58 mm × 38 mm × 42 mm × 0.52). Peripheral zone: On high b-value DW images and ADC map normal peripheral zone with indistinct hypointensities on the ADC map (PI-RADS 2). Transition zone: On T2w image lesion of 9 mm maximal extension (white arrow) at the mid-level in the anterior half on the right with heterogeneous, indistinct triangular, signal intensity with obscured margins with mild hypointense signal (PI-RADS 3). The lesion is showing mildly hyperintense signal on high b-value DW image (white arrowhead) and moderate signal intensity on ADC map (black arrowhead) (ADC ~850 × 10<sup>-6</sup>mm<sup>2</sup>/s) (PI-RADS 3). DCE-MRI is rated positive, showing a focal enhancement, earlier than adjacent prostate tissue (black arrow). Multiple circumscribed hypointense encapsulated nodules (BPH) (PI-RADS 2).

# Poorly differentiated adenocarcinoma of the prostate



# PROSTATE CANCER EXTENDING INTO BOTH SEMINAL VESICLES





# CONCLUSION

## Checklist

### Clinical information

Indication

PSA

Biopsies: date - results

### Findings

Prostate volume

PSA density

Postbiopsy hemorrhage

### Lesion characteristics

Diameter

Location (39 sector model)

T2 and DWI characteristics

Signs of extraprostatic growth

### Conclusion

PI-RADS classification

Morphology and location



# *All India Institute of Medical Sciences*

## *Rishikesh*

**Thanks for your kind attention**

