

WORK UP, REACHING A DIAGNOSIS AND PATHOLOGY OF BREAST CANCER

Dr Devleena (Mukherjee)
MD, DNB, PDCR, ECMO
Consultant Oncologist
AMRI Hospitals, Kolkata

Symptoms

Lump – Often the first symptom

Changes in skin texture

Nipple discharge

Dimpling

Lymph nodal changes

Breast or nipple pain

Nipple retraction or inversion

Redness

Swelling

Work up – Triple assessment

- ▣ History and clinical examination
- ▣ Imaging(USG/ Mammography)
- ▣ Confirmation by Pathological assessment

Relevant h/o in women with palpable breast mass

LUMP CHARACTERISTICS

- 1) Changes in size over time
- 2) Changes relative to menstrual cycle
- 3) Duration of mass
- 4) Pain or swelling
- 5) Redness, fever and discharge

FAMILY HISTORY

- 1) H/O Breast disease in a family
- 2) Relationship to patient
- 3) Relative age of onset

Relevant h/o in women with palpable breast mass

MEDICAL & SURGICAL H/O

- 1) Previous h/o of breast cancer
- 2) Previous breast masses or surgery
- 3) Recent breast trauma or surgery
- 4) Recent Radiotherapy or chemotherapy
- 5) Other exposure of Radiation

PERSONAL CHARACTERISTICS

- 1) Age at first childbearing
- 2) Age at Menarche
- 3) Age at Menopause
- 4) Current age
- 5) Current lactation status
- 6) h/o breast feeding
- 7) Number of children

Relevant h/o in women with palpable breast mass

SOCIAL HISTORY

- ▣ Radiation and chemical exposure
- ▣ Smoking

DIET OR MEDICATION

- ▣ Current Medication
- ▣ History of hormone therapy

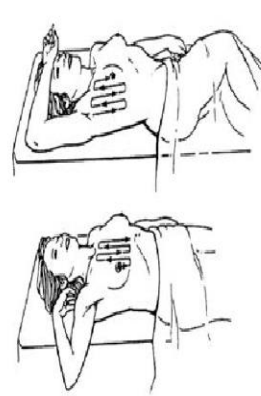
Evaluation: Physical Exam

- **Clinical Breast Exam:**
 - **Inspect (relaxed, arms raised, hands on hips)**
 - Breast symmetry
 - Skin changes (dimpling, retraction, edema, ulceration)
 - Nipples (symmetry, inversion/retraction, discharge)
 - **Palapation (breasts, axillae, entire chest wall)**
 - Pain
 - Masses
 - Regional lymph nodes (Axillary and Supraclavicular)
 - **Documentation**
 - “Clock” system
 - Location of concern and abnormality
 - Distance from areola
 - Size of mass

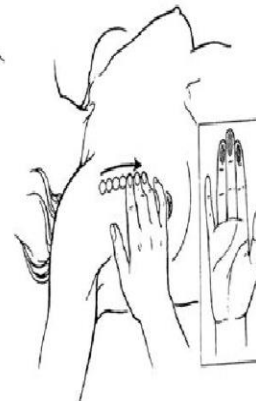
What Is Normal?

Evaluation: Physical Exam

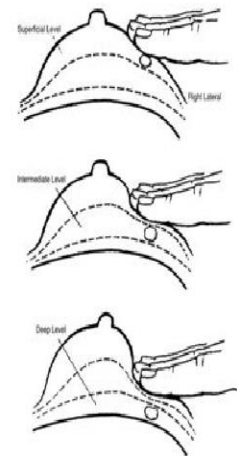
■ Clinical Breast Exam:



Position the patient in the direction of palpation for the CBE.



Use pads of the index, third, and fourth fingers (*inset*) make small circular motions

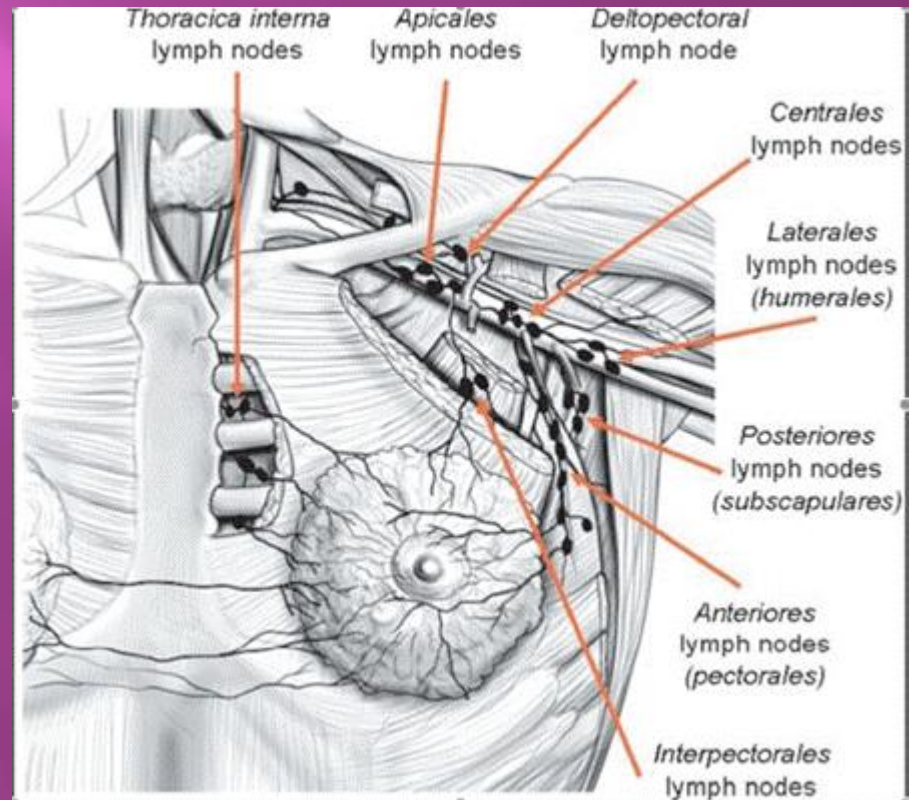


Make three circles with the finger pads, increasing the level of pressure (subcutaneous, mid-level, and down to the chest wall) with each circle

PALPATION

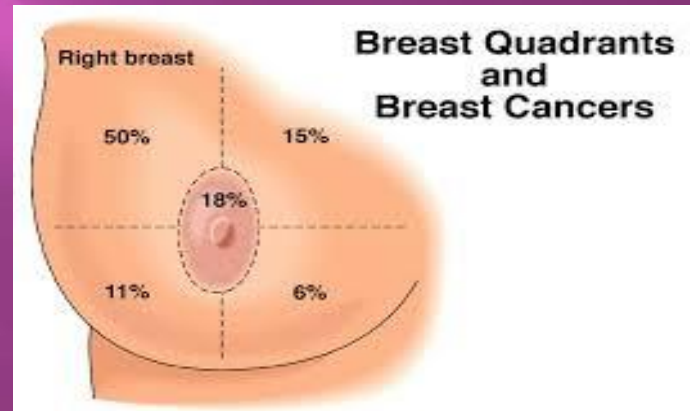
Axilla 5-Points

- 1)Anterior
- 2)Posterior
- 3)Central
- 4)Apical
- 5)Lateral



Breast 5-Points

- 1) Central(nipple areola complex)
- 2) Upper medial
- 3) Upper lateral
- 4) Lower medial
- 5) Lower lateral



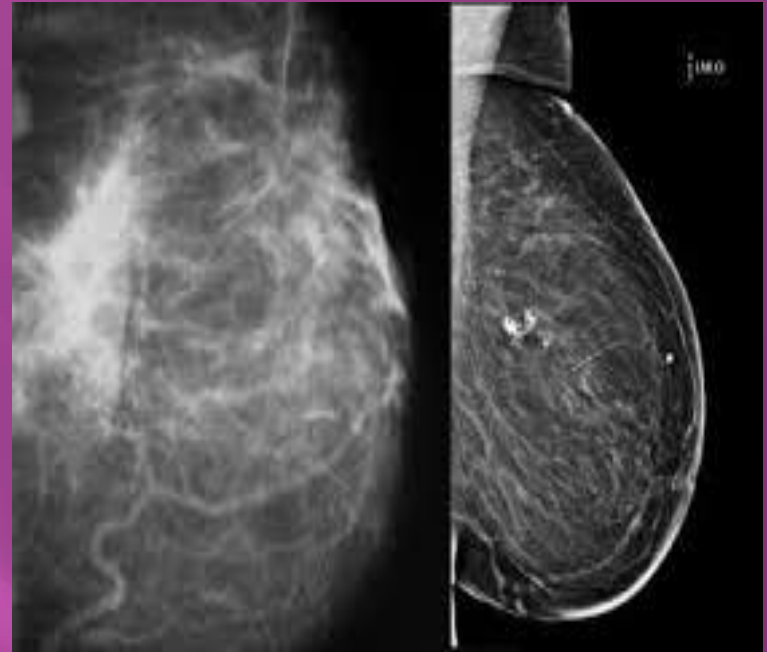
OTHER SYSTEM

- ▣ Cervical lymph nodes
- ▣ Spine - tenderness , restriction of movement
- ▣ Abdomen – Hepatomegaly, ascites,
- ▣ Lung – Breathlessness, effusion
- ▣ CNS – Headache, paresis, paraesthesia
- ▣ P/V/R examination

Imaging

- ❑ Total dose absorbed from mammography, normal breast in two planes , about 2mGy (=0.2rad)
- ❑ Radiation sensitivity of breast is greatest in women <30 yrs and negligible ≥ 40 years.
- ❑ Carcinogenicity depends on absorbed dose, which in turn depends on THICKNESS and DENSITY of breast
- ❑ “...risk of dying from breast cancer induced by mammography... is approximately equivalent to the risk of dying of lung cancer from smoking three cigarettes..” (Heywang-Kobrunner 2001)
- ❑ Negligible for breast cancer causation but not for other possible radiation-induced cancers. Cancer is stochastic hazard, no dose is safe.

**Strangely enough, every
woman is flat-chested
when it's
mammogram
time.**



Microcalcification
Spiculated outer edge
Reported as BIRADS 0-6

Imaging

Routine Mammographic screening is not recommended in patients ≤ 40 yrs because:

- Over all incidence of ca is significantly less
- Tissues are more sensitive to ionizing radiation
- Mammography is less effective in young dense breast

❑ SONOGRAPHY

After mammography, ultrasound imaging is the second most important imaging modality for the breast.

Major Roles

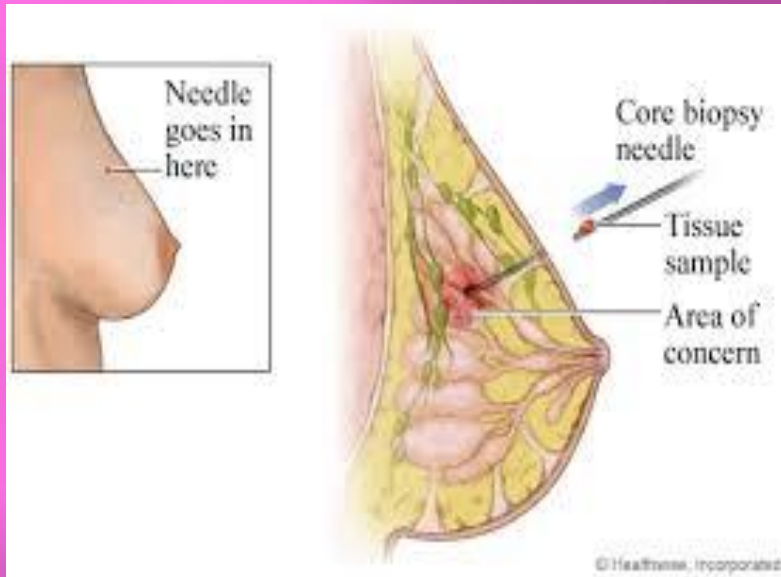
- ❑ Diagnosis of cysts
- ❑ Characterizing masses not fully assessed by mammography
- ❑ Palpable masses obscured by dense tissues during mammography
- ❑ Imaging guidance for percutaneous biopsy and localization
- ❑ First imaging modality for young women ≤ 30 yrs.

Imaging

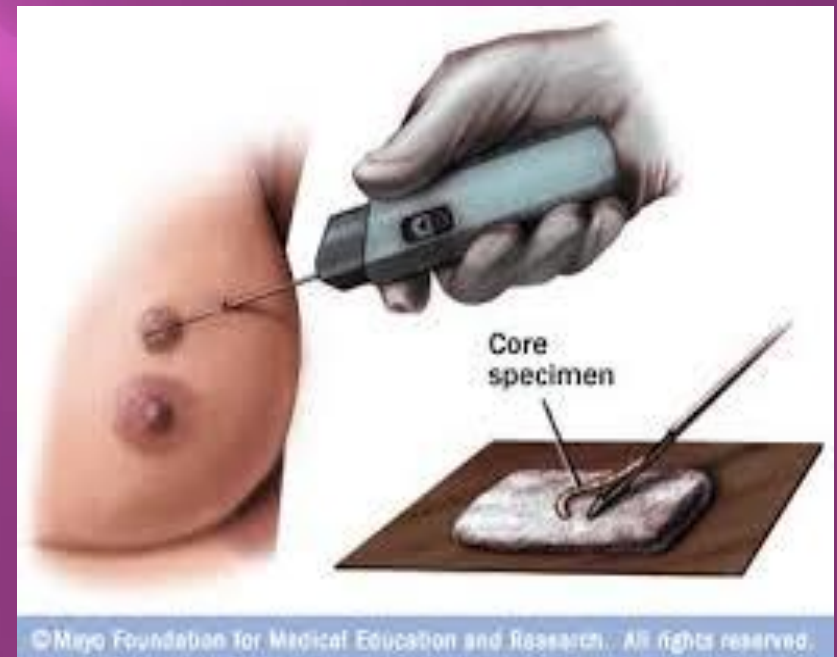- ▣ MRI not routinely recommended but in cases of
 - Familial BC associated with BRCA mutation(IA)
 - Lobular cancers(1A)
 - Dense breasts (IIB)
 - Suspicious of multifocality / multicentricity(IA)
 - Before neoadjuvant systemic therapy and to evaluate response(IIA)

Other s are level III evidence

Confirmation by Pathological assessment



CORE BIOPSY FOR ACCURATE
DIAGNOSIS



Core needle biopsy is the procedure to remove a small amount of suspicious tissue from the breast with a larger “**core**” (meaning “hollow”) **needle**.

At least 2-3 cores are obtained. If multifocal all lesions should be biopsied.

Indications for surgical biopsy after core needle biopsy

- ▣ Diagnosis of atypical ductal hyperplasia
- ▣ Diagnosis of Pleomorphic LCIS
- ▣ Lack of concordance between imaging findings and histologic diagnosis
- ▣ Papillary lesions

A small margin of tissue should be excised around the tumor, oriented sutures should be placed, specimen should be inked to allow margin evaluation

HP report

- ▣ Presence/absence of DCIS
- ▣ Histological grade
- ▣ Histological type
- ▣ IHC evaluation of ER status
- ▣ For invasive ca , PR & HER 2 status, Her 2 status as per ASCO CAP guidelines
- ▣ IHC 3+- >10% of cells harbours complete membrane staining & ISH if number of HER 2 gene copies ≥ 6 or Her 2/chr 17 ratio (CEP 17) ≥ 2 & Her 2 copies ≥ 4 or CEP 17 < 2 & Her 2 copies ≥ 6
- ▣ Ki 67 labellind index – for additional useful information in invasive ca

STAGING AND RISK ASSESSMENT

- ▣ In early breast cancer -routine staging evaluations are directed at locoregional disease. Asymptomatic distant metastases are rare, and most patients do not benefit from comprehensive laboratory tests (including tumour markers [30]) and radiological staging [III, D].
- ▣ Minimum blood work-up (a full blood count, liver and renal function tests, alkaline phosphatase and calcium levels) is recommended before surgery and systemic (neo)adjuvant therapy [V, A].

STAGING AND RISK ASSESSMENT

- ▣ A computed tomography (CT) scan of the chest, abdominal imaging (US, CT or MRI scan) and a bone scan can be considered for patients with:
 1. clinically positive axillary nodes
 2. large tumours (e.g. ≥ 5 cm)
 3. aggressive biology
 4. clinical signs, symptoms or laboratory values suggesting the presence of metastases [III, A]

Recommendations

- ❑ Disease stage should be assessed according to the AJCC TNM staging system [I, A].
- ❑ Comprehensive laboratory including tumour markers and radiological staging is not necessary for all patients [III, D].
- ❑ FDG-PET-CT scanning may be useful when conventional methods are inconclusive [V, A] and may replace traditional imaging for staging in high-risk patients [V, B].
- ❑ Postoperative pathological assessment of the surgical specimens should be made according to the pathological TNM system [I, A].
- ❑ Validated gene expression profiles may be used to gain additional prognostic and/or predictive information to complement pathology assessment and help in adjuvant ChT decision-making [I, A].

ESMO Recommendations:

- ▣ Breast imaging should involve bilateral mammogram and US of breasts and axillae in all cases [I, A];
- ▣ MRI is recommended in case of uncertainties following standard imaging and in special clinical situations [I, A]. ▣
- ▣ Pathological evaluation includes histology from the primary tumour and cytology/histology of the axillary nodes (if involvement is suspected) [I, A]. ▣
- ▣ Pathological report should include histological type, grade, IHC evaluation of ER, PgR (for invasive cancer), HER2 (for invasive cancer) and some form of proliferation markers (e.g. Ki67 for invasive cancer) [I, A].
- ▣ Tumours should be grouped into surrogate intrinsic subtypes, defined by routine histology and IHC data [I, A]. ▣
- ▣ TIL scoring is of prognostic value and may be used to add on information on patient's prognosis. It should not, however, be used to take treatment decisions nor to escalate or de-escalate treatment. ▣
- ▣ Genetic counselling and testing for germline BRCA1 and BRCA2 mutations should be offered to breast cancer patients in high-risk groups [II, A].

PET CT SCAN

- ▣ Fluorodeoxyglucose (FDG) positron emission tomography (PET)-CT may be useful when conventional methods are inconclusive [V, A].
- ▣ PET-CT scanning can also replace traditional imaging for staging in high-risk patients [V, B], a Lobular cancers , for low grade tumors PET may be less sensitive (Koolen BB et al 2012)
- ▣ Current evidence does not support the use of FDG-PET-CT in the staging of locoregional disease, due to its limited sensitivity when compared with the gold standard, sentinel lymph node biopsy (SLNB) and axillary lymph node dissection (ALND) [Robertson IJ et al 2011].

Post op HP report

- The postoperative pathological assessment of the surgical specimens should be made according to the pathological TNM system
- 1. Number, location and maximum diameter of the tumours removed;
- 2. Total number of LN removed and positive lymph nodes, as well as the extent of metastases in the lymph nodes [isolated tumour cells, micrometastases (0.2–2 mm), macrometastases]
- 3. Histological type and grade of the tumour(s) using a standard grading system
- 4. Evaluation of the resection margins, including the location and minimum distance of the margin
- 5. Vascular invasion
- 6. A biomarker analysis, as described above [I, A]
- 7. For small tumours diagnosed by core biopsy, measuring only the residual tumour in the excision may result in understaging. It is recommended to correlate imaging, clinical and gross findings to microscopic observation if necessary [16].

Cardiac Evaluation

- ▣ In patients planned for (neo)adjuvant systemic treatment with anthracyclines and/or trastuzumab, evaluation of cardiac function with a cardiac US or a multigated acquisition (MUGA) scan is essential [I, A].

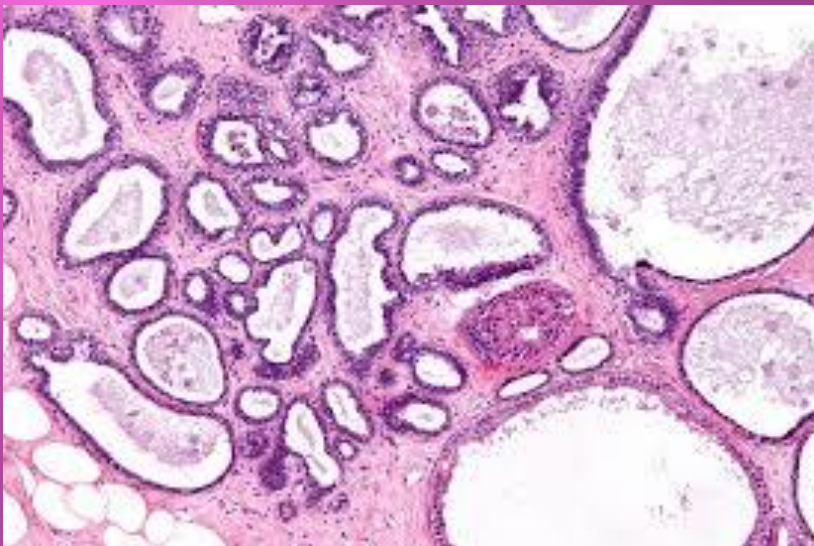
PATHOLOGY – “Pathos” and “Logos”

THE STUDY OF DISEASE



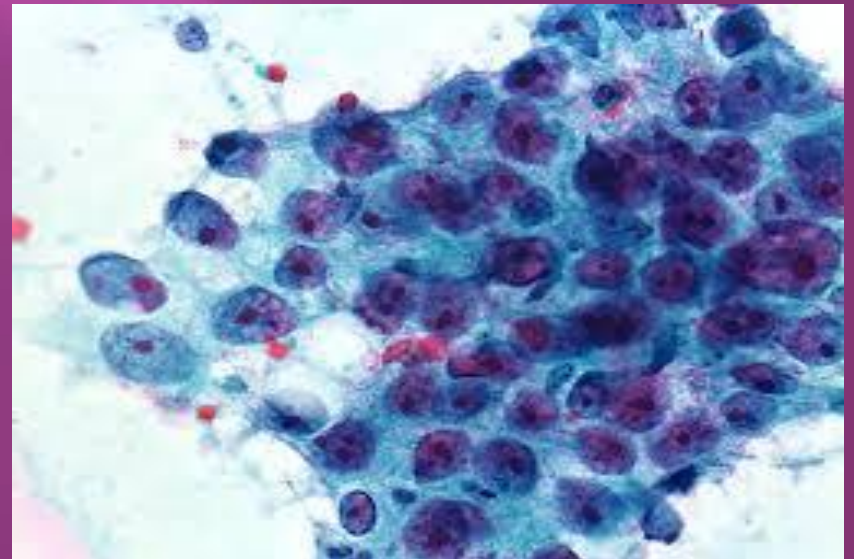
HISTOLOGY

- ▣ Study of tissues
- ▣ Complex
- ▣ Costly



CYTOLOGY

- ▣ Study of cells
- ▣ Simple
- ▣ Cheaper



NORMAL

Lobules and
terminal ducts

Large ducts

Intralobular stroma

Interlobular stroma

Pectoralis muscle

Chest wall and ribs

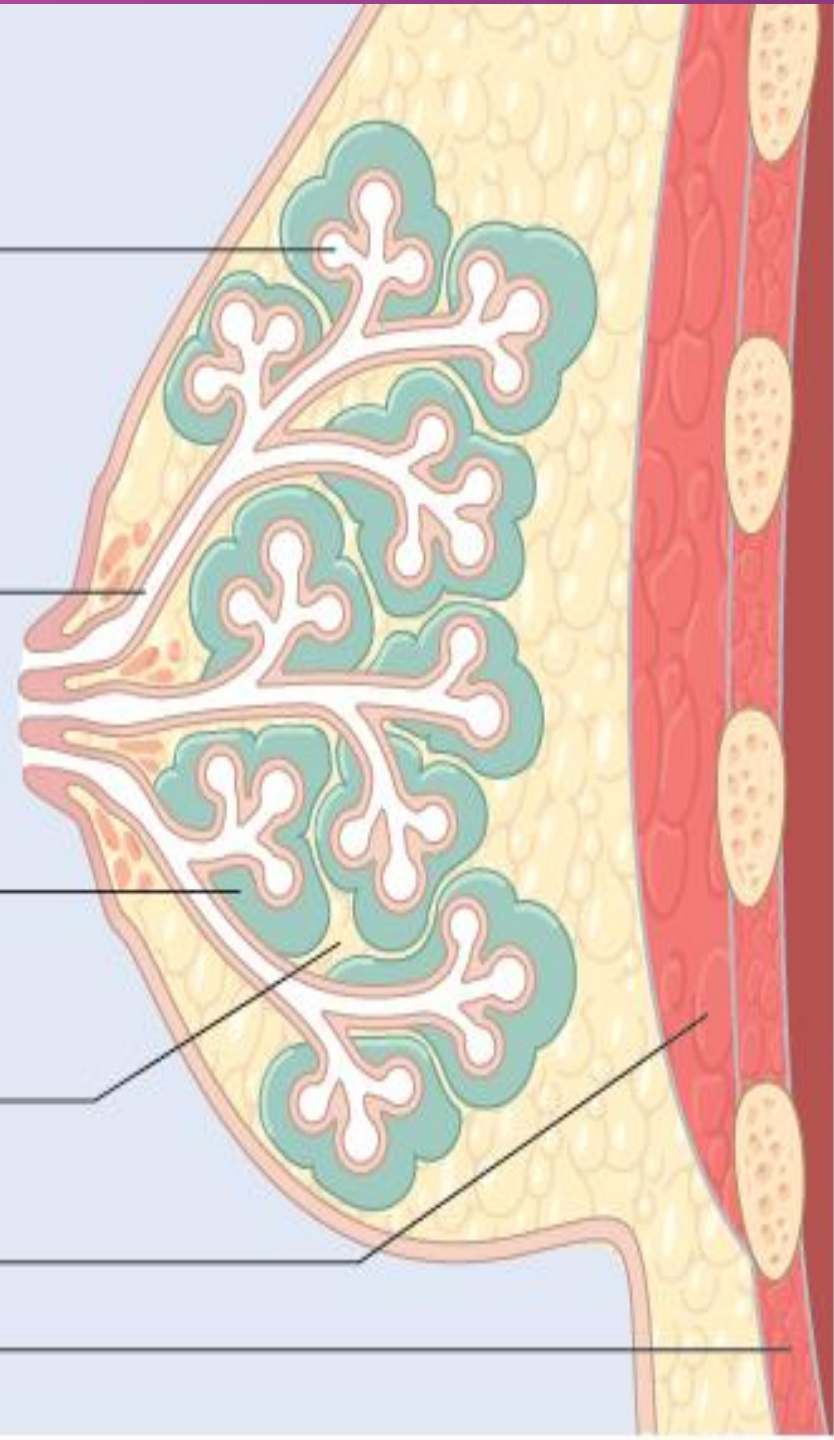
LESIONS

Cyst
Sclerosing adenosis
Small duct papilloma
Hyperplasia
Atypical hyperplasia
Carcinoma

Duct ectasia
Squamous metaplasia
of lactiferous ducts
Large duct papilloma
Paget disease

Fibroadenoma
Phyllodes tumor

Fat necrosis
Lipoma
Fibromatosis
Sarcoma



Benign Breast Disease

1. Fibroadenoma.
2. Fibrocystic breast disease.
3. Intraductal papilloma.
4. Fat necrosis (think of this in trauma to breast)
5. Mastitis (inflammed, painful breast in women who are breast feeding)

WHAT IS THE ROLE OF PATHOLOGY IN BREAST CANCER ?

- ▣ Establish an accurate diagnosis in case of a mass lesion (Benign , Malignant)
- ▣ Confirm a diagnosis of suspected breast cancer
- ▣ For prognosis (grade and stage of tumour, risk of metastases, relapse of cancer)
- ▣ For prediction of response to therapy
- ▣ For choosing appropriate treatment (hormonal therapy, Herceptin)

Pathology of Breast

- ▣ Historically based on morphologic appearance of cancer
- ▣ Most widely used classifications based on the growth pattern and cytological features of the invasive breast cancers (WHO 4th edition)
- ▣ Most invasive cancers arise in terminal duct lobular unit, regardless of histologic type

Pathological classification

- ▣ Final pathological diagnosis should be made as per
 1. WHO classification
 2. 8th edition of AJCC TNM staging system

CLASSIFICATION – BREAST CARCINOMA

❑ ***NON-INVASIVE/IN SITU CARCINOMA***

- ❖ Intraductal carcinoma
- ❖ Lobular carcinoma in situ

❑ ***INVASIVE CARCINOMA***

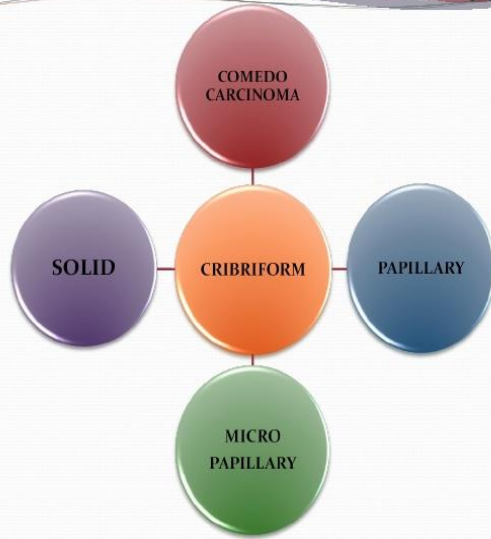
- ❖ Infiltrating (invasive) duct carcinoma – NOS
- ❖ Infiltrating (invasive) lobular carcinoma
- ❖ Medullary carcinoma

- ❖ Colloid (mucinous) carcinoma
- ❖ Papillary carcinoma
- ❖ Tubular carcinoma
- ❖ Adenoid cystic carcinoma
- ❖ Secretory carcinoma
- ❖ Inflammatory carcinoma
- ❖ Carcinoma with metaplasia

❑ ***PAGET'S DISEASE OF THE NIPPLE***

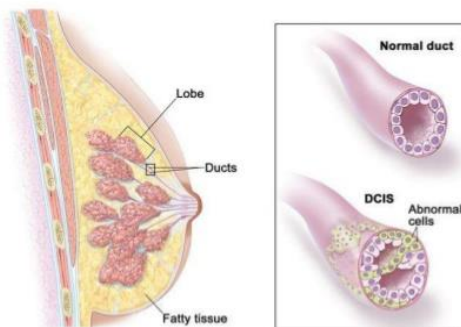
Preinvasive carcinoma- DCIS

DCIS – 5 Architectural subtypes



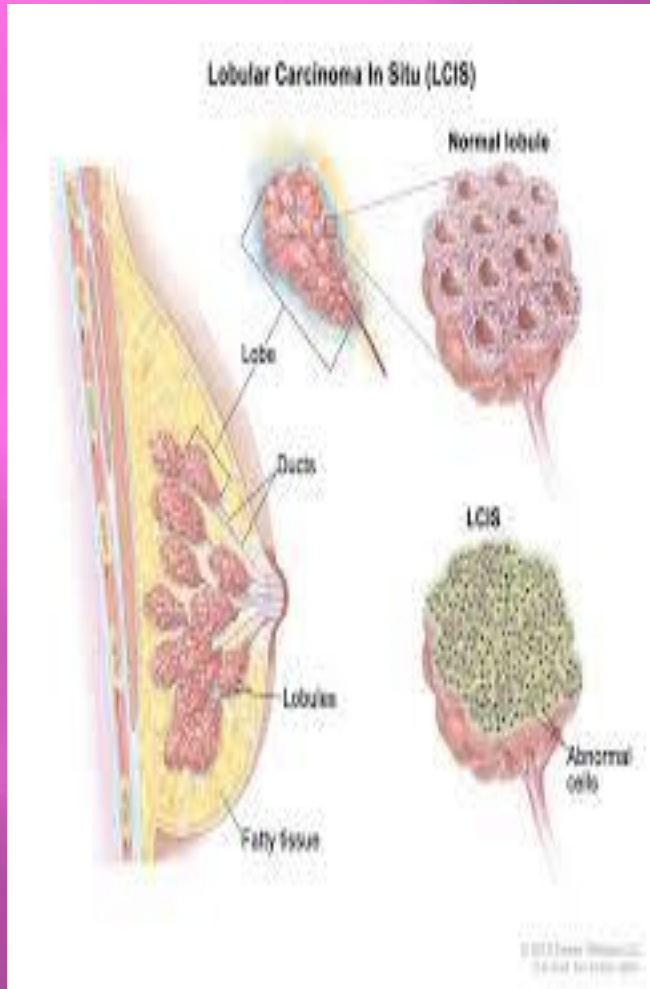
- 15-30% of tumors
- Early malignancy without basement membrane penetration
- Age group – 49-69 years
- 30-60% of DCIS display more than one histologic pattern
- May present as palpable or non palpable mass
- 2 commercially available assay Oncotype Dx DCIS Score and DCIS biologic risk profile provide an estimate of 10 year risk of LR for patients treated with surgery alone

Ductal Carcinoma In Situ (DCIS)



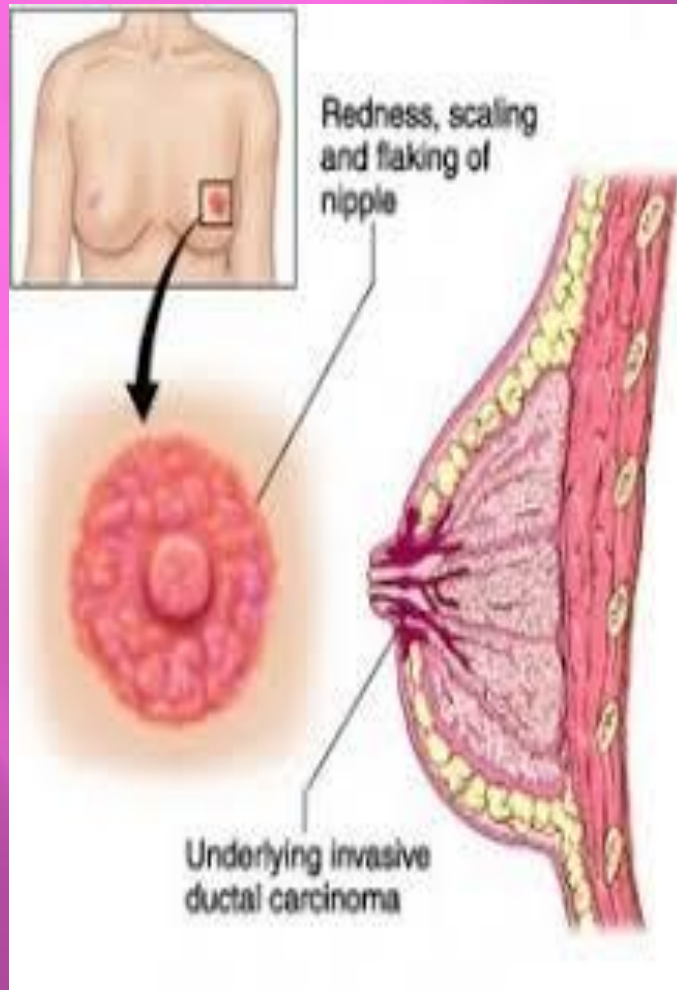
schedule surgical resection with clear margins (lumpectomy; i.e., breast conserving surgical resection) and give radiation therapy (RT) and tamoxifen for 5 years to prevent the development of invasive disease

Preinvasive carcinoma- LCIS



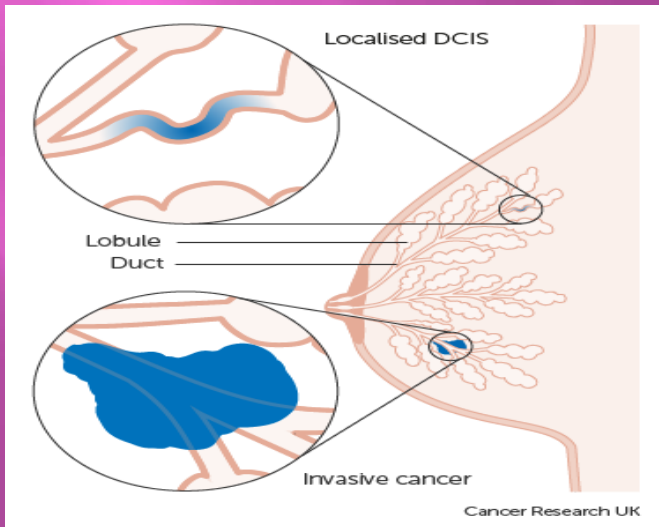
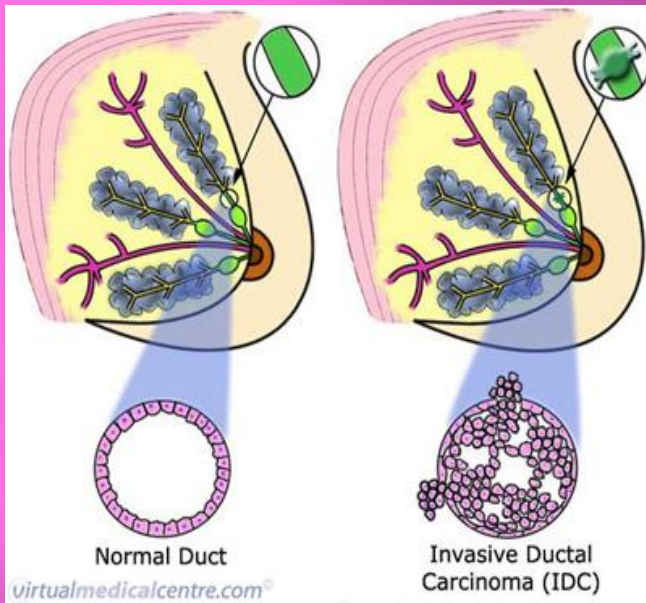
- Diagnosis usually incidental, previously in 40's to 50's now incidence in post menopausal is increasing
- Lack of expression of E-cadherin(transmembrane cell adhesion protein) except in pleomorphic variety
- Recently term Lobular neoplasia(LN) used to cover both atypical lobular hyperplasia(ALH) and LCIS
- Morphologically , LN is defined as proliferation of small and loosely cohesive cells originating in terminal duct lobular unit with or without pagetoid involvement of involvement terminal ducts.
- Risk of dev. of invasive ca 1-2%/year, lifetime risk of 30-40%
- Both multifocal and bilateral in large percentage of cases
- ER/PR+, Her 2 –
- Genetic changes – recurrent loss of 16q and gain of 1 q

PAGET'S Disease of nipple



- ❑ Rare , incidental finding
- ❑ No palpable mass – DCIS
- ❑ Palpable mass – 50 -60% - invasive ca
- ❑ Malignant cells/Paget's cells- extends from DCIS within ductal system via lactiferous sinus-nipple skin without crossing BM
- ❑ Paget's cell detected by nipple biopsy / cytological preparation of exudate
- ❑ Poorly diff, ER -, Her 2 Neu overexpressed
- ❑ Prognosis – depends on underlying ca

Invasive Ductal Carcinoma

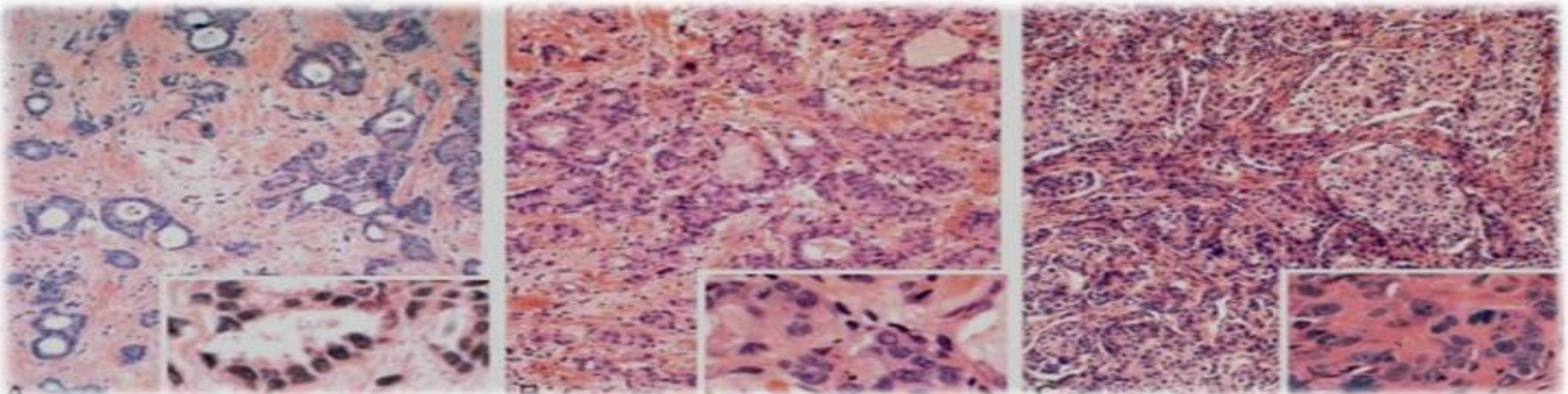


- 70-80% of all cases
- Defined as type of cancer not classified into any special types so the term "NOS" or "NST"
- Palpable mass, axillary LN involvement, fixity to chest wall, skin dimpling, nipple retraction, lymphedema, tethering of skin to breast by Cooper's ligament i.e. Peau d'orange
- Gross - Most tumours are firm to hard, irregular border




Invasive cancer- subclassification based on microscopic features

Invasive Carcinoma – NST- HPE

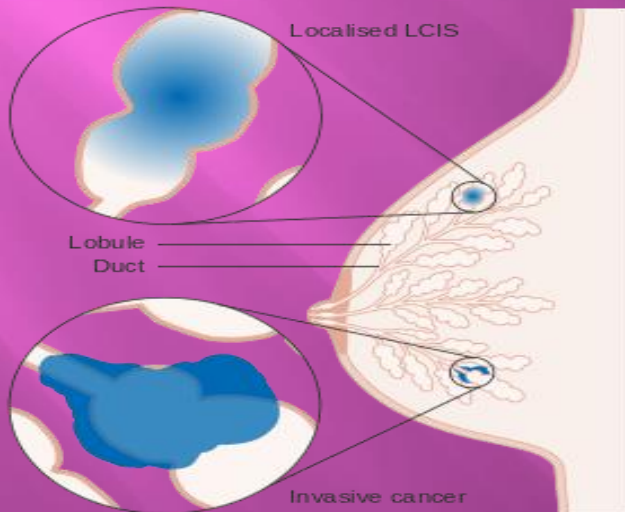
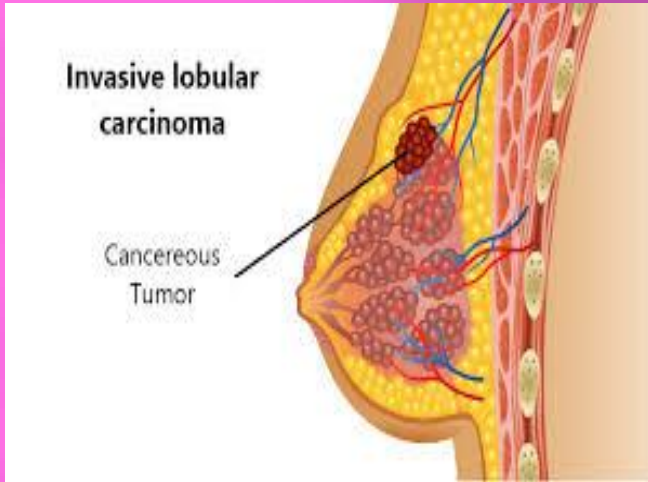
Features	Well diff. Ca	Mod. diff.Ca	Poorly diff. Ca.
Tubule formation	Prominent	Less,solid clusters/ single infiltrating cells	Ragged nests/solid sheets of cells
Nuclei	Small,round,mono morphic	Greater nuclear pleomorphism	Nuclei – enlarged,irregular.
Mitotic figures	Rare	Present	Numerous
Proliferation rate	-	-	High
Tumour necrosis	-	-	Present



Nottingham grading system(recommended as part of AJCC system)

		Score						
Parameter		1	2	3				
	Tubule formation	>75%	10-75%	<10%				
	Nuclear pleomorphism	Absent*	Moderate	Marked				
	Mitotic count**	<9	9-17	>17				
Final score		3	4	5	6	7	8	9
		Grade I			Grade II		Grade III	

Invasive Lobular carcinoma

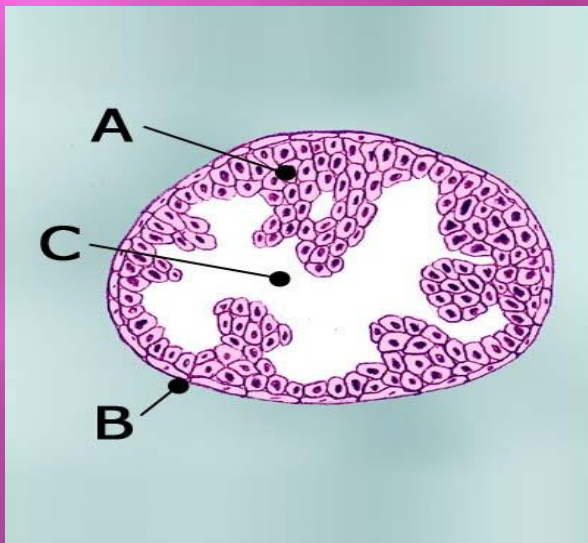


- ❑ Bilateral 5-10%
- ❑ Morphology – Indian file appearance
- ❑ Well to mod diff
- ❑ ER+, Her 2 over expression rare
- ❑ Different pattern of metastasis from other types – peritoneum, retroperitoneum, leptomeninges, ovary, uterus, GI tract

Invasive papillary & micropapillary carcinoma - 1% or fewer, more commonly seen in DCIS

PAPILLARY

- ▣ ER +
- ▣ Favourable prognosis



MICROPAPILLARY

- ▣ ER -, HER 2+
- ▣ LN Mets – Very common
- ▣ Prognosis – poor

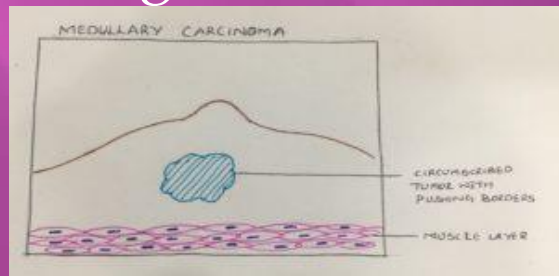
Other Invasive carcinoma

MEDULLARY CARCINOMA

- ▣ 6th decade, 5-7%, 45-54 yr
- ▣ Mimic benign tumour
- ▣ Morphologically well circumscribed, soft fleshy mass
- ▣ Poorly differentiated
- ▣ Often triple negative
- ▣ Pushing smooth borders instead of infiltrative margins

MUCINOUS (COLLOID) CARCINOMA

- ▣ 7th decade, grow slowly
- ▣ Morphologically tumor soft rubbery
- ▣ Well to mod diff
- ▣ ER+
- ▣ LN mets - uncommon
- ▣ Prognosis bit better



Other Invasive carcinoma

TUBULAR CARCINOMA

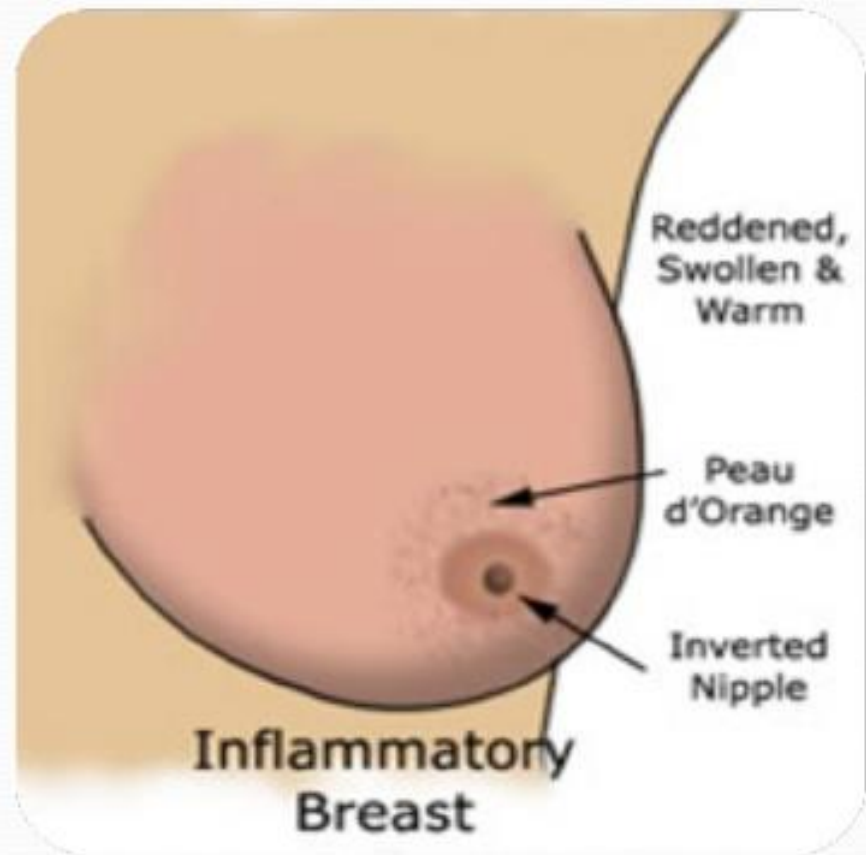
- ▣ Small irregular mammographic densities – late 40's
- ▣ Uncommon
- ▣ ER+, Her 2 –
- ▣ Well diff
- ▣ Good prognosis

METAPLASTIC CARCINOMA

- ▣ Includes variety of rare types(<1% of all cases)- matrix producing ca, sq cell ca, ca with prominent spindle cell component
- ▣ Triple Negative
- ▣ LN mets – infrequent
- ▣ Prognosis - poor

INFLAMMATORY CARCINOMA

- Tumors → swollen, erythematous breast - caused by **extensive invasion and obstruction of dermal lymphatics by tumor cells.**
- Underlying carcinoma - diffusely infiltrative - does not form a discrete palpable mass → confusion with true inflammatory conditions a → delay in diagnosis.
- Many patients → metastases at diagnosis / recur rapidly.
- Overall prognosis → poor



Phylloids tumor

- ▣ < 1%, relatively younger age (42-45), tend to grow quickly, rarely spreads outside breasts
- ▣ Most are benign, some cancerous, some in between(borderline), WHO classification

	Benign	Borderline	Malignant
Mitosis/10HPF	0-4	5-10	>10
Tumor border	Pushing	Focally infiltrative	Diffusely infiltrative
Nuclear atypia	None	Mild to mod	Marked
Stromal overgrowth	None	Focal	Diffuse
Str cellularity	Mild	Mod	High
Malig str elements	None	None	Present

Most important prognostic factors in early breast cancer

- ▣ expression of ER/PgR, HER2 and proliferation markers (e.g. Ki67),
- ▣ the number of involved regional lymph nodes,
- ▣ tumour histology, the size, grade and the presence of peritumoral vascular invasion.
- ▣ Additionally, in patients undergoing breast-conserving therapy (BCT), the ipsilateral breast recurrence risk is related to the status of the surgical margins and the presence of DCIS.

Prognostic & Predictive factors

- ▣ **IHC-detected tumour markers** -great practical treatment importance are **now incorporated into the eighth edition of the AJCC TNM staging system** to refine prognosis, which also uses genomic assays, when available, to downstage some ER positive, lymph node-negative tumours
- ▣ Clinical parameters (age, tumour stage, ER, PgR and HER2 expression and histological grade) have also been integrated into scoring systems, allowing a relatively accurate estimation of the probability of recurrence and death from breast cancer; examples include the Nottingham Prognostic Index (NPI), the PREDICT score (Wishart GC et al. Eur J Surg Oncol 2011) and Adjuvant! Online (Ravdin PM ,JCO,2001)

Prognostic & Predictive factors

- ▣ Gene expression profiles, such as MammaPrint (Agendia, Amsterdam, the Netherlands), Oncotype DX Recurrence Score (Genomic Health, Redwood City, USA), Prosigna (PAM50) (NanoString technologies, Seattle, USA), Endopredict (Myriad Genetics, USA), and Breast Cancer Index (Biotheranostics, Inc., San Diego, USA), may be used to gain additional prognostic and/or predictive information to complement pathology assessment and to predict the benefit of adjuvant ChT . All tests except MammaPrint were designed for patients with ER-positive early breast cancer only.

Association of clinicopathologic factors of breast cancer with intrinsic subtypes

Intrinsic subtype	Luminal A	Luminal B	HER 2 Enriched	Basal like
ER/PR expression	Positive – strong	Positive-variable	+ve or -ve	Negative
HER 2 amplification	Rare	Rare but small %age +ve	common	Negative
Grade	Low to intermediate	Intermediate to high	Intermediate to high	High
P53 mutation	Rare	Uncommon	common	common
Ki67	Low	Intermediate to high	High	High
DNA copy number	Diploid	Aneuploid	Aneuploid, high genomic instability	Aneuploid, high genomic instability
mRNA exp	High ER cluster, low proliferation	Low ER cluster, high proliferation	High HER2 amplicon, high prolifer.	Basal signature, high prolifer.



Luck is
yours
wishes are
mine let's
your future
be always
shine.

Best of Luck