


# Pathology of Pre-Cancer and Invasive Cancer of the Uterine Cervix: An Overview

**Dr. Radhika Srinivasan**

**Department of Cytology & Gynaec Pathology  
PGIMER, CHANDIGARH, INDIA**

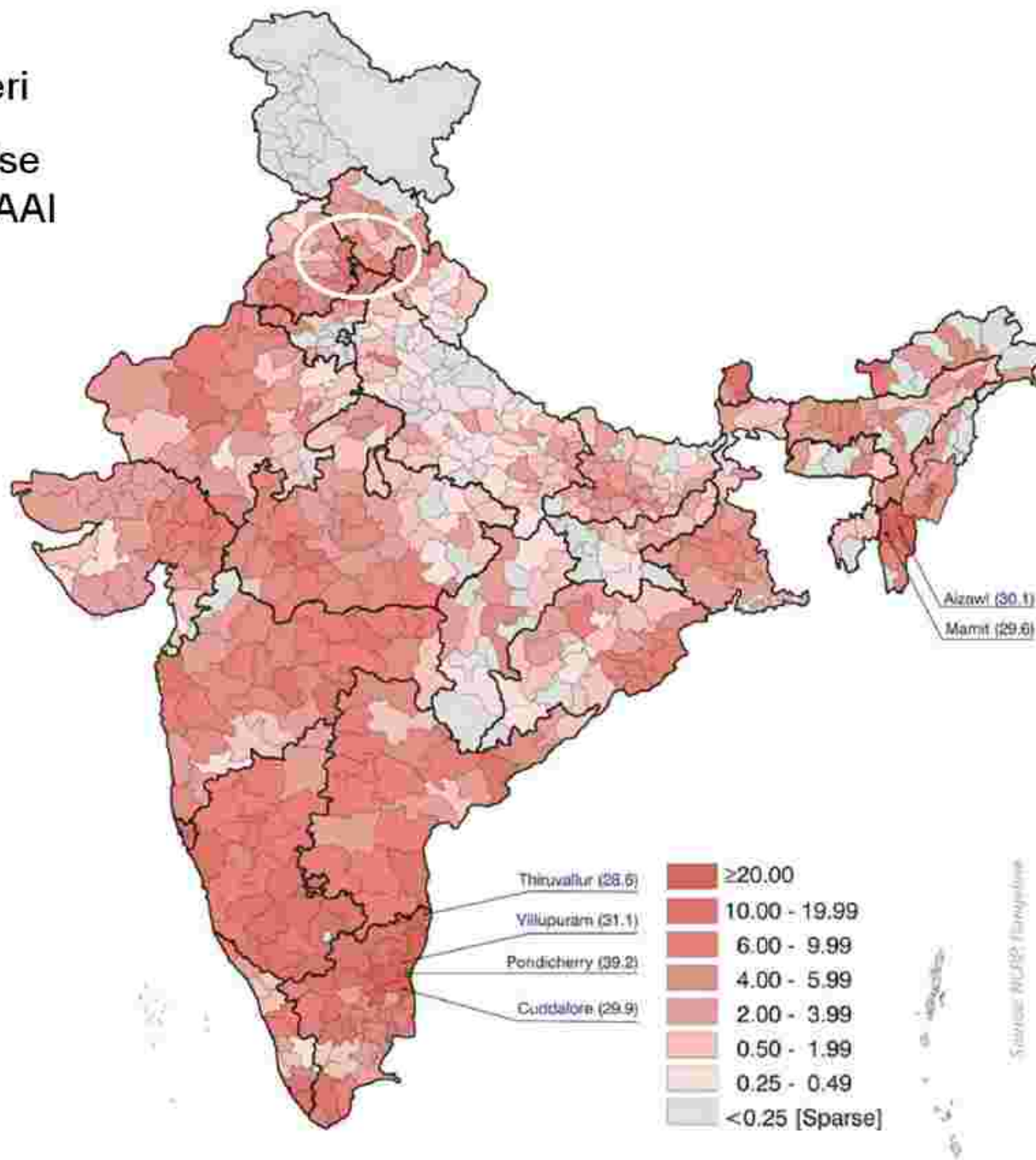


## Cervical Cancer- Facts

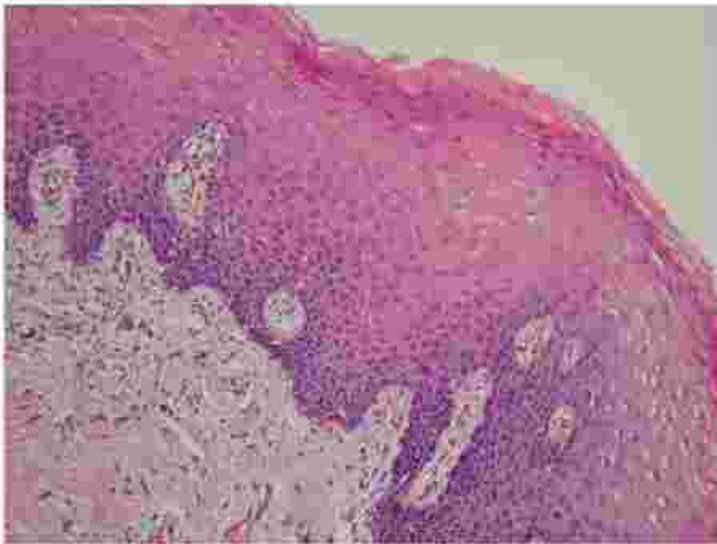


- Second most common cancer in women worldwide
- The most common / 2<sup>nd</sup> most common cancer affecting Indian women with an MAAI around 25 per 100,000 women
- The global incidence is 5,00,000 per year of which India contributes approx 1/4<sup>th</sup>. Around 1,25,000 new cases are diagnosed in India each year.
- By current trends, in the next quarter of a century, 5 million Indian women could be diagnosed with cervical cancer and 2.5 million of them may die of it!

Cervix uteri  
District-wise  
map of MAAI

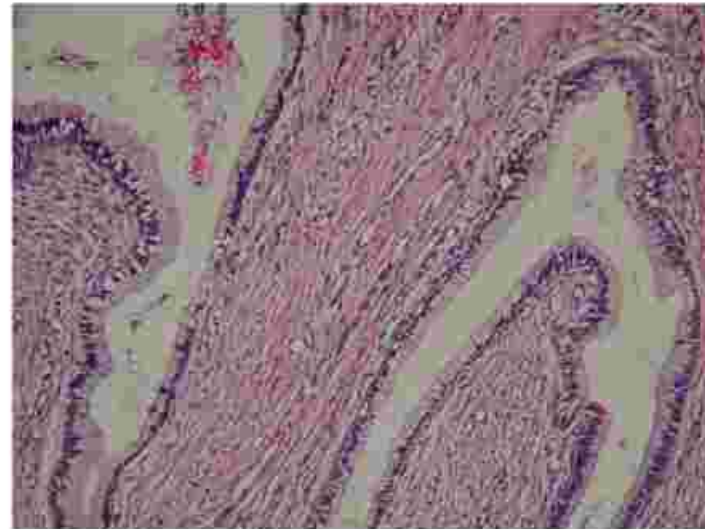

# Cervix – Normal histology



Exocervix

Stratified Squamous  
epithelium



Endocervix

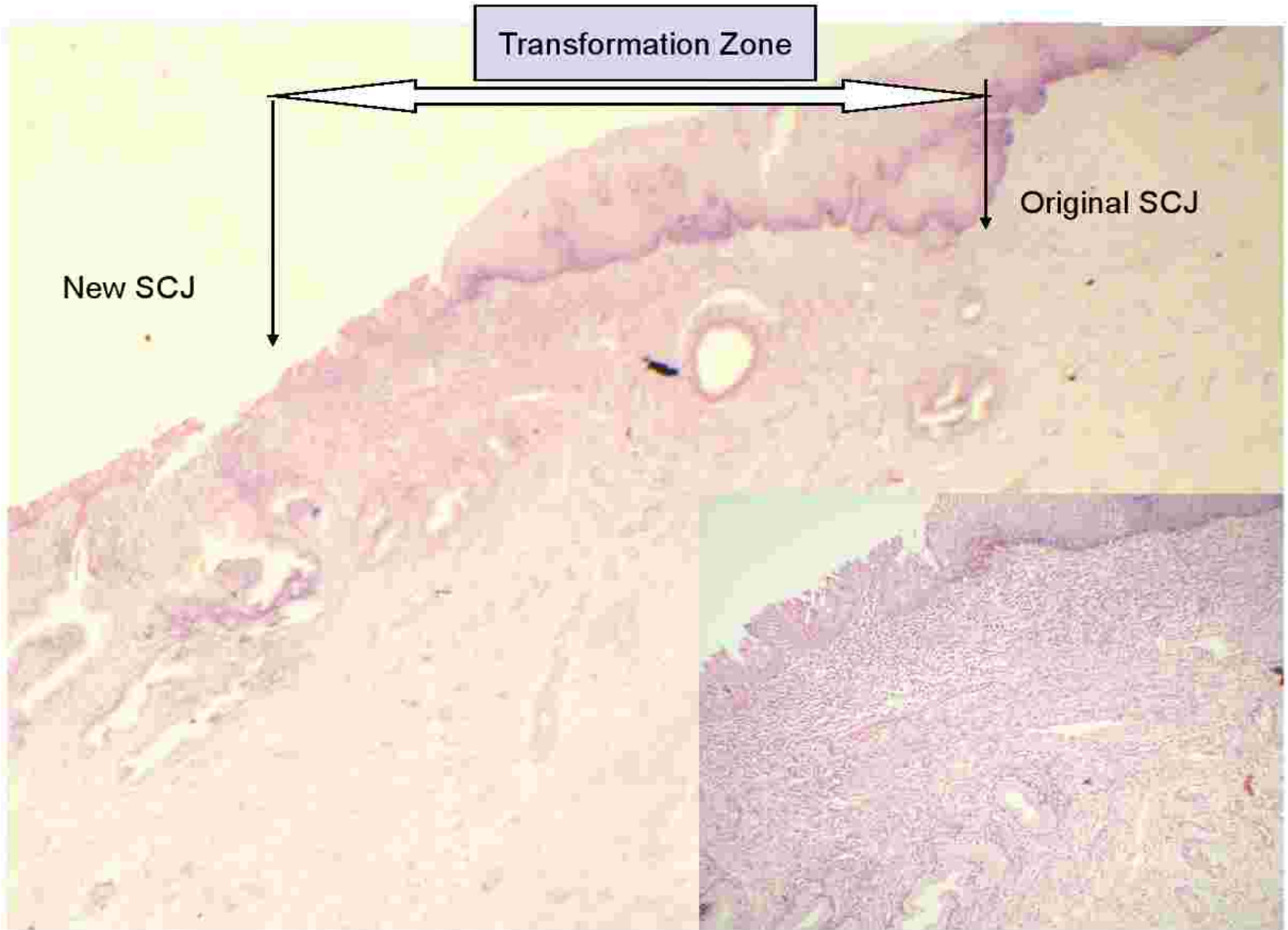
Columnar mucin-producing  
epithelium epithelium



# Squamocolumnar Junction and Transformation Zone



- SCJ is defined as the border between the stratified squamous epithelium and the mucin-secreting endocervical epithelium
- Morphogenetically, there are two SCJ.
  - **Original SCJ** - seen at birth.  
Subsequently, with puberty, sexual activity and pregnancy there is 'ectopy' of the endocervical epithelium which undergoes squamous metaplasia resulting in the formation of
  - **'New SCJ'**
  - The region between the original and new SCJ is the **Transformation Zone or TZ.**
- This concept is extremely important for understanding the pathogenesis of cervical cancer because virtually all of these lesions originate here.

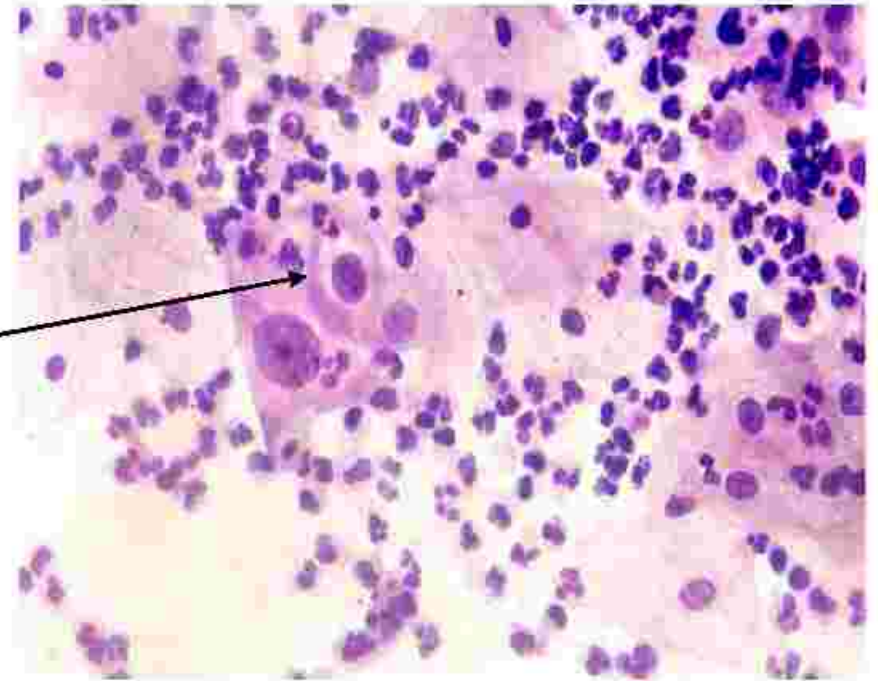
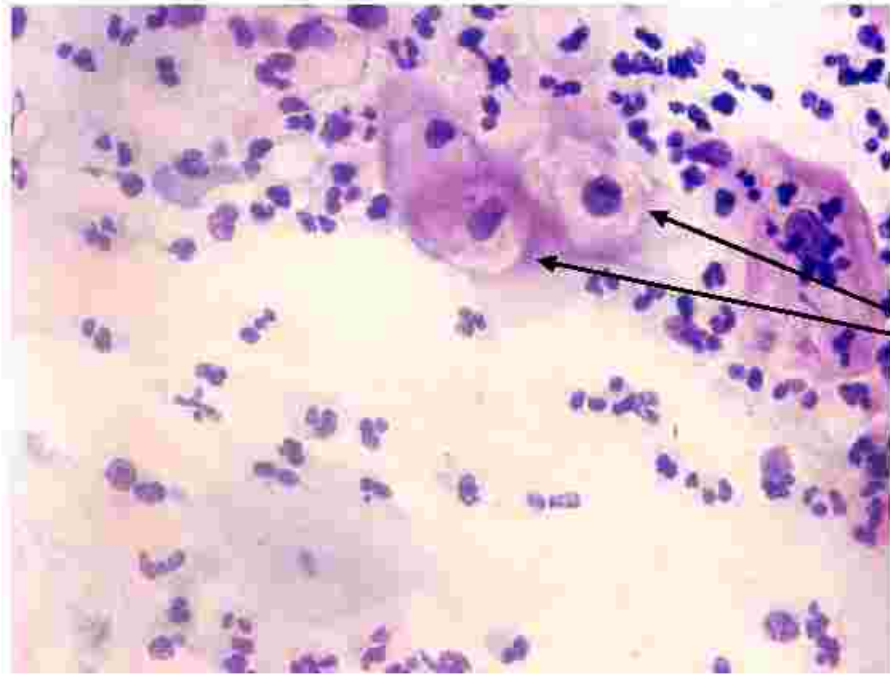


# HPV & Cervical cancer

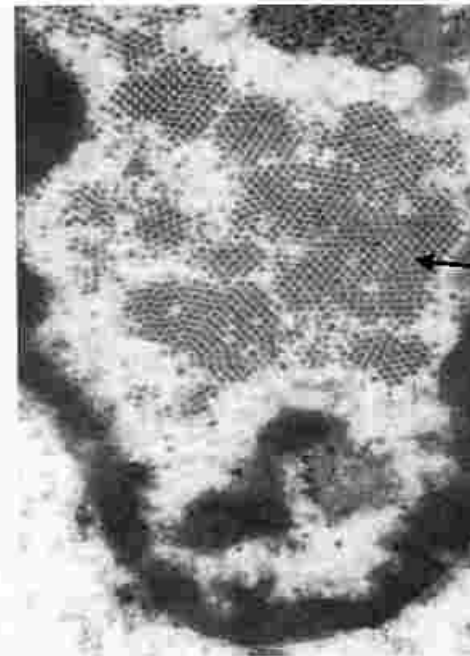
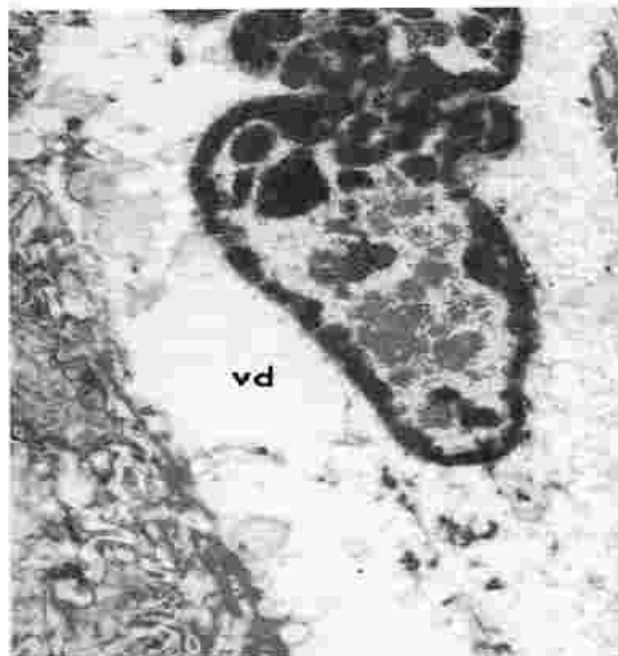


- Originally proposed by zur Hausen, it is now accepted that infection by Human Papilloma virus is critical for the causation of cervical cancer
- **Strength and consistency of association** : HPV DNA is detected by hybridization techniques in >95 % of cancers.
- **HPV divided based on oncogenic risk-**
  - Low risk:** 6, 11, 42, 43, 44, 53
  - High risk:** 16, 18, 45, 56, 58
  - Other high risk:** 31, 33, 35, 39, 51, 52, 59, 68



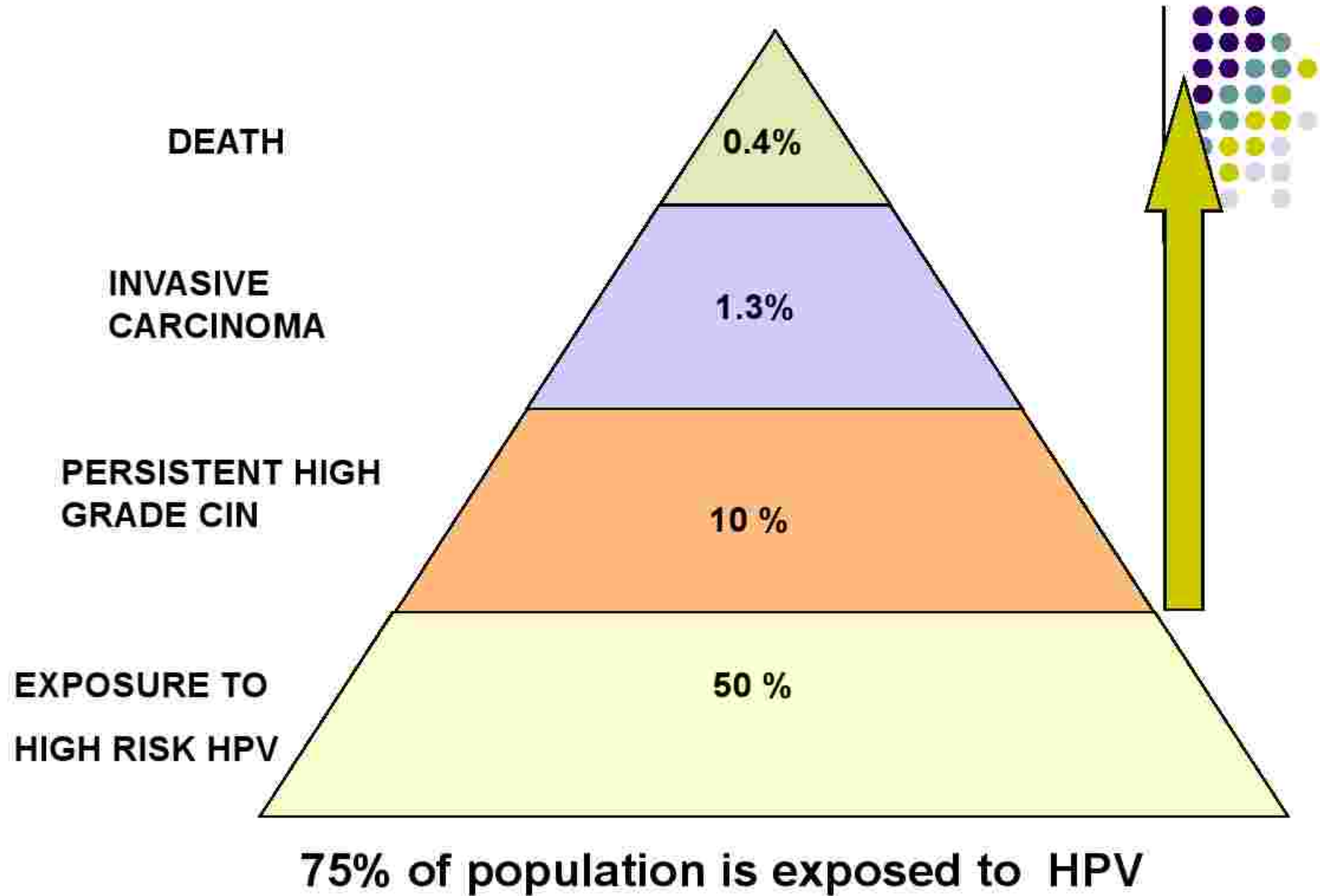


Koilo  
cytes

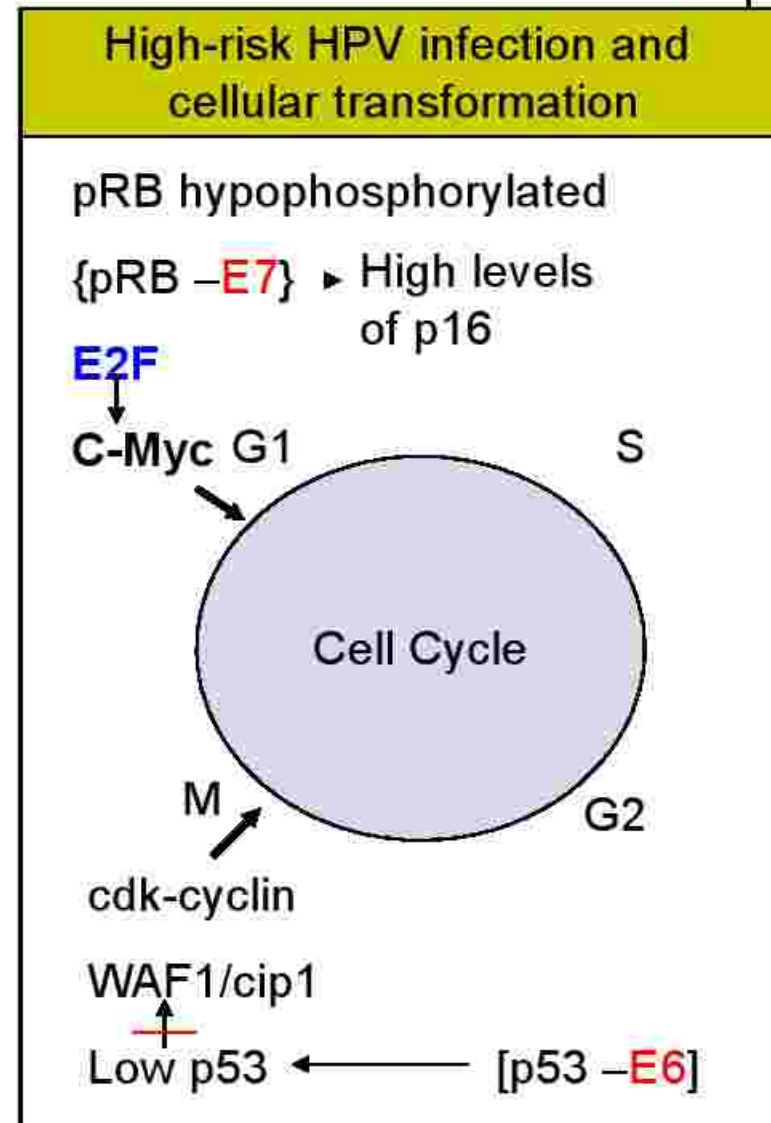
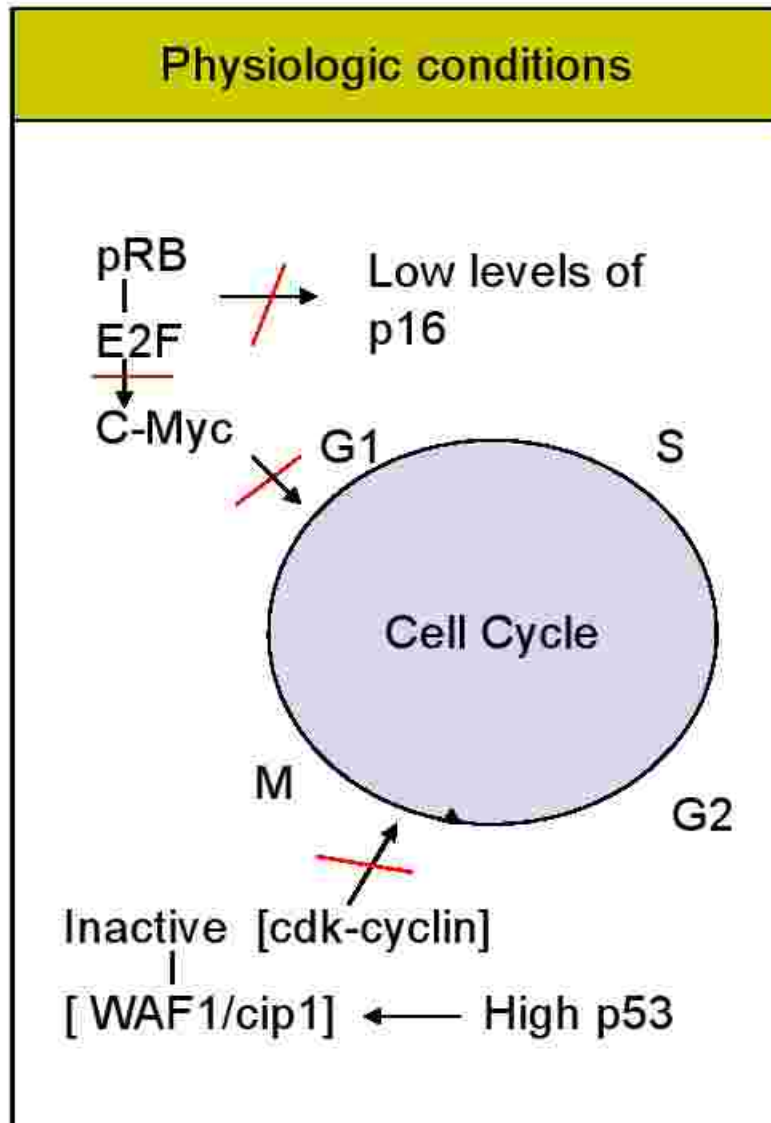


Ultrastructure  
of HPV virion

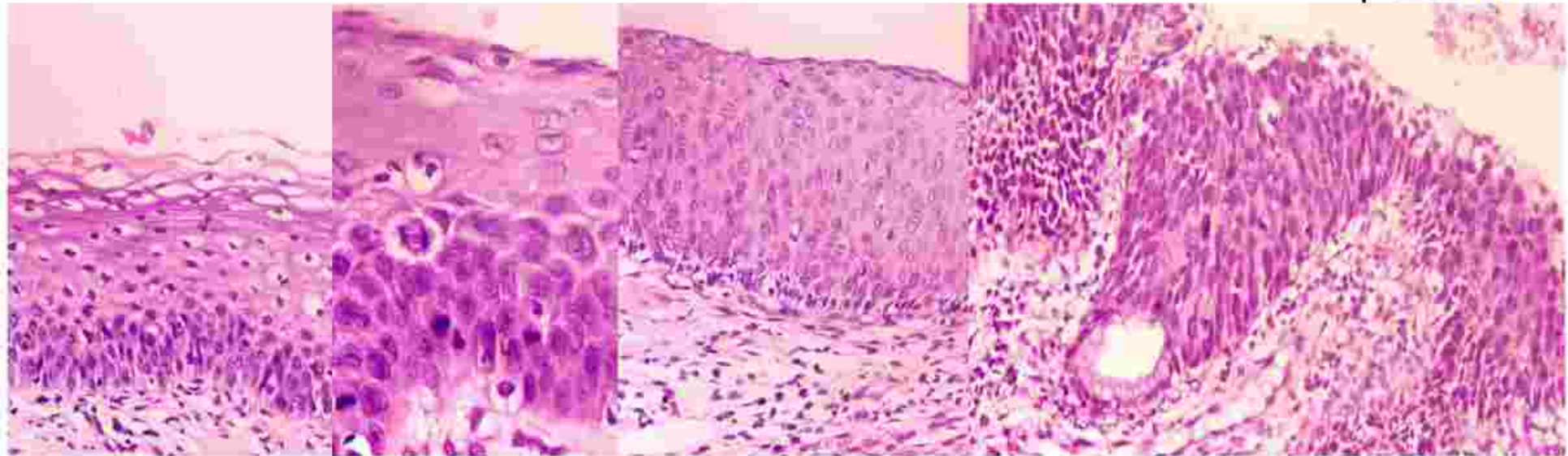




# Pathogenesis of cervical cancer: Interaction of HPV proteins with the cell cycle



# Natural History of Cervical Intraepithelial Neoplasia: Approximate rates of progression, persistence and regression



|      | <b>%</b> | <b>%</b> | <b>to CIN3</b> | <b>to Inv Ca</b> |
|------|----------|----------|----------------|------------------|
| CIN1 | 60       | 30       | 10             | <1               |
| CIN2 | 40       | 35       | 20             | 5                |
| CIN3 | 30       | 48       | n/a            | 22               |

Arends et al, J Clin pathol, 1998; Holowaty et al, J Natl Can Inst, 1999; McIndoe et al 1984; Melnikow et al, Obstet Gynecol, 1998.



# Rationale for screening



- Development of cervical cancer proceeds in a predictable fashion over a long period, allowing ample opportunity for intervention at a pre-cancer stage.
- Primary goal of cervical cytological screening- to identify women, in whom further evaluation with colposcopy is required to detect the presence of true cancer precursors.
- Cancer cervix is preventable by early detection by primary prevention (Etiology), secondary prevention (Pap smear) and tertiary prevention (Down Staging the disease).

# Cervical cancer screening



- VIA/ VILI (Visual Inspection after application of Acetic Acid/ Lugol's iodine)- Fewer False Negatives
- Pap Smear– Fewer False Positives
- HPV Testing
  - Women who persistently test negative for HPV, very rarely develop cervical neoplasia
  - Therefore, the suggestion to use HPV testing as the primary screening device
  - Prohibitory Cost



# The Pap Smear



- **George Papanicolaou** discovered that tumor cells could be found in vaginal fluid of women with cervical cancer – a seminal discovery!
- The developed world has witnessed a 75% reduction in the incidence of, and a 70% reduction in the mortality from invasive cancer due to the Pap test
- **Screening can be population based or hospital based**
- Countries with “**Once in a lifetime Pap Smear**”- **40% reduction**
- **Indian Scenario-** Disappointing
  - Scattered projects undertaking a population-based screening
  - Several Hospital-based screening centers

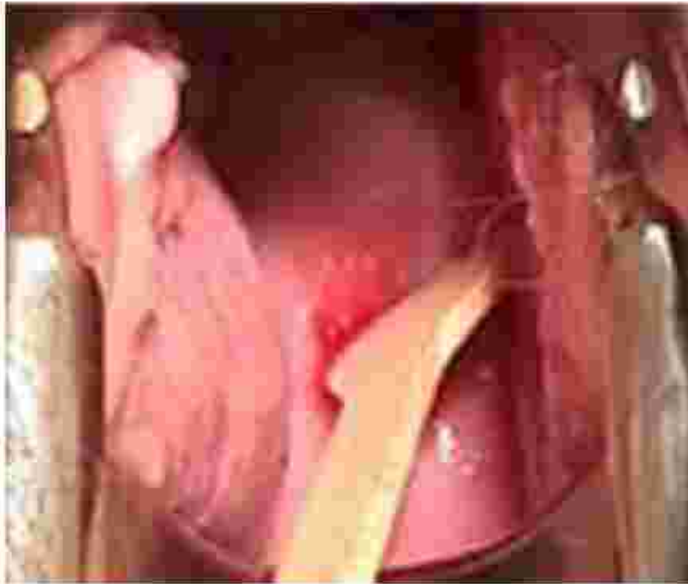

# How to Perform a Pap Test



- **The patient should not be actively menstruating. It is preferable that the patient refrain from sexual activity or use of vaginal medications or spermicides for the 48 hours prior to the test. Cervical irritation can lead to obscuring inflammation or reactive changes on the smear.**
- **Insert appropriately sized bivalve speculum. Do not use lubricant jelly. Instead, use water for easier passage of the speculum.**
- **If mucus or small amounts of blood are on the cervix, gently remove with a large cotton swab with a dabbing motion (to avoid removing cells from the transformation zone).**

# How to Perform a Pap Test




- **Scrape cervix with the Ayre's Spatula by inserting the larger irregularly shaped side of the spatula into the endocervix and turning 360 degrees, making sure to cover the entire transformation zone. [Endocervical brush and broom smears are optional]**
- **Spread the cells from the spatula onto a numbered slide, evenly, avoiding clumping. Immediately fix the smear in a coplin jar containing 95% alcohol (alternatively use spray fixative at a distance of 12 inches, to avoid disrupting the cells)**



# CERVICAL PAP SMEAR REQUEST FORM

## NEW / FOLLOW-UP



- SLIDE NO: \_\_\_\_\_
- NAME
- AGE
- I.D. NO.
- ADDRESS:
- CHIEF COMPLAINTS: Discharge / spotting / post-coital bleeding / menorrhagia / others
- CONTRACEPTION: Barrier / Hormonal / IUCD / Tubal ligation / Others
- H/O ANY THERAPY : None / Surgery / Radiotherapy / Chemotherapy
- PER SPECULUM FINDINGS: cervix normal / erosion / bleeds on touch / Suspicious
- COLPOSCOPIC FINDINGS: Not Done / Unsatisfactory / Normal / Not Done

NEW / FOLLOW UP



# Recommendations for Screening



## Whom to Test ?

- All women who are sexually active, starting within three years after onset of sexual activity
- All women over 21 years of age
- In a Low-resource setting, even a once-in a-lifetime screen of a woman between 35-60 years of age will provide protection against cervical cancer (WHO)

# Frequency of screening



- Dependent on resources available
- Once-in-a-lifetime for low-resource countries
- Otherwise, once in 3– 5 years is recommended
- In case of smear reported as a low grade epithelial abnormality, it is repeated after 6 months

## Potential reduction in cumulative cervical cancer rates with different frequencies of screening



| Frequency of screening | Percent reduction in cumulative rate |
|------------------------|--------------------------------------|
| Every year             | 90-95%                               |
| Every 2 years          | 86-91%                               |
| Every 3 years          | 75-88%                               |
| 5 times per life time  | 61-74%                               |
| 3 times per life time  | 35-55%                               |
| 2 times per life time  | 29-42%                               |
| 1 time per life time   | 17-32%                               |



# The Bethesda System 2001



## INTERPRETATION / RESULT

- **NEGATIVE for Intraepithelial lesion or malignancy**

- Other non neoplastic findings
- Reactive cellular changes associated with:  
Inflammation (includes typical repair)  
*Organisms:*
  - Trichomonas vaginalis
  - Fungal: Candida
  - Altered flora: Actinomyces species
  - Herpes Simplex virus

### Radiation

### Intrauterine Contraceptive Devices(IUD)

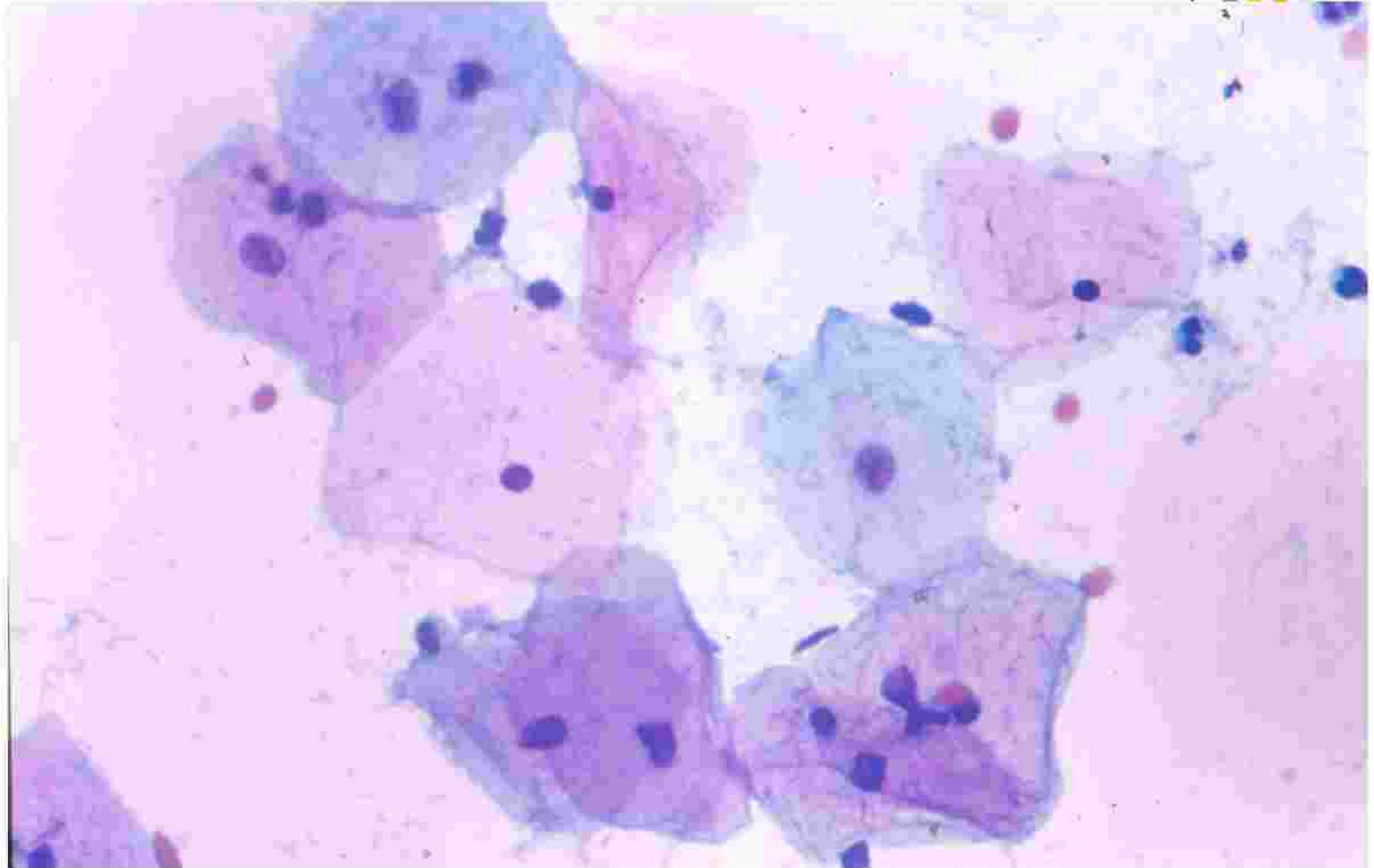
- Glandular cells status post hysterectomy
- Atrophy
- Other: Endometrial cells  
(in a woman  $\geq 40$  years of age)  
(Specify if 'negative for squamous intraepithelial lesion')

# The Bethesda System 2001

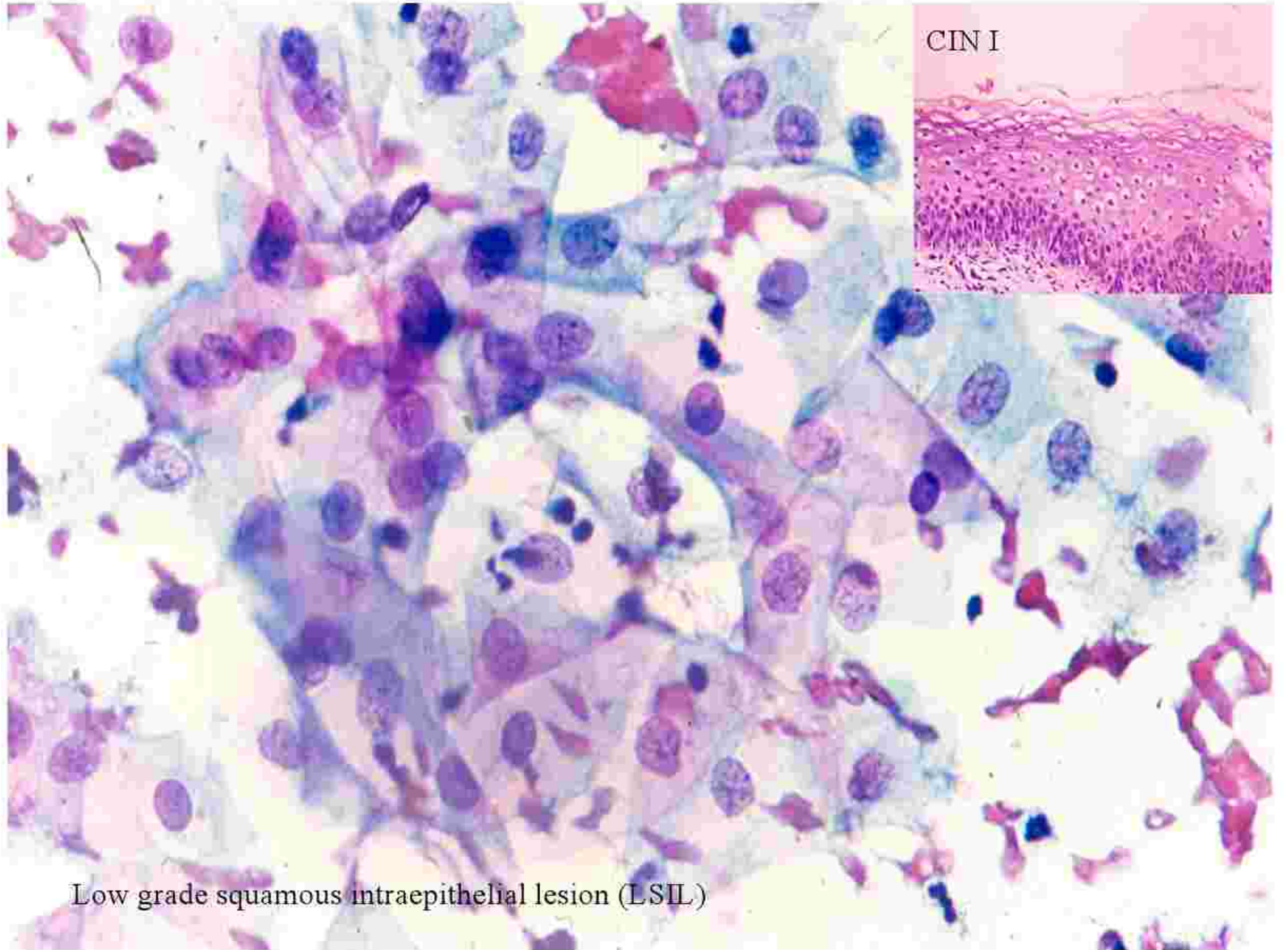


- **Epithelial Cell Abnormalities**
- **Squamous cells**
  - Atypical squamous cells
    - Undetermined significance (ASC- US )
    - Can not exclude H SIL (ASC- H)
  - Low grade Squamous Intraepithelial Lesion (LSIL)**  
**encompassing: HPV/mild dysplasia/CIN 1**
  - High grade Squamous Intraepithelial Lesion (HSIL)**  
**Encompassing: moderate and severe dysplasia, CIS; CIN 2 and CIN 3**
- **Squamous Cell Carcinoma**
  - **With features suspicious for Invasion (if invasion is suspected)**

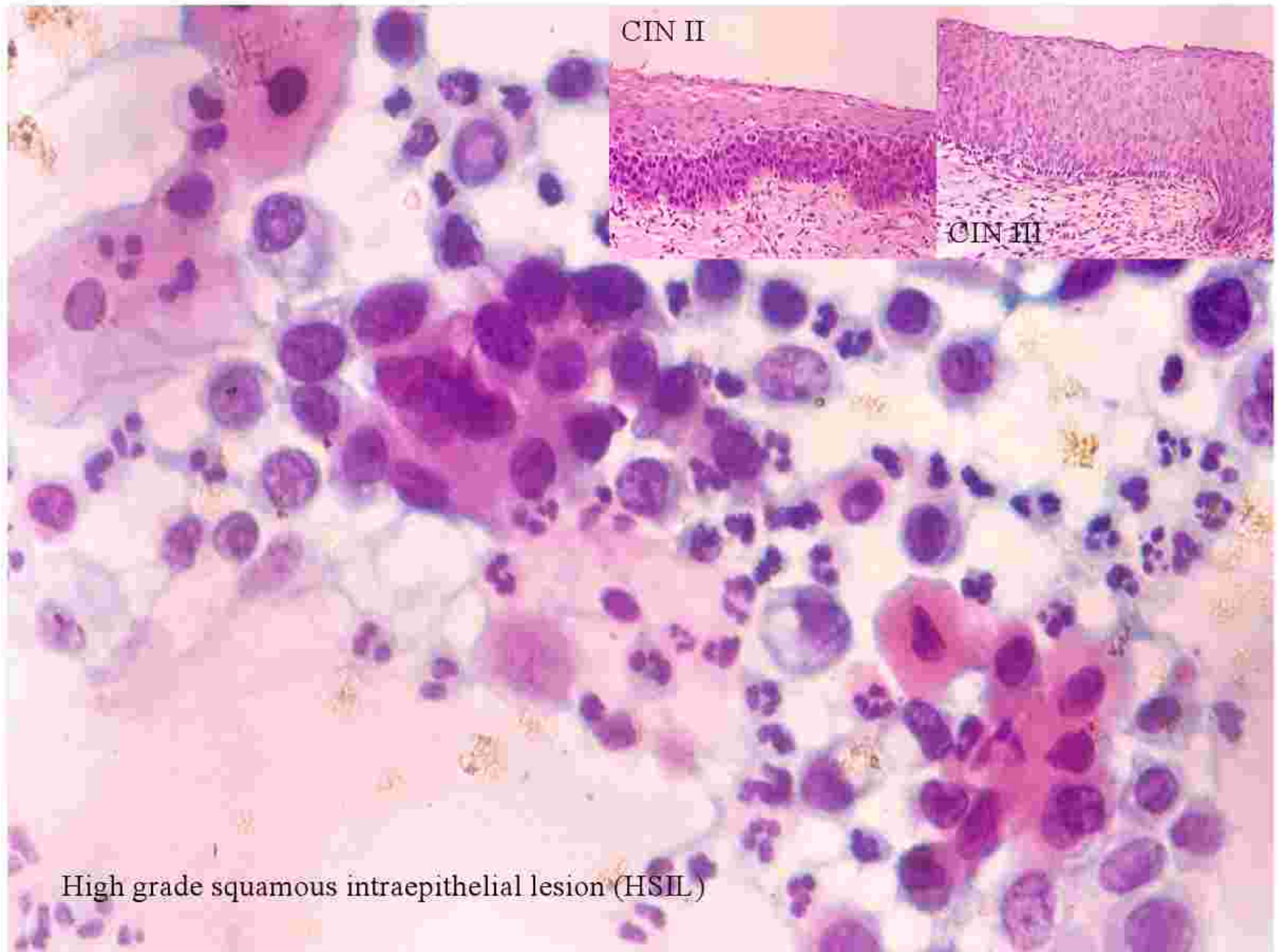
# Normal smear







Low grade squamous intraepithelial lesion (LSIL)



High grade squamous intraepithelial lesion (HSIL)



## Pap test as a guide to management of cervical Pre-cancer



| Cervical smear results   | Significance/Meaning   | Actions   |
|--------------------------|--|---|
| LSIL (2% of Pap tests)   | Mild cell changes<br>85% will regress spontaneously over 2 years; about 15% will worsen. 0.1% will become invasive if left ignored | Need colposcopy or biopsy. Treatment may be necessary.          |
| HSIL (0.5% of Pap tests) | Moderate or severe cell changes.<br>1-2% chance of becoming invasive cancer if untreated   | Need colposcopy or biopsy.<br>Treatment is necessary            |
| Invasive                 | Cells with features suggestive of invasive cervical cancer   | Urgent referral to gynecologist for investigation and treatment |

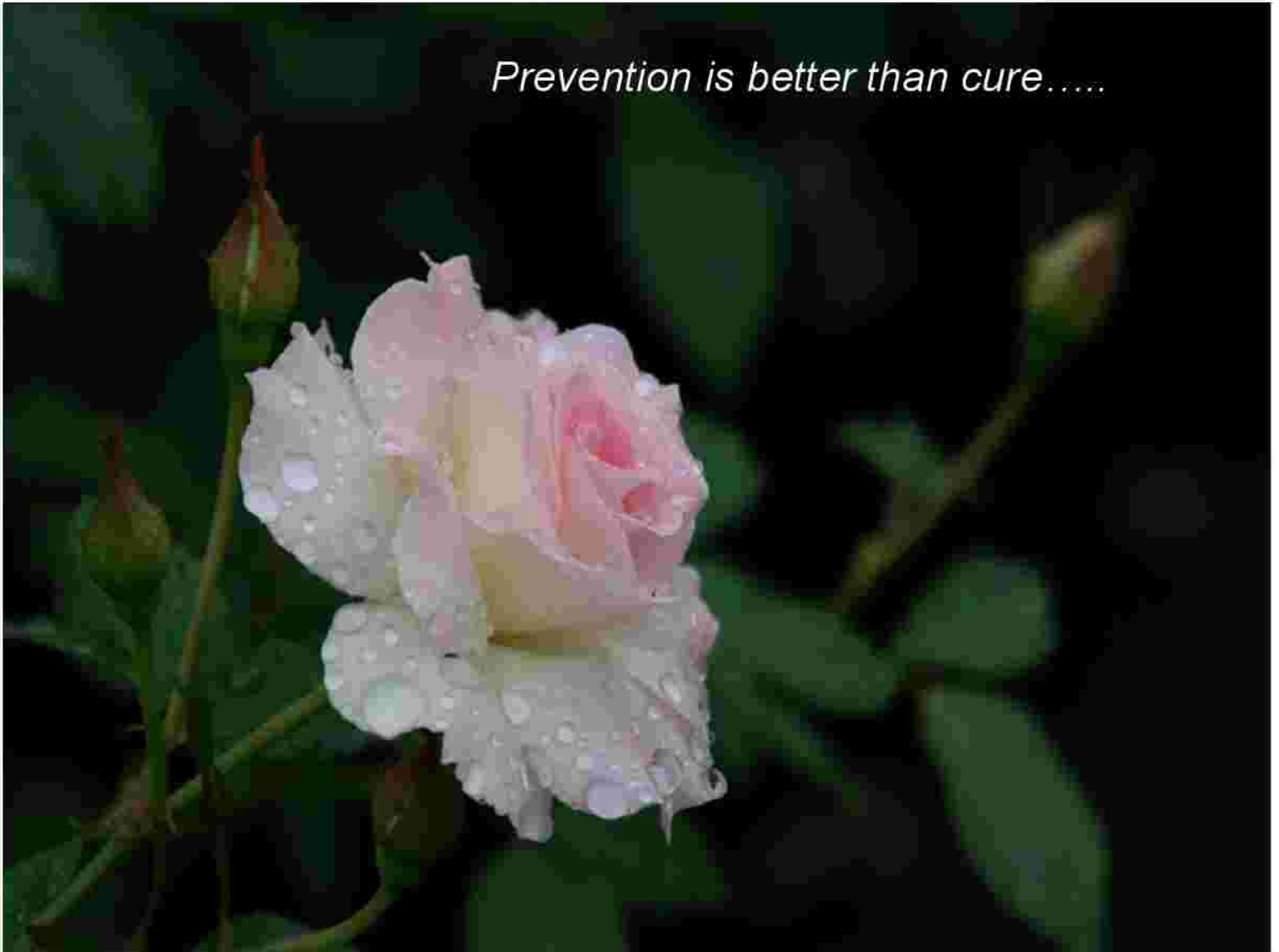

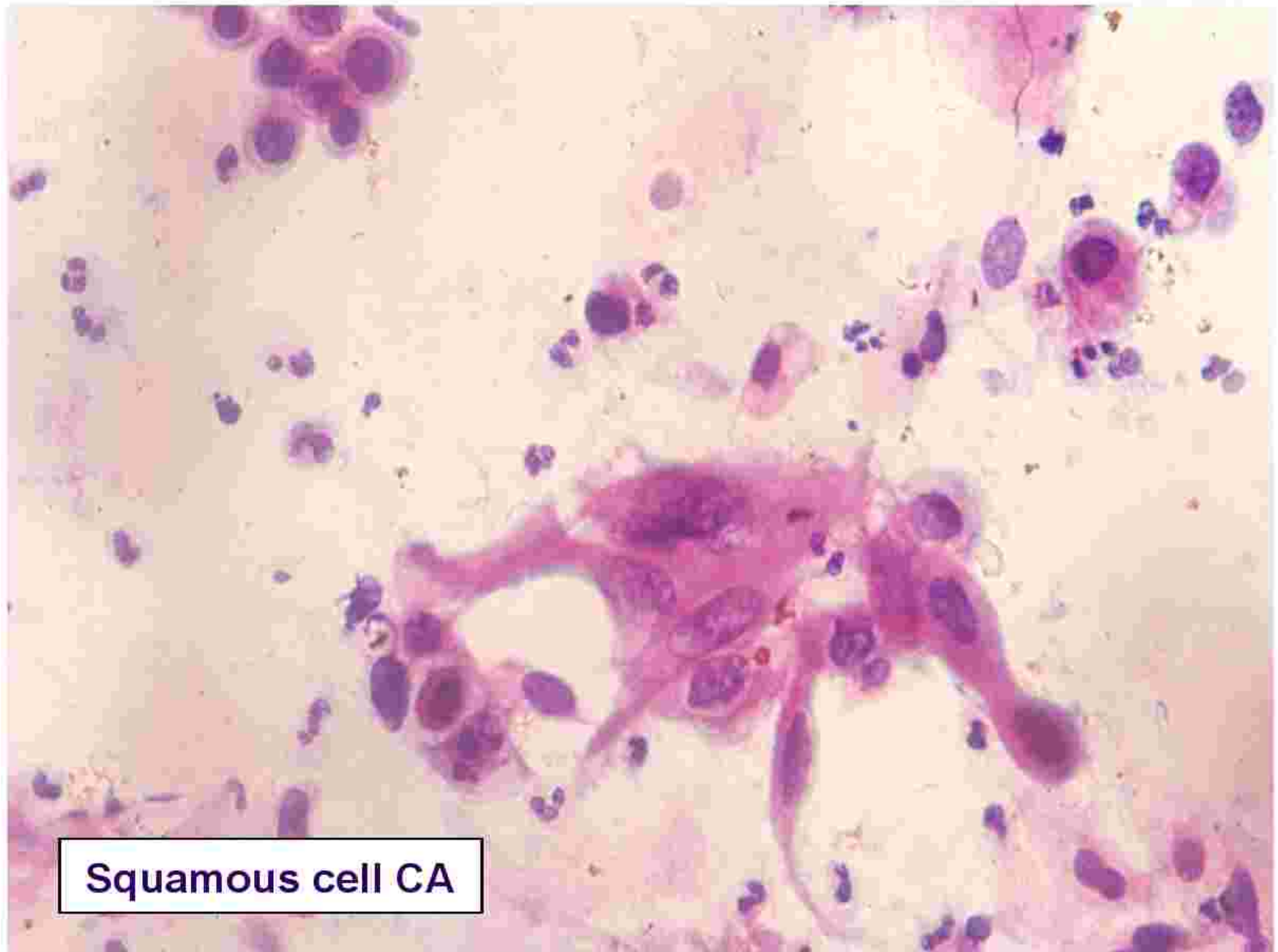## PAP smear



- Although cervical smear is currently the most effective way to prevent cervical cancer, no test is perfect.
- False negative: (about 5-20% of cervical smears), due to sampling, transfer or laboratory error.
- False positive: due to over interpretation of changes of repair, inflammation, radiation, degeneration & florid squamous metaplasia
- Liquid-based Pap test: improves both sensitivity and specificity

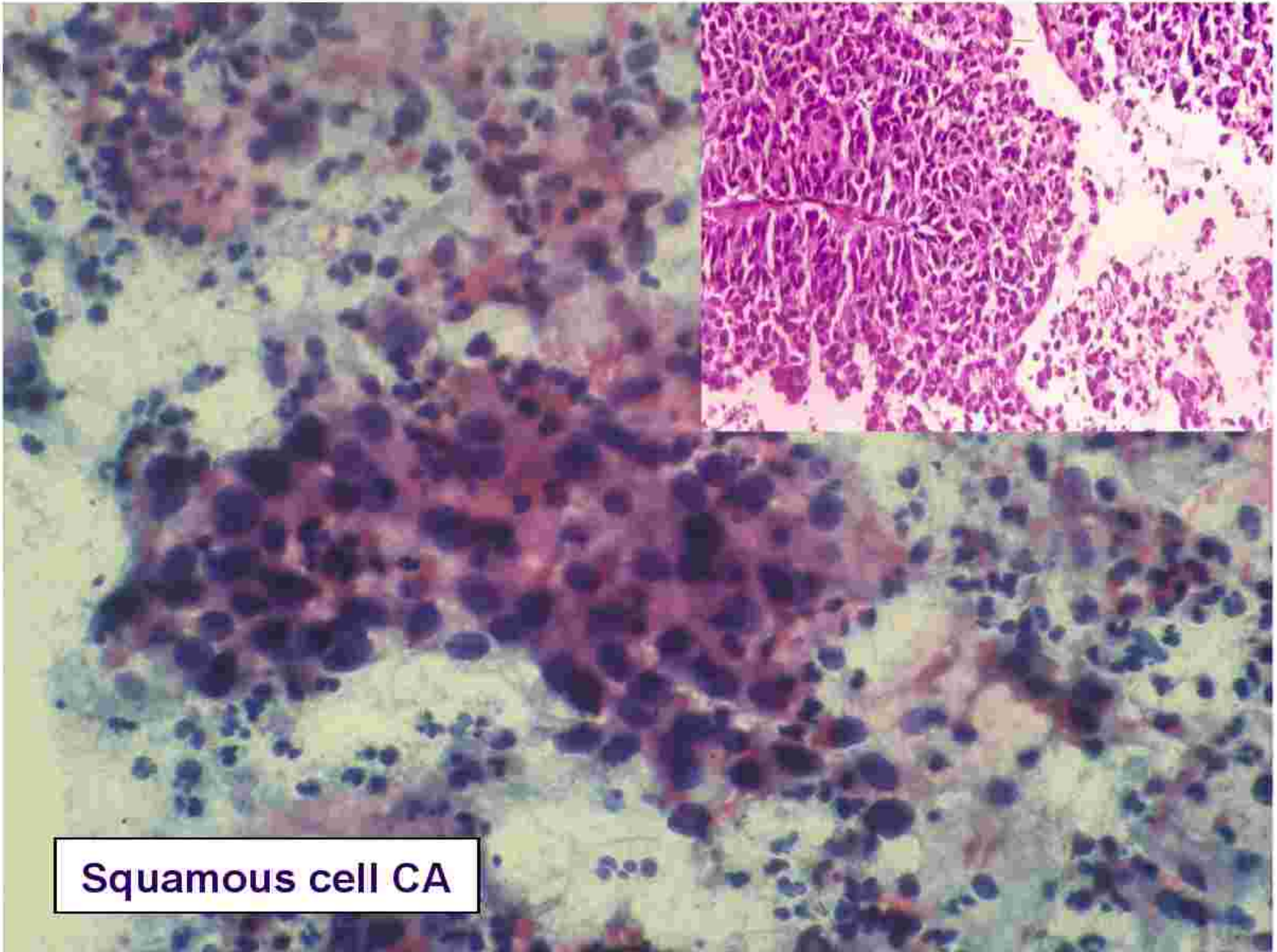
*Prevention is better than cure.....*





**Squamous cell CA**






**Squamous cell CA**

# Invasive Carcinoma of the uterine cervix

---





# FIGO Staging of Cervical Cancer



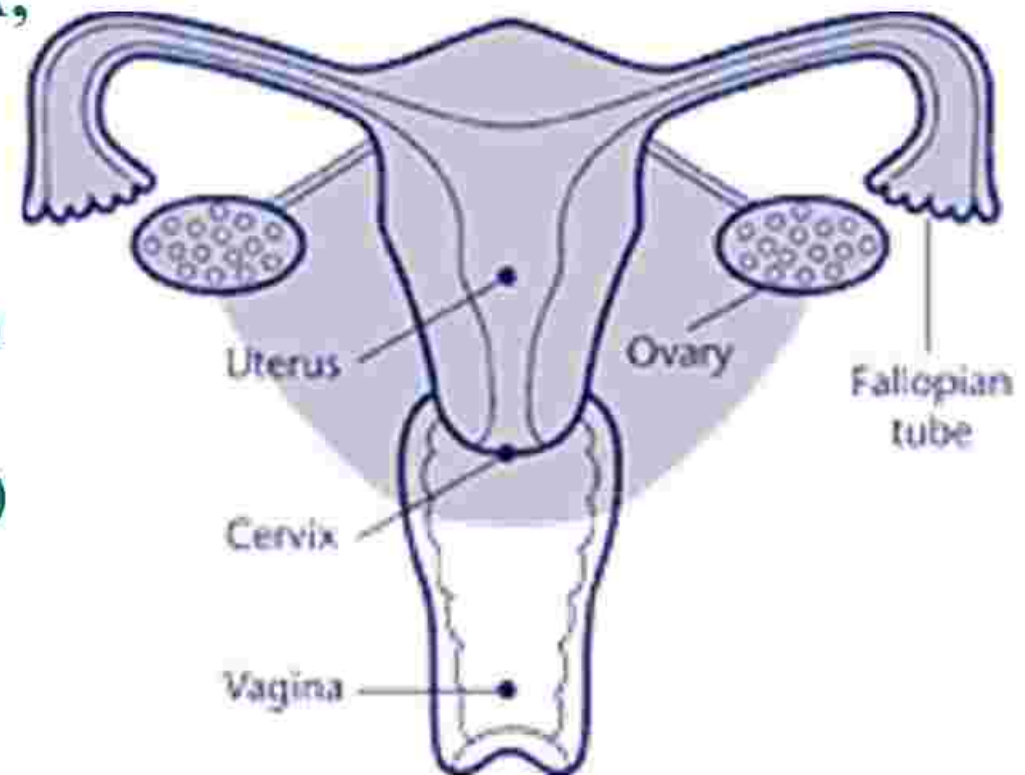
| Stage | Definition   |
|-------|--|
| 0     | Carcinoma in situ (preinvasive carcinoma)  |
| I     | Cervical carcinoma confined to uterus (extension to the corpus should be disregarded)  |
| IA    | Invasive carcinoma diagnosed only by microscopy; all macroscopically visible lesions, even with superficial invasion, are state IB |
| IA 1  | Stromal invasion no greater than 3.0 mm in depth and 7.0 mm or less in horizontal spread   |
| IA 2  | Stromal invasion > 3.0 mm and not more than 5.0 mm with a horizontal spread of 7.0 mm or less                                      |
| IB    | Clinically visible lesion confined to the cervix or microscopic lesion greater than IA2  |
| IB1   | Clinically visible lesion 4.0cm or less in greatest dimension  |
| IB2   | Clinically visible lesion more than 4.0 cm in greatest dimension   |
| II    | Tumor invades beyond the uterus but not to pelvic wall or to lower third of the vagina   |
| IIA   | Without parametrial invasion   |
| IIB   | With parametrial invasion  |
| III   | Tumor extends to the pelvic wall and/or involves lower third of vagina and/or causes hydronephrosis or nonfunctioning kidney       |
| IIIA  | Tumor involves lower third of vagina with no extension to pelvic wall  |
| IIIB  | Tumor extends to pelvic wall and/ or causes hydronephrosis or nonfunctioning kidney  |
| IVA   | Tumor invades mucosa of bladder or rectum and/or beyond true pelvis <sup>b</sup>   |
| IV    | Distant metastasis   |



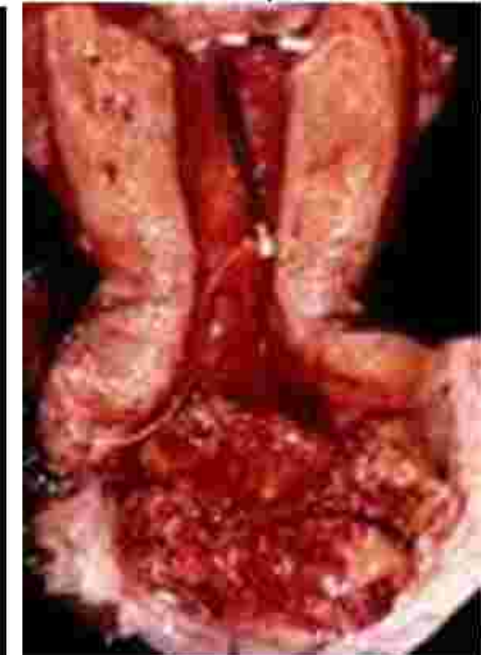
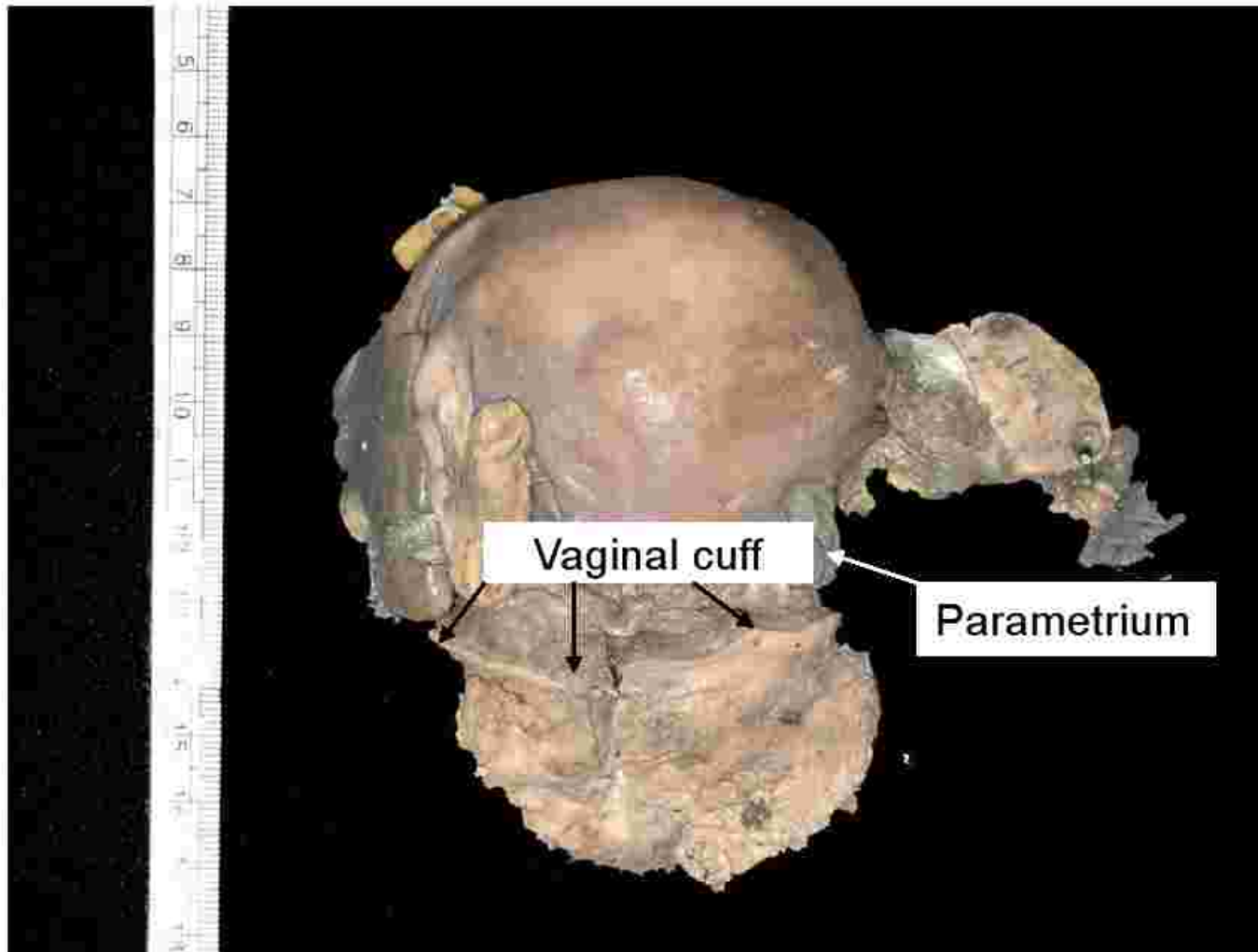
# Wertheim's hysterectomy (Radical hysterectomy)



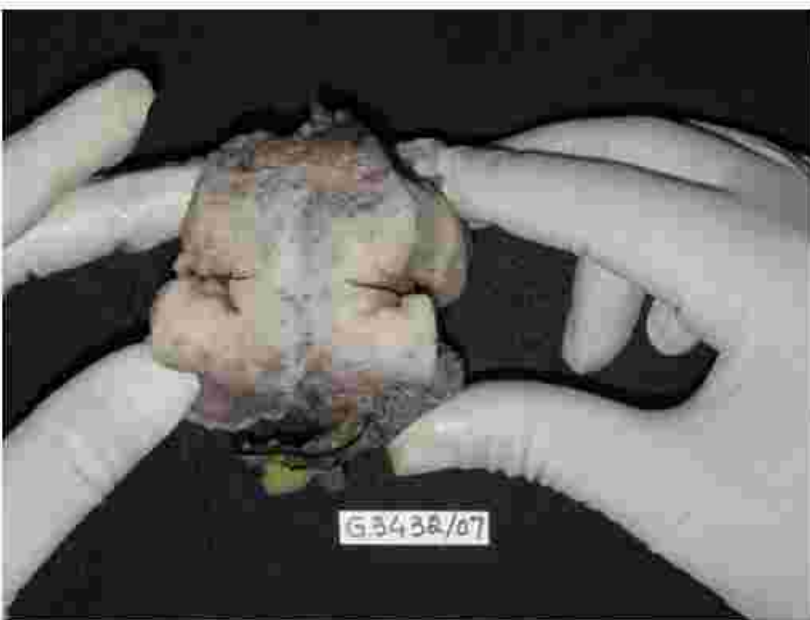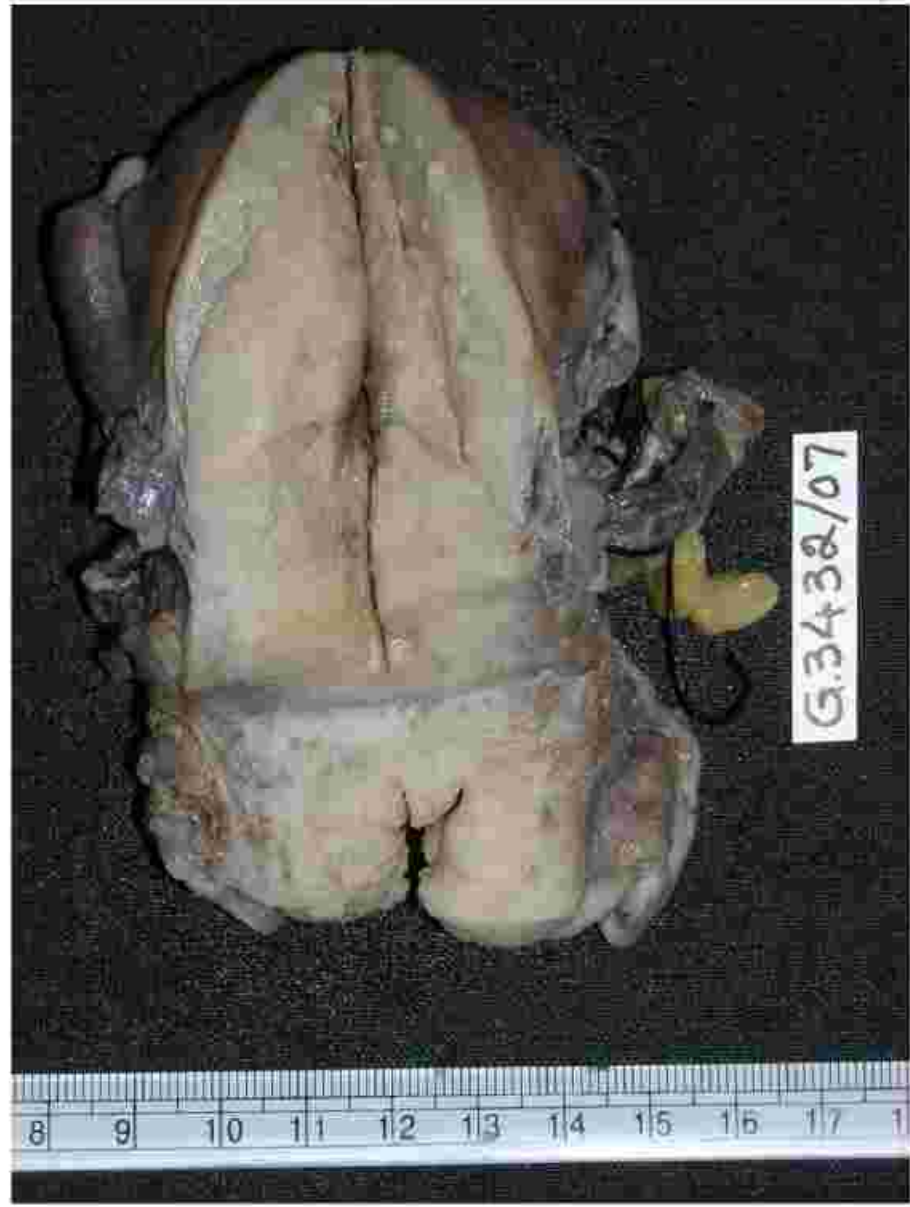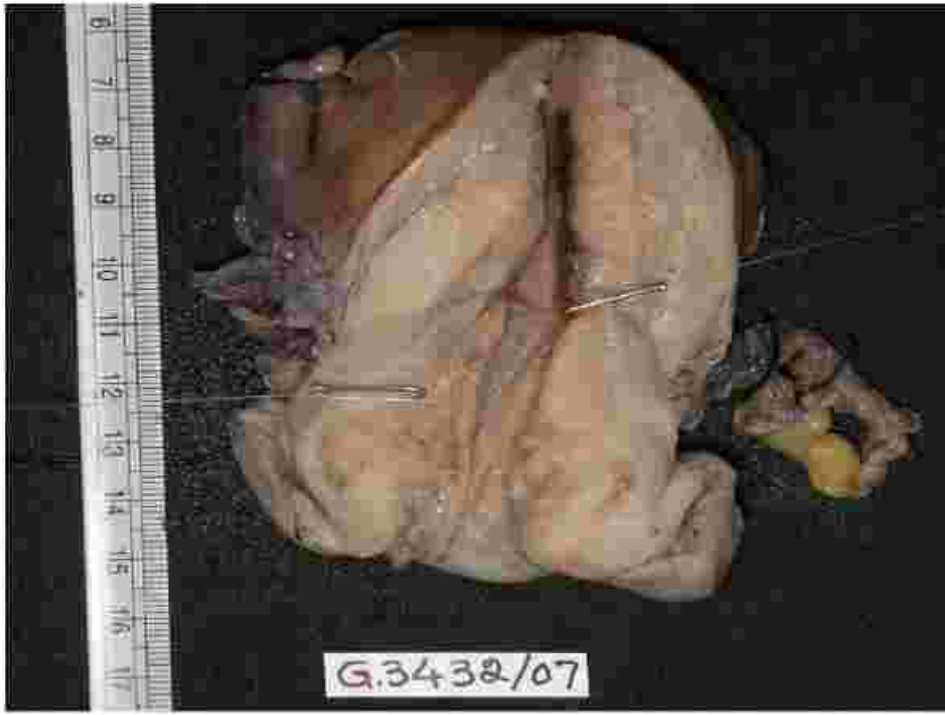- **Body of uterus and cervix, upper portion of the vagina (vaginal cuff), fallopian tubes, usually the ovaries, parametrium (the broad ligament below the fallopian tubes) and lymph glands and fatty tissue in the pelvis removed.**



# Wertheim's hysterectomy



Wertheim's (Radical) hysterectomy sp







# Gross features

- **Specimen type:** Hysterectomy/ Radical hysterectomy- Wertheim's
- **Tumor site:** Right superior quadrant/ Rt inf quadrant/ Lt sup quad/ Lt inf quadrant/ Not specified
- **Tumor size:**
- **Extent of tumor** [stromal invasion /upward extension]
- Uterine corpus/ Vaginal cuff/ Parametrium

# WHO Histological Classification of Invasive carcinomas of uterine cervix



- **Squamous Cell CA**

- **Microinvasive**
- **Invasive**
  - **Well differentiated (large cell keratinising)**
  - **Moderately differentiated (large cell nonkeratinising)**
  - **Poorly differentiated (small cell type)**
- **Verrucous**
- **Warty ( condylomatous)**
- **Papillary (transitional)**
- **Lymphoepithelioma like**

- **Adenocarcinoma**

- **Mucinous**
  - **Endocervical**
  - **Intestinal**
  - **Signet-ring type**
- **Endometrioid**
- **Clear cell ca**
- **Miminal deviation adenoCa**
- **Villoglandular**
- **Serous**
- **Mesonephric**

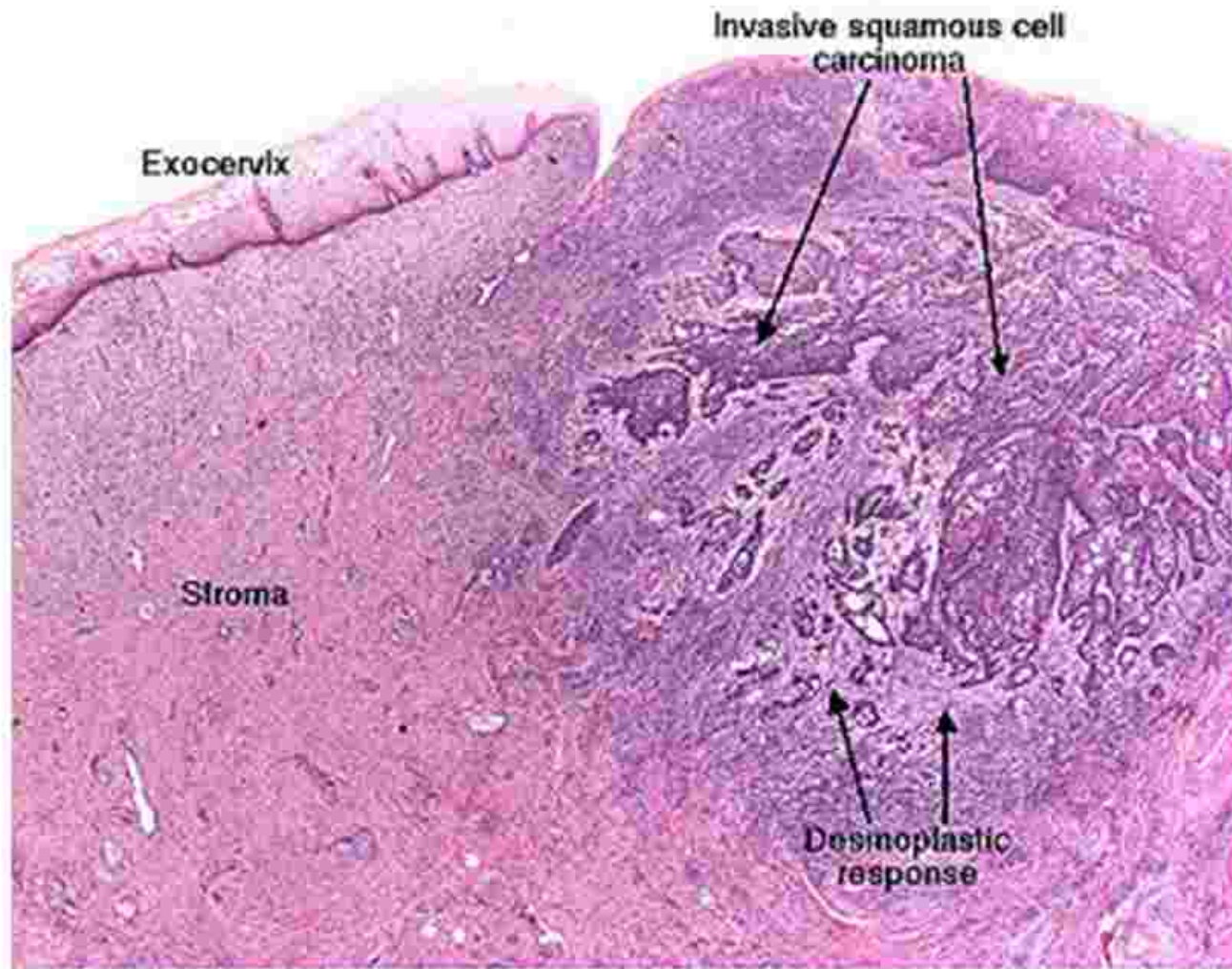
# Carcinoma cervix – histopathological types



- **Others**

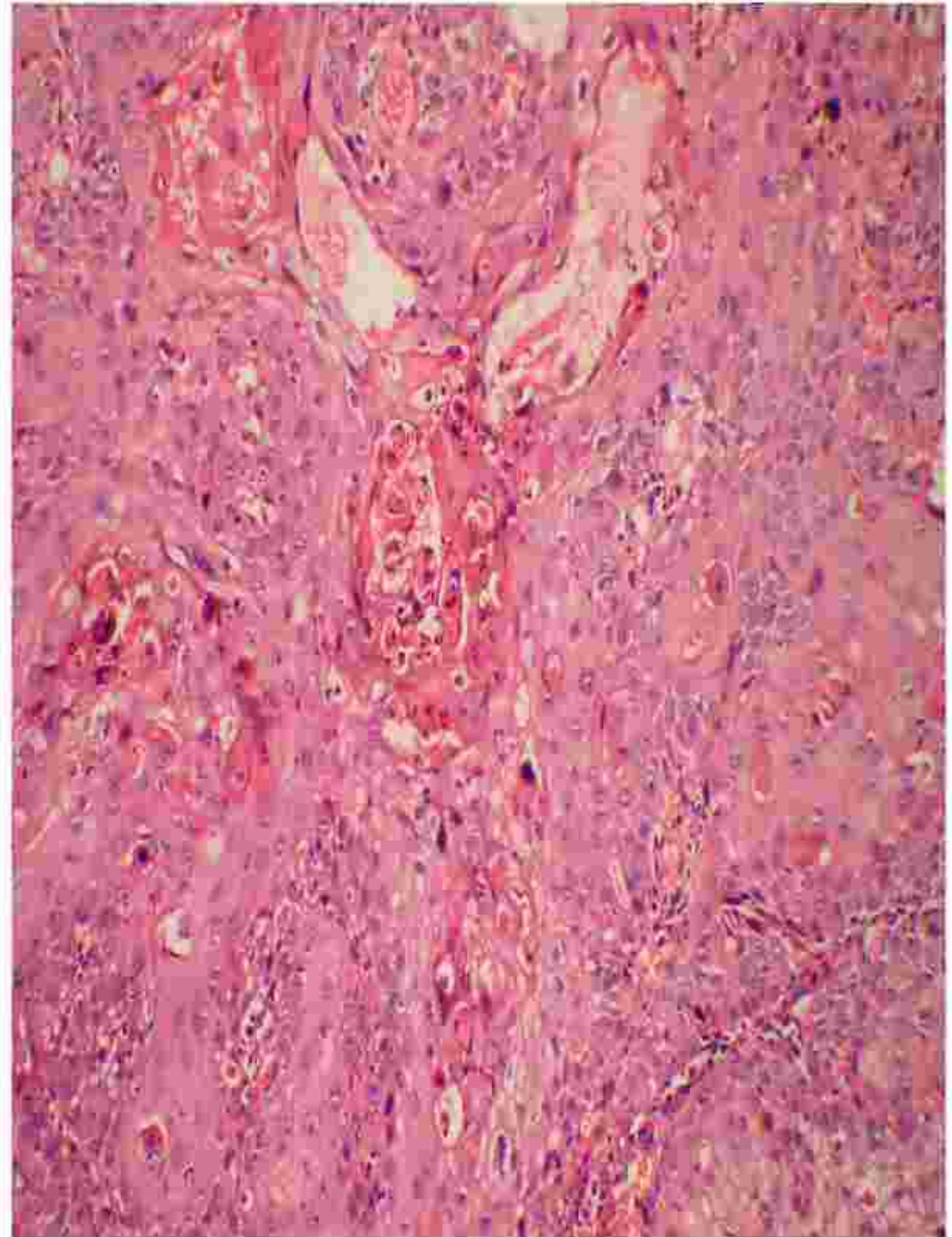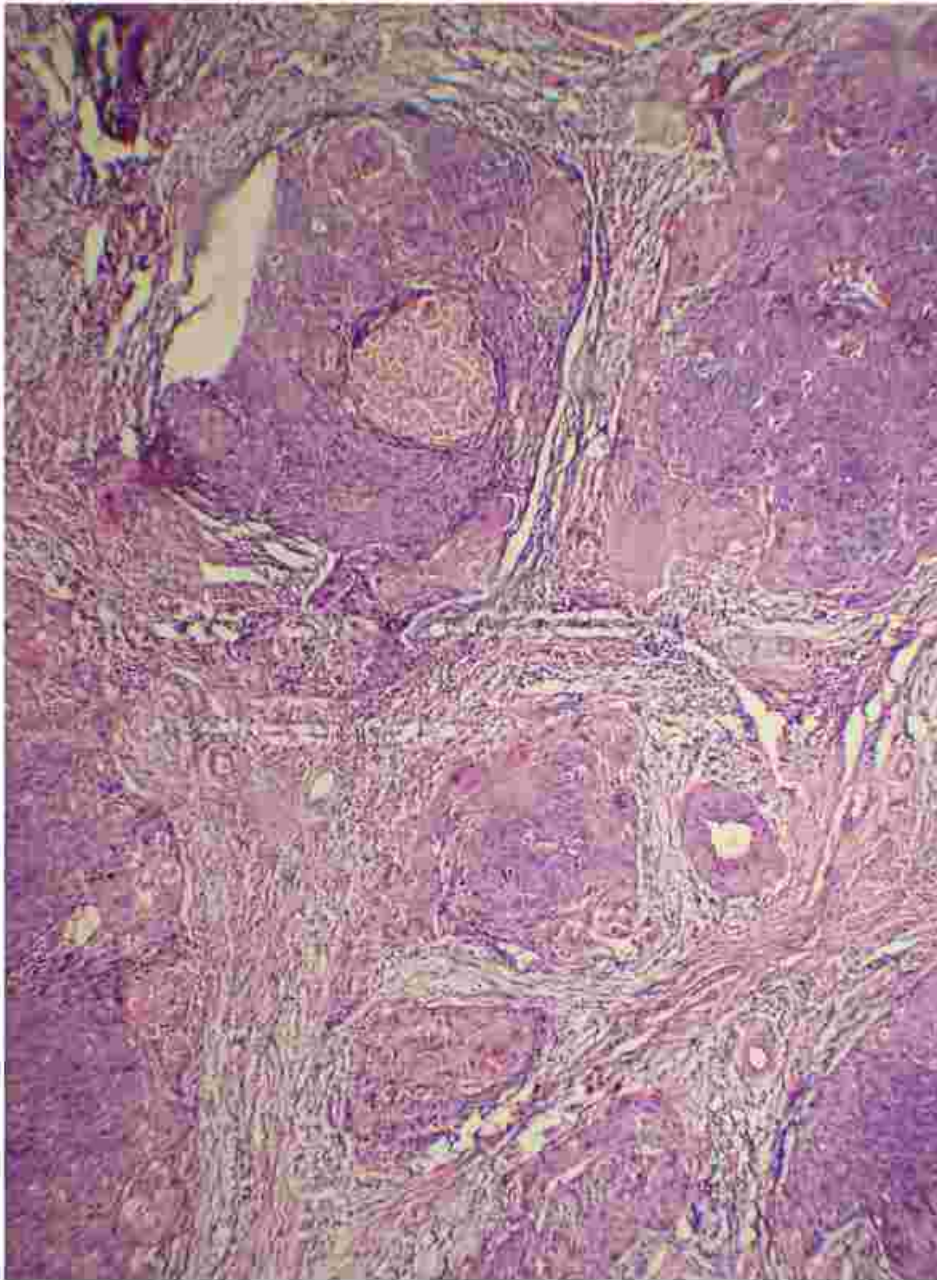
- Adenosquamous ca
- Glassy cell ca
- Adenoid cystic
- Undifferentiated ca
- Small cell ca
- Carcinoid
- Large cell neuroendocrine ca

# Early invasive squamous cell carcinoma



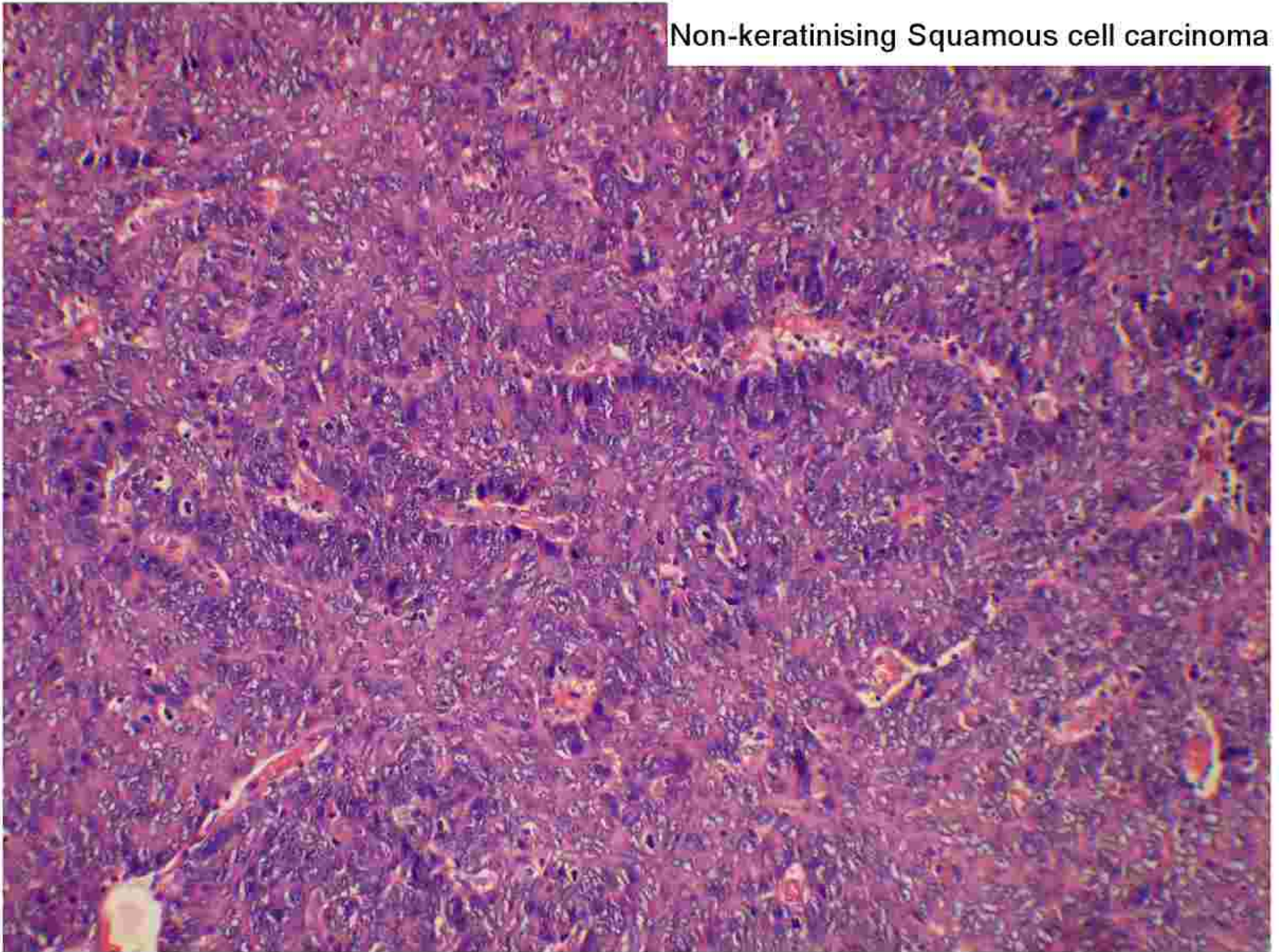


## Keratinizing SCC

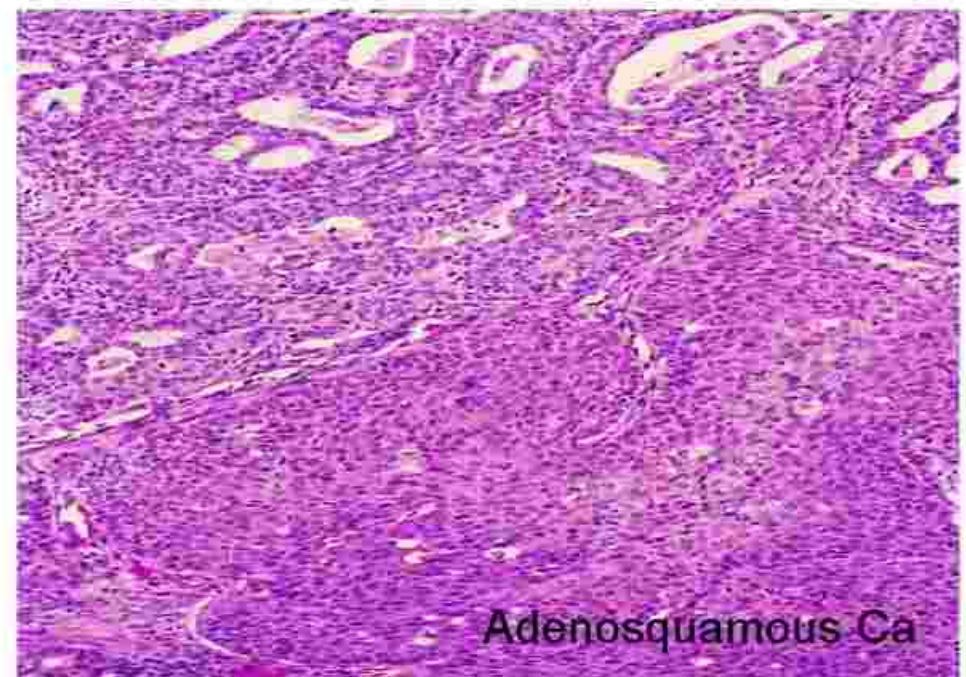
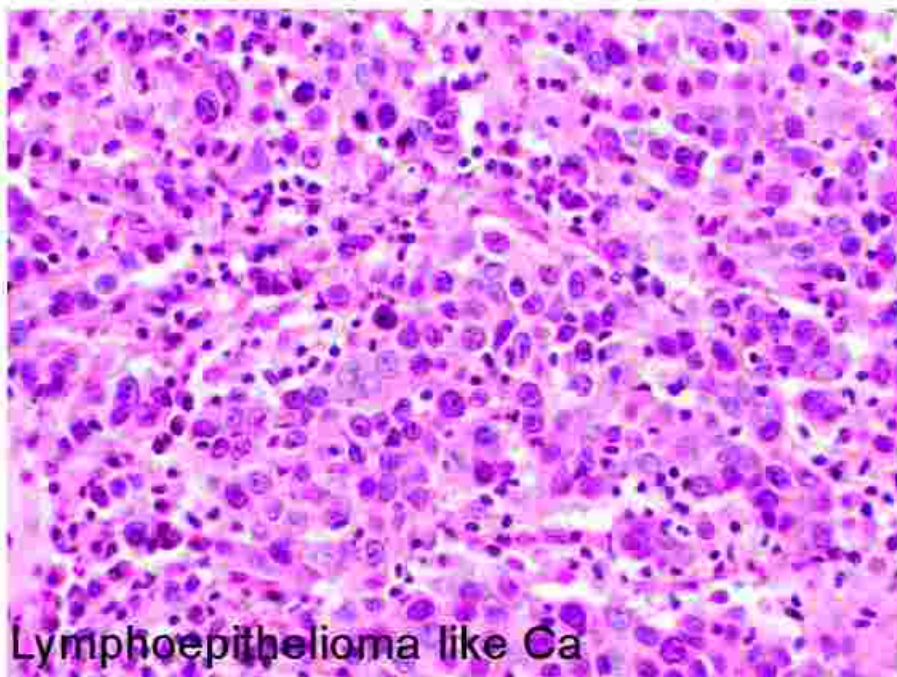
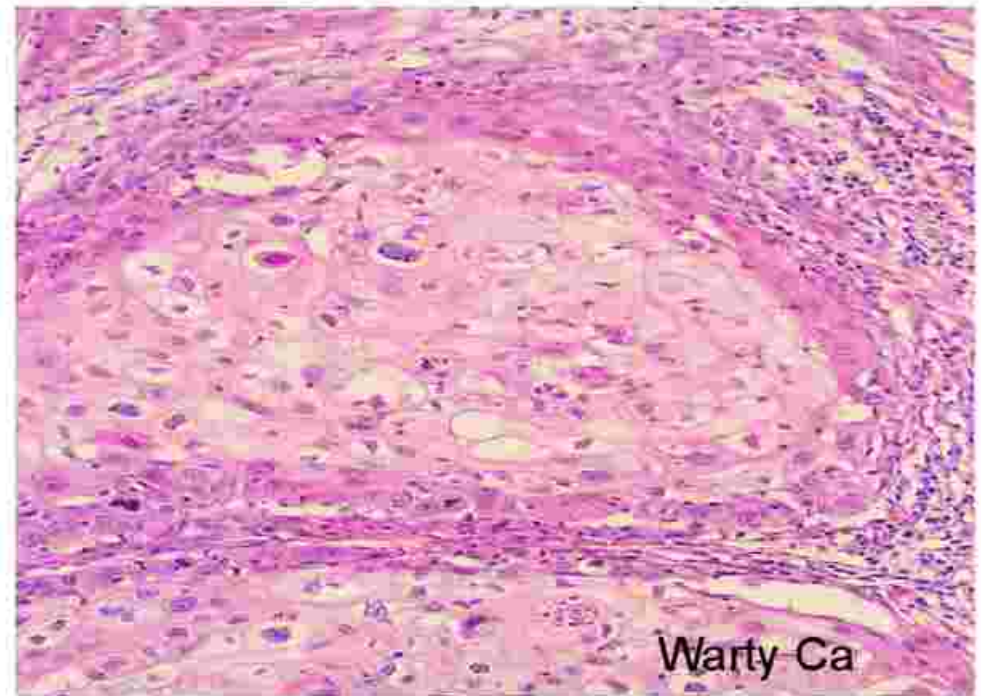
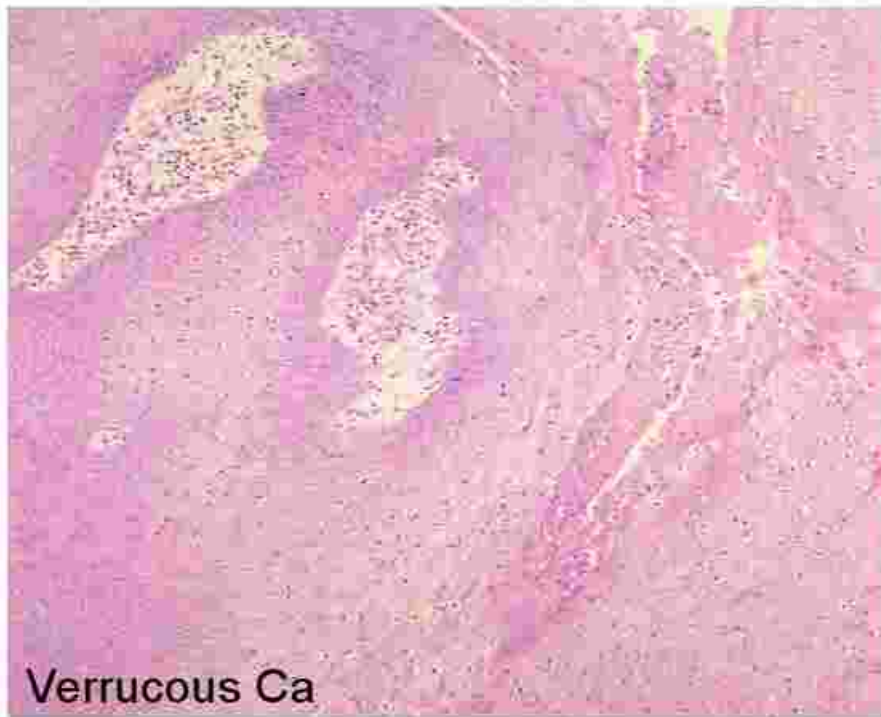



Non-keratinising Squamous cell carcinoma

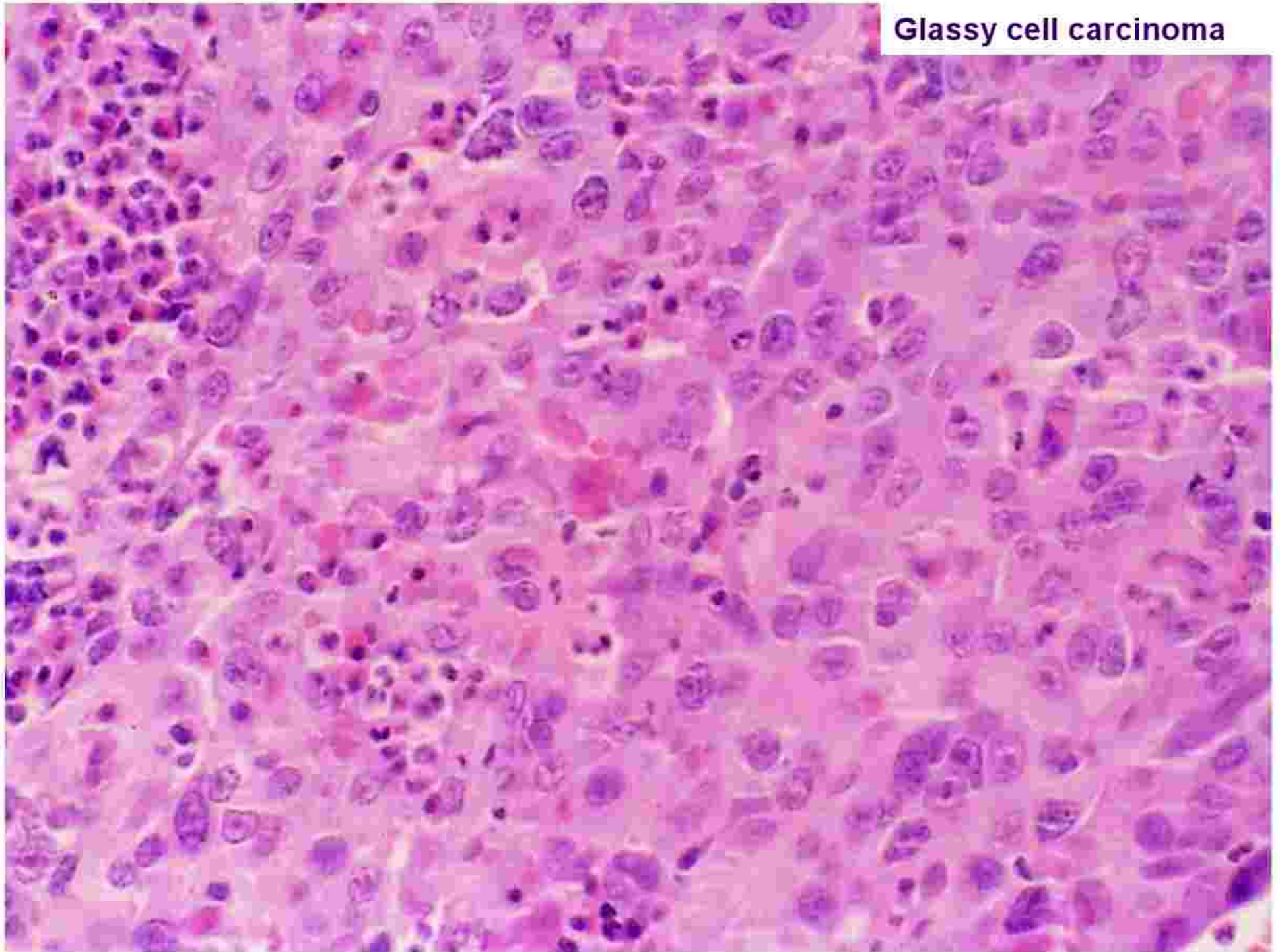



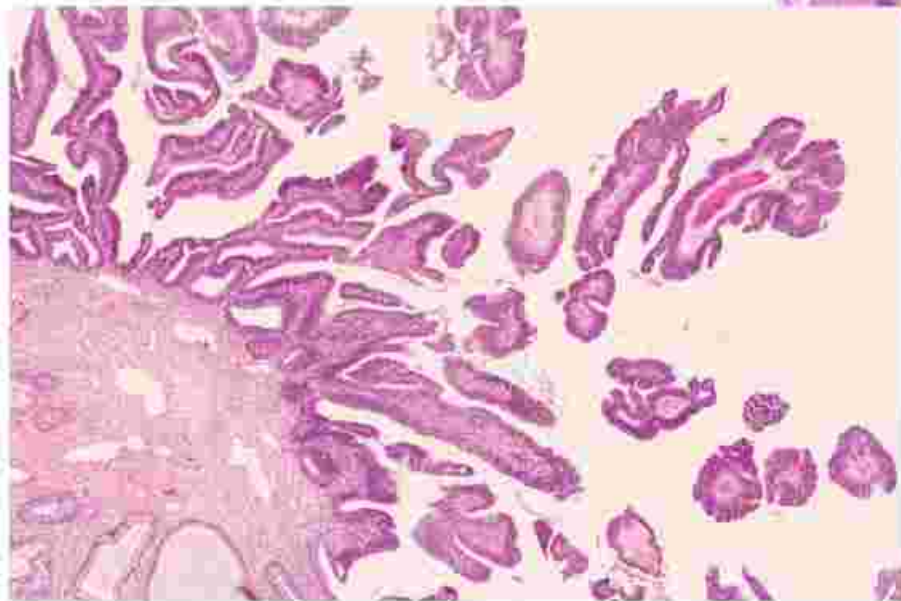
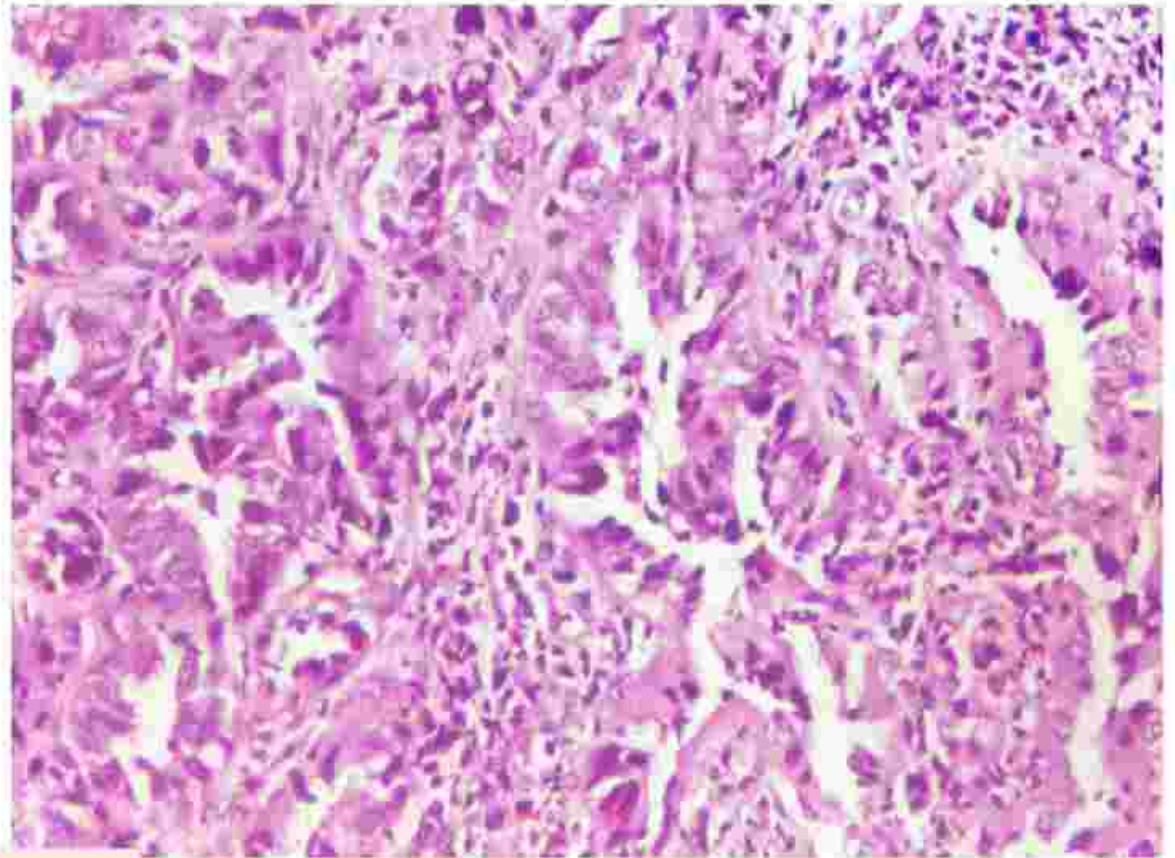




**Glassy cell carcinoma**

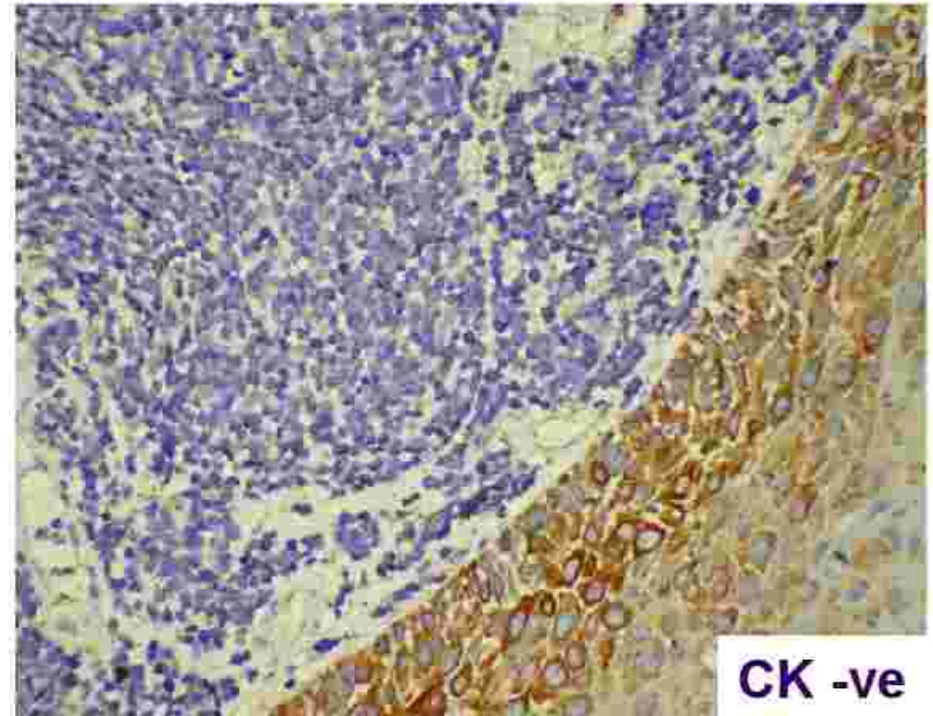
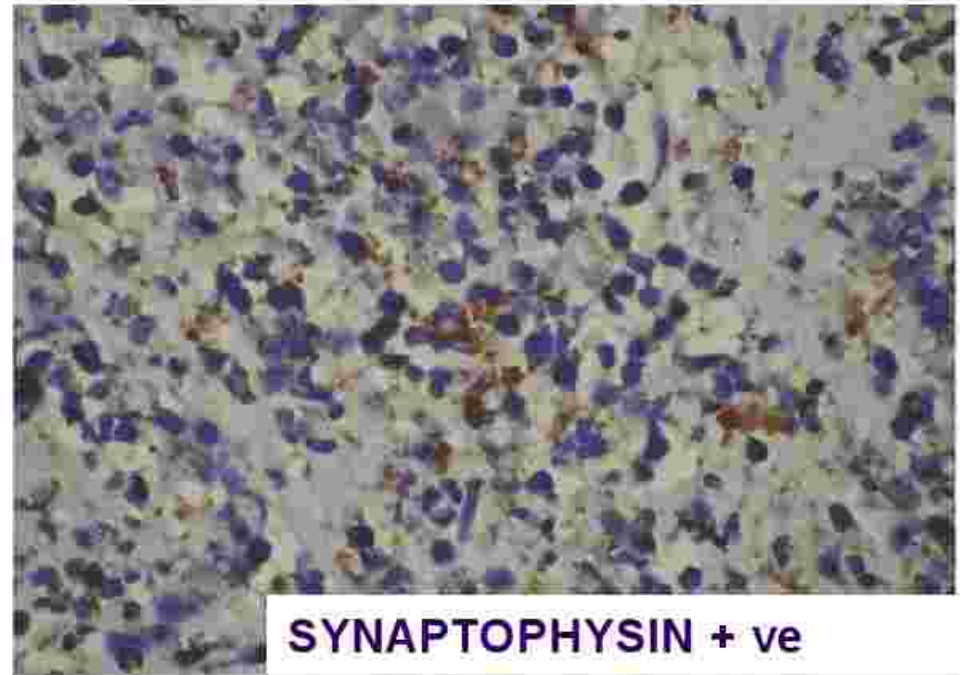
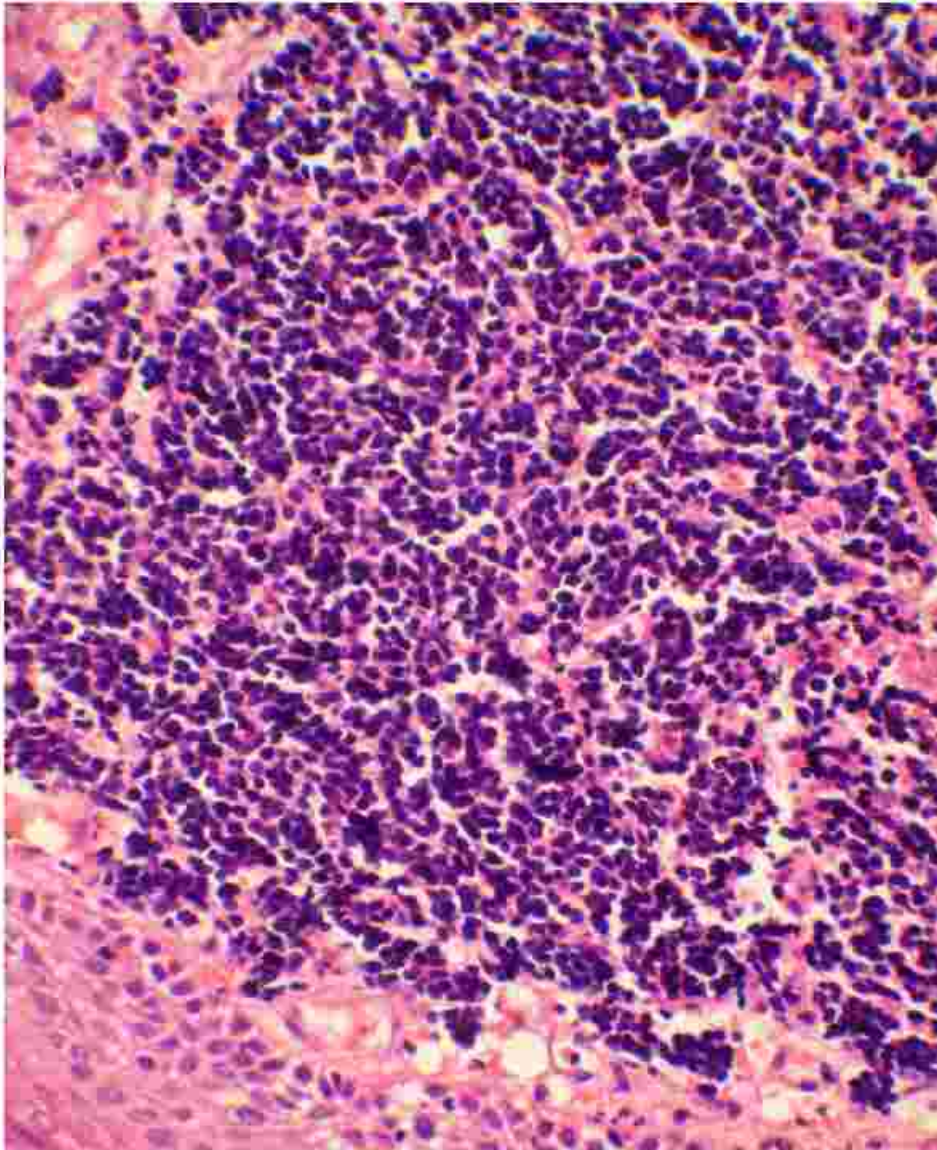


## Adenocarcinoma Cervix





# Neuroendocrine Ca cervix





# Histological type and prognosis



- For a given stage, the histological type of tumor has little bearing on the prognosis.
- However, some subtypes such as small cell carcinoma, neuroendocrine carcinoma and adenosquamous ca tend to have a worse prognosis

# Histopathologic Prognostic factors



- Tumor size
- Depth of invasion (measured in millimeters or in thirds of cervical stromal thickness)
- Tumor growth pattern
- Mitotic rate
- Lympho-vascular space involvement (LVSI)
- Status of the surgical margins
- Vaginal involvement
- Lymph node status
- Parametrial involvement.

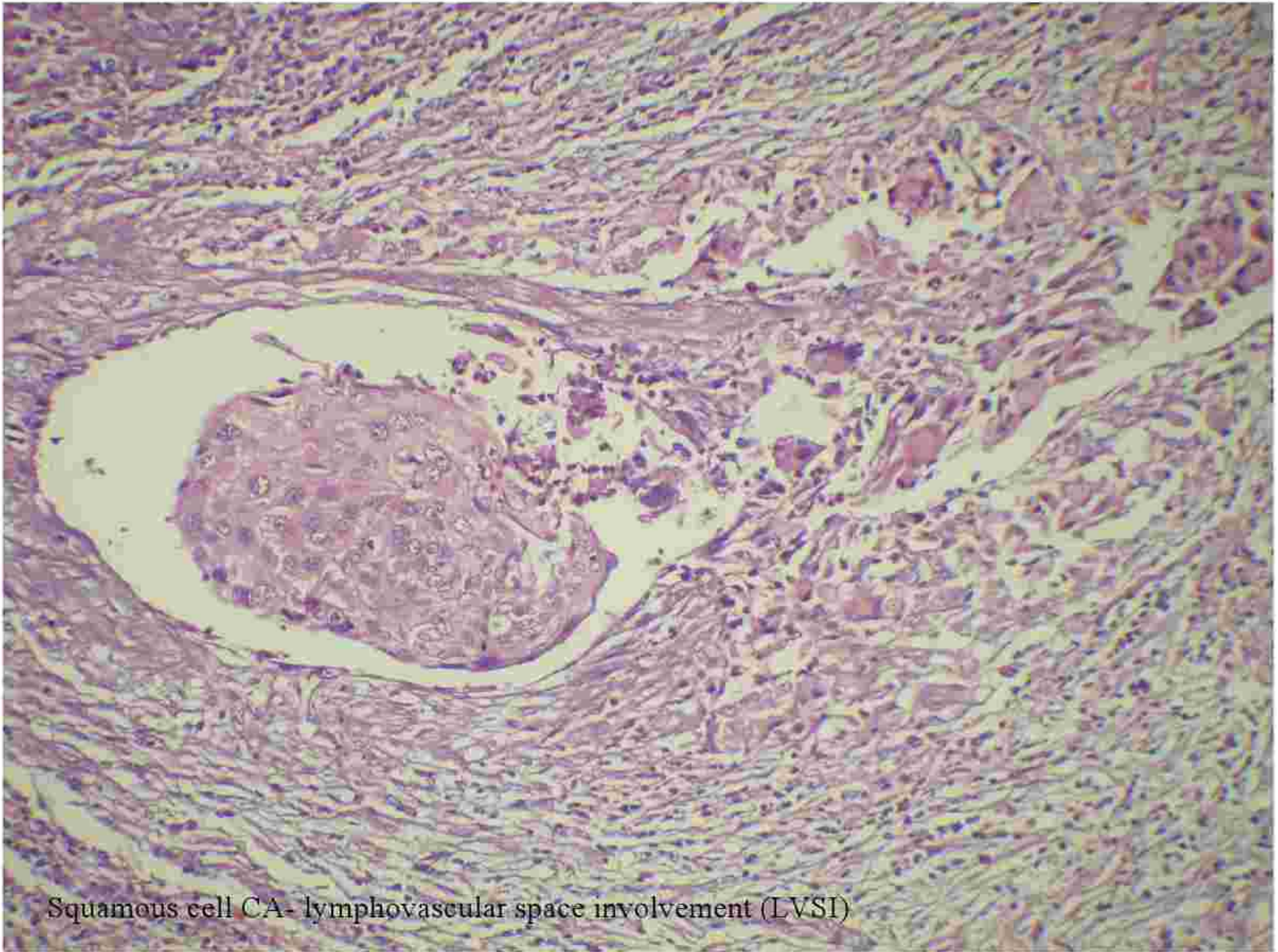
# Depth of cervical stromal invasion



- Increasing depth of invasion strongly correlate pelvic nodal spread and diminished progressive- free interval (PFI) at 5 years. Cancer 1992; 69: 1750-8
- Increasing depth of invasion correlates closely with parametrial extension Cancer 1984; 54:3035-42.

| Depth of invasion | % positive nodes | % PFI at 5 yr |
|-------------------|------------------|---------------|
| 3-4 mm            | 0                | 100           |
| 5-7 mm            | 18               | 88            |
| 8-10 mm           | 23               | 77            |
| 11-15 mm          | 32               | 54            |
| 16+ mm            | 23               | 54            |





Squamous cell CA- lymphovascular space involvement (LVSI)


# Microinvasive Squamous Cell carcinoma (FIGO Stage IA)



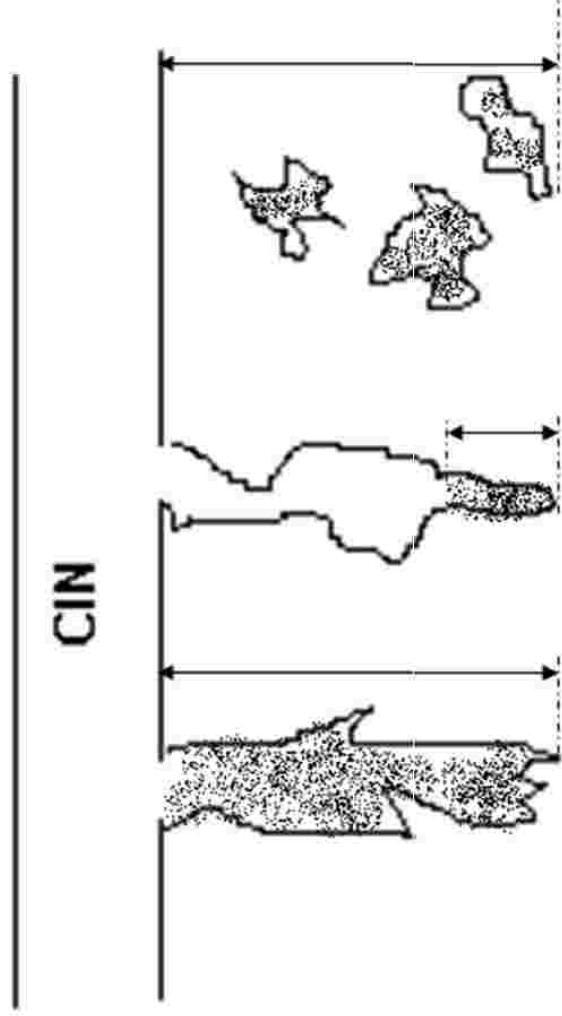
- Also known as Superficially Invasive carcinoma or carcinoma with early invasion. Tongues of malignant cells penetrate the basement membrane
- IA- Depth of invasion is not more than 5mm from the base of the epithelium and horizontal spread not more than 7mm
  - IA1 – stromal invasion  $\leq$  3mm
  - IA2 – stromal invasion  $>$ 3mm

Diagnosis by pap smear is difficult and done by biopsy – a cone biopsy or LEEP specimen

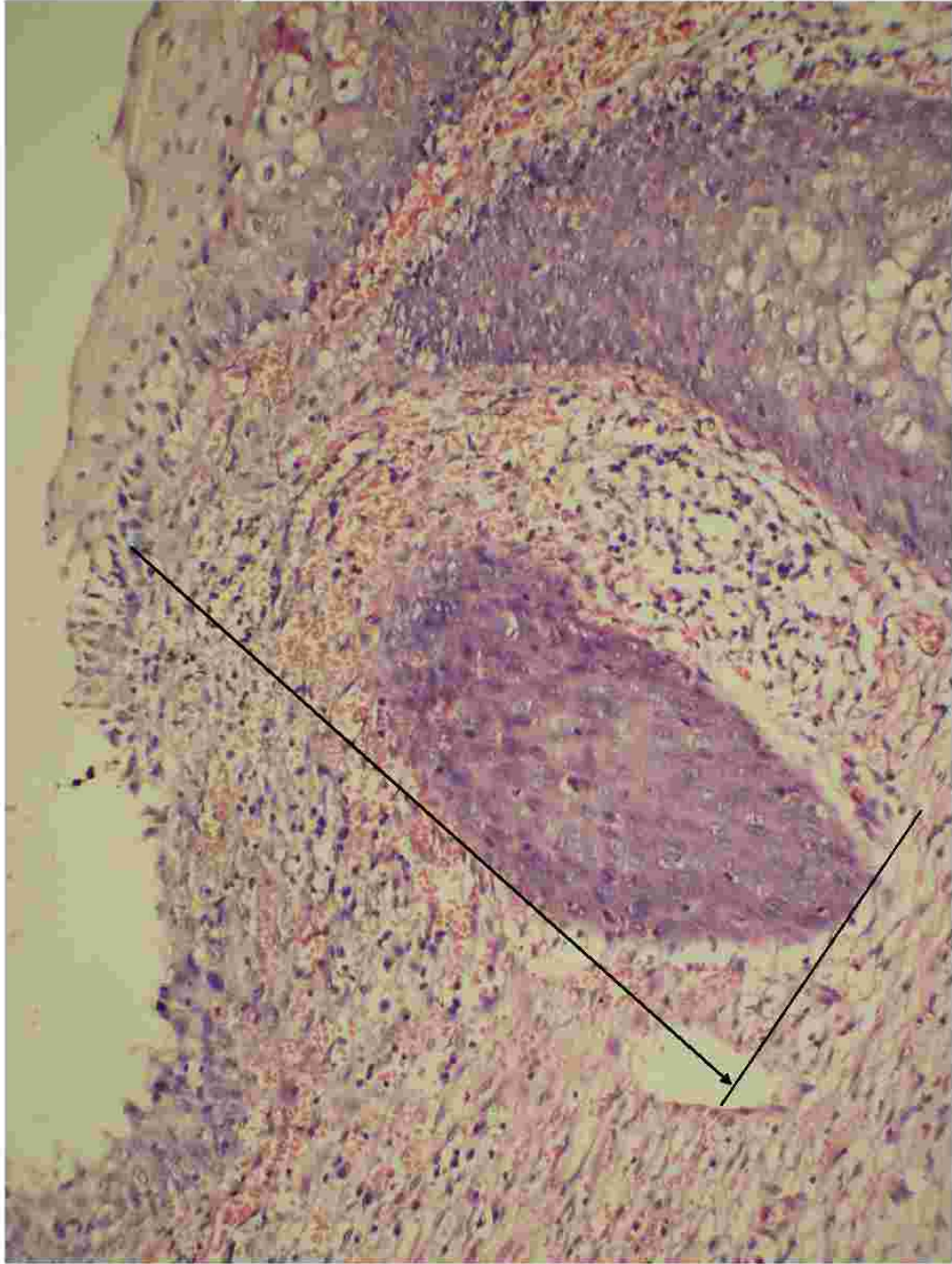MICA have virtually no potential for metastases or recurrence



## DEPTH OF INVASION







# Canned report



**Specimen type:** Hysterectomy/ Radical hysterectomy- Wertheim's

**Tumor site:** Right superior quadrant/ Rt inf quadrant/ Lt sup quad/ Lt inf quadrant/ Not specified

**Tumor size:**

**Extent of tumor** [stromal invasion /upward extension]

Uterine corpus/ Vaginal cuff/ Parametrium

**Other organs:**

Rt. Ovary/ Lt. Ovary/ Rt. Fallopian tube/ Lt. Fallopian Tube

**Microscopy:**

Histologic Type:

Histologic Grade:

Extent of invasion:

**Margins** (check all that apply):

Cannot be assessed/ Uninvolved by ca/ Distance of tumor from closest margin/ Specify if in-situ changes are present at distal margin

Margin Involved –Specify location

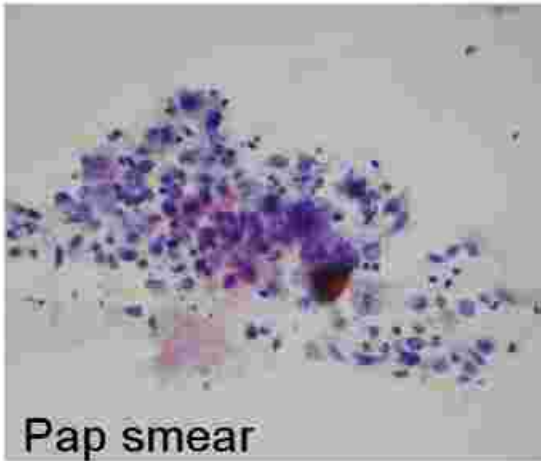
**Lymphatic and venous invasion:** Present / Absent / indeterminate

**Additional pathological findings:** None / intraepithelial neoplasia / others

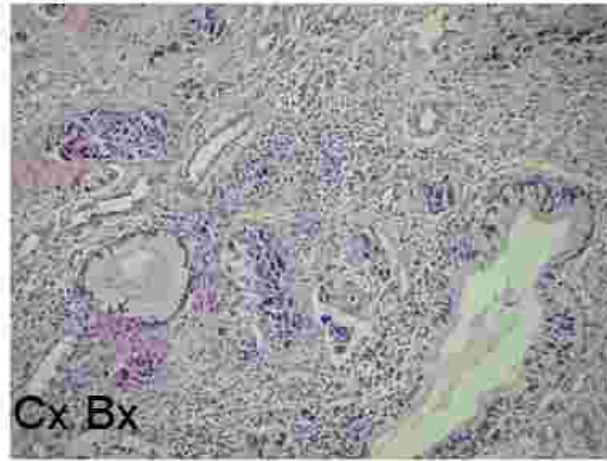
**Comment:**

**Pathologist:**

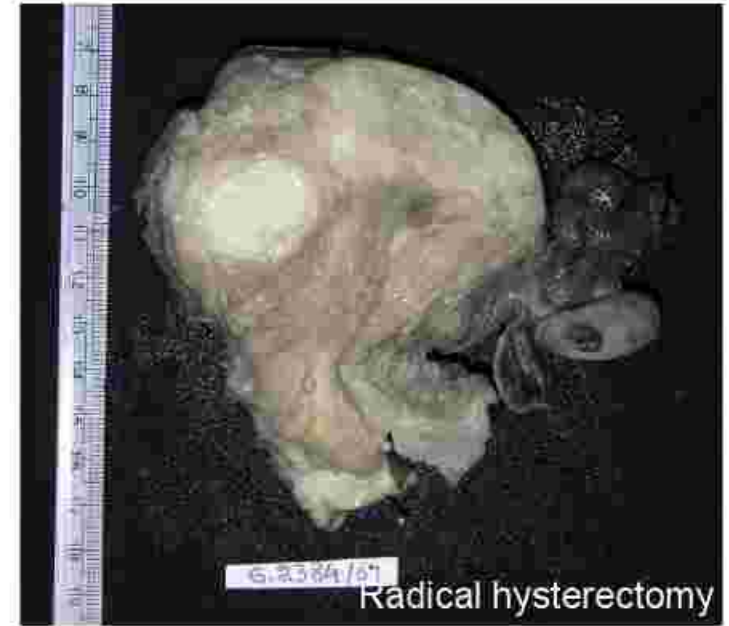



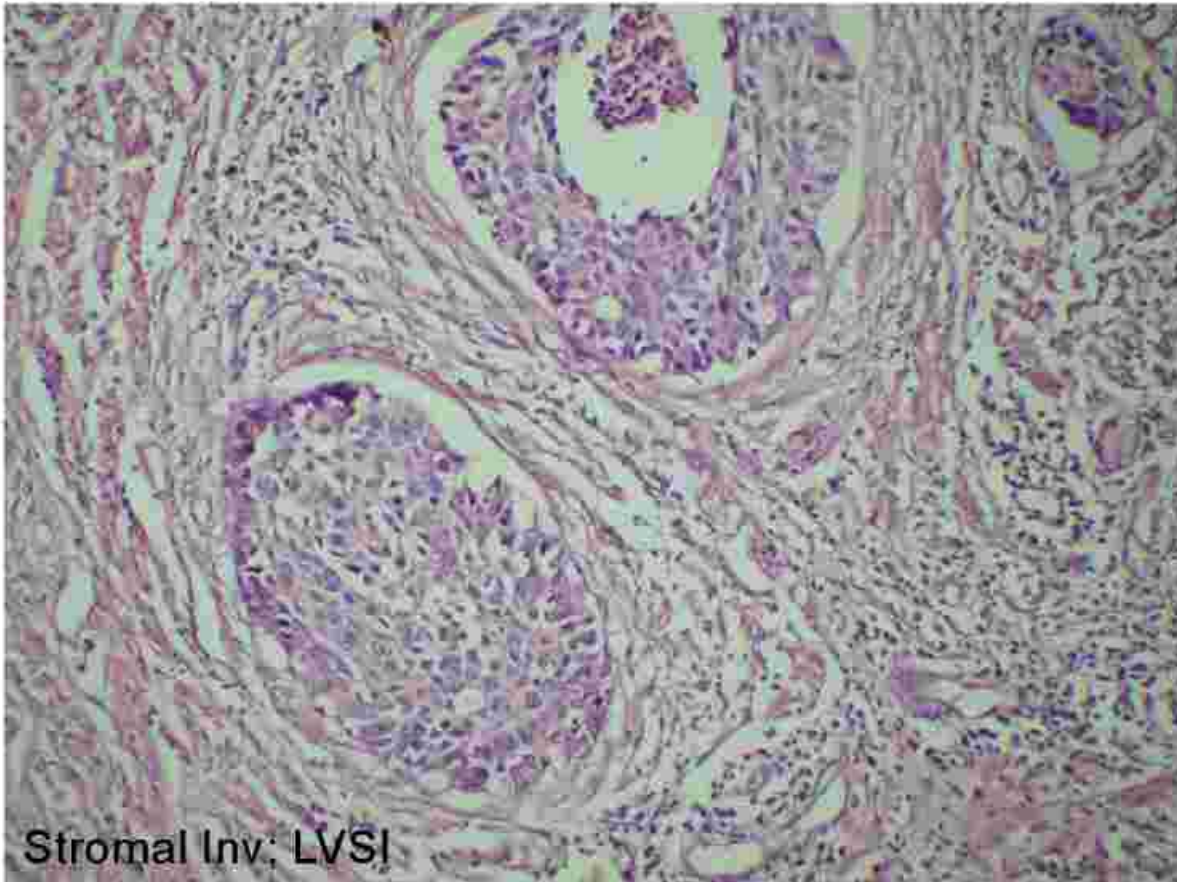
Pap smear



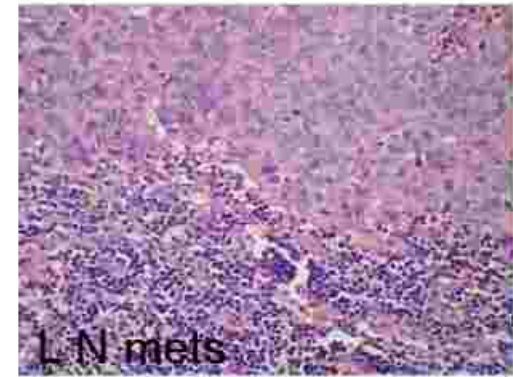
Cx Bx



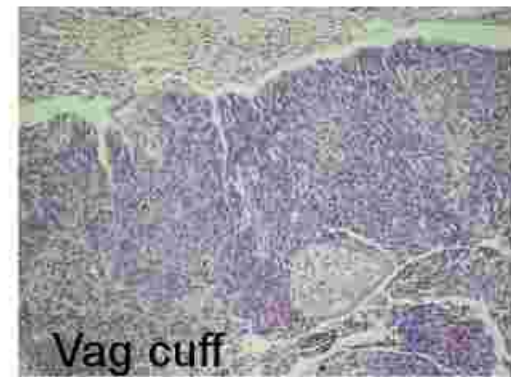Radical hysterectomy



Stromal Inv; LVSI



LN mets




Vag cuff



# Sample HPE Report



- **Specimen type:** Radical hysterectomy- Wertheim's
- **Tumor site:** Circumferential
- **Tumor size:** 4X3X2 cms
- **Extent of tumor [stromal invasion /upward extension]**
  - Uterine corpus – Free
  - Vaginal cuff – involved
  - Parametrium- Free
- **Other organs:** Rt. Ovary/ Lt. Ovary/ Rt. Fallopian tube/ Lt. Fallopian Tube - Free
- **Microscopy:**
- **Histologic Type:** Squamous cell Ca, non-keratinising
- **Histologic Grade:**G2
- **Extent of invasion:**More than half stromal thickness
- **Margins (check all that apply):**
  - Distance of tumor from closest margin – 3mm, involved
- **Lymphatic and venous invasion:** Present
- **Lymph nodes:** Ext iliac group : Metastases present (1/3). Rest - free
- **Pathologist:**



# Treatment of Cervical Cancer



- ❖ **Stage 0:** Loop electrosurgical excision procedure (LEEP), laser therapy, conization or cryotherapy
- ❖ **Stage IA: Standard treatment- total hysterectomy.**
  - Lymph node dissection is not required if the **depth of invasion is less than 3 mm** and no lympho-vascular invasion is noted.
- ❖ **Stage IB or IIA**
  - Either **combined external beam radiation with brachytherapy** or **radical hysterectomy with bilateral pelvic lymphadenectomy.**



# Treatment of Cervical Cancer

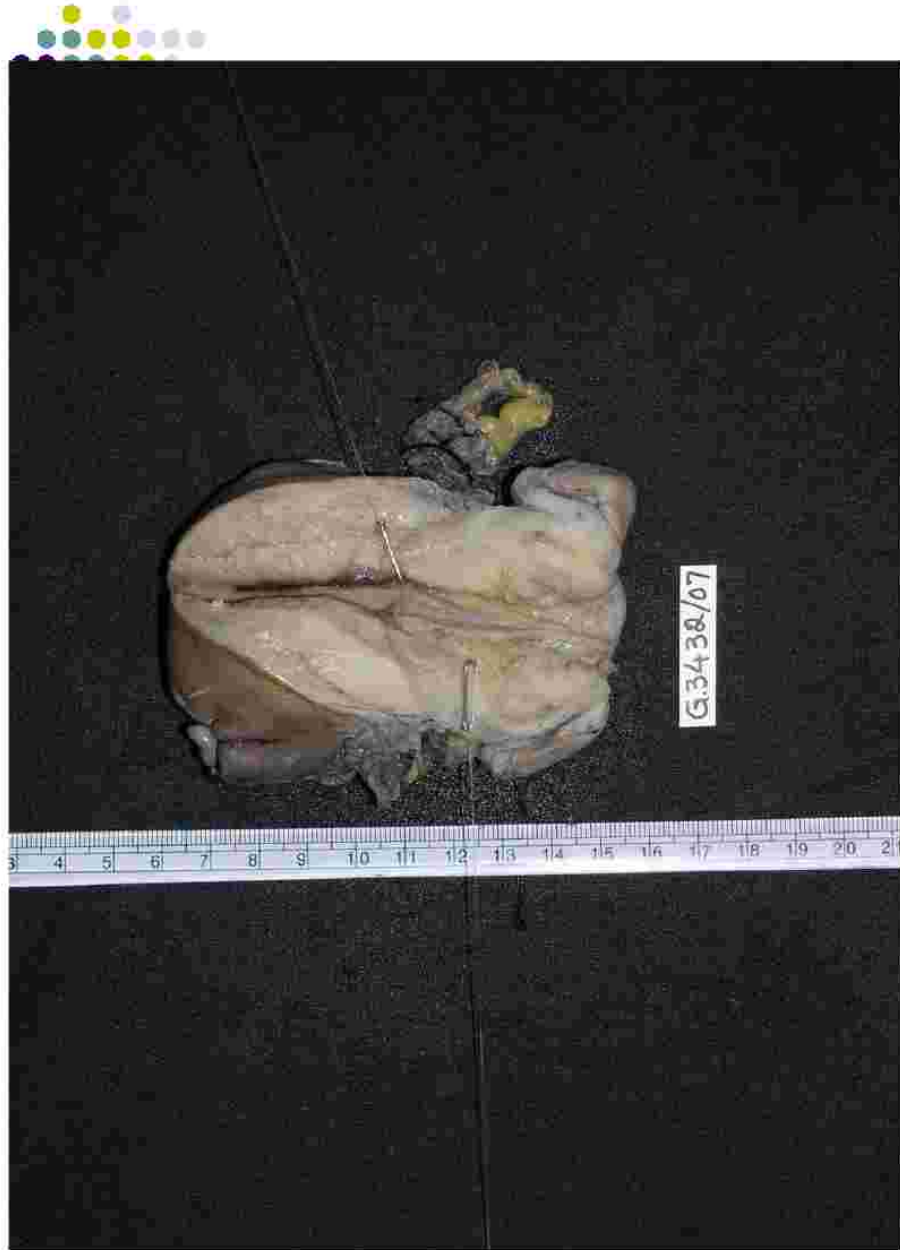

- ❖ **Stage IIB, III and IVA**
  - **Radiation therapy**- the treatment of choice
  - For locally advanced cervical cancer- use of cisplatin-based chemotherapy in combination with radiation.
- ❖ **Stage IVB and recurrent cancer**
  - **Chemotherapy**- single agent cisplatin or combined use of cisplatin and topotecan
  - **Palliative radiation/ Total pelvic exenteration** may be considered.

## Prognosis of cervical cancer





- Stage I cancer is confined to the cervix and has a 5-year-survival of 80-90%.
- Stage II cancer extends beyond the cervix and has a 5-year-survival of 50-65%.
- Stage III cancer extends to the pelvic wall and has a 5-year-survival of 25-35%.
- Stage IV cancer extends beyond the pelvic area and has a 5-year-survival of 0-15%.

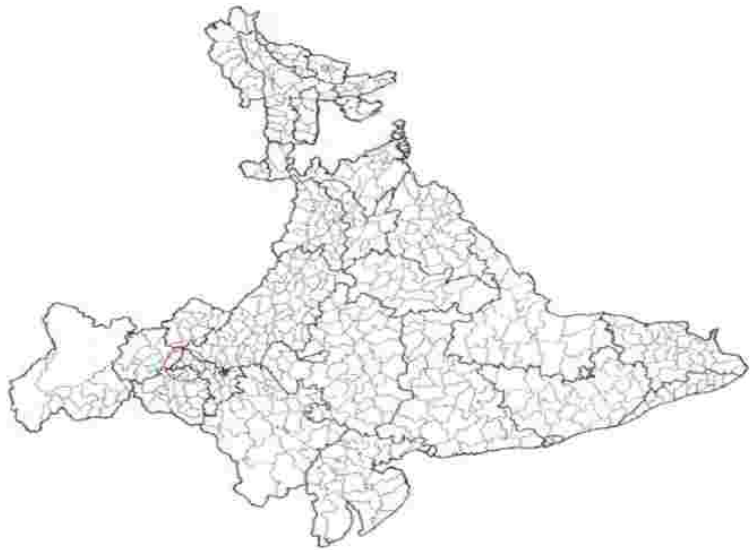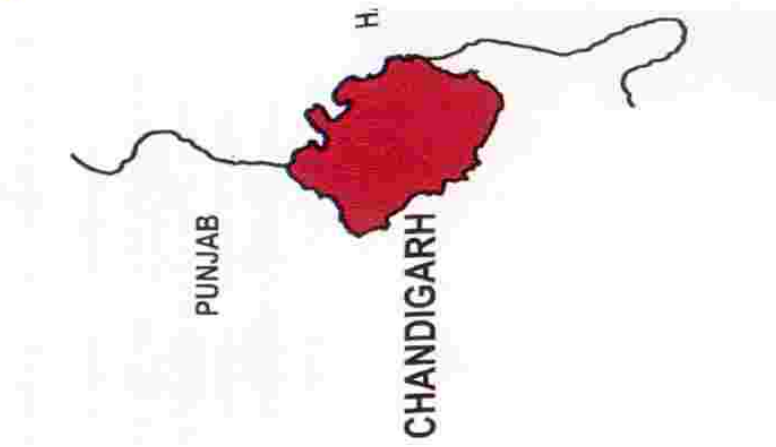


G.3438/07











# Pap Smear Reporting format



- SLIDE No. \_\_\_\_\_ I.D. No. \_\_\_\_\_ PAP SMEAR NO.- \_\_\_\_\_
  - SATISFACTORY FOR INTERPRETATION / UNSATISFACTORY (STATE REASON)
  - **NO EVIDENCE OF EPITHELIAL ABNORMALITY**
  - **EPITHELIAL ABNORMALITY PRESENT**
  - BENIGN CELLULAR CHANGES
    - INFECTION: T.V. / CANDIDA / COCCOBACILLI / HSV / OTHERS
    - ATROPHY
    - REPAIR
    - RADIATION
    - IUCD EFFECT
  - **EPITHELIAL ABNORMALITY**
  - **SQUAMOUS CELLS:**
    - ASC-US
    - ASC-HSIL CANNOT BE EXCLUDED
    - LSIL (WITH OR WITHOUT HPV ASSOCIATED CHANGES)
    - HSIL
    - SQUAMOUS CELL CARCINOMA - ? INVASIVE / INVASIVE
  - **GLANDULAR CELLS**
    - Endometrial Cells, Cytologically Benign Post-Menopausal Woman
    - AGUS
    - ADENOCARCINOMA : ENDOCERVICAL / ENDOMETRIAL / OTHERS
  - CYTODIAGNOSIS:
  - RECOMMENDATION: TREAT AND REPEAT / FOLLOW-UP SMEAR AFTER 4-6 MONTHS / BIOPSY CONFIRMATION
  - DATE: \_\_\_\_\_
  - \_\_\_\_\_
- CYTOSCREENER  
CYTOPATHOLOGIST



- **Solid nests of tumor cells with glassy, eosinophilic cytoplasm**
- **Large eosinophilic nuclei, prominent nucleoli**
- **Surrounded by heavy inflammatory infiltrate containing eosinophils;**
- **Frequent mitotic figures**
- **Pure cases have no histologic evidence of glandular or squamous differentiation, which is detectable only by EM**
- **Positive stains: PAS in cell wall**
- **EM: adenosquamous features**