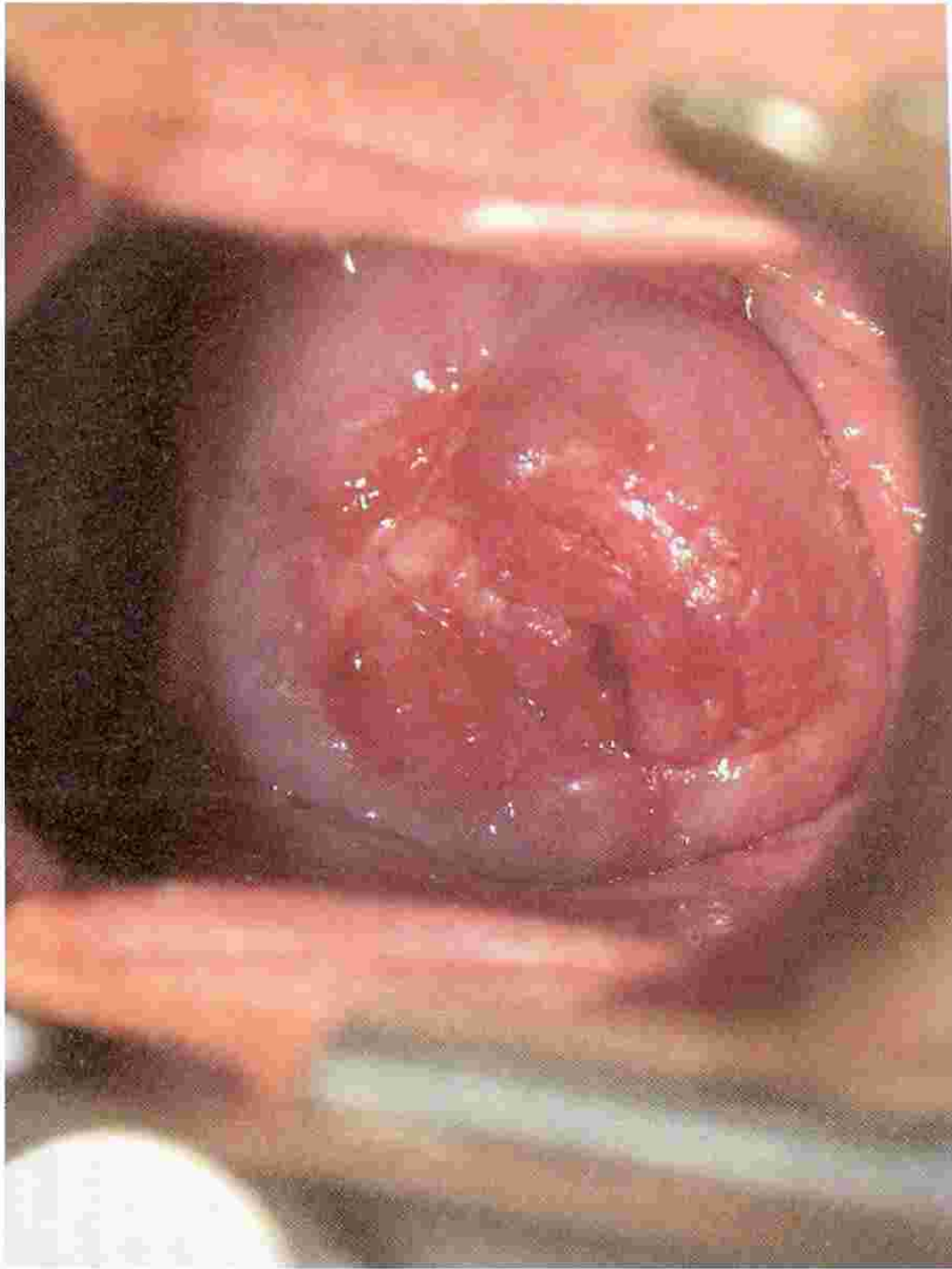


Role and Techniques of Surgery in Carcinoma Cervix

Dr Vanita Jain
Additional Professor
OBGYN
PGIMER, Chandigarh



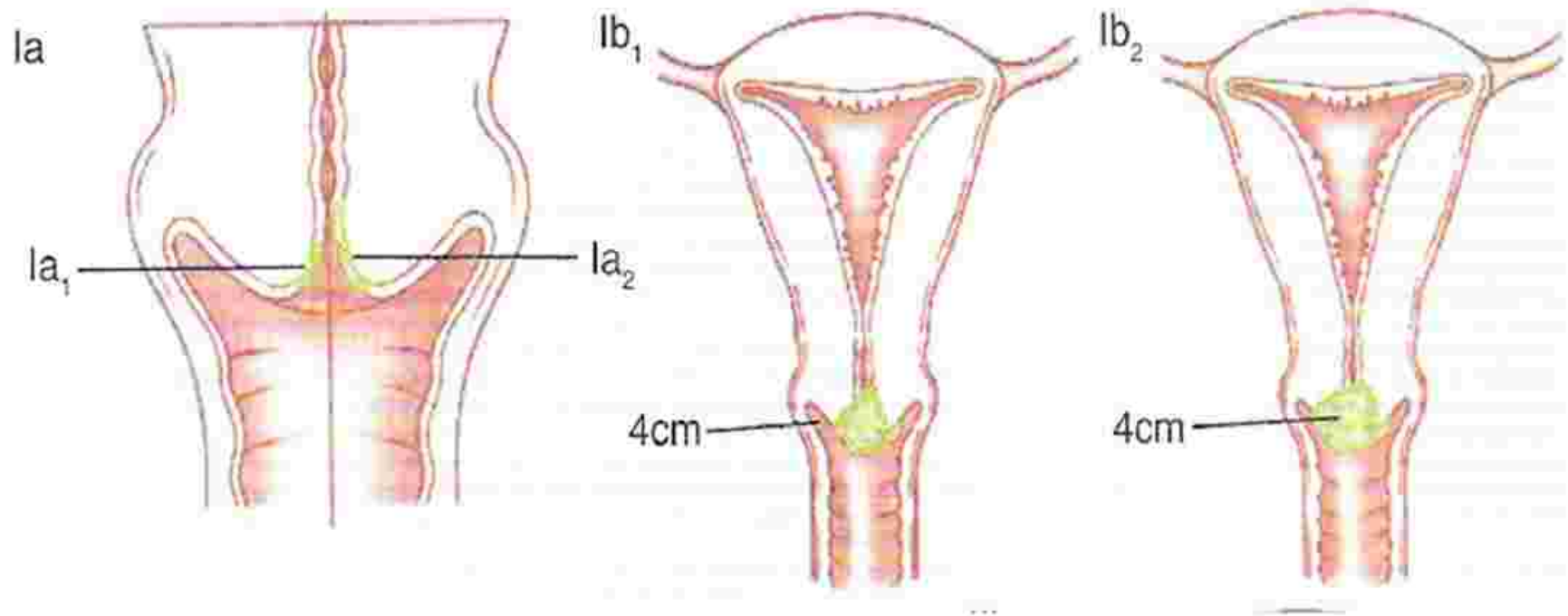


Points for Discussion

- Pattern of spread
- Therapeutic options
- Types of surgical procedures
- Stage wise treatment
- Special situations

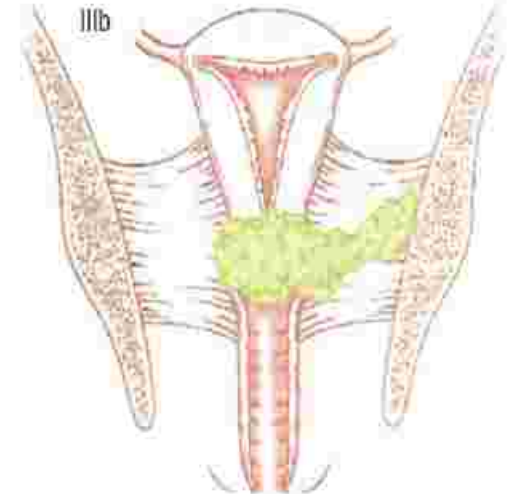
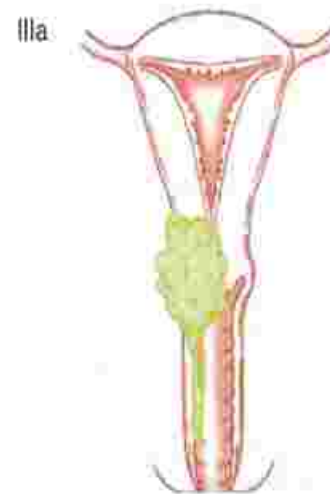
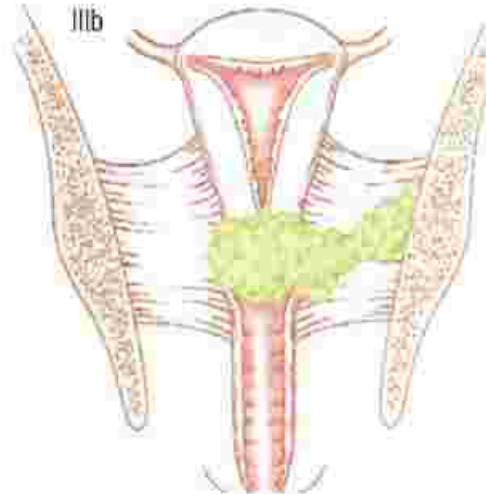
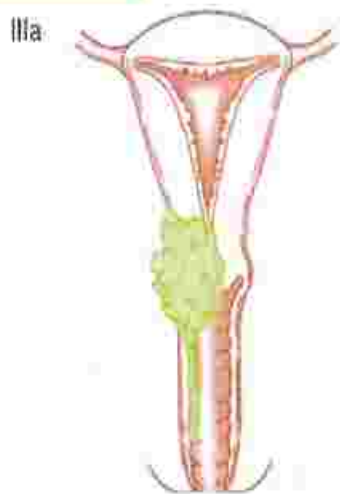Carcinoma cervix - Pattern of Spread

- Grows locally



Carcinoma cervix - Pattern of Spread

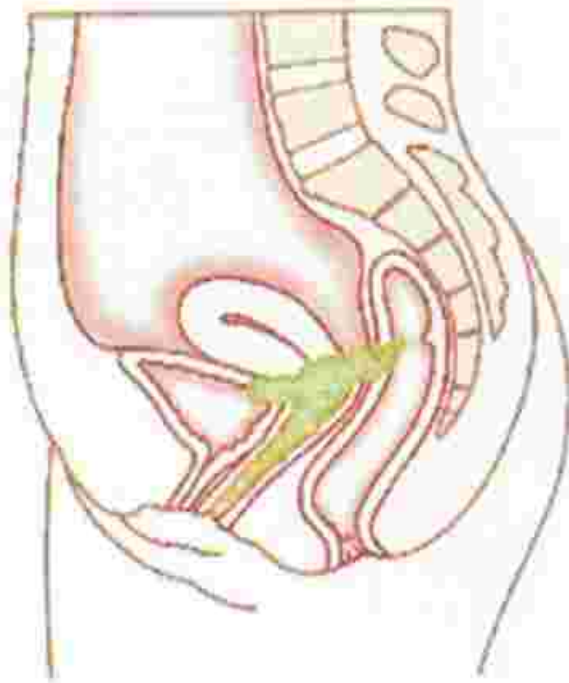
- Extends to paracervical tissues & pelvic organs & Spreads to regional lymph nodes



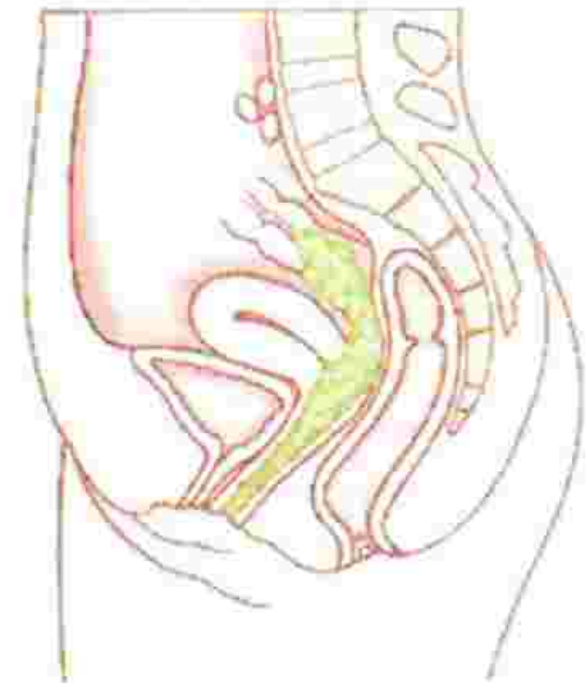
Carcinoma cervix - Pattern of Spread

- Metastasizes to distant structures later

IVa



IVb



Therapeutic modalities

- Surgery - limited to patients with stage I-IIa disease
- Radiotherapy - can be used in all stages of disease
- Chemotherapy
- Chemoradiation

Principles of treatment

- Both the primary lesion and the potential sites of spread should be evaluated and treated
- Optimal therapy consists of radiation or surgery ALONE - Morbidity is higher when both are combined
- Primary therapy should avoid planned use of both surgery & radiation



Types of surgical procedures



Surgical procedures in Carcinoma Cervix

- Fertility sparing surgeries
 - Conization
 - Trachelectomy
- Radical hysterectomy
- Laparoscopic assisted radical vaginal hysterectomy
- lymphadenectomy
- Staging lymphadenectomy
- Exentration
- Oophoropexy

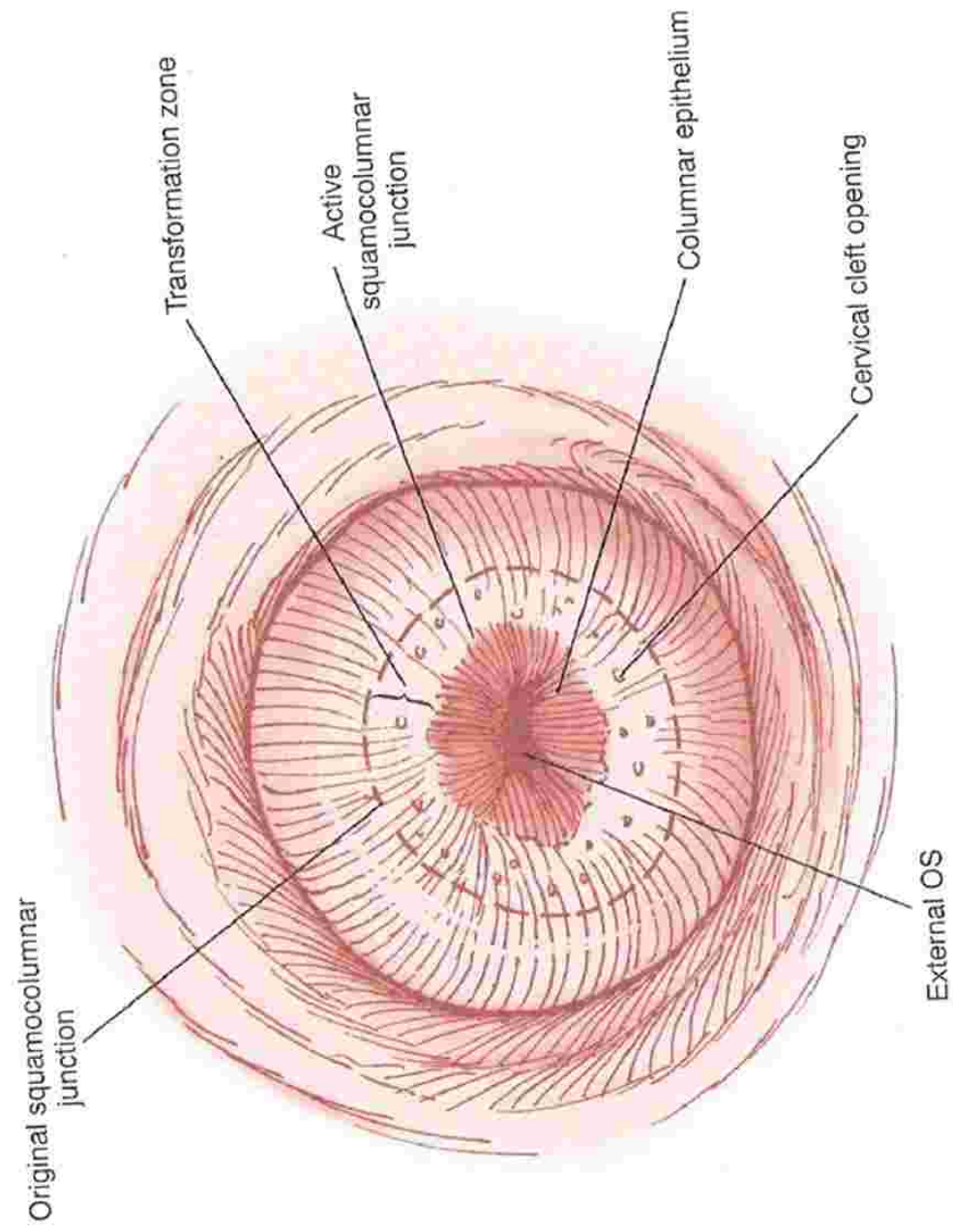


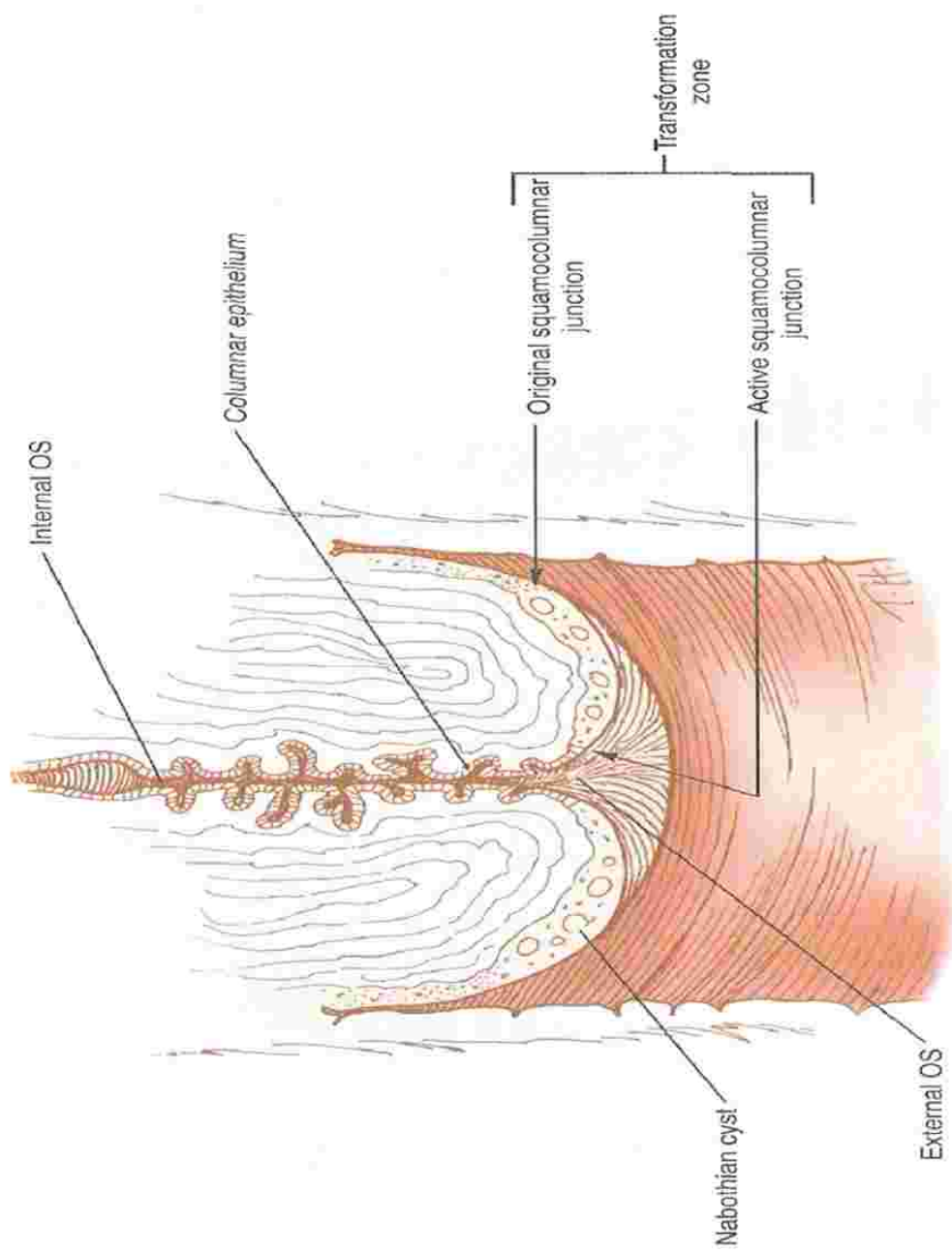
Conization



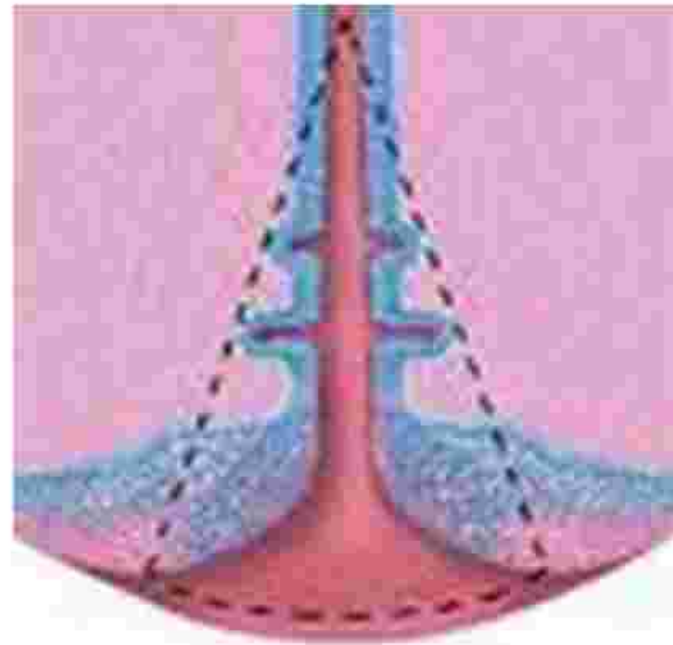
Conization

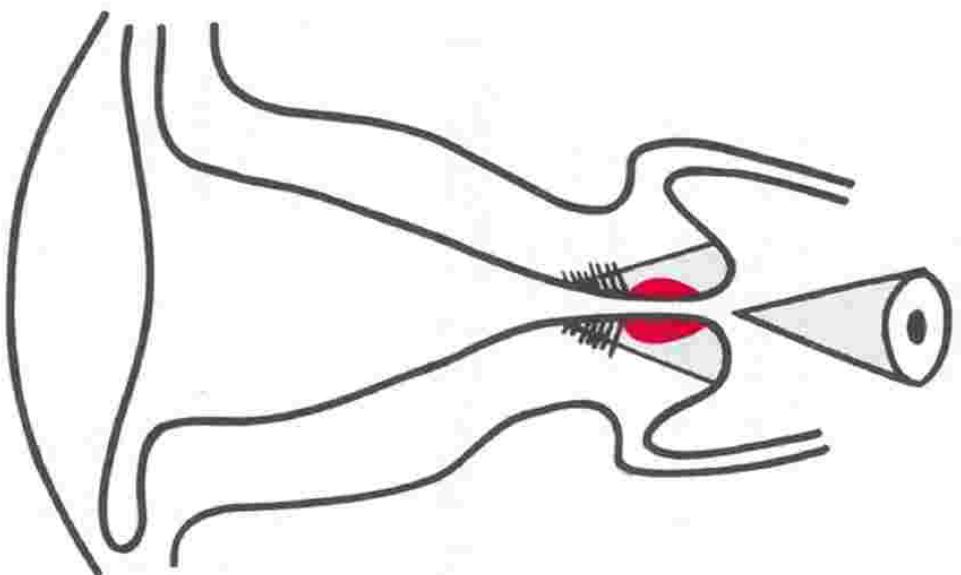
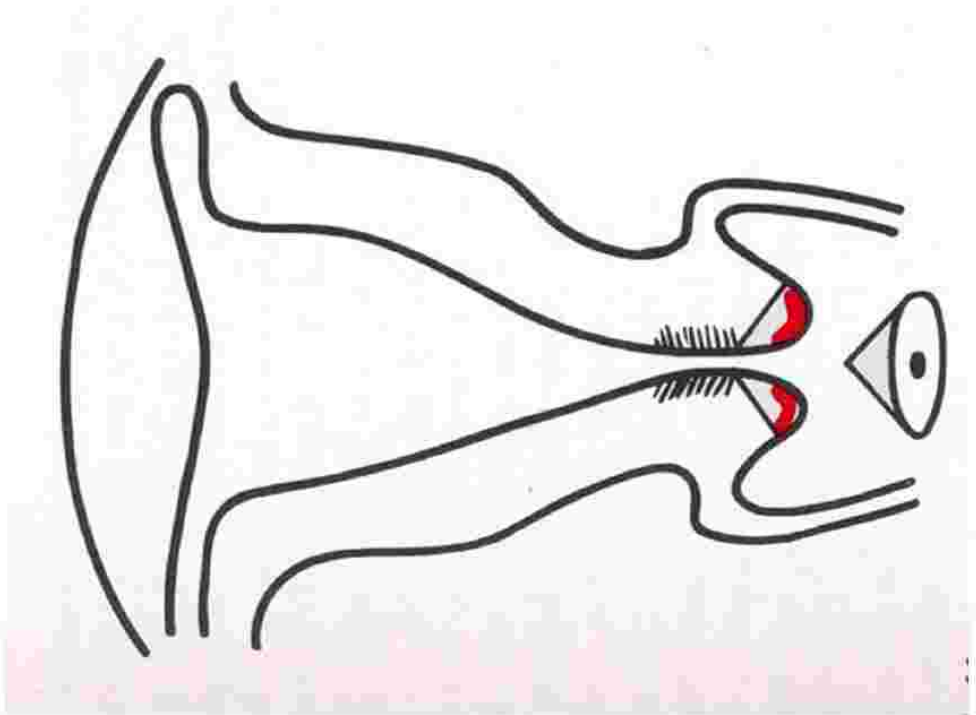
- Removes the cervical lesion, the transformation zone & the endocervical canal in the shape of a cone along with endocervical curettage
- Is both diagnostic & therapeutic

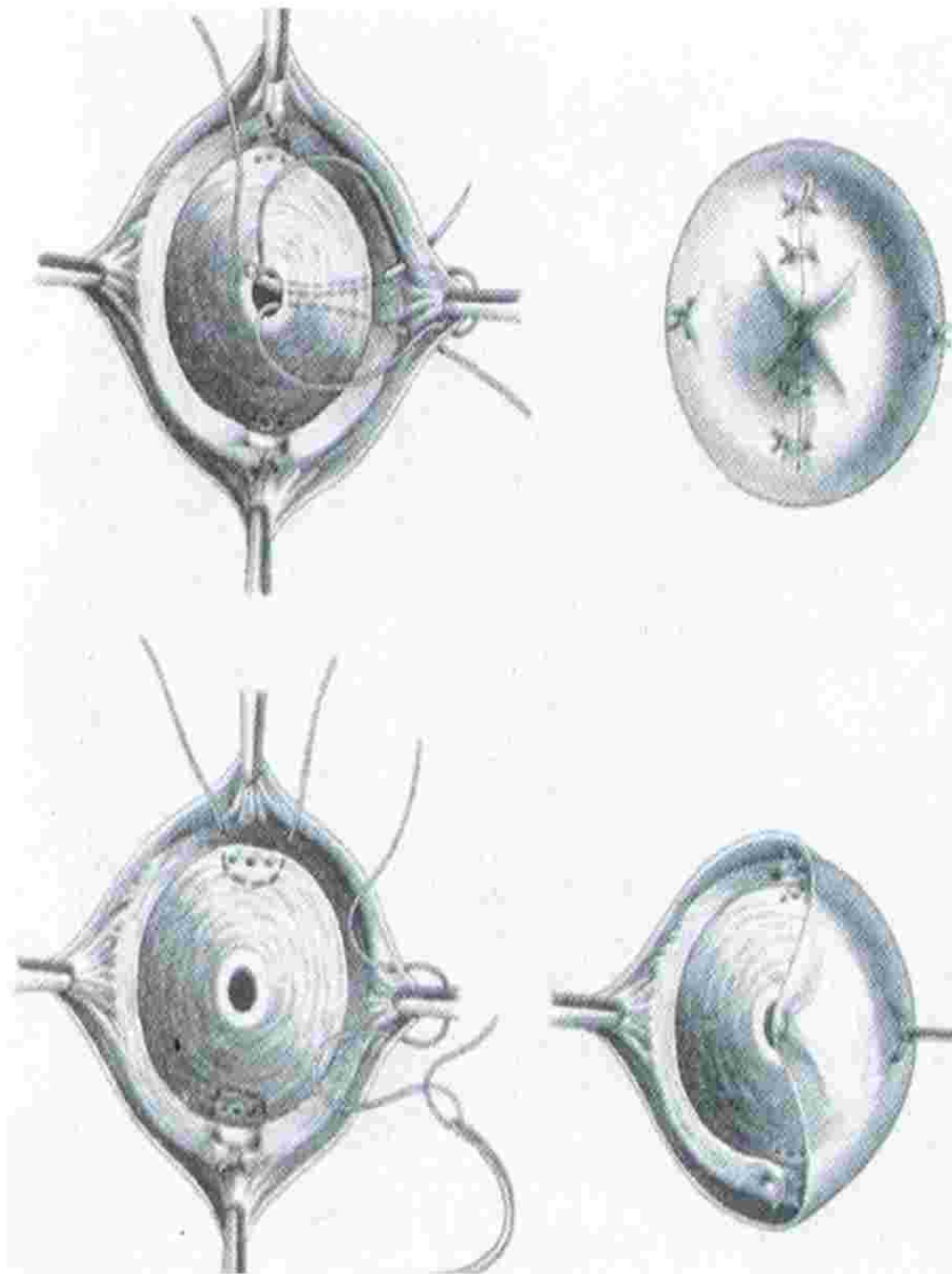




Conization







Conization

- Presence of dysplasia either at the endocervical conization margin or in the endocervical curettings is a strong predictor of residual invasive disease
- Residual invasive disease
 - 4 % when both are negative
 - 33% when both are positive
 - 22 % with positive endocervical conization margin
- Repeat conization should be performed to exclude more deeply invasive residual disease.

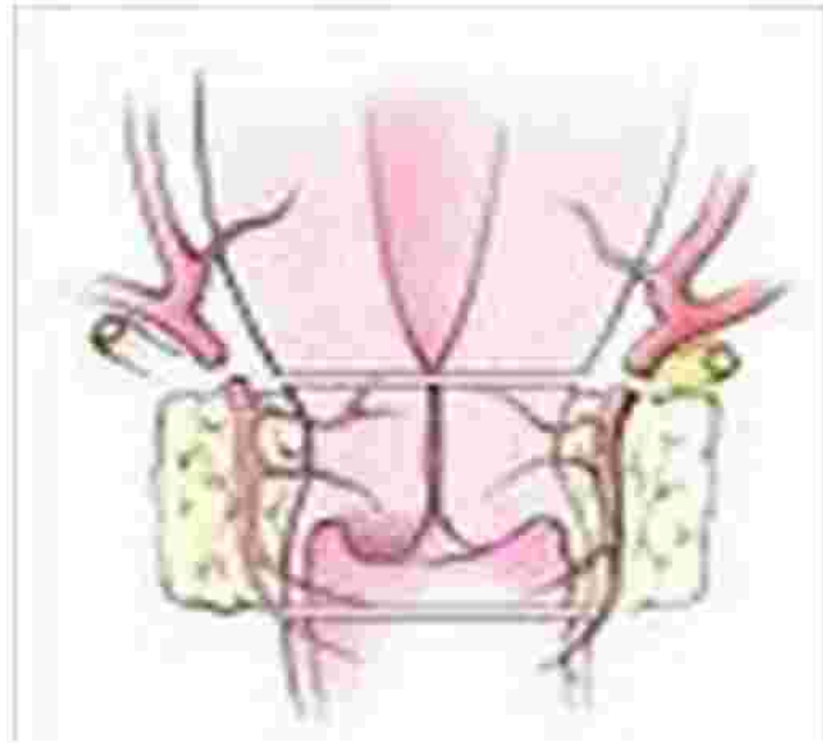
A large green shape on the left side of the slide, featuring a white semi-circular cutout. A dark blue horizontal bar with rounded ends extends from the bottom right of the green shape towards the right edge of the slide.

Radical trachelectomy

Radical trachelectomy

- The cervix and parametria are resected with placement of a cerclage so that the uterus can be preserved with a competent vaginal-uterine junction.
- Radical trachelectomy can be performed transvaginally or transabdominally with lymphadenectomy.

Radical trachelectomy



Radical trachelectomy

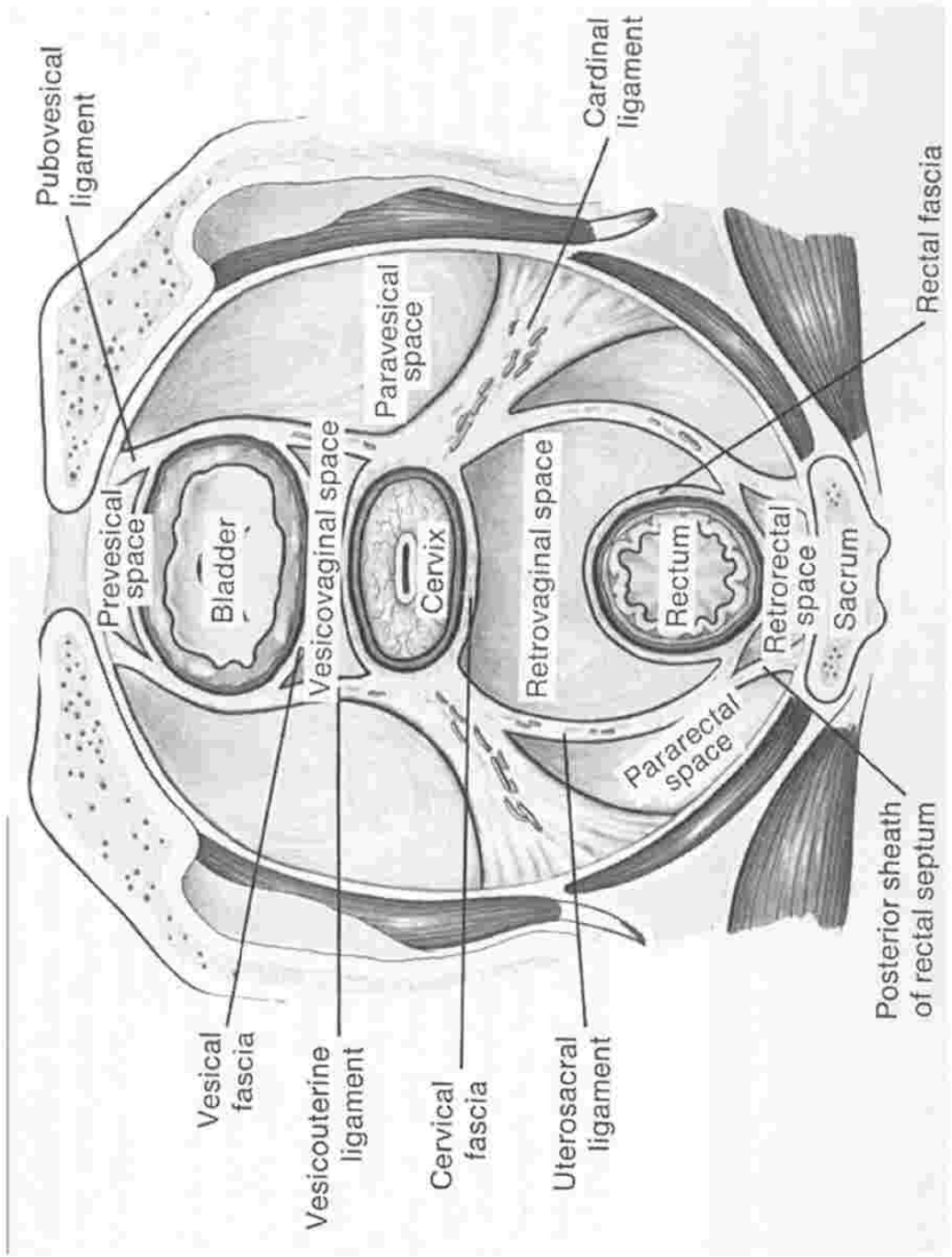
- **Selection criteria**

- Lesion size < 2 cm
- Absence of overt LN metastases
- Absence of vascular / lymphatic space involvement



Radical hysterectomy





Radical hysterectomy

- Refers to the excision of the uterus en bloc with the parametrium (i.e., round, broad, cardinal, and uterosacral ligaments) and the upper one-third to one-half of the vagina,

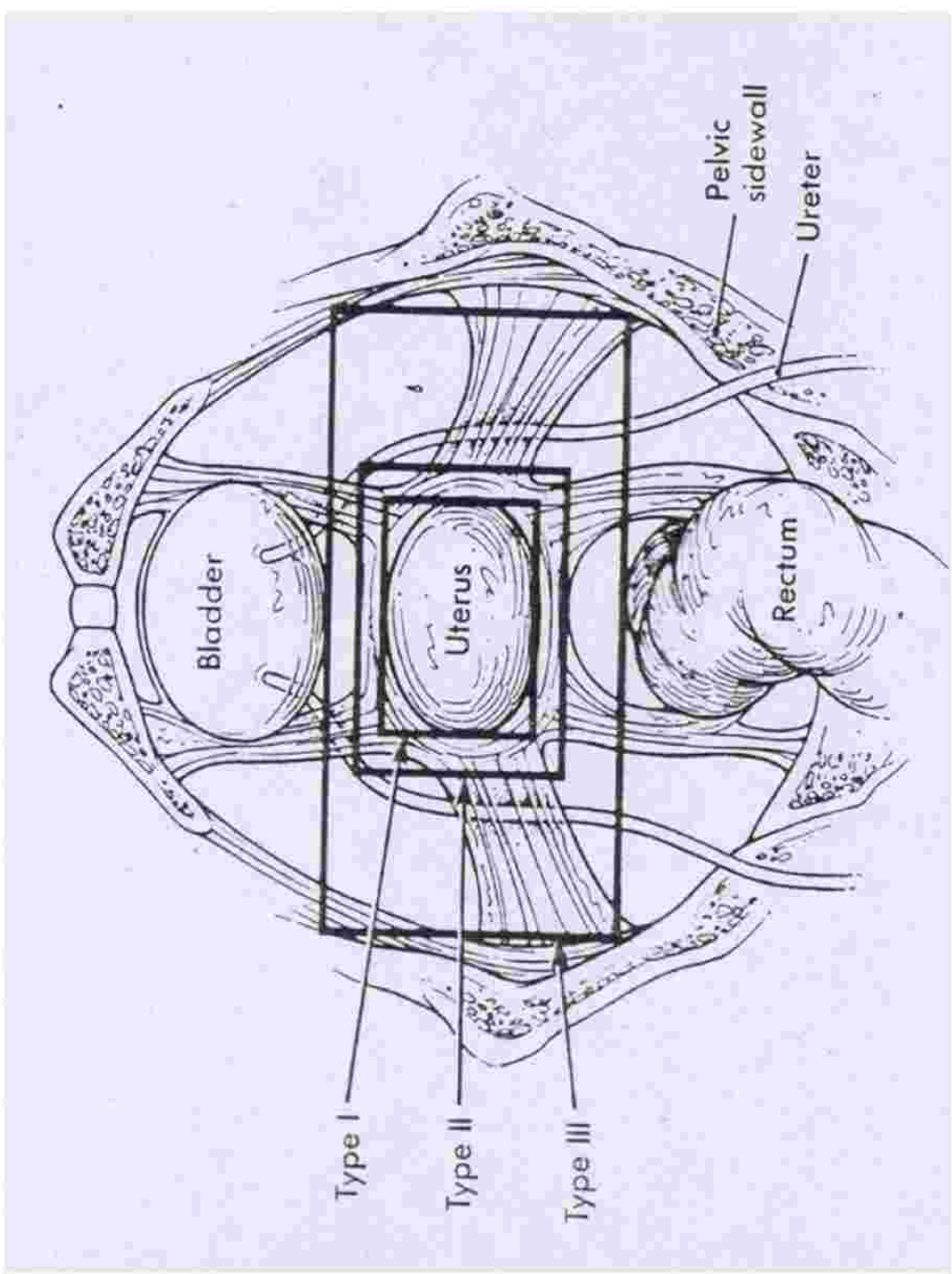
Radical hysterectomy

- Inspection of abdomen and pelvis
- Inspection and palpation of pelvic & para-aortic lymph nodes
- Any suspicion of disease-frozen section to be done
- No gross evidence of metastatic disease-surgery begun
- Metastatic disease identified- abandon surgery

Types of radical hysterectomy

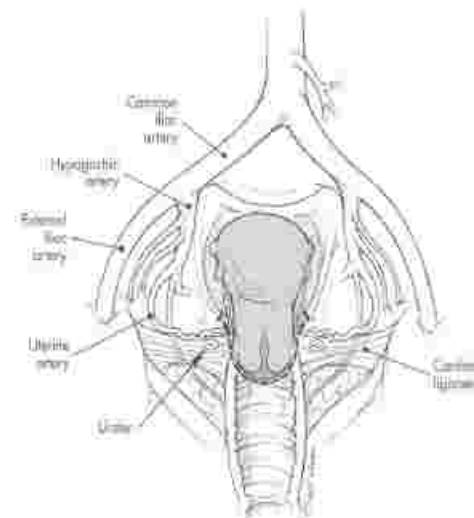
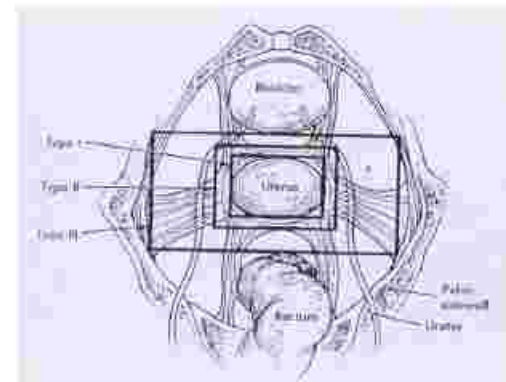
Piver-Rutledge

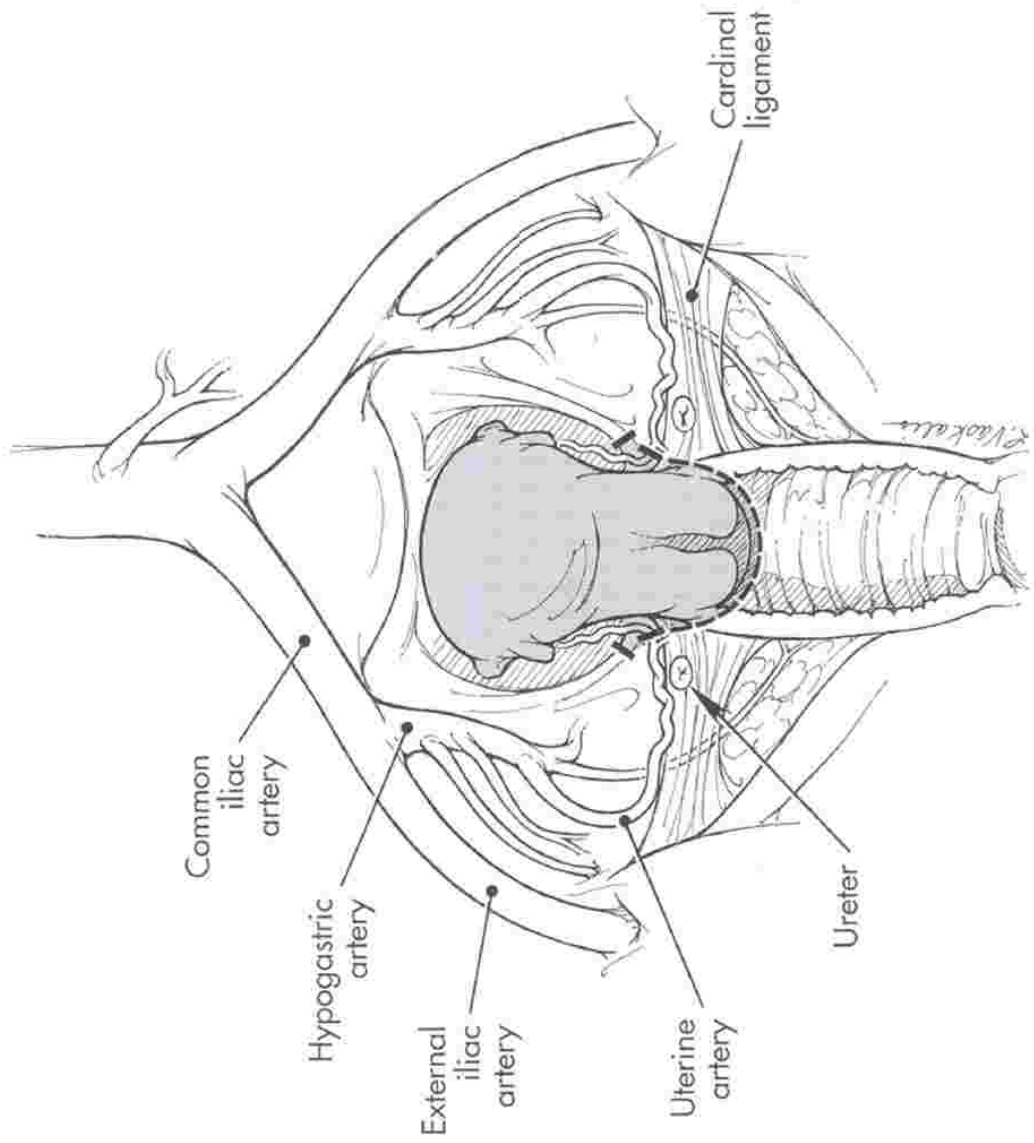




Type I radical hysterectomy

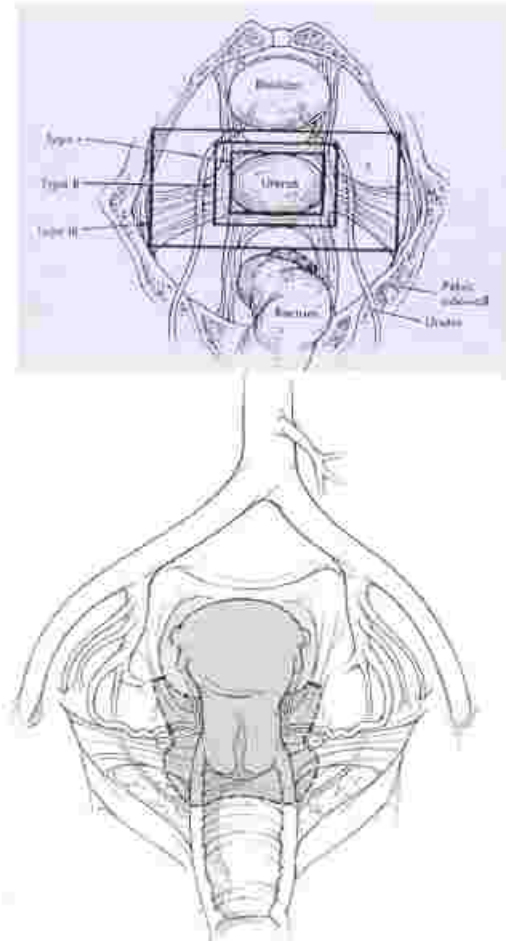
- Extrafascial hysterectomy. The fascia of the cervix and lower uterine segment, which is rich in lymphatic, is removed with the uterus

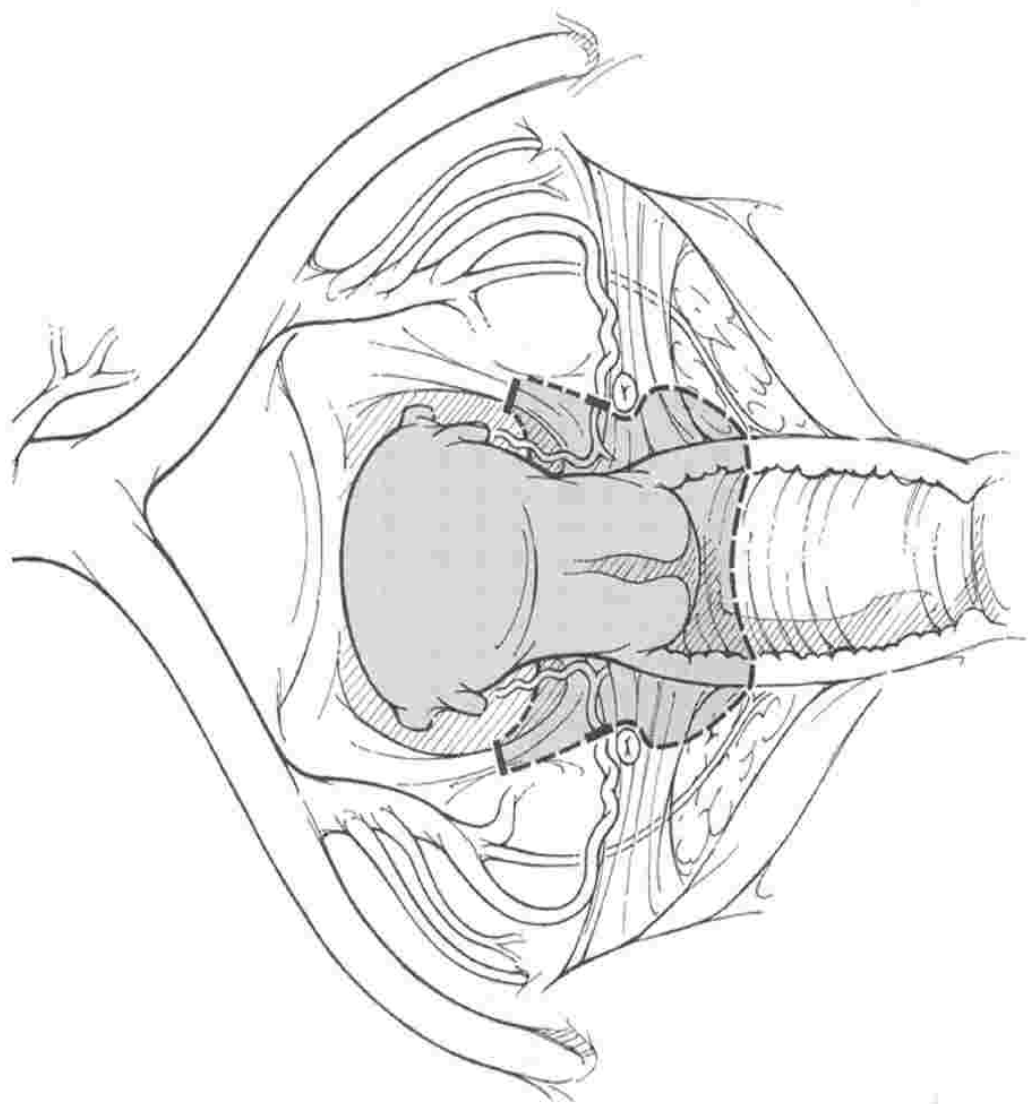




Type II radical hysterectomy

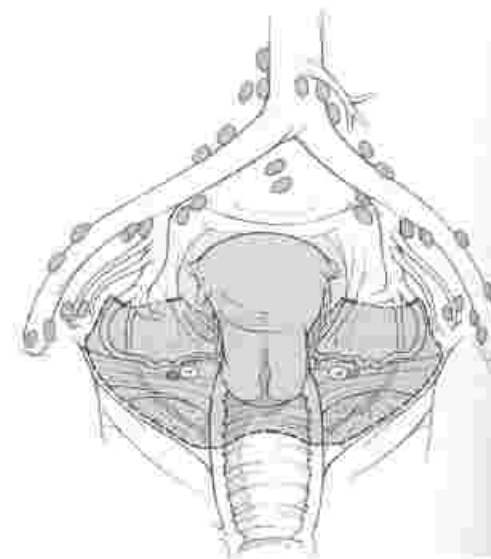
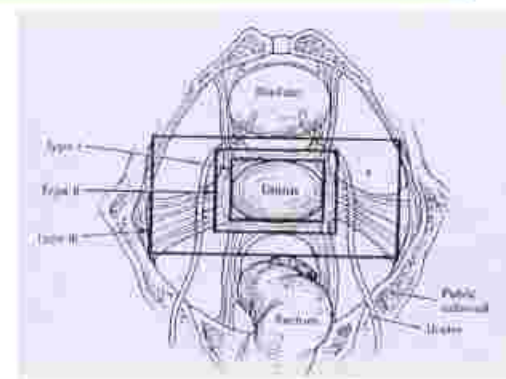
- The uterine artery is ligated where it crosses over the ureter and the uterosacral and cardinal ligaments are divided midway towards their attachment to the sacrum and pelvic sidewall, respectively. The upper one-third of the vagina is resected.

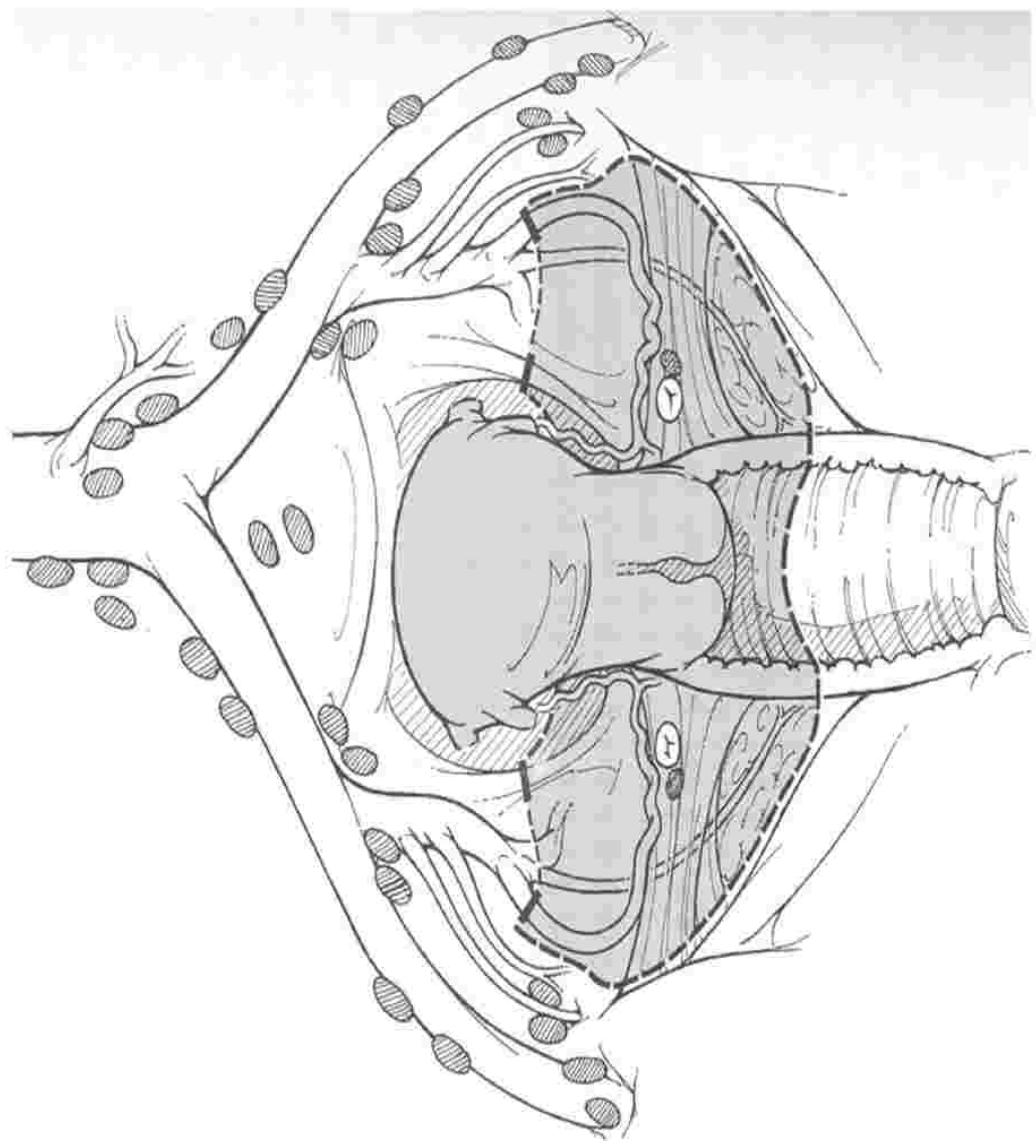




Type III radical hysterectomy

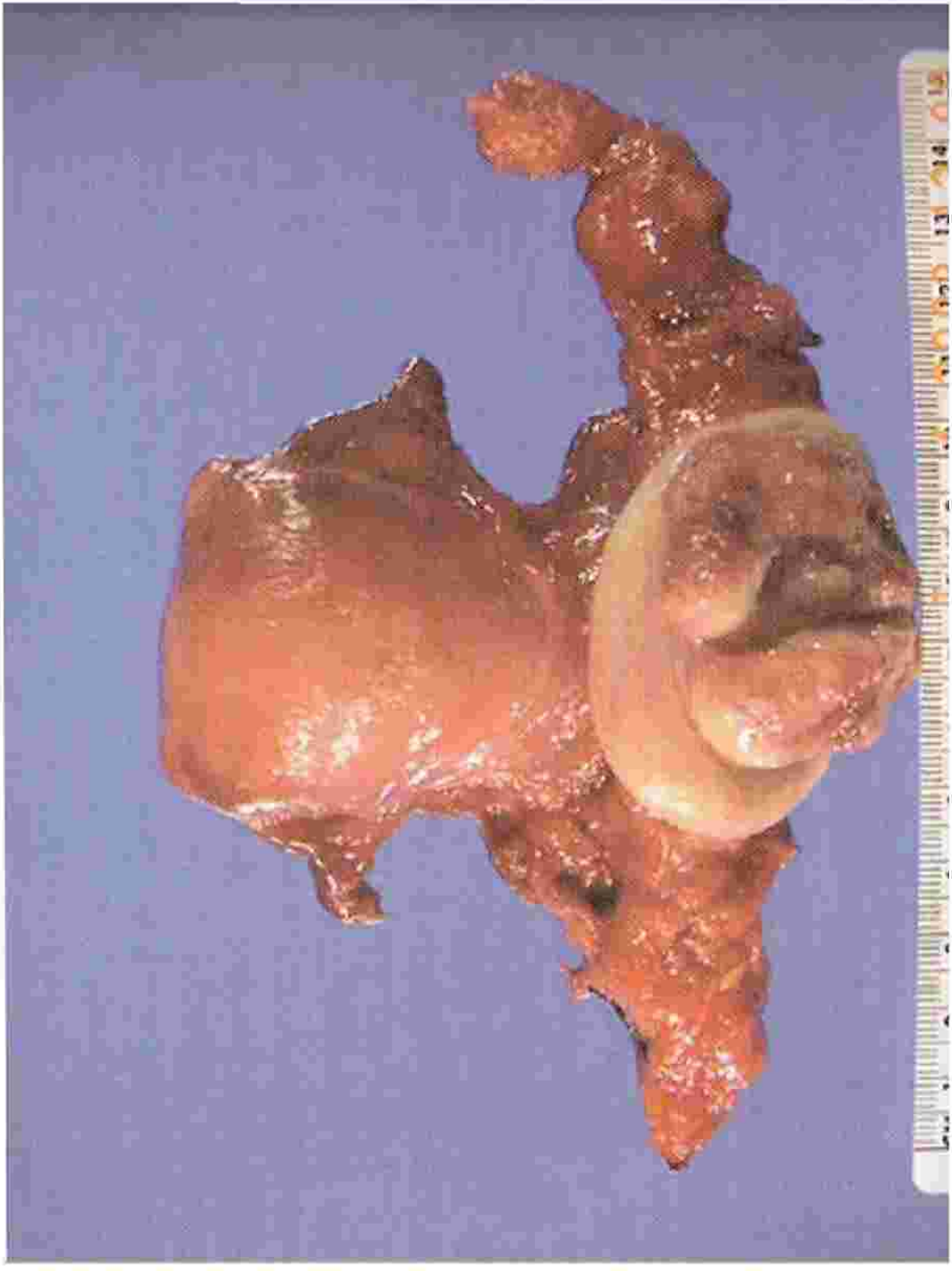
- The uterine artery is ligated at its origin from the superior vesical or internal iliac artery. Uterosacral and cardinal ligaments are resected at their attachments to the sacrum and pelvic sidewall. The upper one-half of the vagina is resected.





Types of radical hysterectomy

- IV - The ureter is completely dissected from the vesicouterine ligament, the superior vesical artery is sacrificed, and three-fourths of the vagina is resected
- V - There is additional resection of a portion of the bladder or distal ureter with ureteral reimplantation into the bladder.



Type II Vs Type III Hysterectomy

- The therapeutic efficacy of a type II comparable to that of a type III but with lower morbidity
- The type II operation was associated with
 - Shorter mean operative time
 - Less late urologic morbidity
 - Similar recurrence rates & Cause-specific mortality
 - 5year OS & DFS
- Type II procedure appears preferable as long as appropriate tumor clearance can be achieved

Laparoscopy-assisted radical vaginal hysterectomy (LARVH)



Laparoscopy-assisted radical vaginal hysterectomy (LARVH)

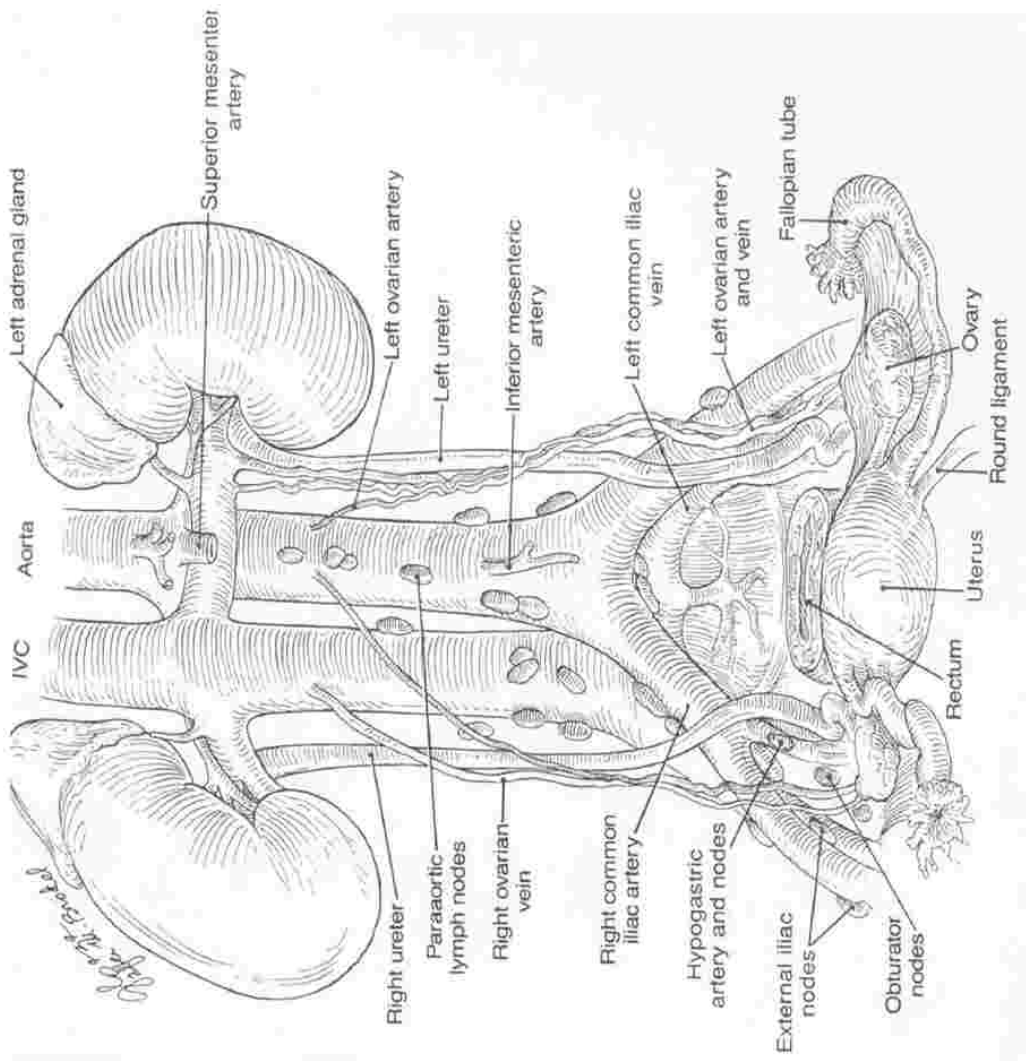
- **Procedure :**
 - laparoscopic visualization of the abdominal cavity to exclude macroscopic disease
 - Laparoscopic lymphadenectomy
 - Radical vaginal hysterectomy (type II or III)
- **Advantages :**
 - Less blood loss
 - Better cosmetic results
 - Faster recovery, Shorter hospitalization
- **Complications**
 - Similar to those seen with abdominal surgery



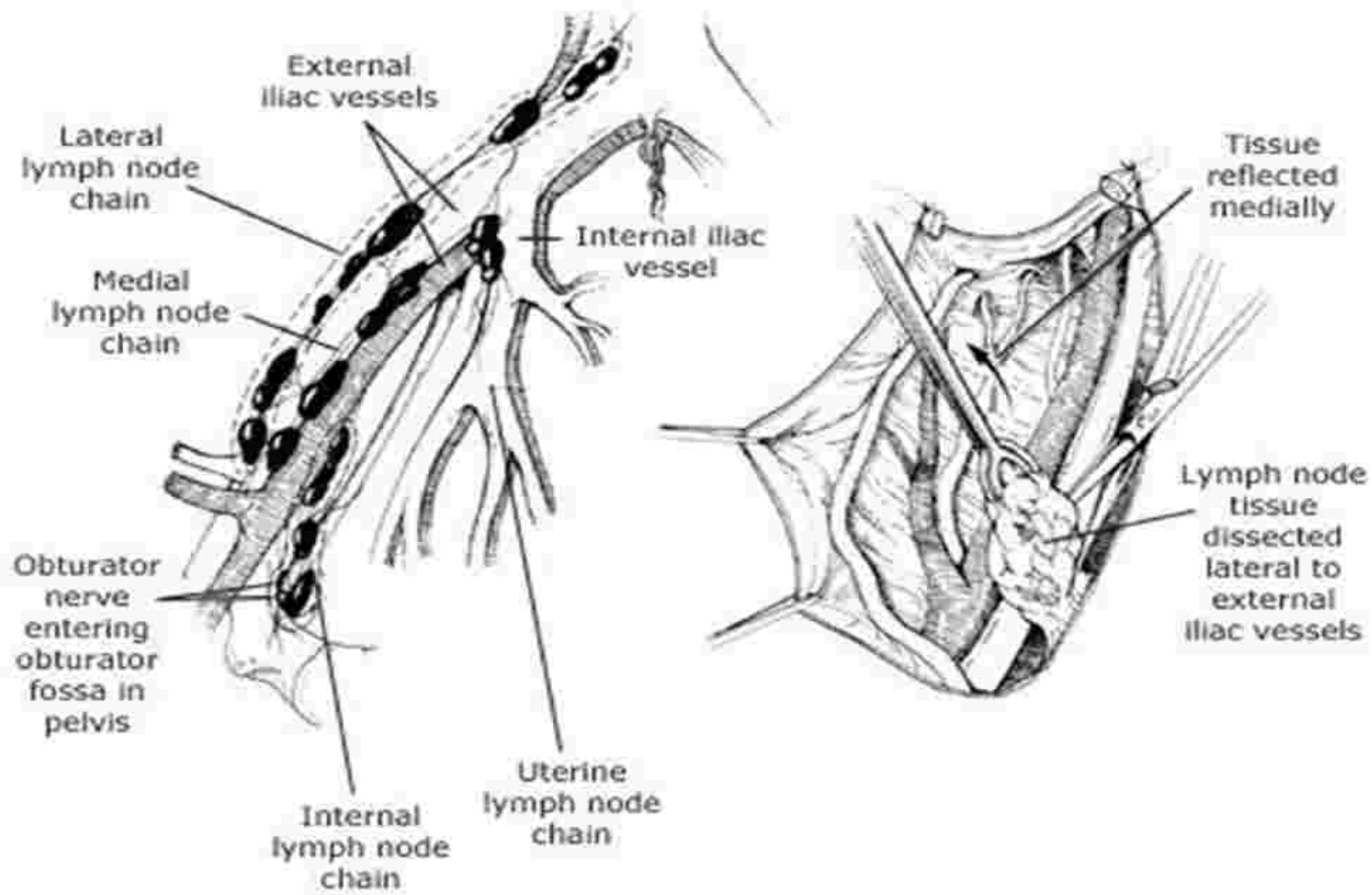
Lymphadenectomy

Nodal stations

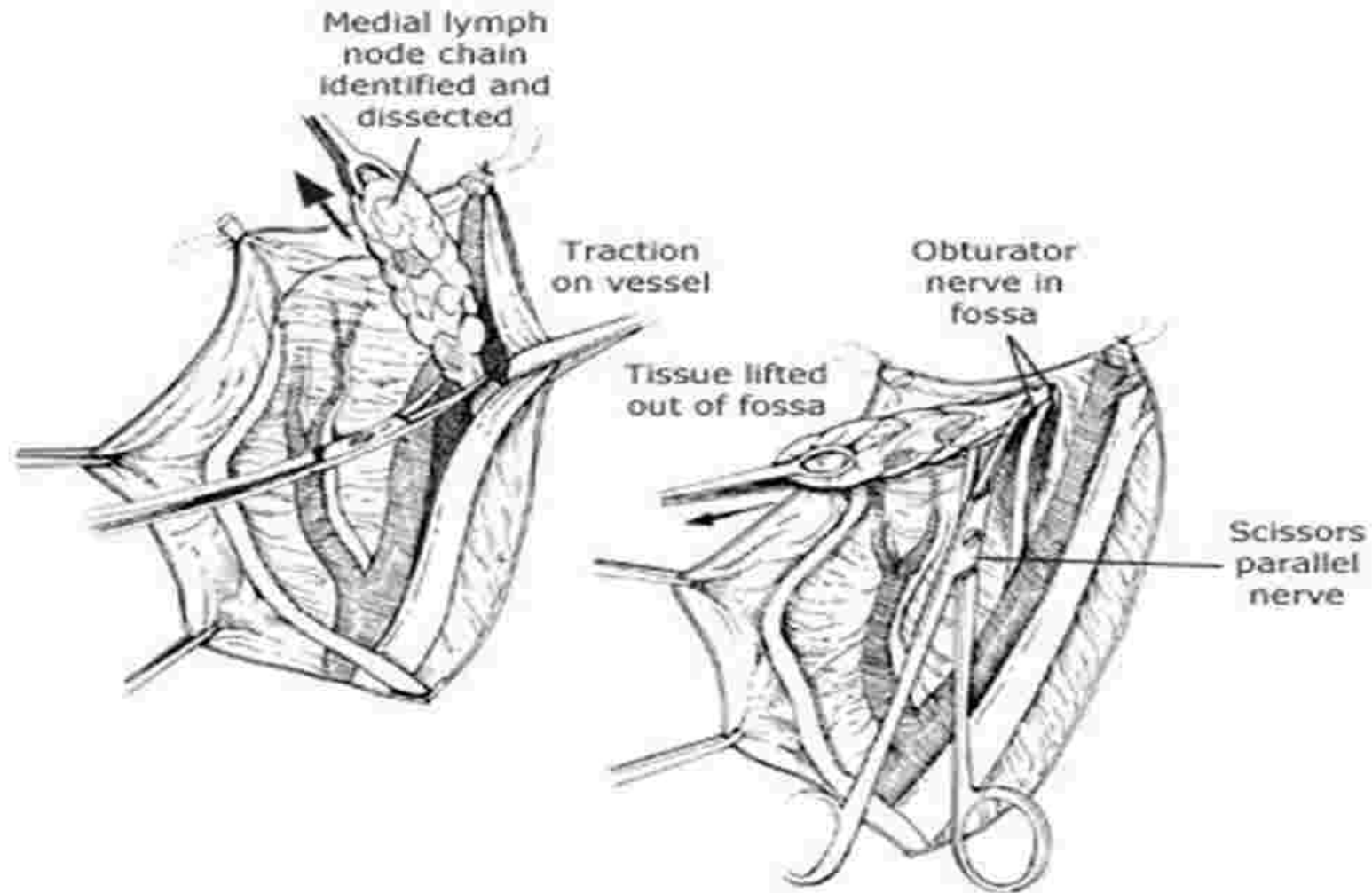
- First station-Parametrial, internal iliac, external iliac, presacral, common iliac
- Second station- Para-aortic nodes



Lymphadenectomy



Lymphadenectomy



Sentinel node biopsy

- Hypothesis- tumor cells colonize one or a few lymph nodes before involving other nodes & their status accurately predicts the status of the remaining regional LNs.
- Procedure-Peritumoral injection of Tc-99 and/or a vital blue dye permits identification
- Reliability for clinical use - not yet established
- Status - investigational

The slide features a large green shape on the left side, resembling a stylized letter 'E' with a rounded top-left corner. A white semi-circular cutout is positioned within the upper part of this shape. The text 'Staging lymphadenectomy' is centered within this white area. A dark blue horizontal bar with rounded ends extends from the right side of the green shape across the middle of the slide.

Staging lymphadenectomy

Staging lymphadenectomy

- Aim- To discover positive lymph nodes as clinical staging is imprecise
- Clinical stage fails to identify para-aortic involvement
 - Stage 1b - 7 %
 - Stage IIb - 18%
- Treatment plan changes in 40%

Staging lymphadenectomy

- **Arguments in favor**
 - Surgical staging is the most accurate method of determining lymph node involvement.
 - Therapeutic survival benefit of resecting bulky lymph nodes prior to chemo radiation
- **Arguments against**
 - Delay in the institution of primary chemoradiotherapy
 - Increased risk of morbidity (especially late bowel obstructions) with the combined modality approach.

Staging lymphadenectomy

- **Methods**

- Transperitoneal approach-radiotherapy induced bowel complications – 30%
- Extraperitoneal dissection-postradiotherapy bowel complications-<5%
- Laparoscopic lymphadenectomy

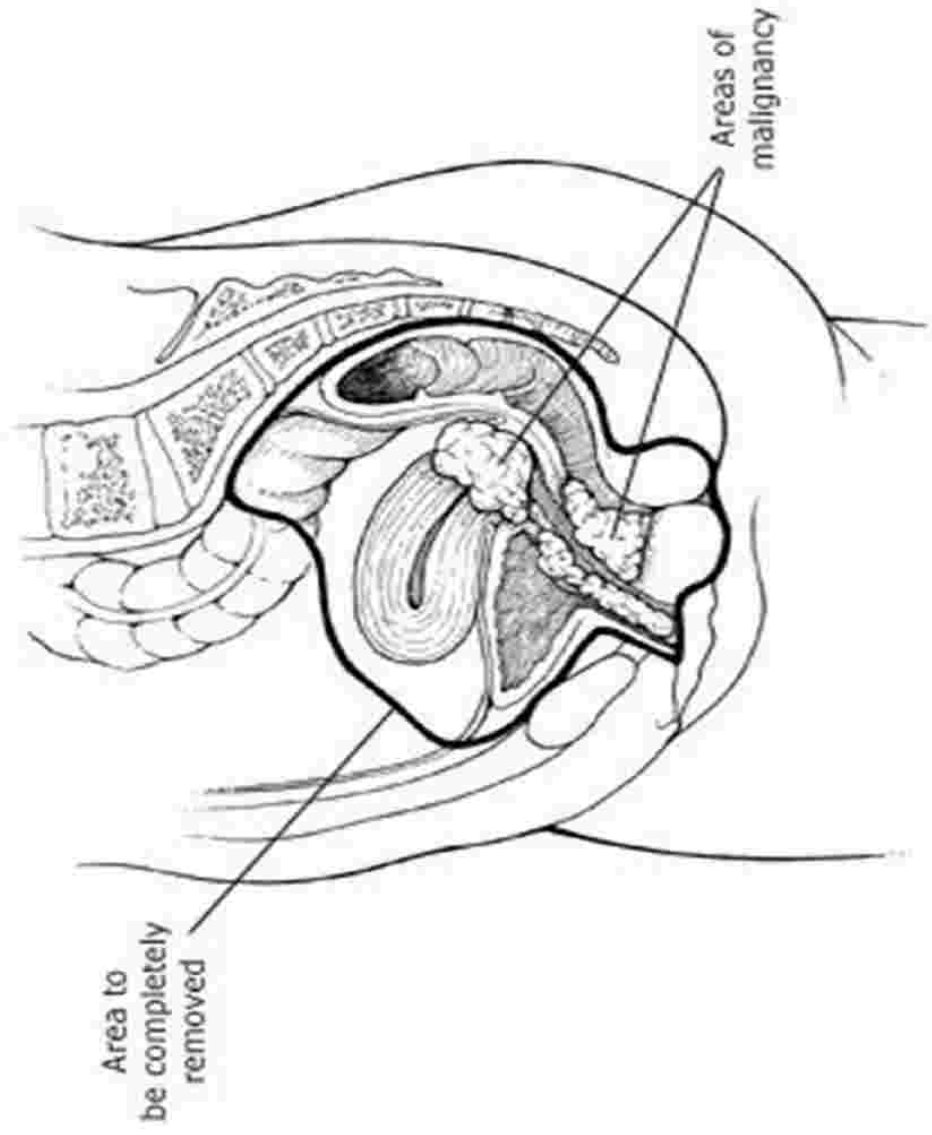


Exenteration

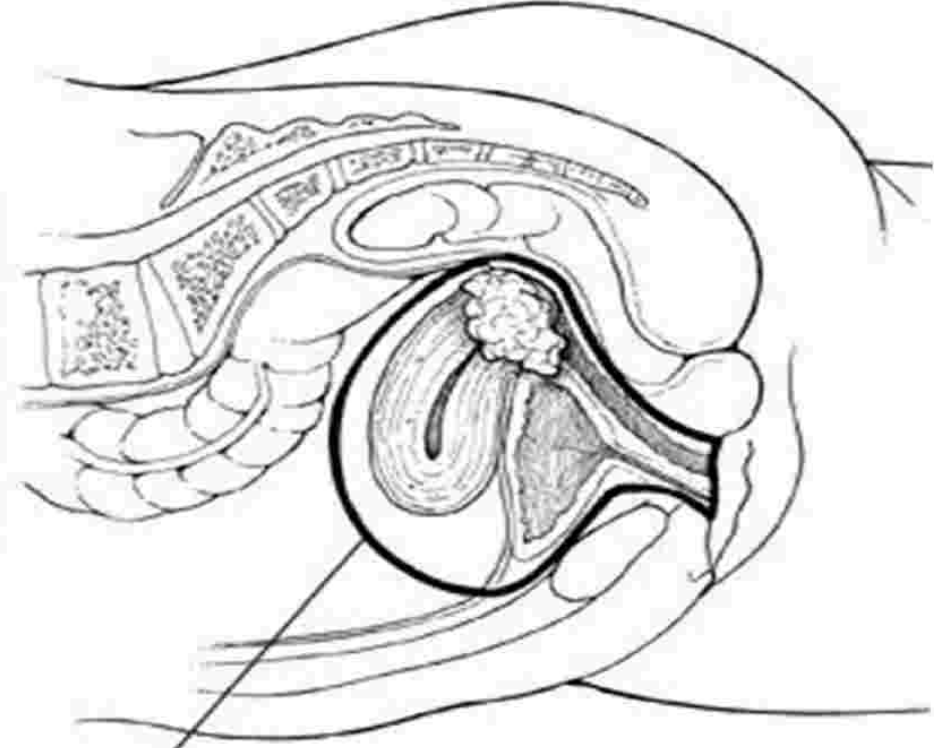
Exenteration

- An ultraradical surgical procedure consisting of an en bloc resection of the female reproductive organs, lower urinary tract, and a portion of the rectosigmoid.
- Indications
 - Recurrent or advanced gynecologic cancer
 - Extensive central pelvic disease that cannot be resected with a lesser procedure
 - Has received Radiation before
- Contraindications
 - Presence of distant metastasis - 50%
 - Unresectable or extrapelvic disease - 30-50%
 - Disease extending to pelvic side walls

Total exenteration with perineal phase



Anterior exenteration



**Area to be
eviscerated**

LEER

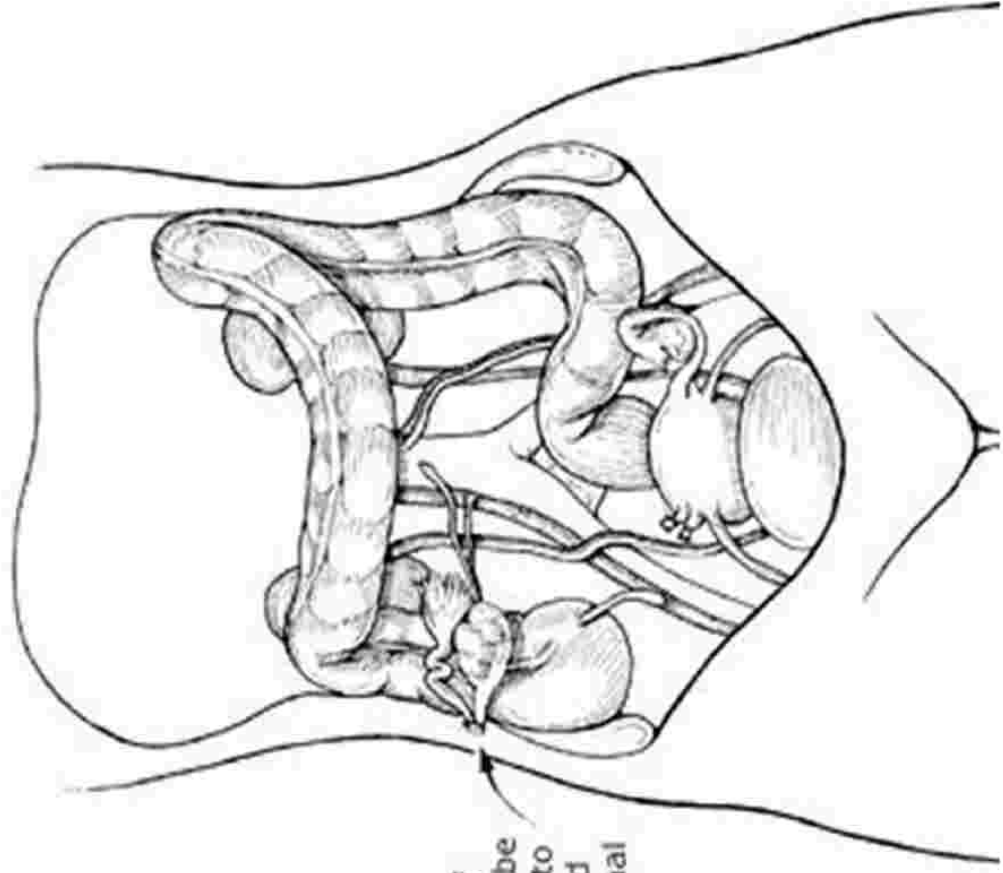
- Laterally extended endopelvic resection
- For recurrent disease involving pelvic side walls
- Extended lateral resection plane
- Internal iliac vessels, endopelvic part of obturator internus, coccygeus, iliococcygeus, pubococcygeus are removed
- Limited experience



OOPHOROPEXY

OOPHOROPEXY

- **Aim:** To shield the normal premenopausal ovary from the damaging effects of radiation
- **Procedure:** The ovaries and their vascular supply are brought out of the pelvis and sutured lateral and above the psoas muscle
- **Ovarian failure can result despite oophoropexy because of scatter radiation and surgically induced changes in ovarian blood supply & innervation**



Stump of fallopian tube and ovary to be sutured to abdominal wall

Stagewise Surgical treatment

A large green shape on the left side of the slide, with a white semi-circular cutout containing the title. A dark blue horizontal bar with rounded ends extends from the bottom of the green shape towards the right.

Lymph node metastasis

Stage	Pelvic LN(%)	Para-aortic (%)
Ia1	0.5	0
Ia2	4.8	<1
Ib	15.9	2.2
IIa	24.5	11
IIb	31.4	19
III	44.8	30
IVa	55	40

Stage Ia 1

- Incidence of pelvic node metastasis - <1%
- LVSI – Risk of nodal metastasis / central pelvic recurrence
- <3mm invasion & no LVSI – lymph node dissection not needed
- Choices – No LVSI
 - Fertility desired - conization
 - Fertility not desired – extrafascial hysterectomy
- Ia 1 cervical adenocarcinoma – expert pathological assessment

Stage Ia 2 & Ia 1 with LVSI

- Incidence of pelvic node metastasis – 3%
- 8%
- lymph node dissection needed
- Choices – lymphadenectomy +
 - Radical hysterectomy (Type II) if fertility not desired
 - Radical trachelectomy if fertility desired

Stage Ib1, nonbulky IIa

- **Radical hysterectomy (Type III) plus pelvic/para-aortic lymphadenectomy**

OR

- **Definitive radiation therapy (RT)**

Surgery Vs RT

	Surgery	Radiation
Survival	85%	85%
Complication	Fistula 1-2 %	Fistula 1-5%
Vagina	Shortened but lengthens	Fibrosis
Ovaries	Conserved	Destroyed
Chronic effects	Bl. Atony 3%	Fibrosis 6-8%
Mortality	1%	1%
applicability	< 65yrs, Healthy	All patients

Stage Ib1, nonbulky IIa

- The optimal choice depends upon
 - Patient's age Childbearing plans
 - Disease stage
 - Comorbidities
 - Histopathological review
 - Physician and patient preference.

Bulky stage Ib & IIa disease

- Options

- Primary chemoradiotherapy
 - Post RT hysterectomy
 - PreRT lymphadenectomy ?

OR

- Primary radical hysterectomy & lymphadenectomy followed by tailored RT
 - Undiagnosed, coexisting pelvic mass
 - Anatomic alterations making optimal RT difficult

Postchemoradiotherapy hysterectomy

- **The rationale**

- Many of the bulky tumors extend laterally beyond the tumoricidal isodose curve of the brachytherapy application
- They may contain hypoxic central areas, which do not respond well to RT.

- **Indications**

- No consensus
- Tumor size > 8 cm,
- A poor response to RT

Indications for adjuvant therapy

- **High-risk disease**

- Positive or close resection margins
- Positive lymph nodes
- Microscopic parametrial involvement

- **Intermediate-risk disease**

- Large tumor size (>4 cm) [51]
- Deep cervical stromal invasion (to the middle or deep one-third)
- Lymphovascular space invasion

Recurrent cervical cancer

- Treatment depends upon
 - Mode of primary therapy
 - Site of recurrence
- Central pelvic disease-Exentration
- Disease involving pelvic side walls-LEER
- Small volume disease limited to cervix-Type I/II hysterectomy

SPECIAL CIRCUMSTANCES

- Diagnosis and treatment during pregnancy
- Management of incidentally diagnosed cervical cancer after simple hysterectomy
- Carcinoma of the cervical stump

Diagnosis and treatment during pregnancy

- **Pap +ve for malignancy, Colposcopy & biopsy cannot rule out malignancy**
- **A combined procedure of conization and cerclage in second trimester.**

Treatment during pregnancy

- Stage I or IIA
 - Early pregnancy - radical hysterectomy and therapeutic lymphadenectomy with the fetus left in-situ unless the patient is unwilling to terminate the pregnancy
 - Pregnancy closer to fetal viability or patient unwilling to lose the baby may continue the pregnancy – Caesarean with radical hysterectomy and therapeutic lymphadenectomy

Mode of delivery

- **Microinvasive disease**
 - Vaginal delivery
 - Evaluate episiotomy site
 - Reevaluation and treatment six weeks postpartum
- **Early lesions**
 - A classical cesarean-radical hysterectomy with lymphadenectomy, after fetal pulmonary maturity is established.
- **Larger volume**
 - Classical cesarean delivery followed by RT

Incidentally diagnosed cancer after a simple hysterectomy

- Microinvasive disease : No additional therapy
- Invasive disease with no gross parametrial disease
 - Radical parametrectomy and upper vaginectomy with therapeutic lymphadenectomy
 - or
 - RT
- Extensive disease: RT

Carcinoma of the cervical stump

- **Early stage**
 - Radical trachelectomy with upper vaginectomy and therapeutic lymphadenectomy
 - Surgery is preferred over RT because the ability to deliver adequate doses of RT compromised in patients with a short cervical stump
- **Advanced disease - RT**

Conclusion

- **SURGERY**
 - **Best role, only option : Preinvasive disease**
 - **Definite role, alternate option : Early invasive disease**
 - **Controversial role : Bulky disease**
 - **Some role, only option : recurrent disease (RT failure)**

Carcinoma cervix is a preventable disease

Prevention is better than cure



THANK YOU