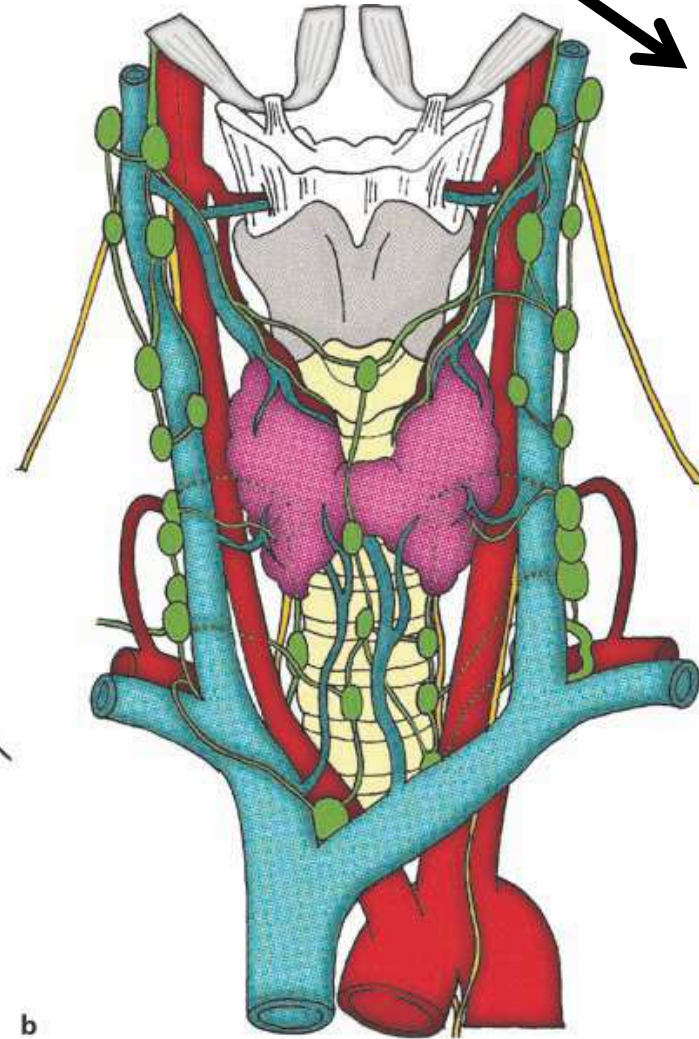
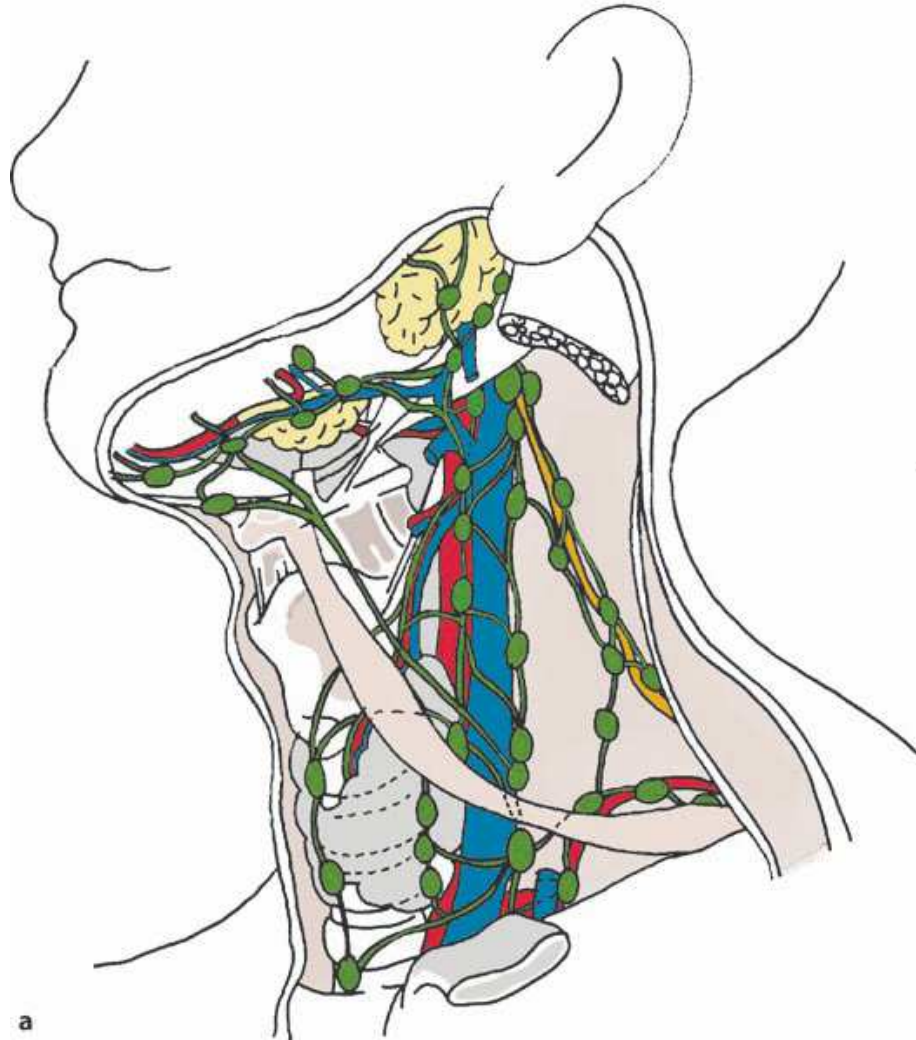


Management of Neck

N0

N+



Management of Neck

Not all the neck nodes are involved in all sites.

Fixed and Predictable Pattern of regional spread to Nodes.



Treating whole neck in all patients make no sense.

IMRT




Selective neck irradiation similar to selective neck dissection



Location of the nodes and Pattern of spread

Location of Neck Nodes

- **Robbins Classification:- Surgeons**
 - **Brussels system**
 - **Rotterdam system**
 - **RTOG Consensus Guidelines**
- 

Due to discrepancies in different systems , a consensus guidelines was derived

Changes in Robbins classification

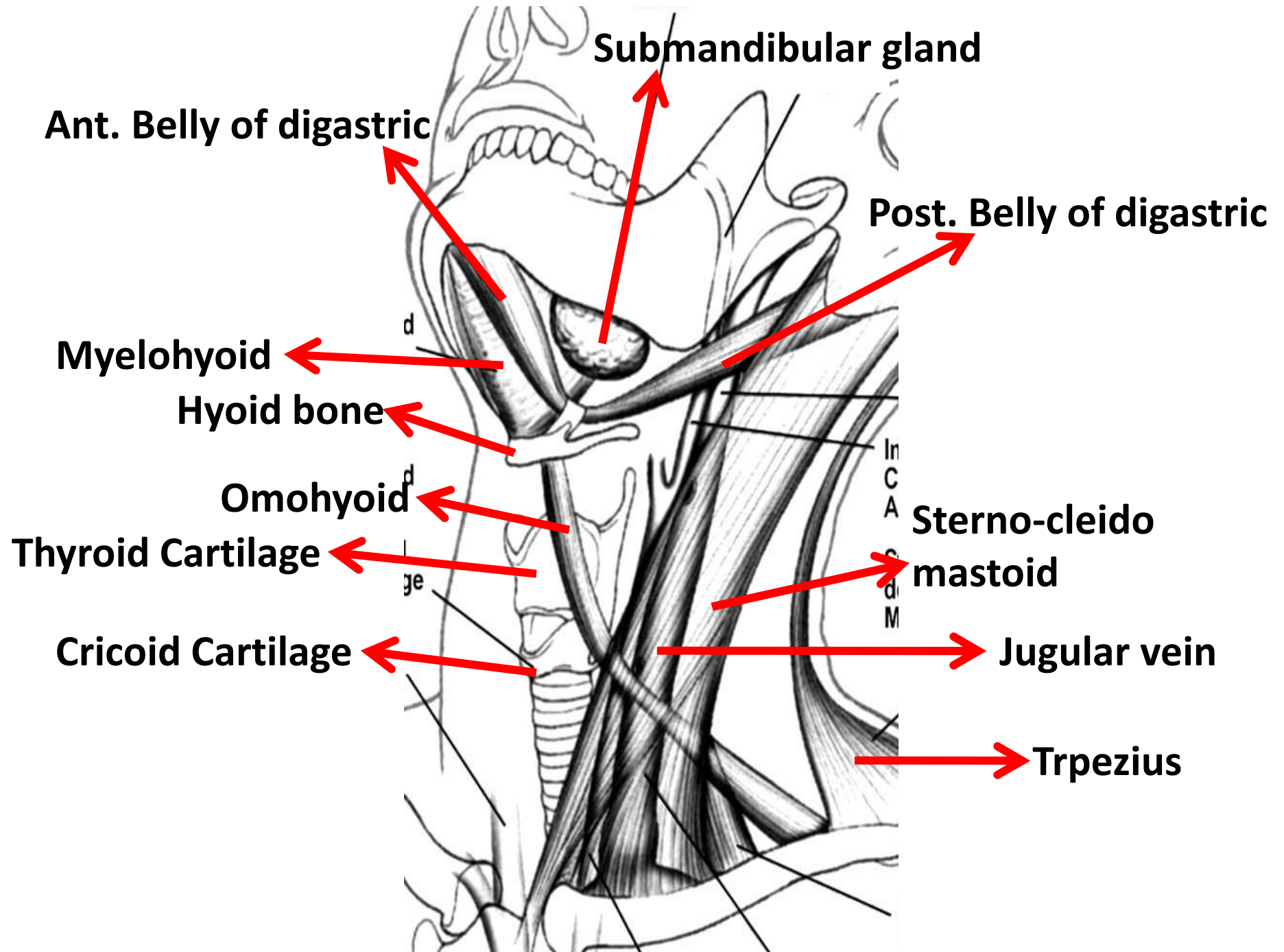
- Based on surgical boundaries like muscles, nerves and vessels.
- But these structures may not be identifiable on CT.
- Cranial limit for level II was defined by surgeons at insertion of post belly of digastric muscle at mastoid.
- But this point may not be identifiable on CT.
- So cranial limit was modified to bony land mark like cervical vertebrae.

Changes in Robbins classification

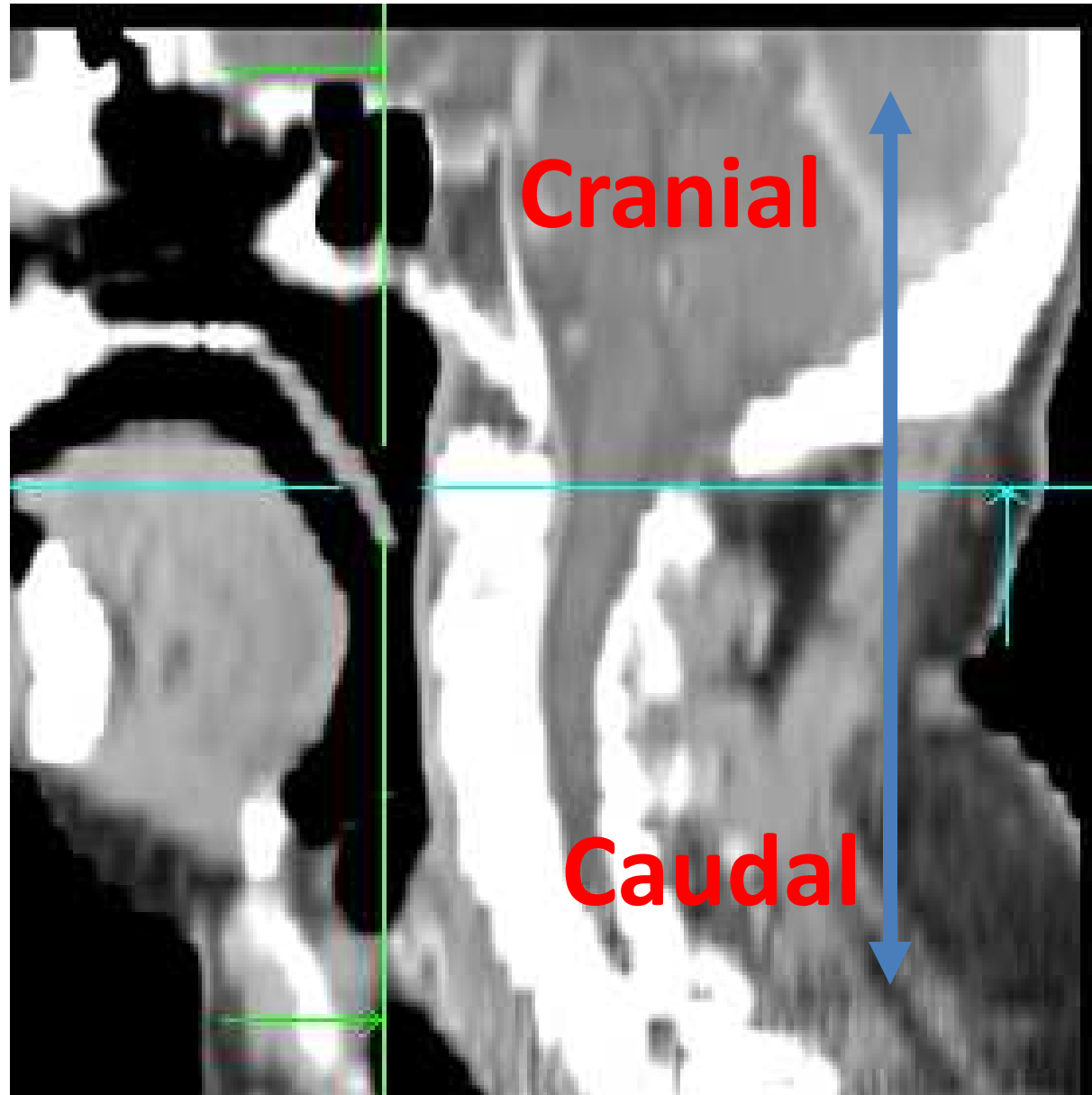
- **Similarly, Robbins defined the caudal limit of level III as the point at which the omohyoid muscle crossed the internal jugular vein (IJV); again not clearly identifiable on CT.**
- **So easily identifiable landmark is chosen like lower border of cricoid cartilage.**

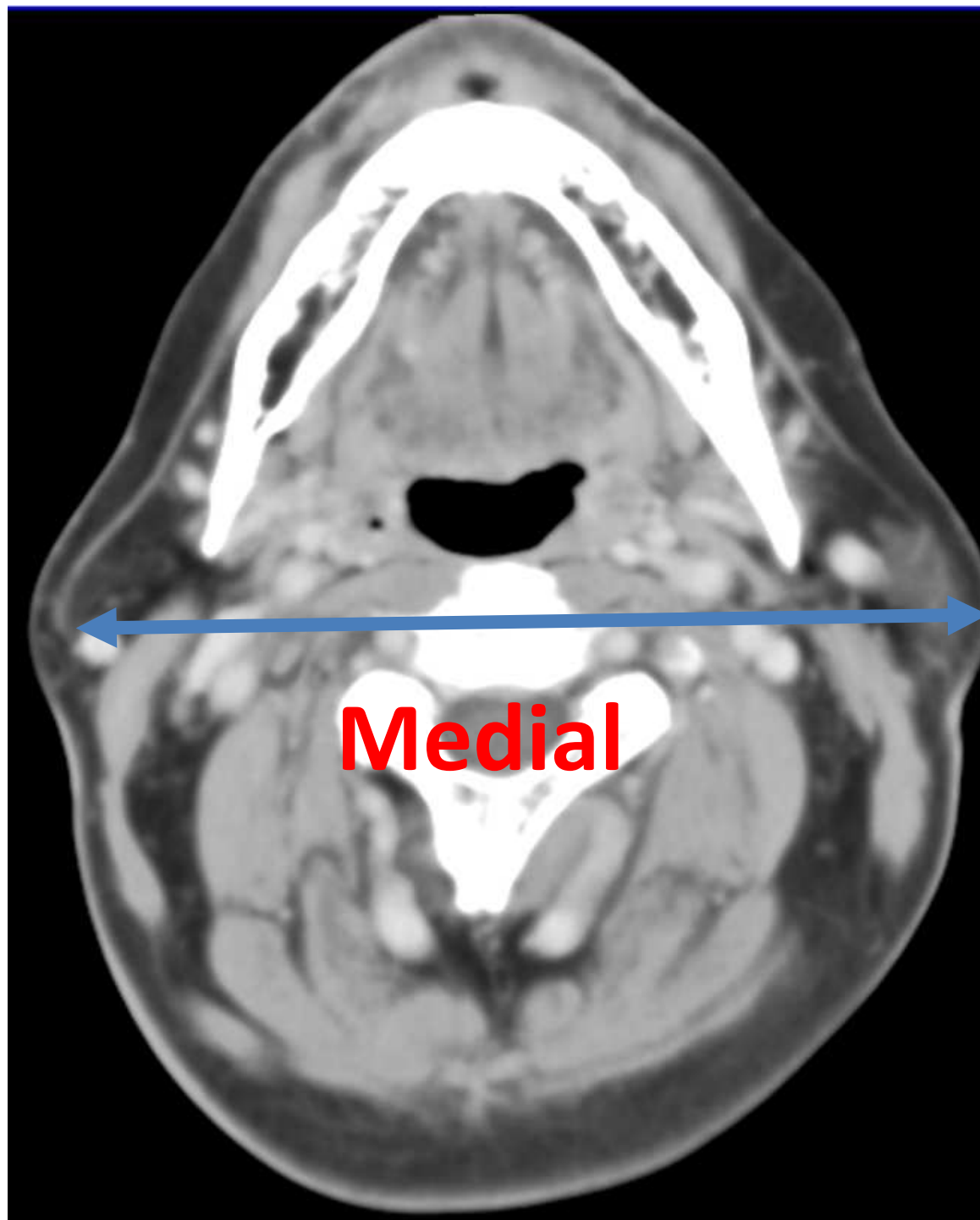
Changes in Robbins classification

- **Robbins used the spinal accessory nerve (SAN) to sub-divide level II into IIa (anterior to a vertical plane defined by the nerve) and IIb (posterior to that plane).**
- **SAN cannot be identified on CT scans,**
- **So, posterior edge of the IJV for the subdivision between levels IIa and IIb**



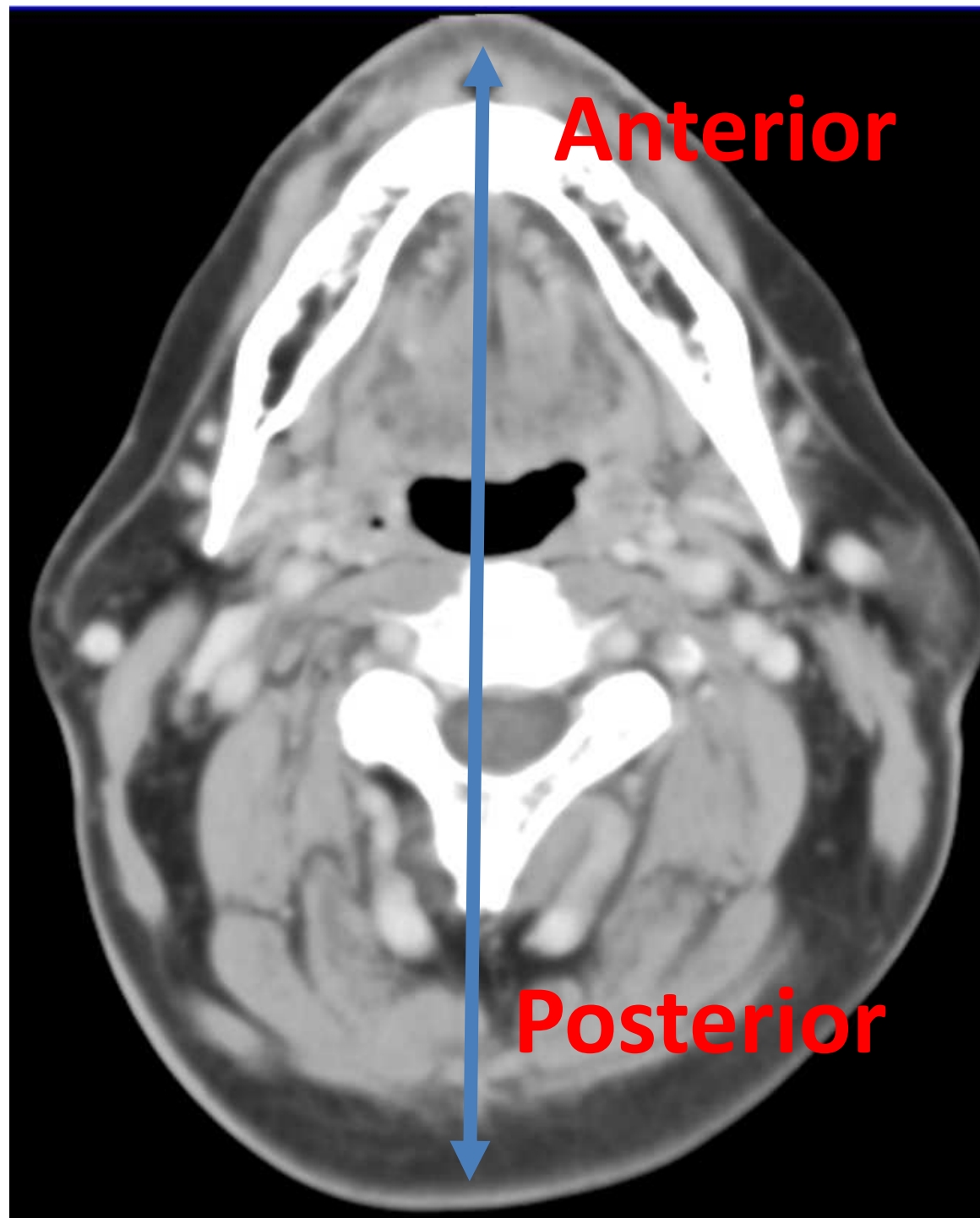
Boundaries

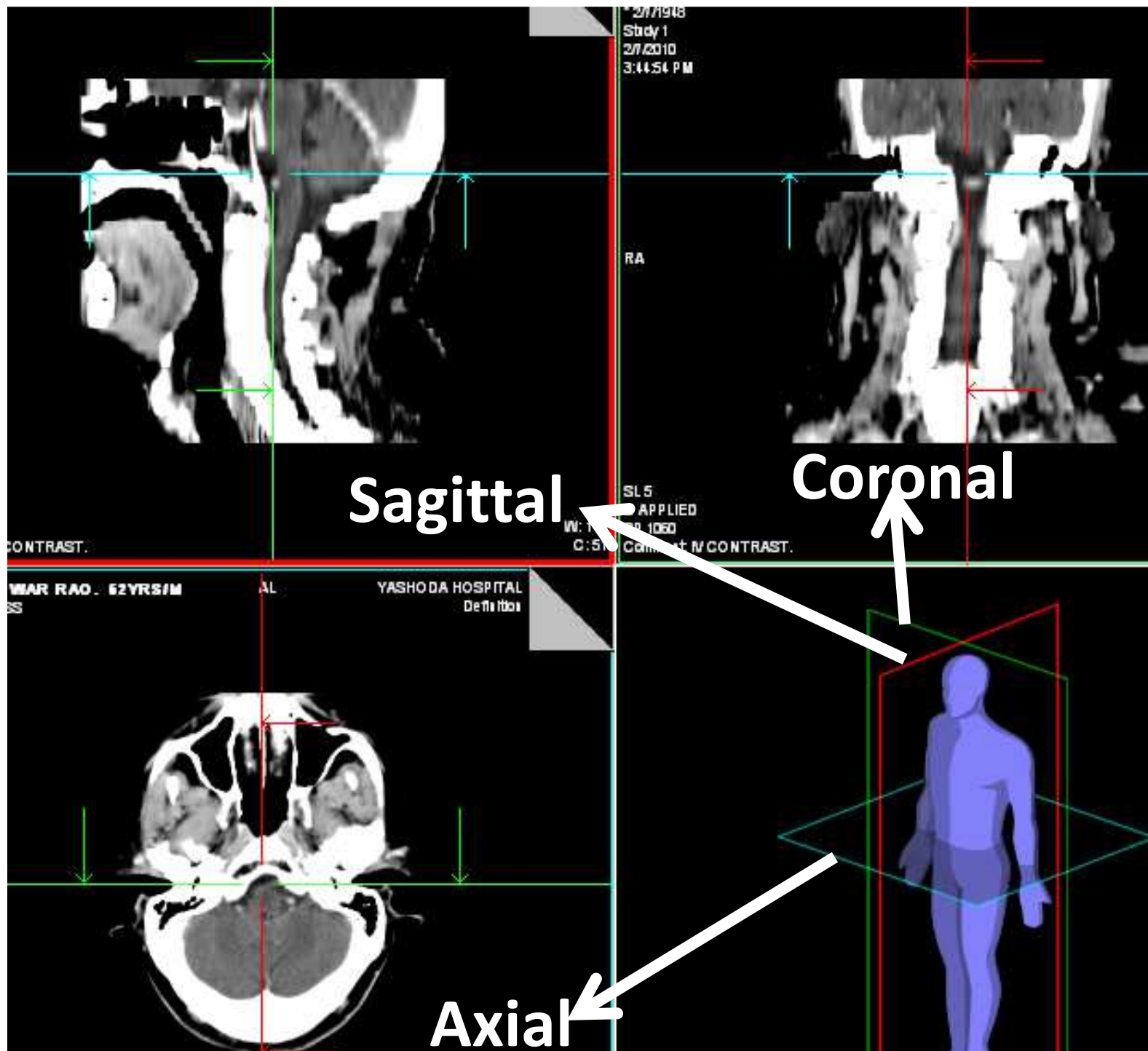




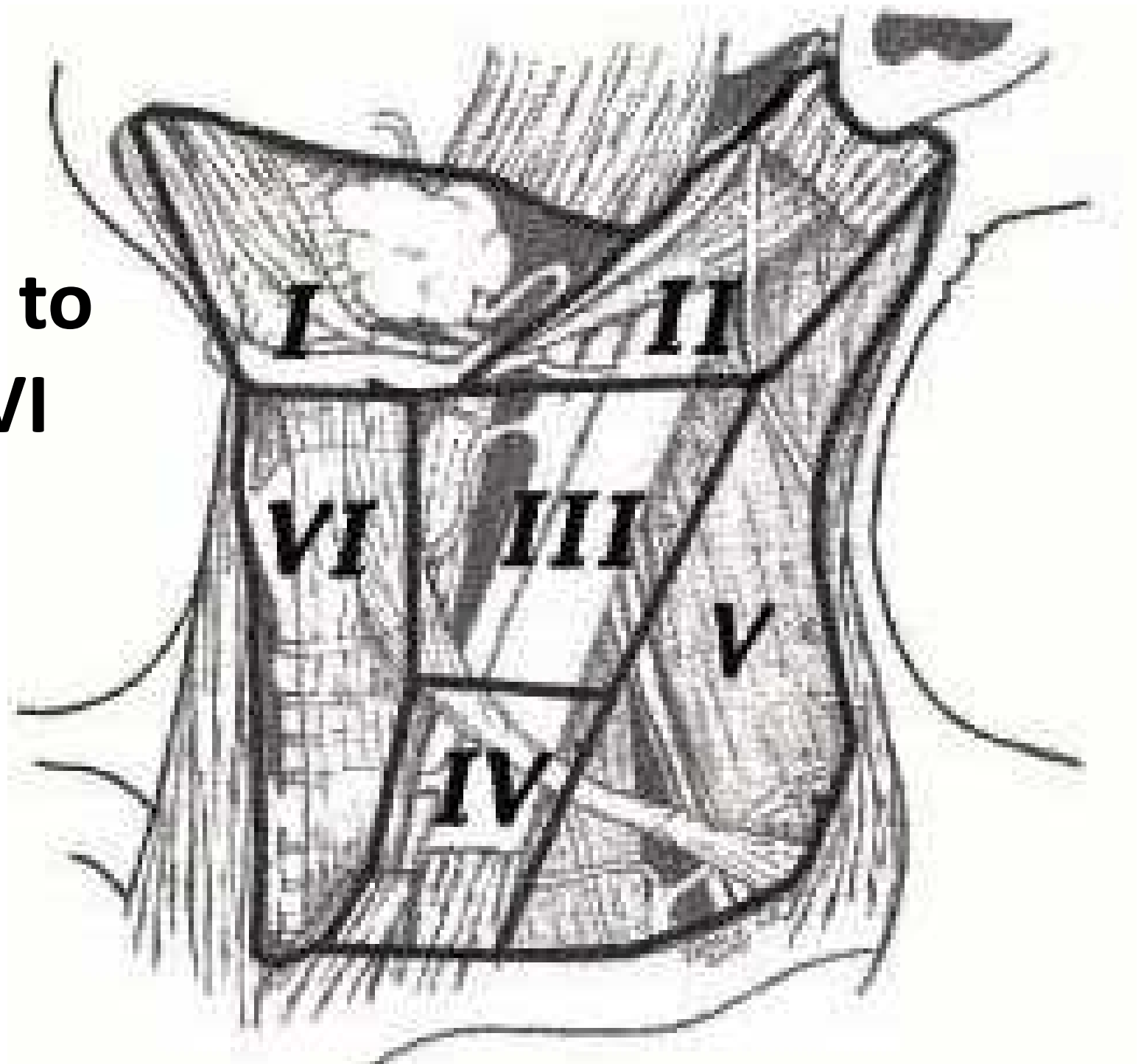
Medial

Lateral





**Level I to
Level VI**

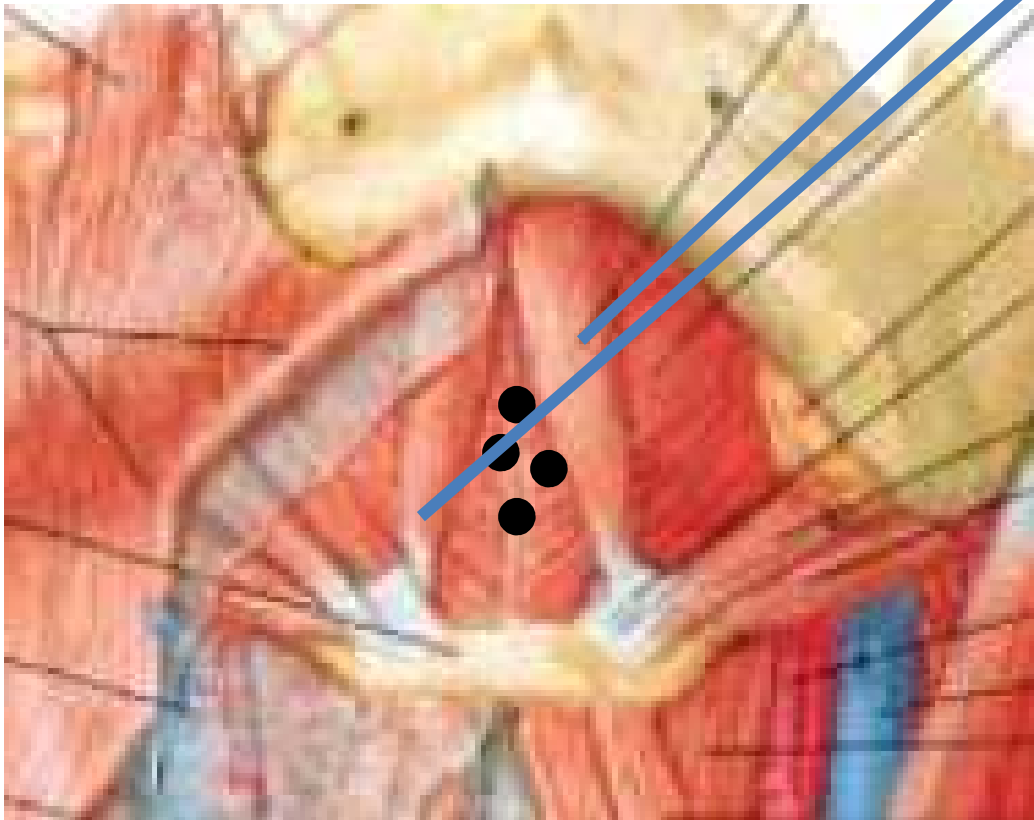


Level I

- **Level Ia (Sub-mental)**

Sub-mental triangle:

– Bounded by two anterior belly of digastric



Primary for la

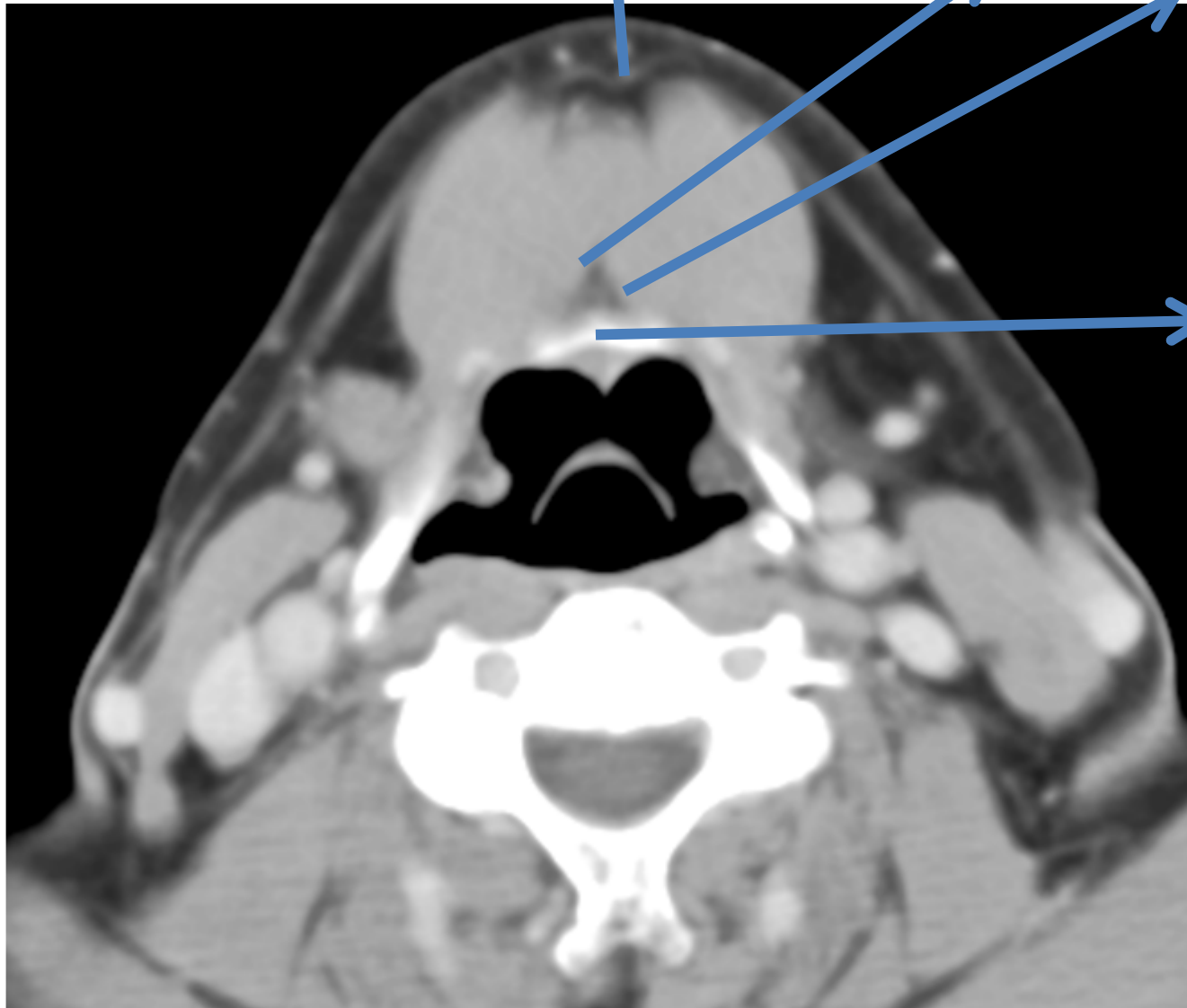
- Floor of the mouth.
- Anterior oral tongue.
- Anterior mandibular alveolar ridge.
- lower lip.

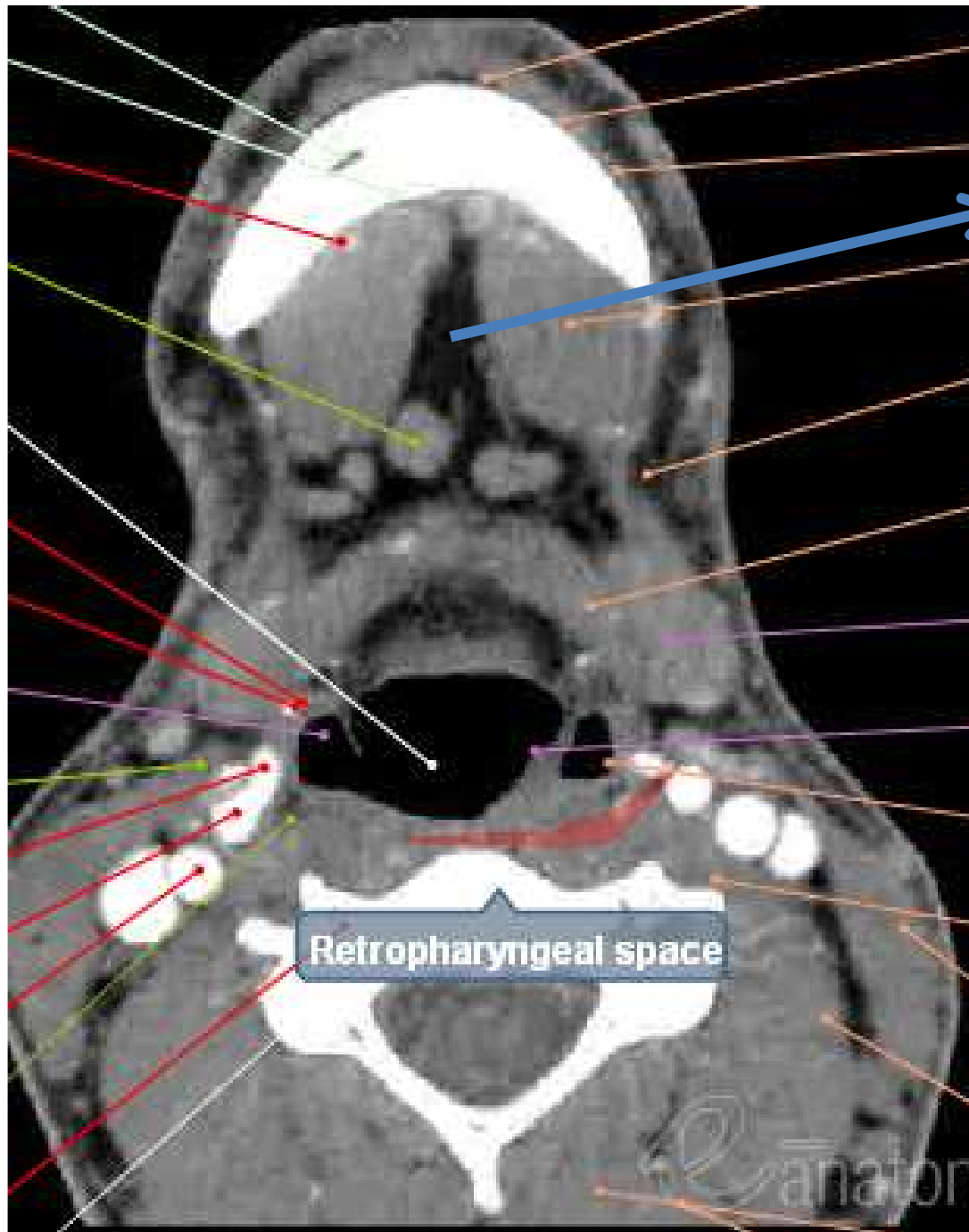
Anterior-> Platysma
muscle and the symphysis
menti,

Lateral-> Medial edge
of ant belly of two
digastric muscles

Posterior ->
body of the hyoid
bone,

Level Ia



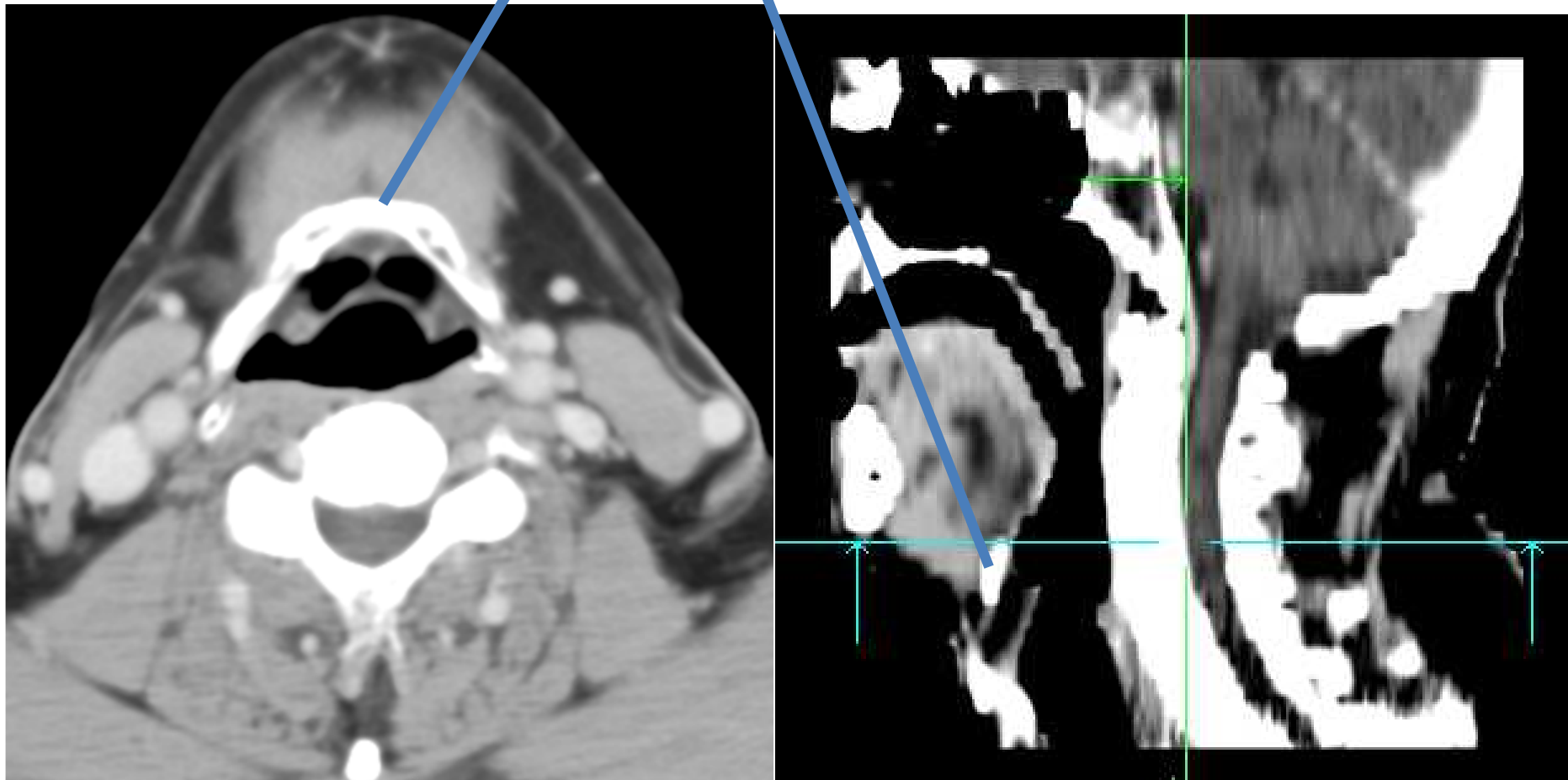


Medial-> region
continues into the
contralateral level Ia

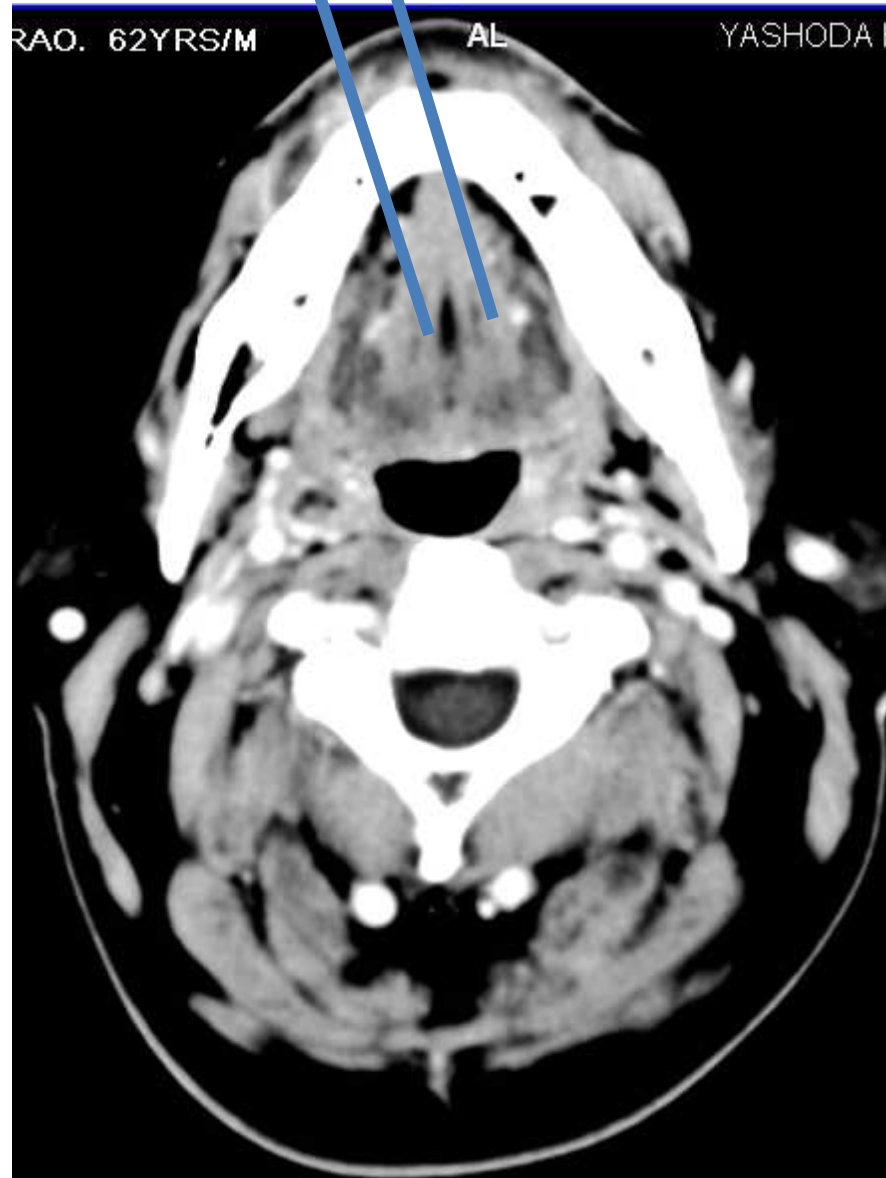
Level Ia

Level Ia

Caudal-> hyoid bone



Cranial-> Geniohyoid muscle or a plane tangent to the basilar edge of the mandible.



This axial CT scan of the neck shows a red outline highlighting a lesion in the soft tissue of the upper neck, likely the thyroid gland. The lesion is located anterior to the trachea and posterior to the larynx. The surrounding structures, including the trachea, larynx, and vertebrae, are visible in cross-section.

This axial CT scan of the neck shows segmented regions. Region IA is a small red area at the top. Region IB is a larger red area on the right side. Region IC is a yellow area on the right side, below IB. A white line points to the boundary between IB and IC. A green square is in the top right corner.

Level I

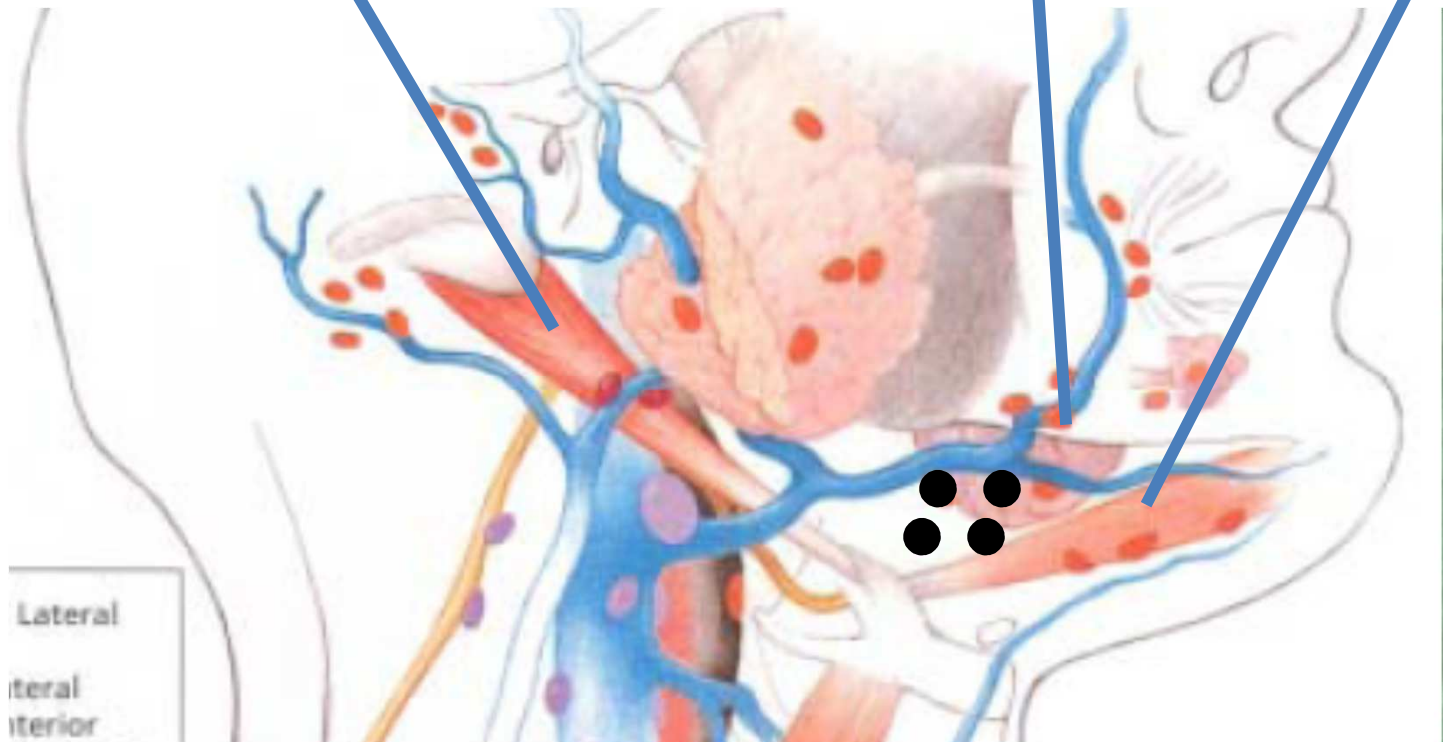
- **Level Ib (Sub-mandibular)**

Sub-mandibular Triangle Formed by the Digastric Muscle

Posterior belly

Anterior belly

Body of the mandible

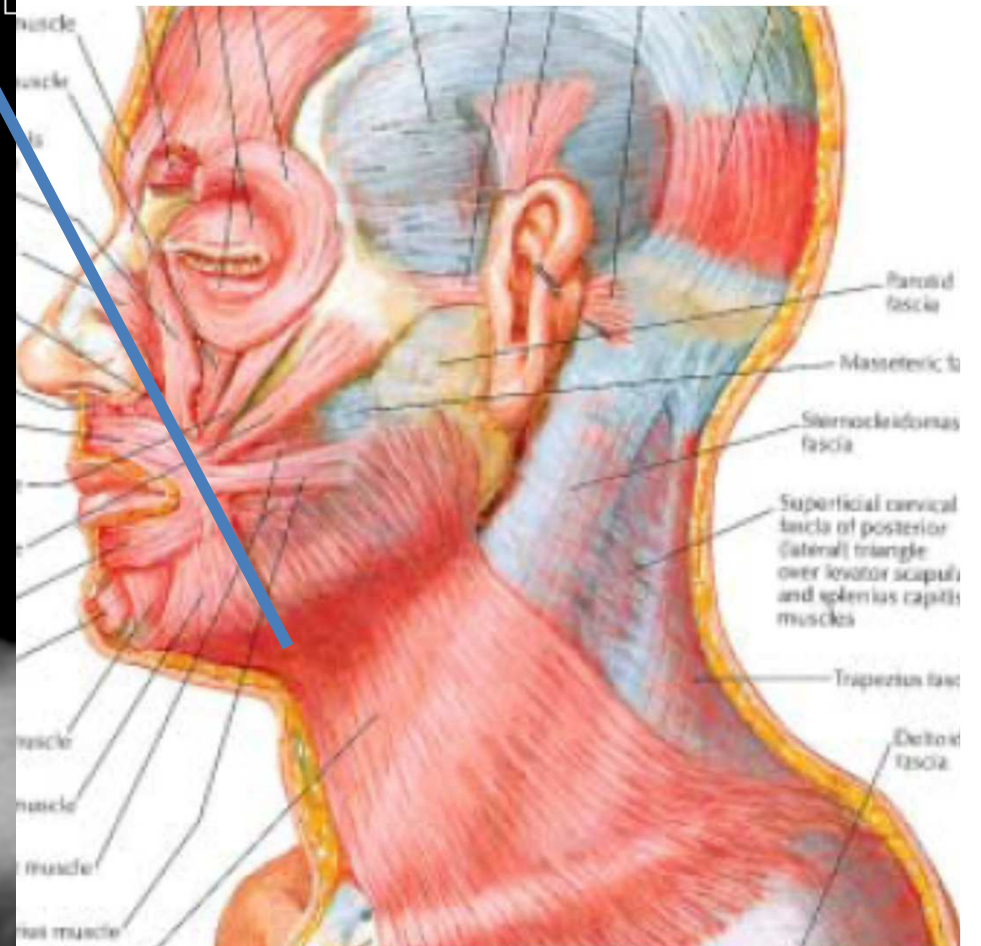
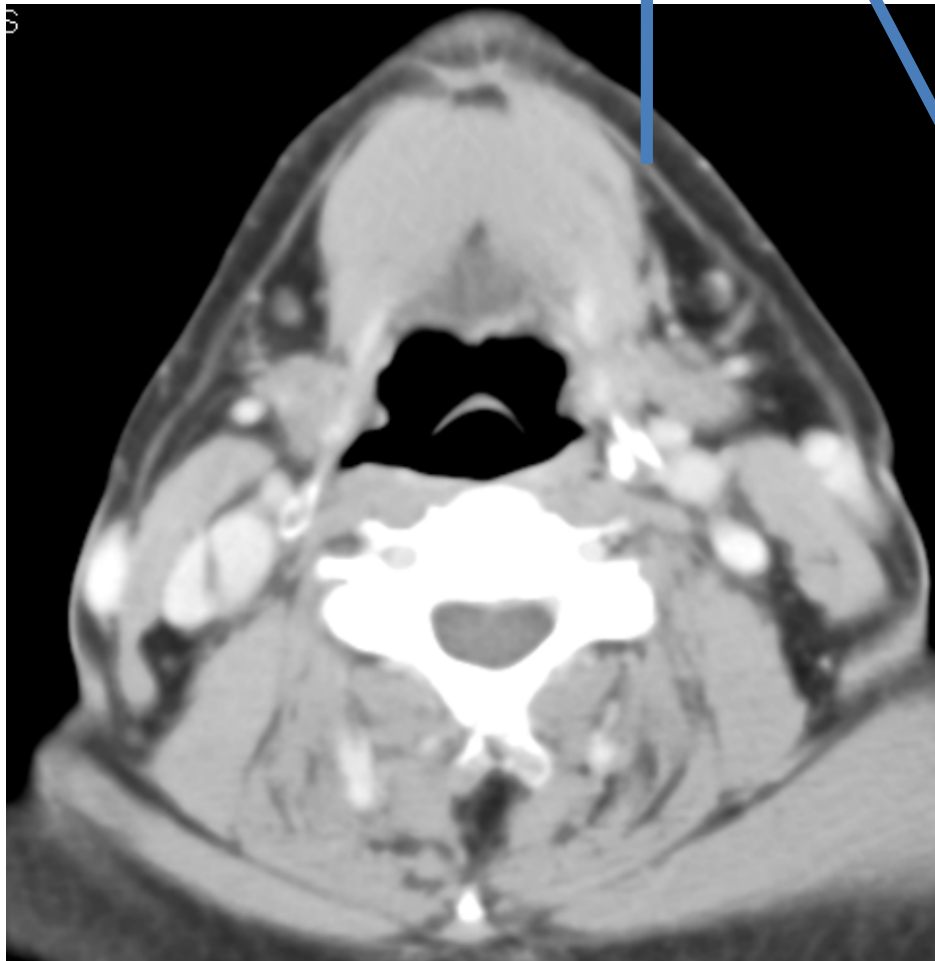


Primary for Ib

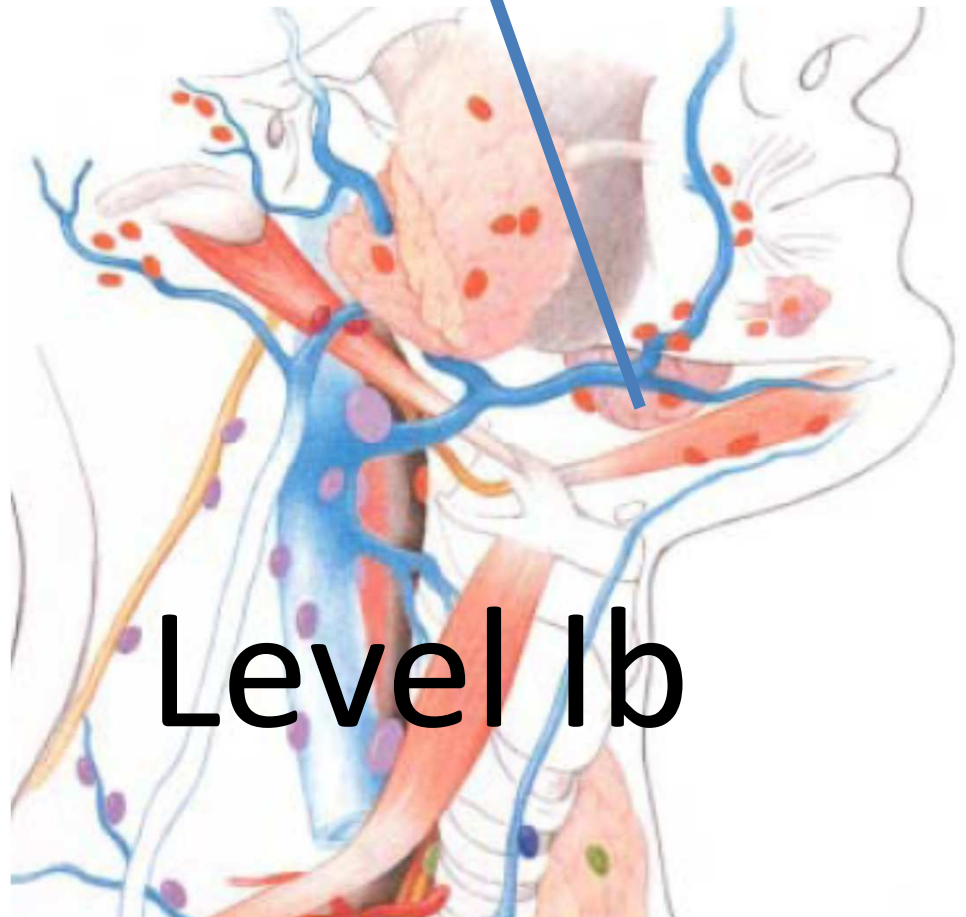
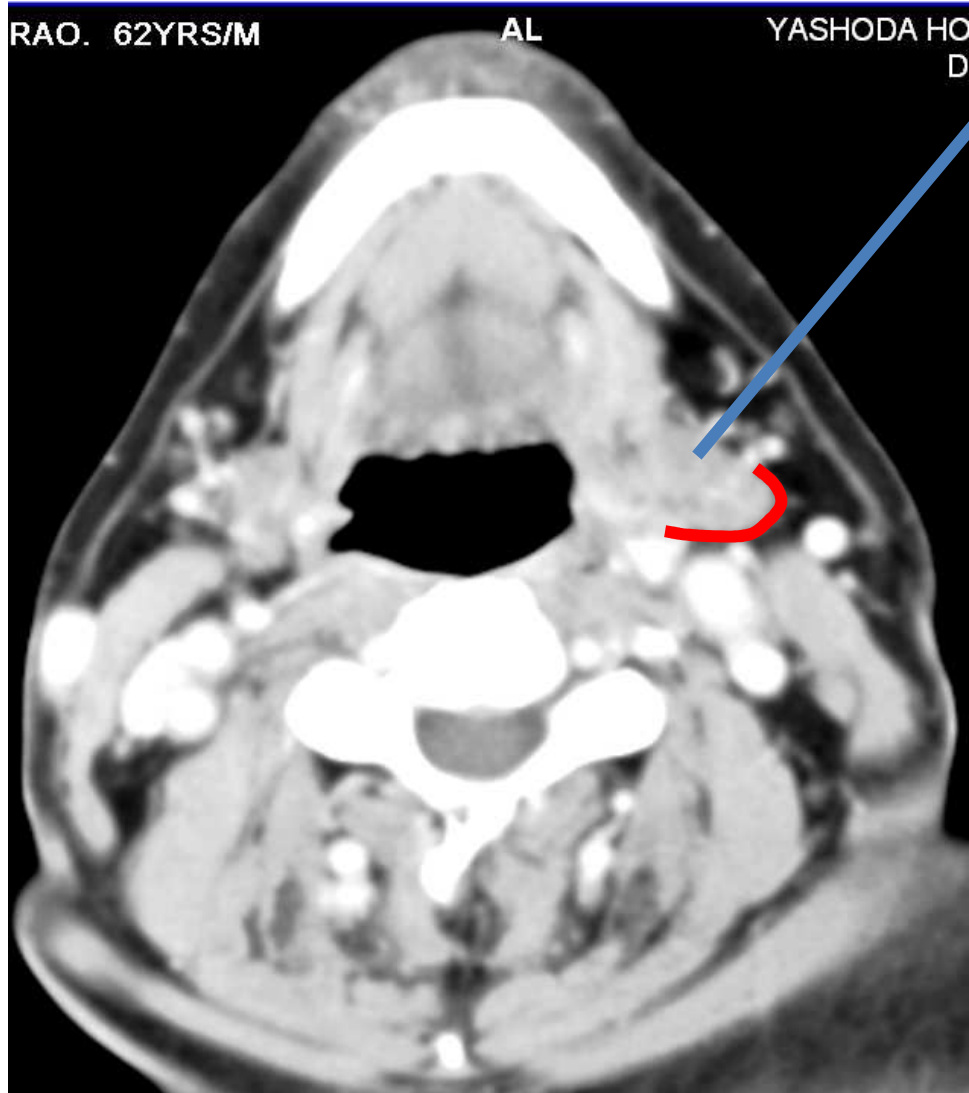- **cancers of the oral cavity,**
- **anterior nasal cavity,**
- **soft tissue structures of the mid-face and**
- **the submandibular gland.**

Anteriorly -> Platysma muscle

Level Ib

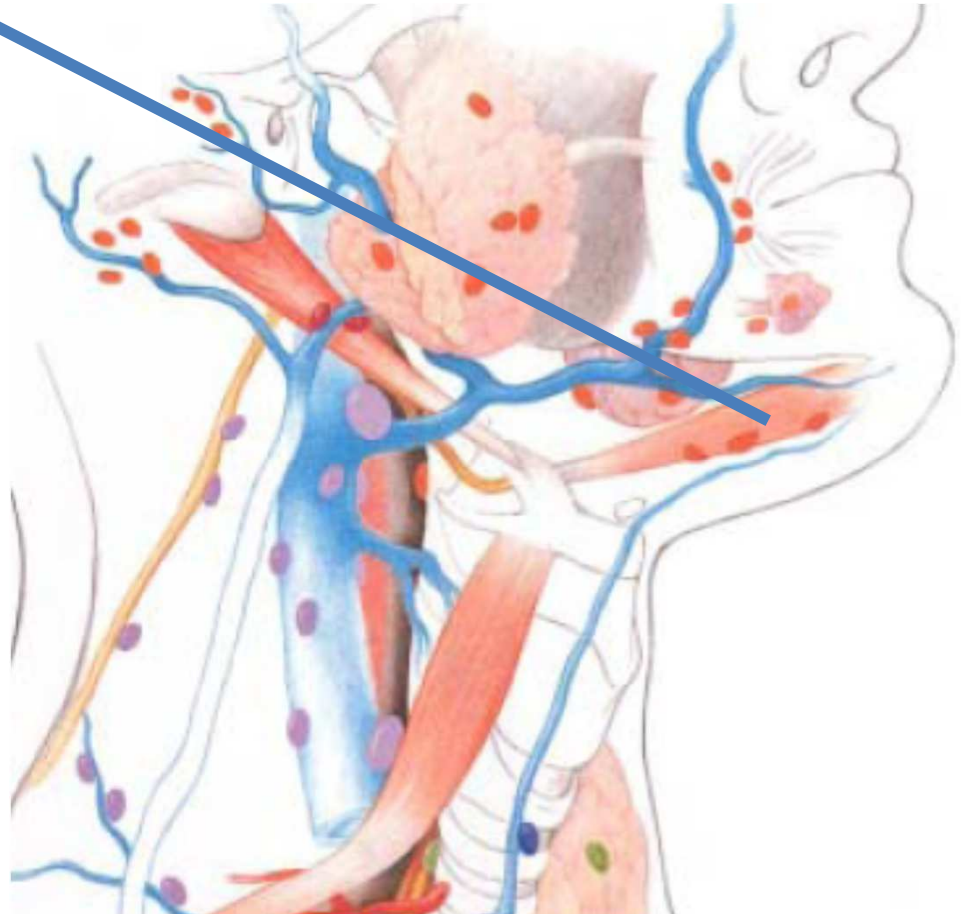
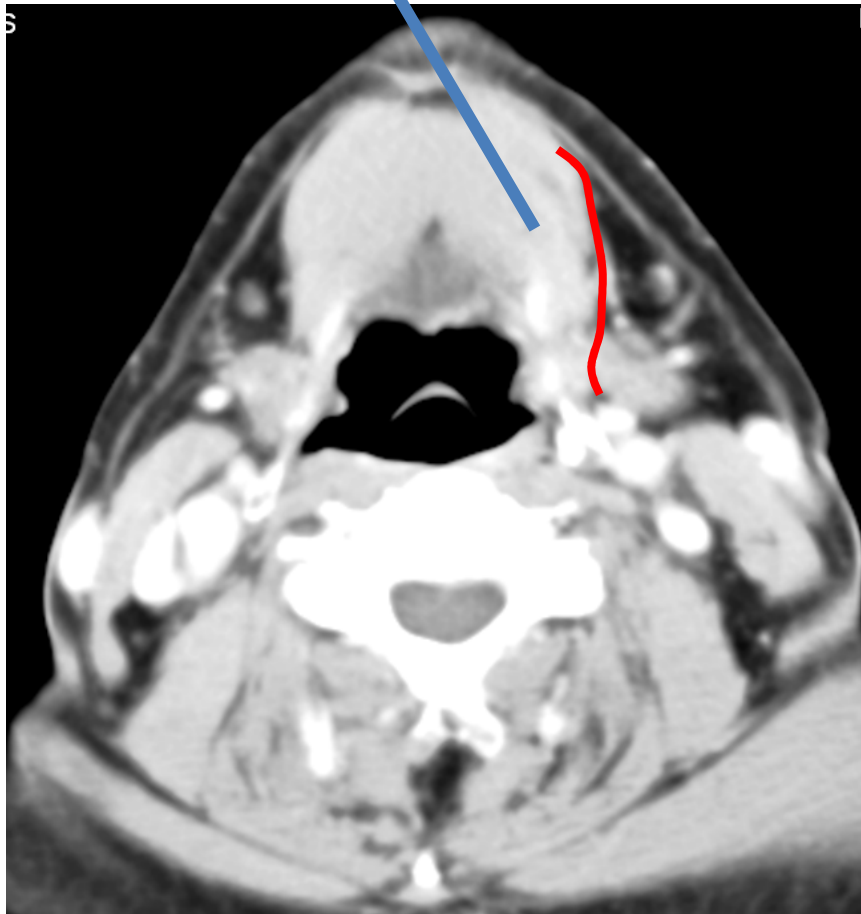


Posterior-> Posterior edge of the submandibular gland



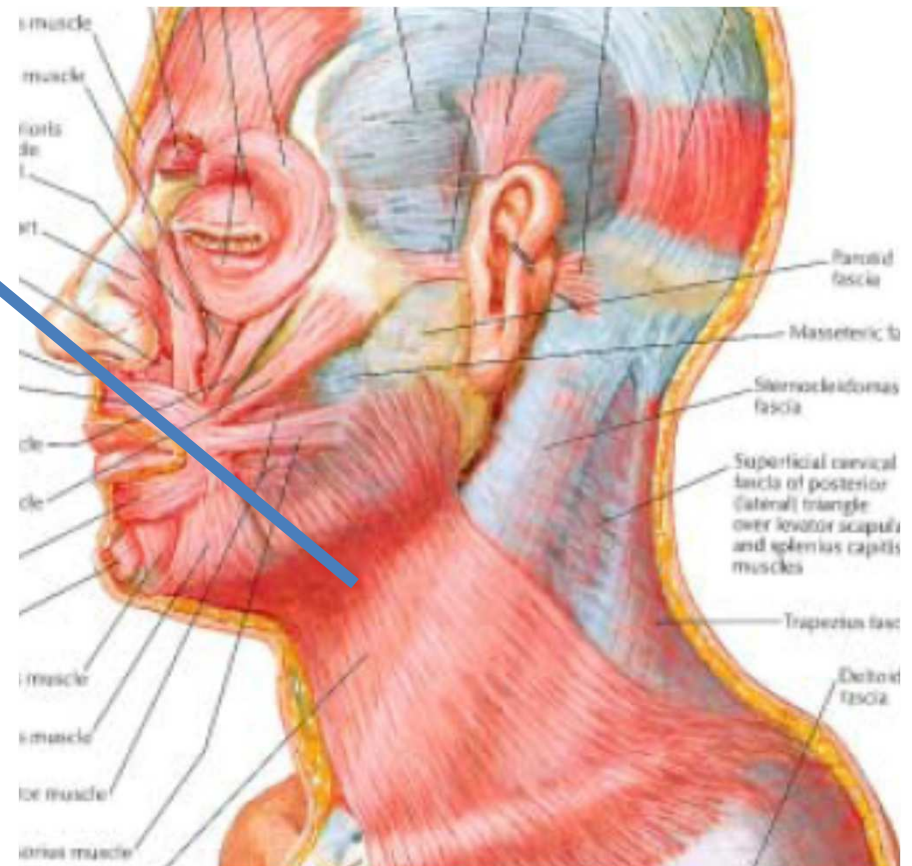
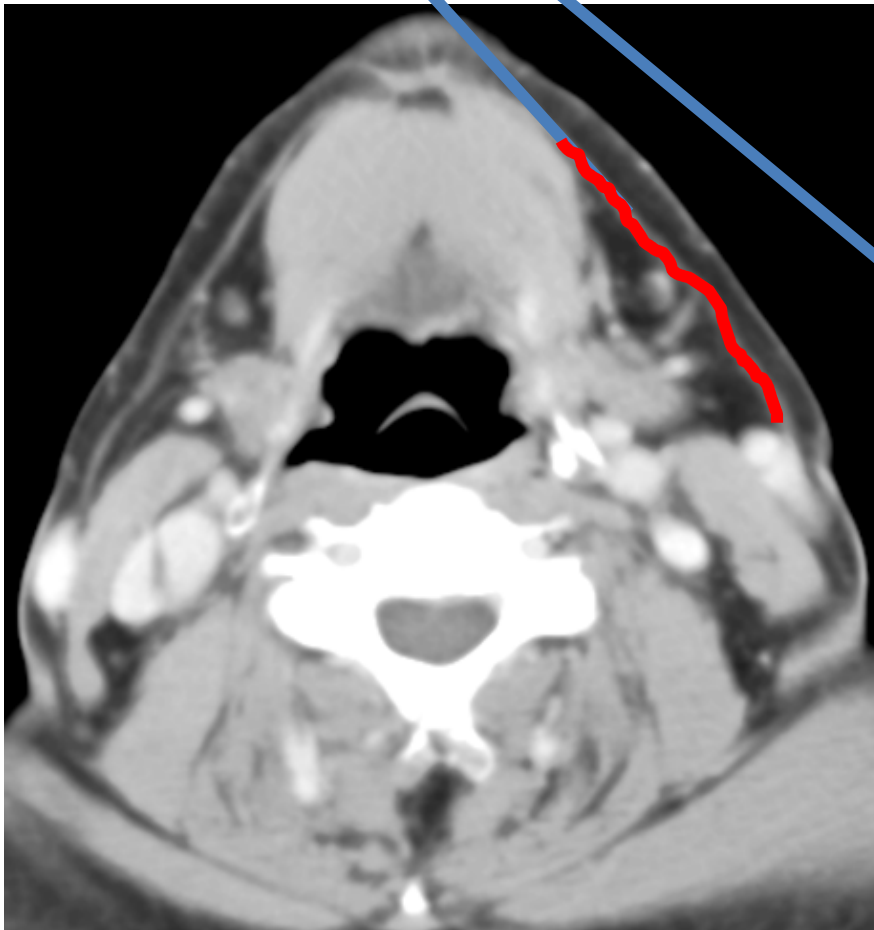
Medial-> lateral edge of the ant belly of digastric muscle

Level Ib

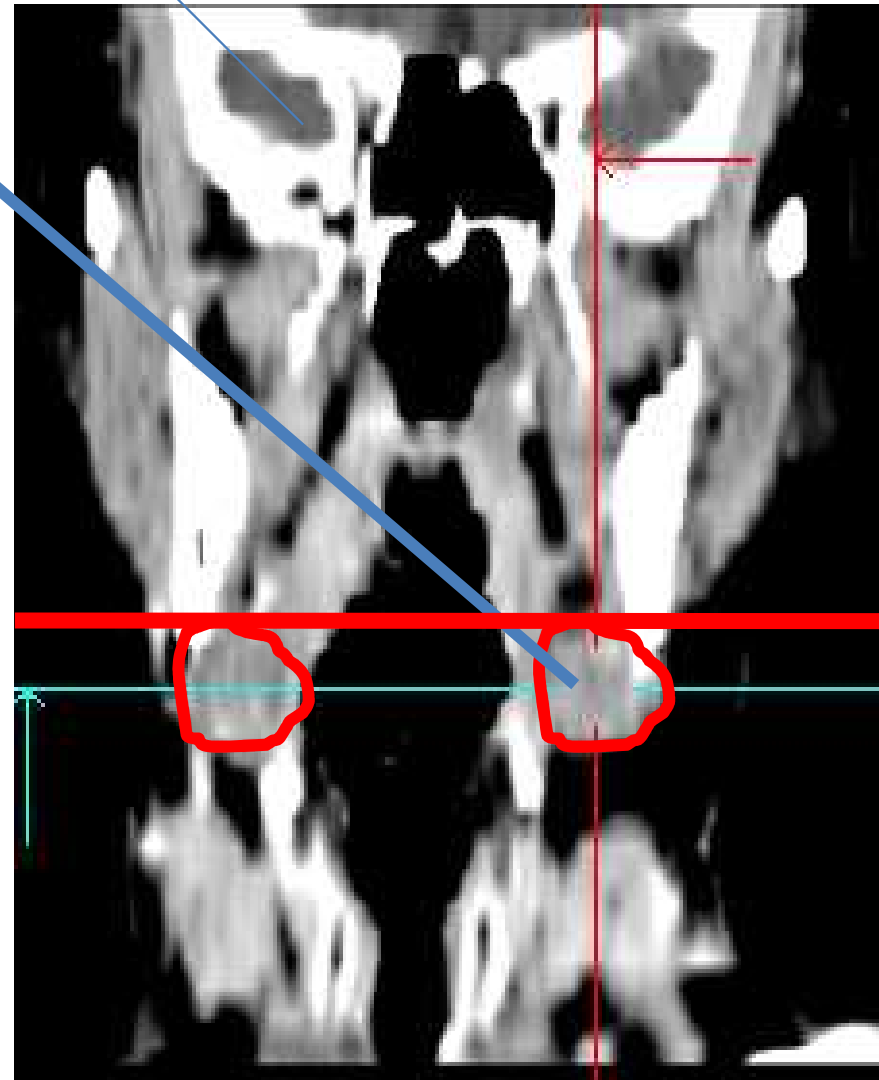
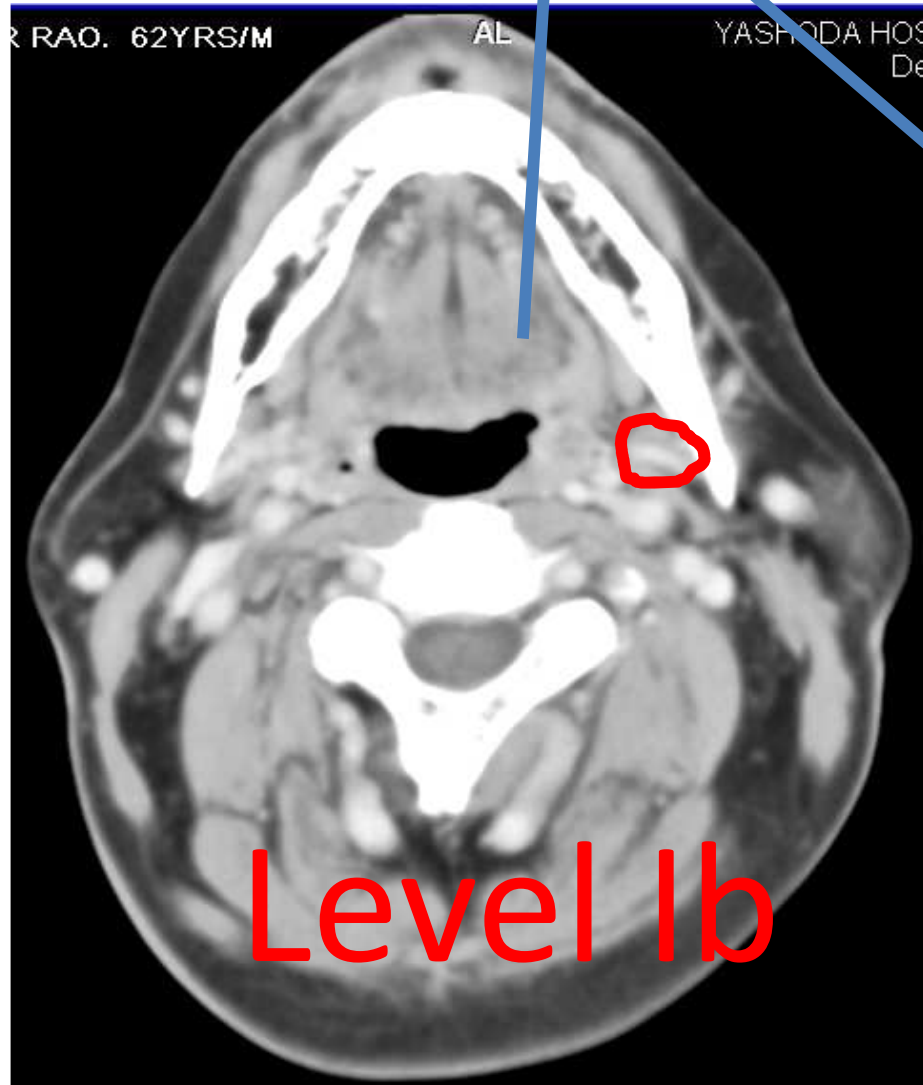


Lateral-> Inner side of the mandible, Platysma and skin.

Level Ib

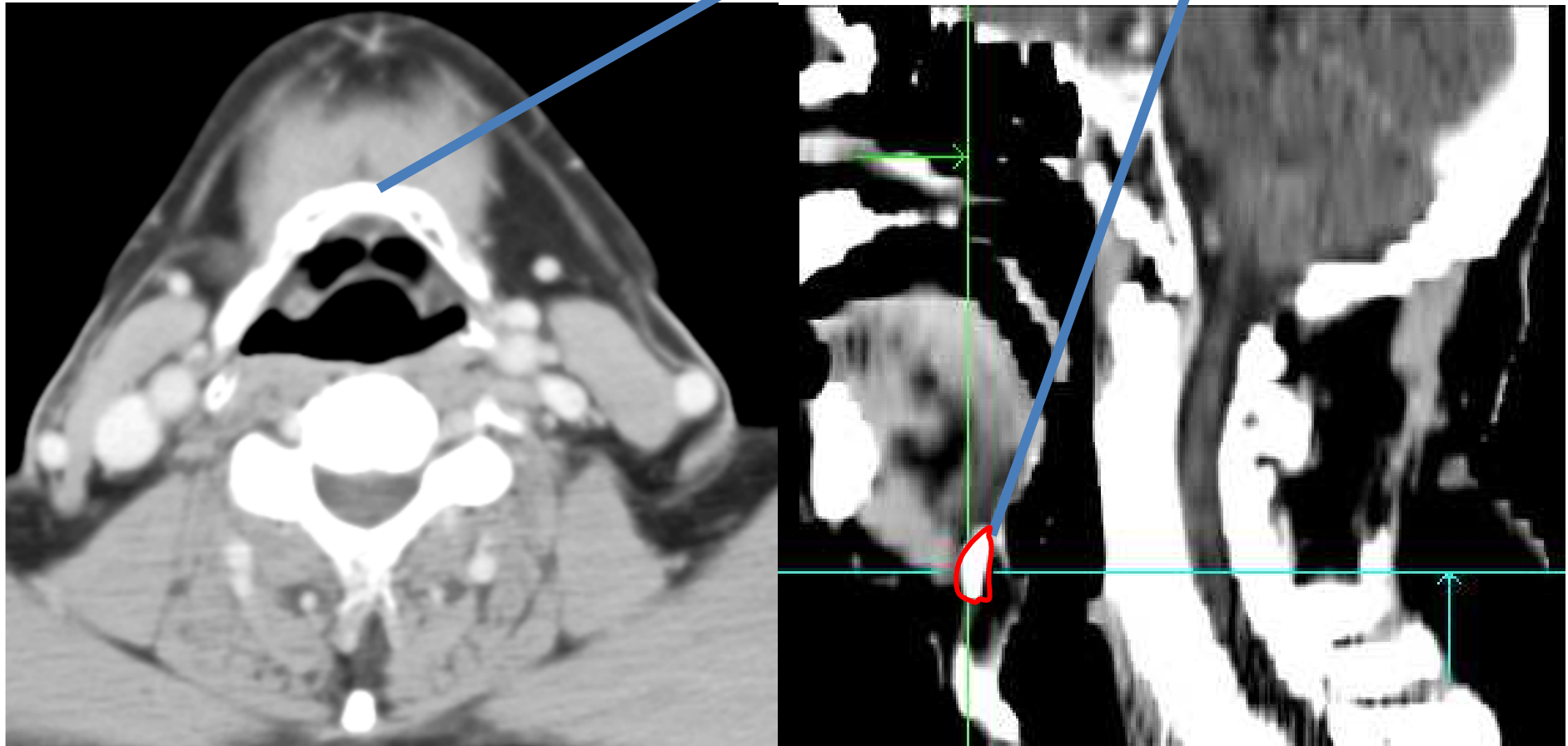


Cranial-> Mylohyoid muscle and cranial edge of the submandibular gland.



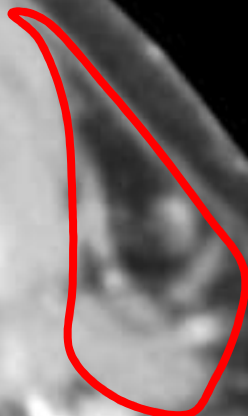Caudal-> Plane crossing the central part of Hyoid bone

Level Ib



RAO. 62YRS/M AL YASHODA HO
D

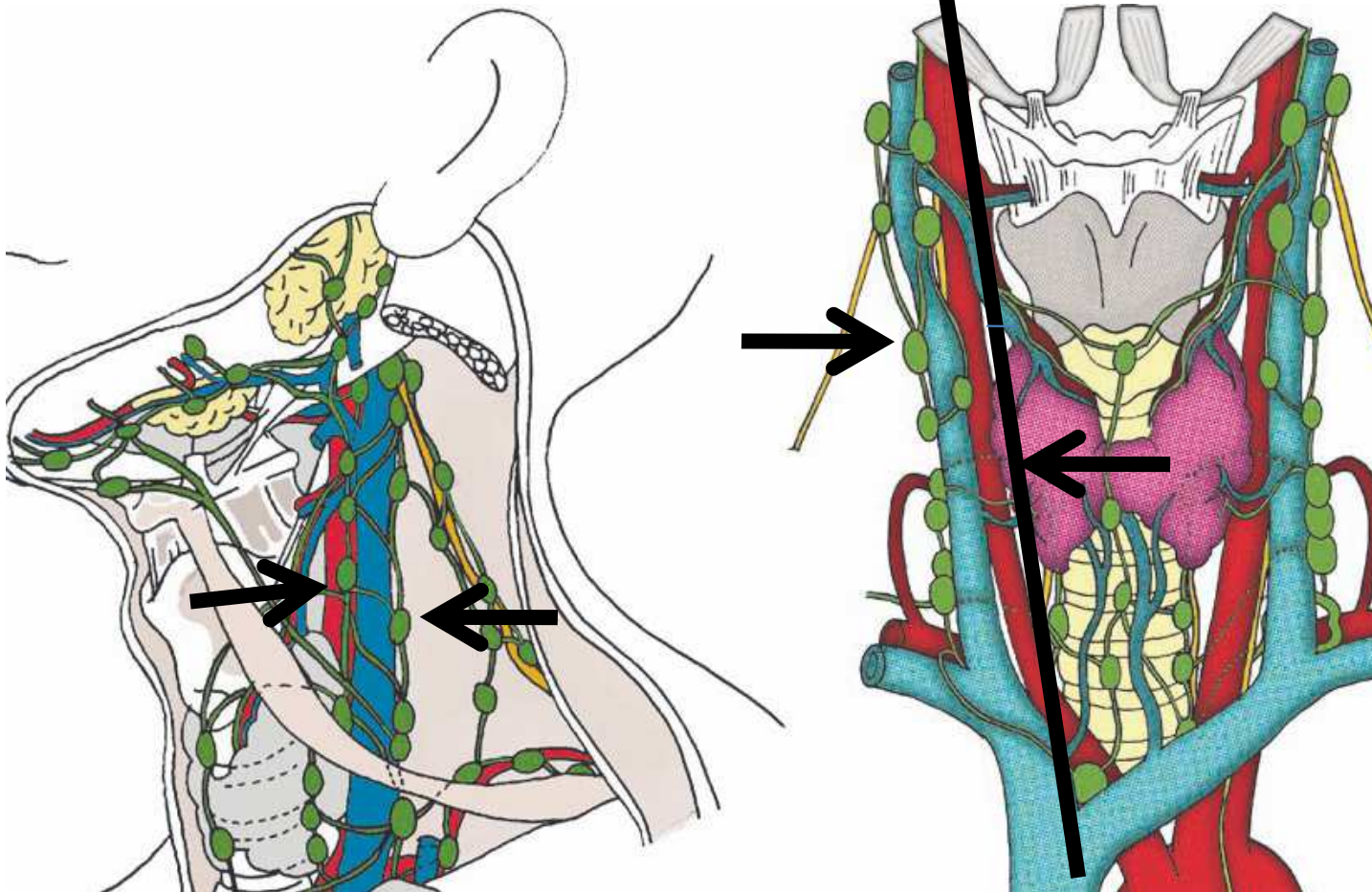
Contouring



Level Ib

Jugular nodes

- Most of the jugular nodes(lev. II-IV) present ant., post., and lateral to the IJV.
- No nodes on medial to IJV
- So medial boundary is medial edge of the vessel bundle.

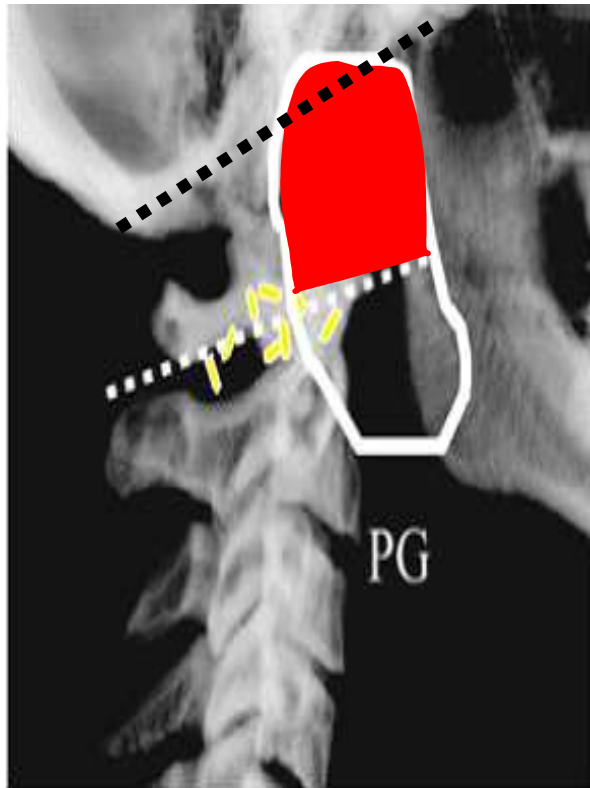


Level II

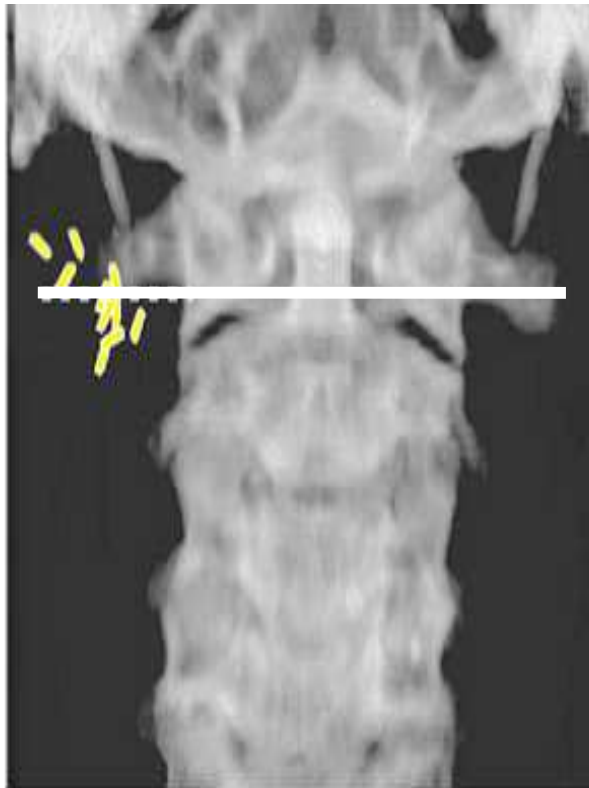
How consensus was made for cranial border for level II Nodes?

- **Cranial limit for level II was defined by surgeons at insertion of post belly of digastric muscle at mastoid.**
- **But this point may not be identifiable on CT.**
- **Surgeons were asked to put the clips at the upper level of dissection for level II nodes in node negative neck.**

How consensus was made for cranial border for level II Nodes?

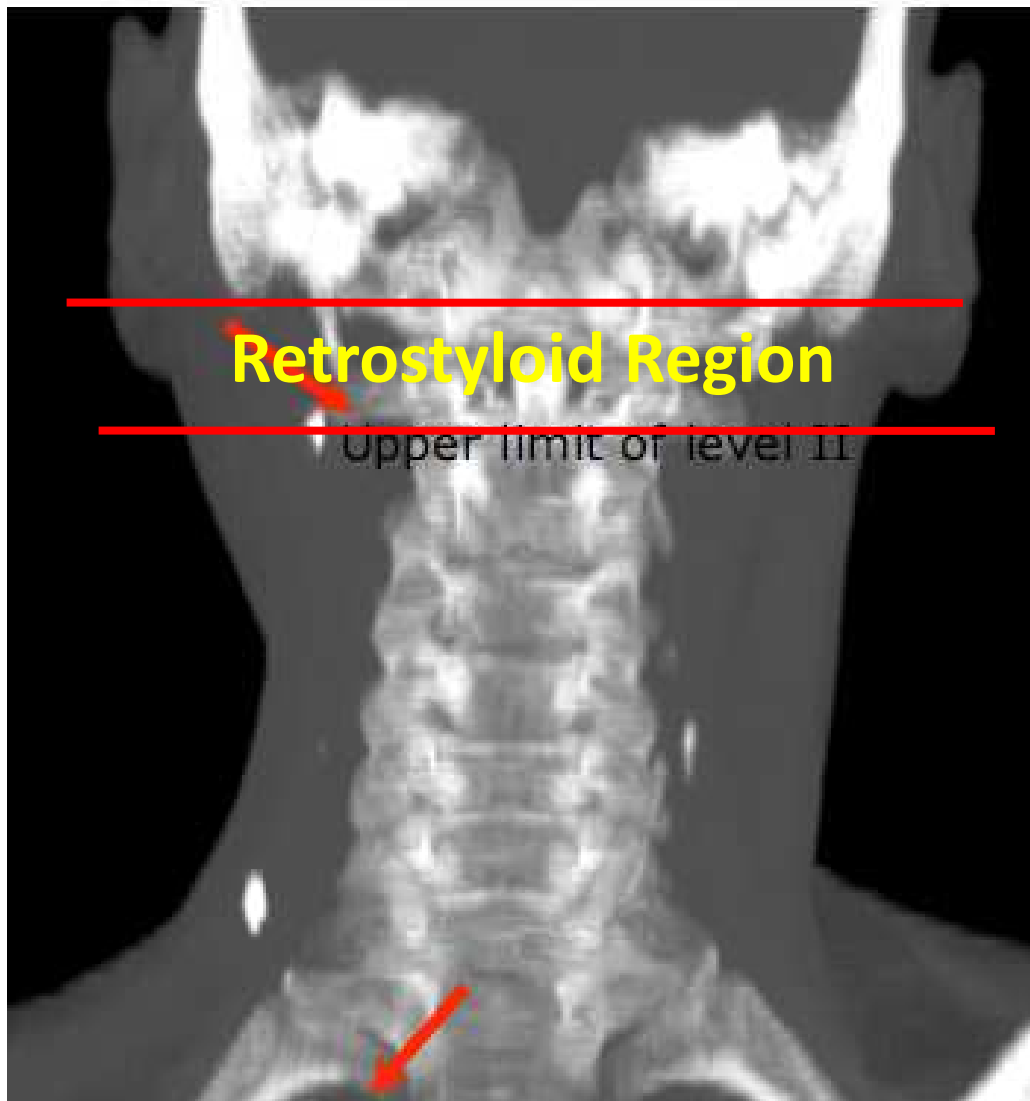


Parotid projection
so if cranial limit is
taken at base of
skull then more
parotid will be
irradiated.



- Clips cluster around caudal border of transverse process of vertebra C1.
- So cranial border of level II is taken at caudal edge of transverse process of C1.

Level II



- Usually the cranial limit of level II is caudal border of transverse process of C1 vertebrae.
- But few nodes also present superior to this up to base of skull.
- This region cranial to cranial limit of Level II is called Retro Styloid region.

When to treat Retro Styloid Region

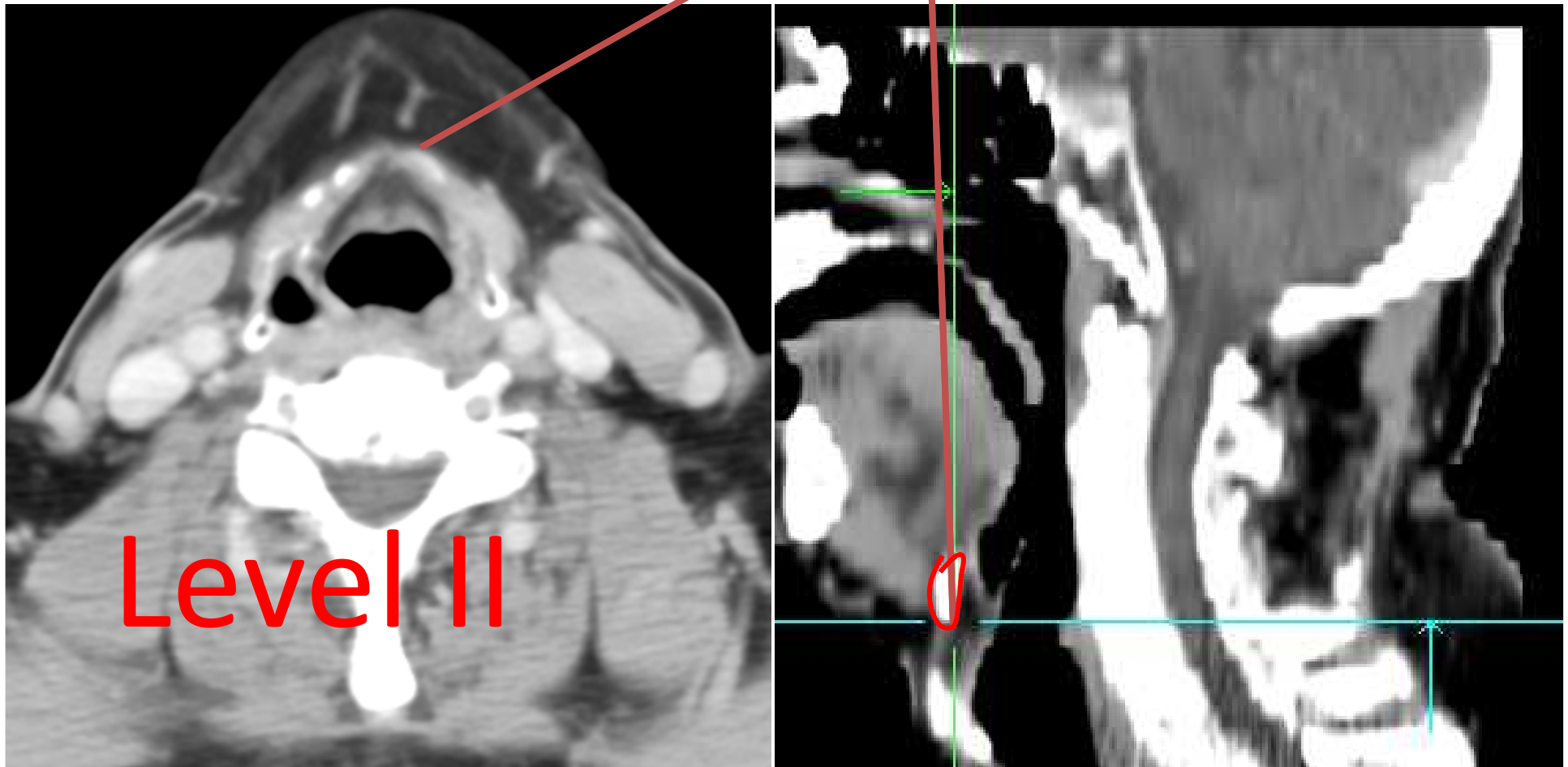
- **Ca Nasopharynx.**

Bilateral

- **In +ve level II node**

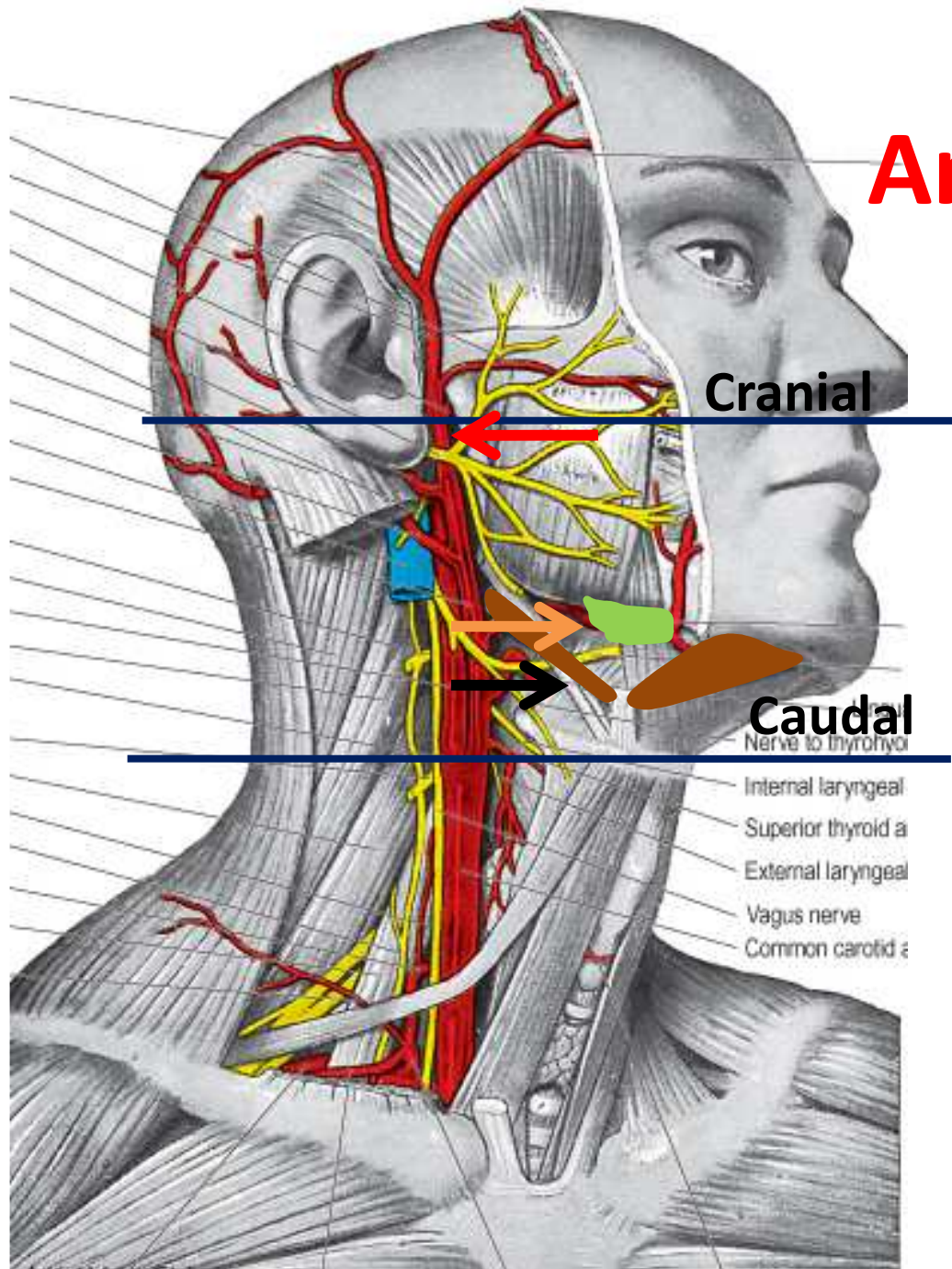
Ipsilateral

Caudal-> Carotid Bifurcation (Surgical Boundry)
caudal edge of body of the hyoid bone.



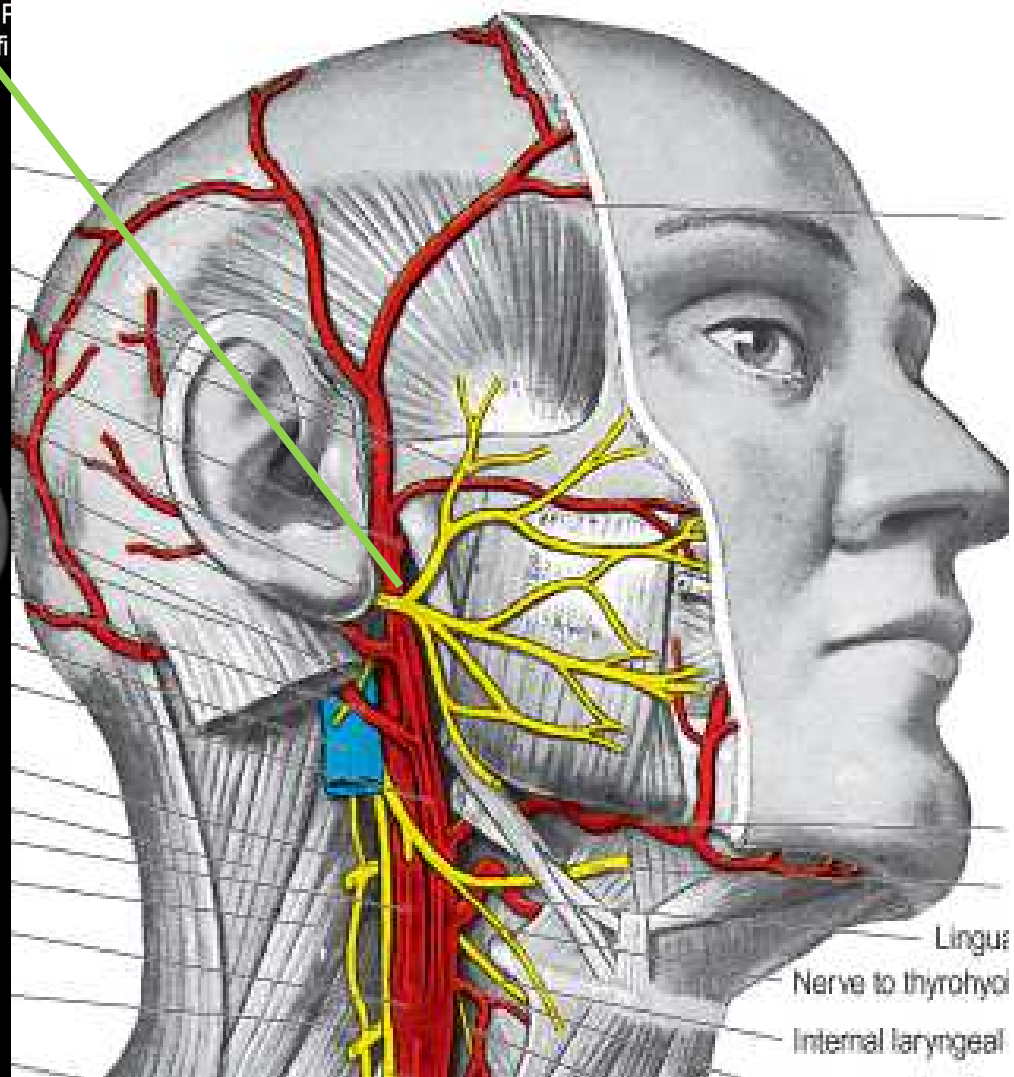
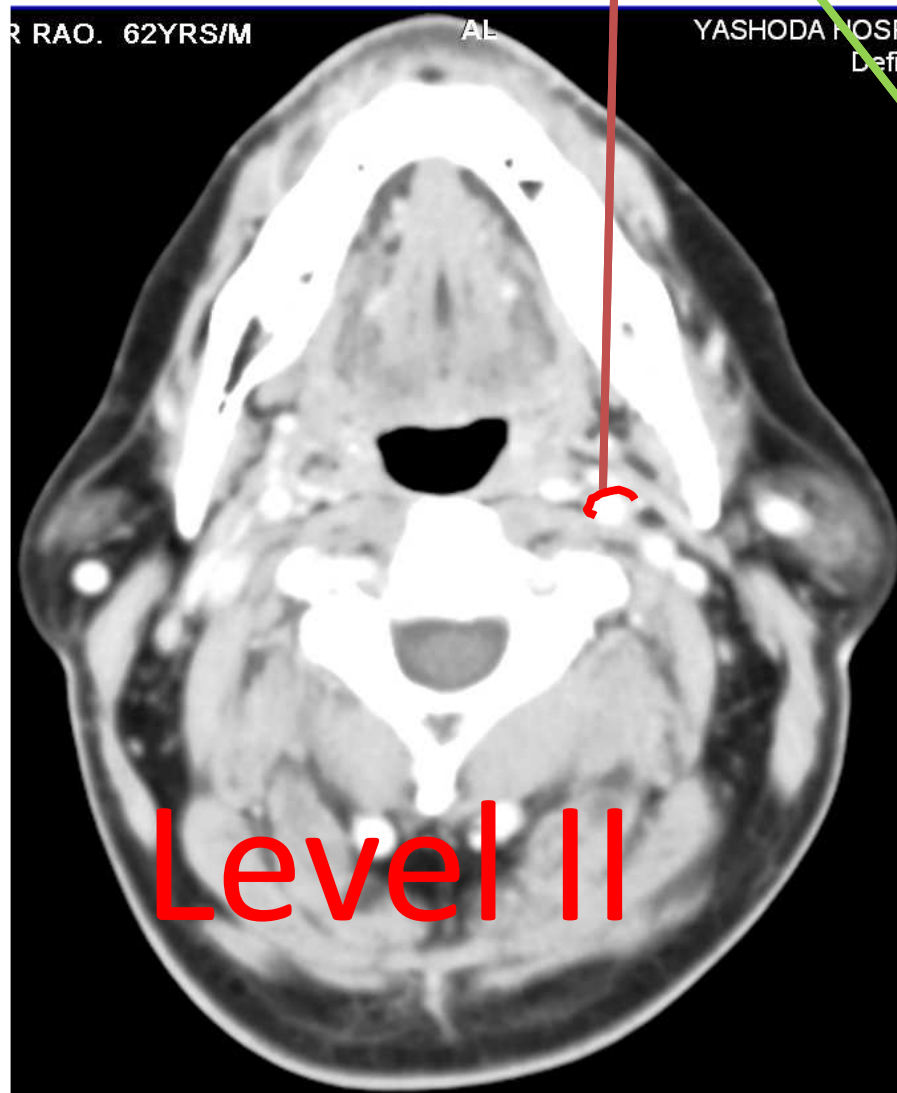
Level II

Anterior Relation

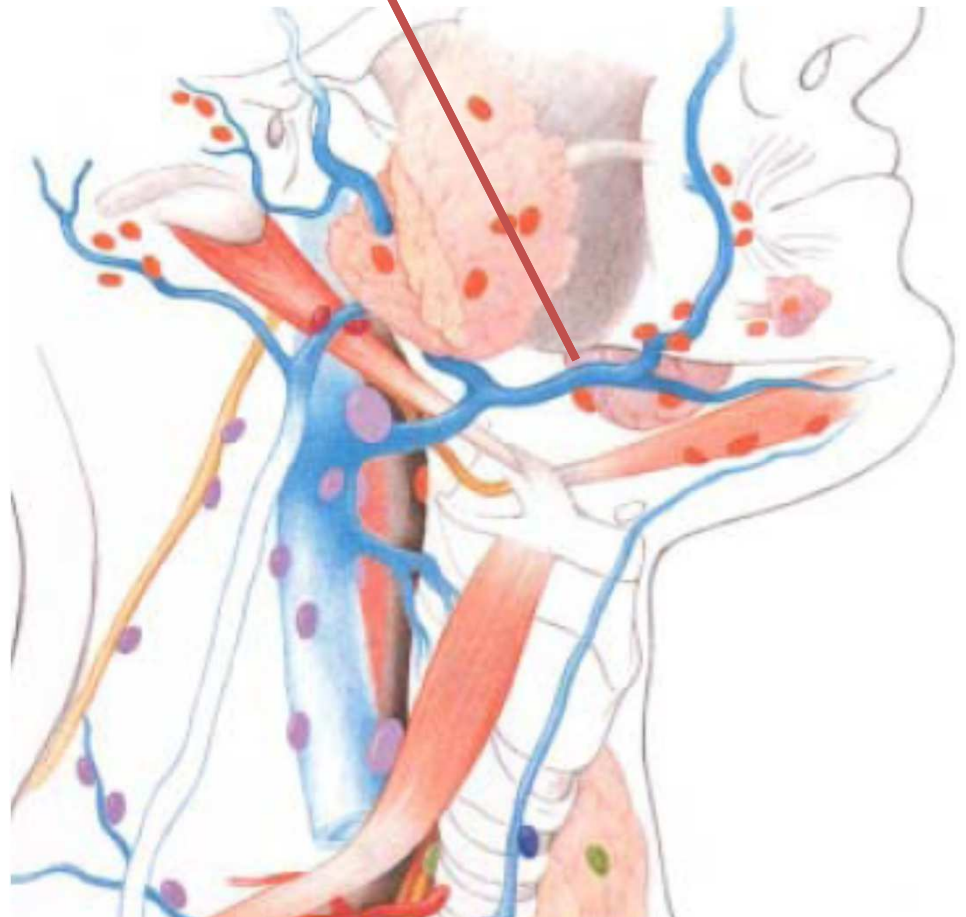
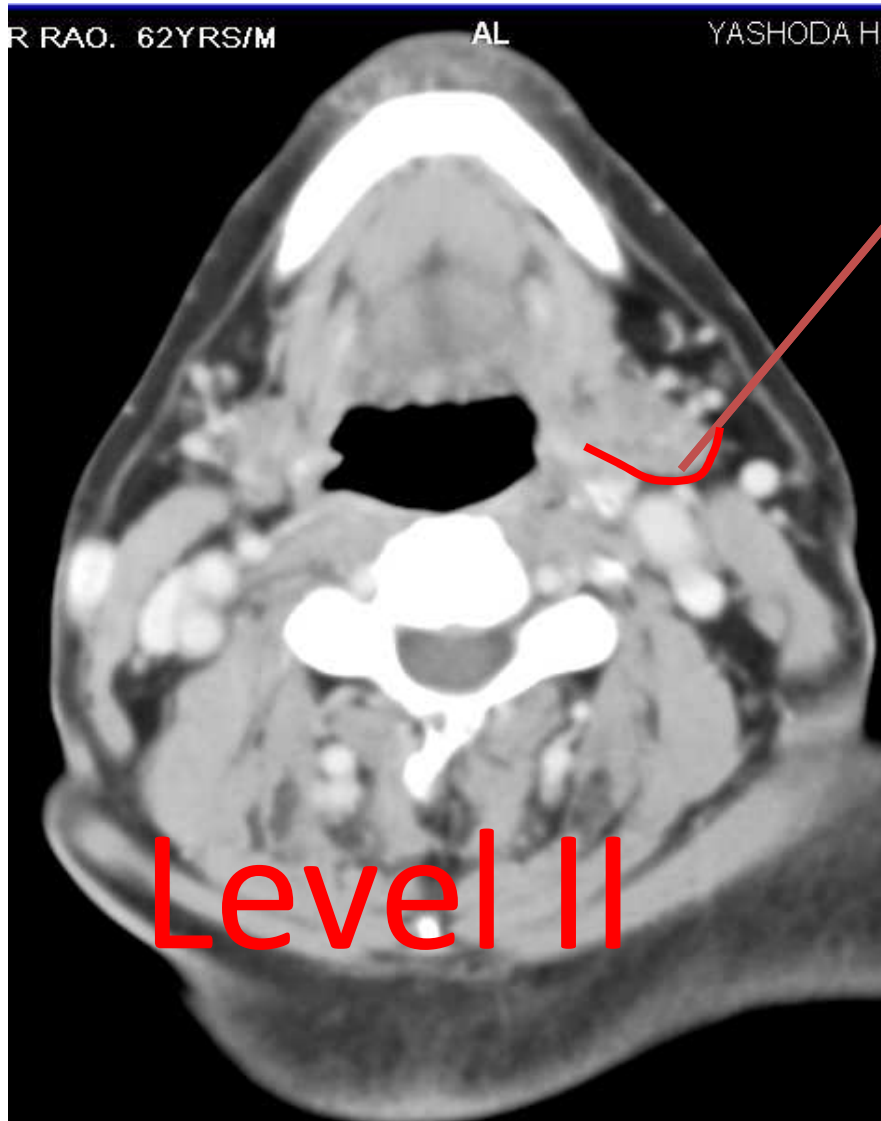


- the anterior edge of the carotid artery
- posterior edge of the submandibular gland,
- the posterior belly of the digastric muscle,

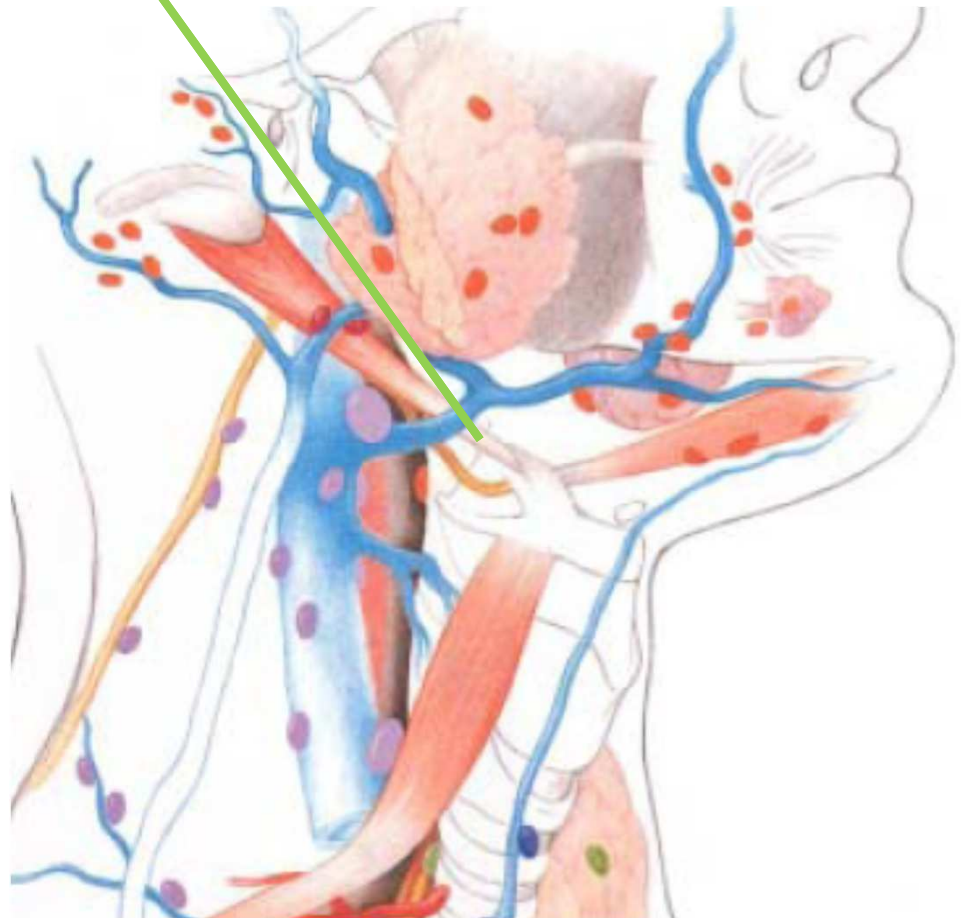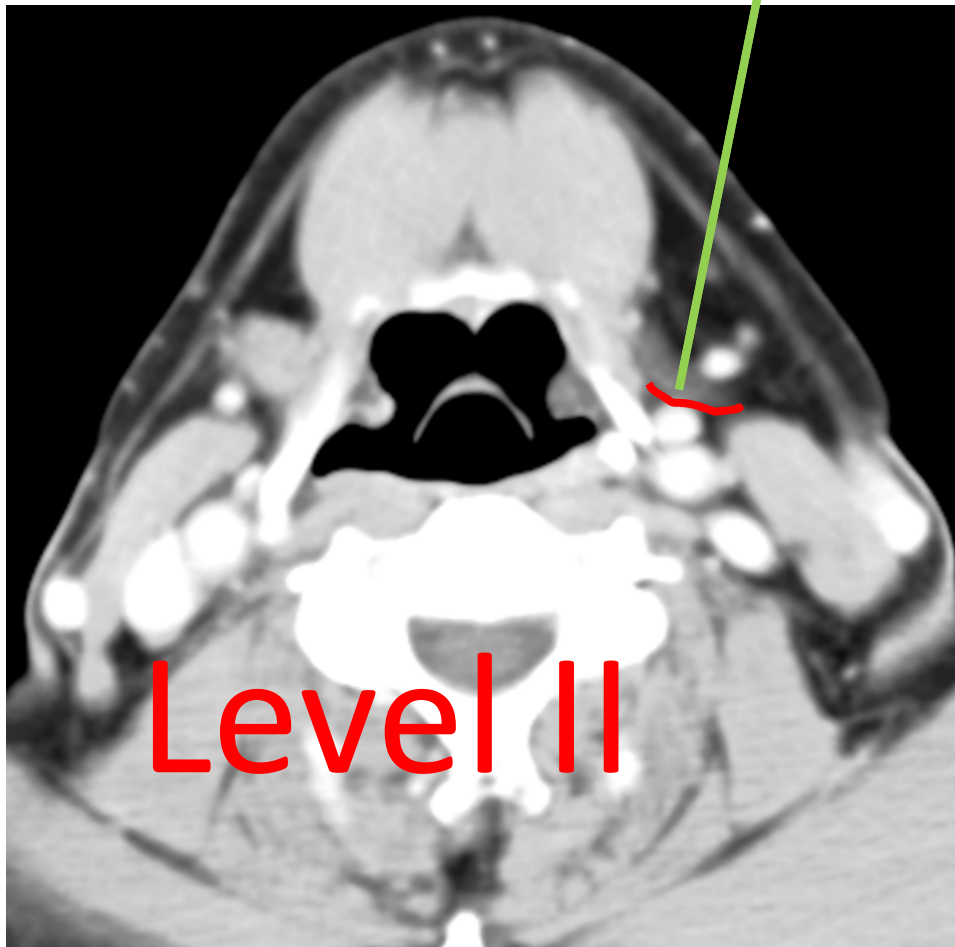
Anterior-> Anterior edge of the carotid artery



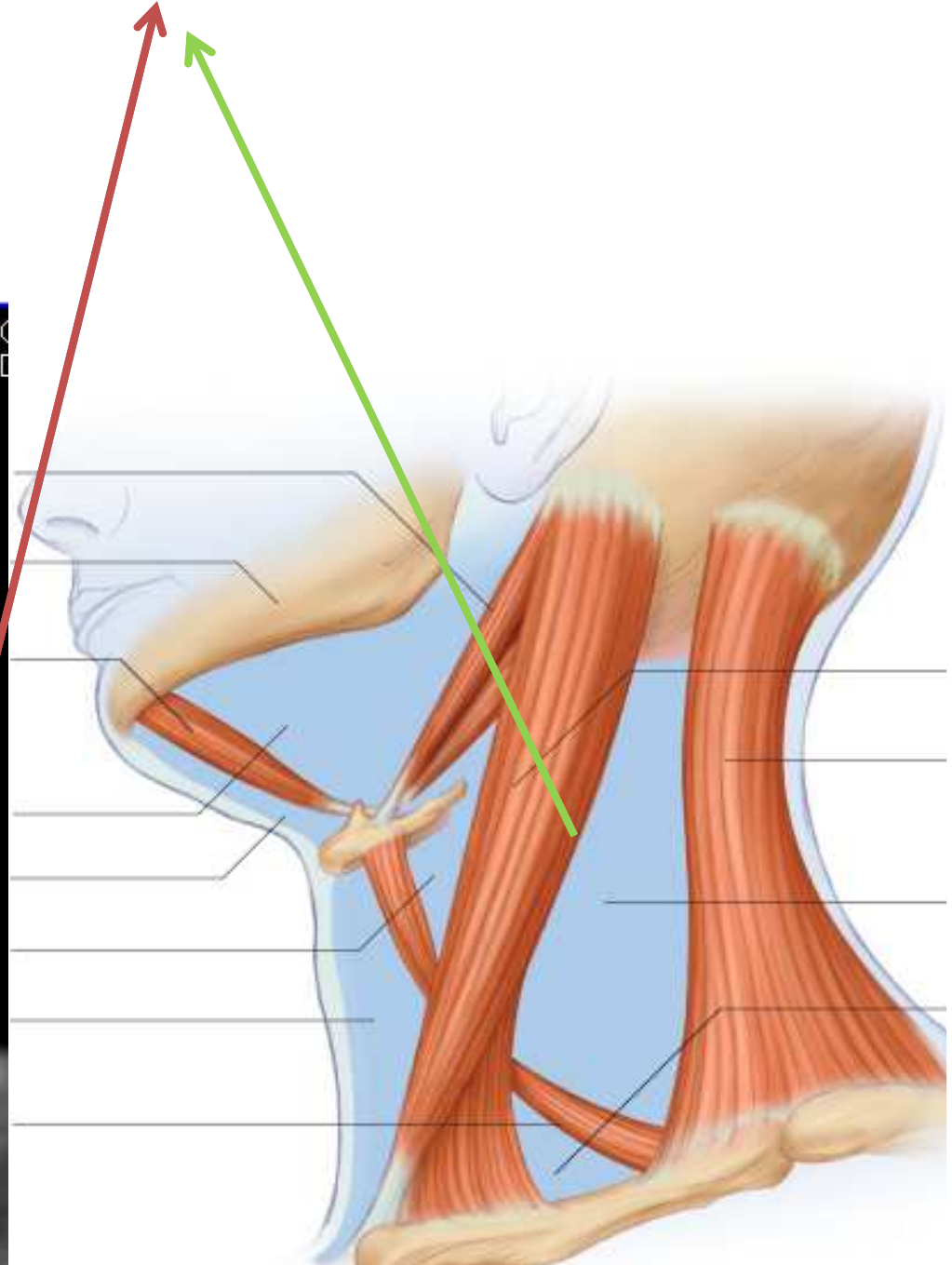
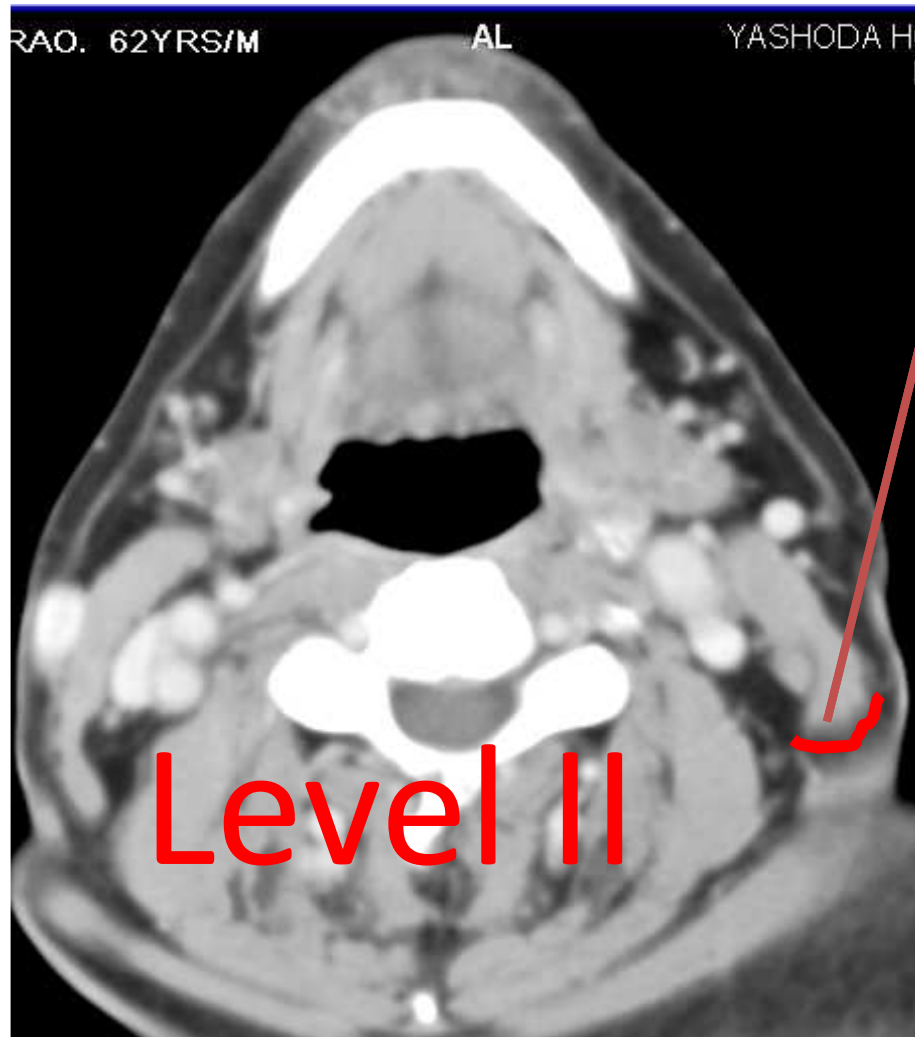
Anterior->Posterior edge of the submandibular gland,



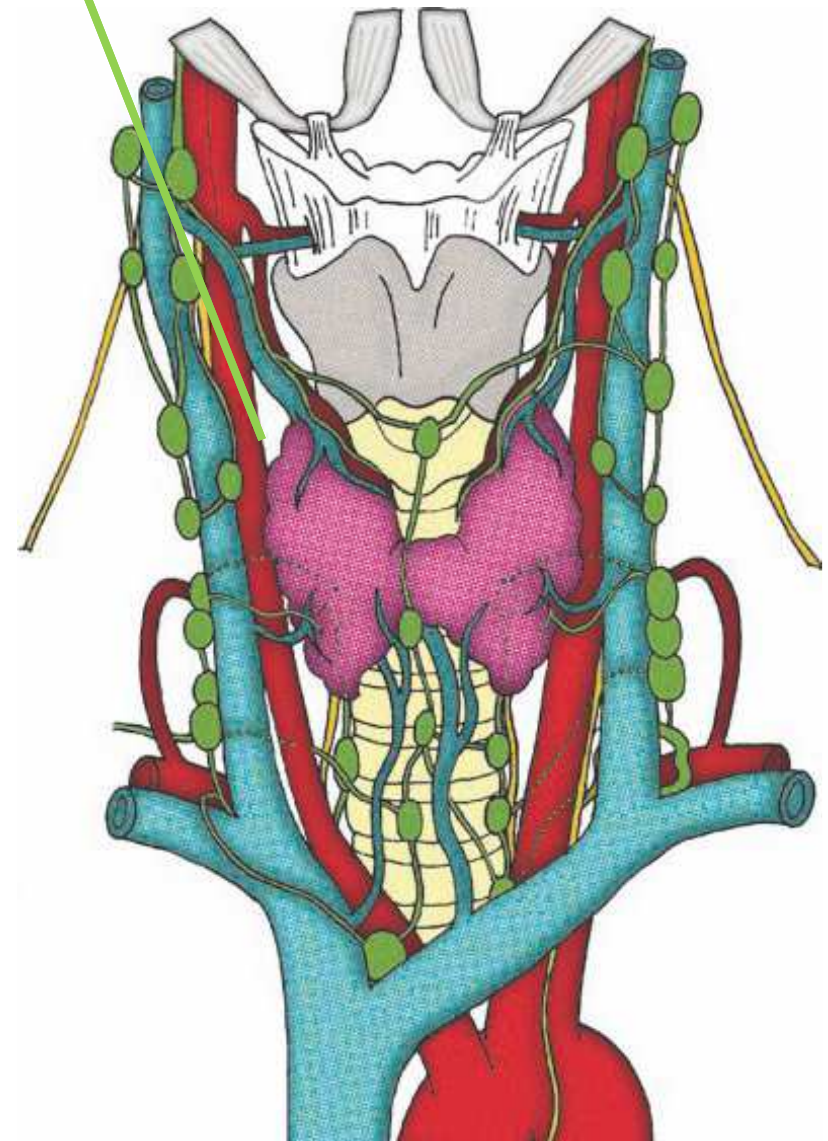
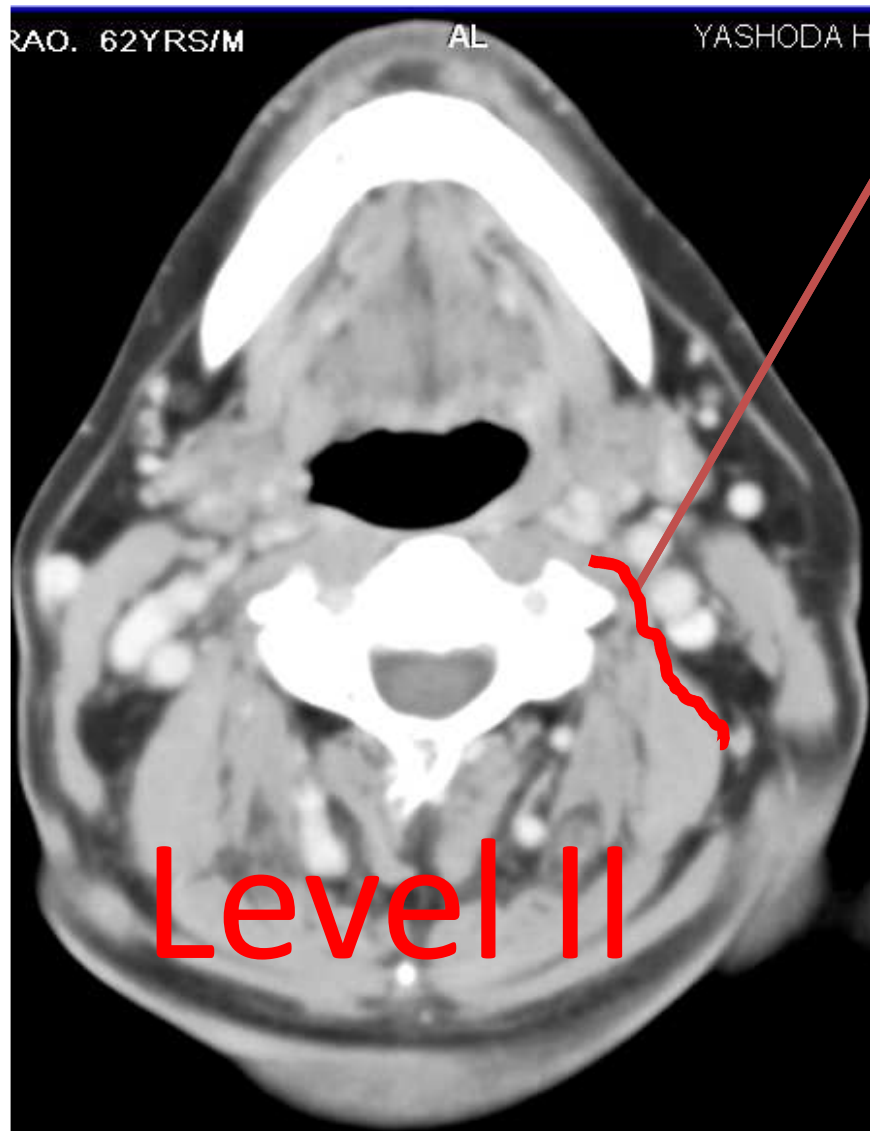
Anterior-> posterior belly of the digastric muscle,



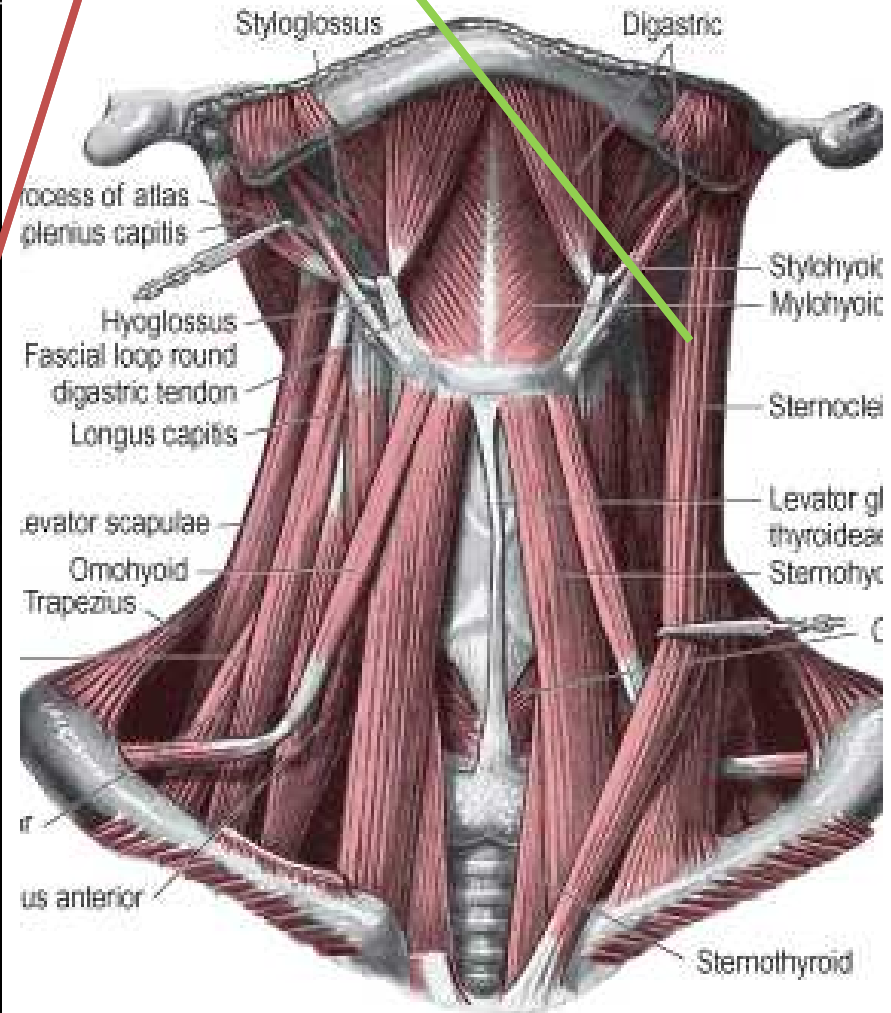
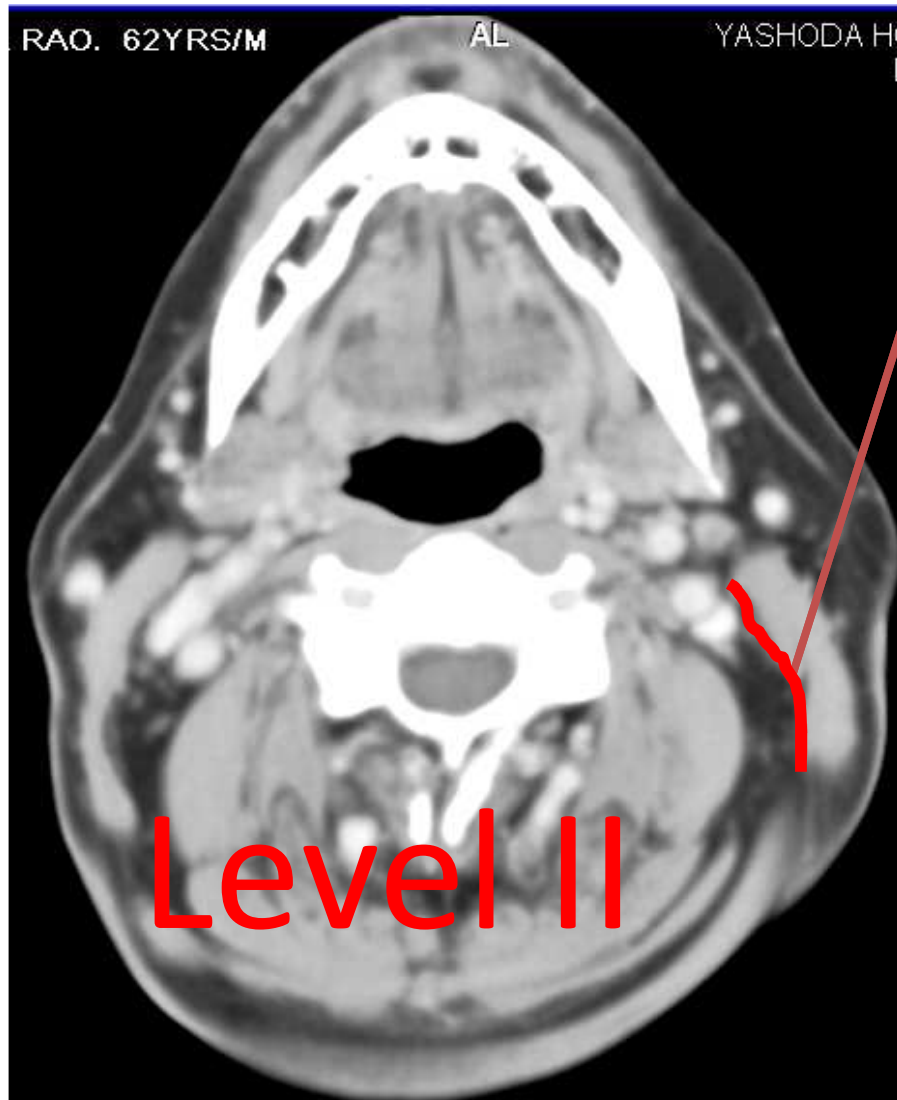
Posterior-> Posterior edge of the sternocleidomastoid (SCM) muscle,



Medial-> Medial edge of the carotid artery and the paraspinal muscles (levator scapulae and splenius capitis)



Lateral-> Medial edge of the SCM



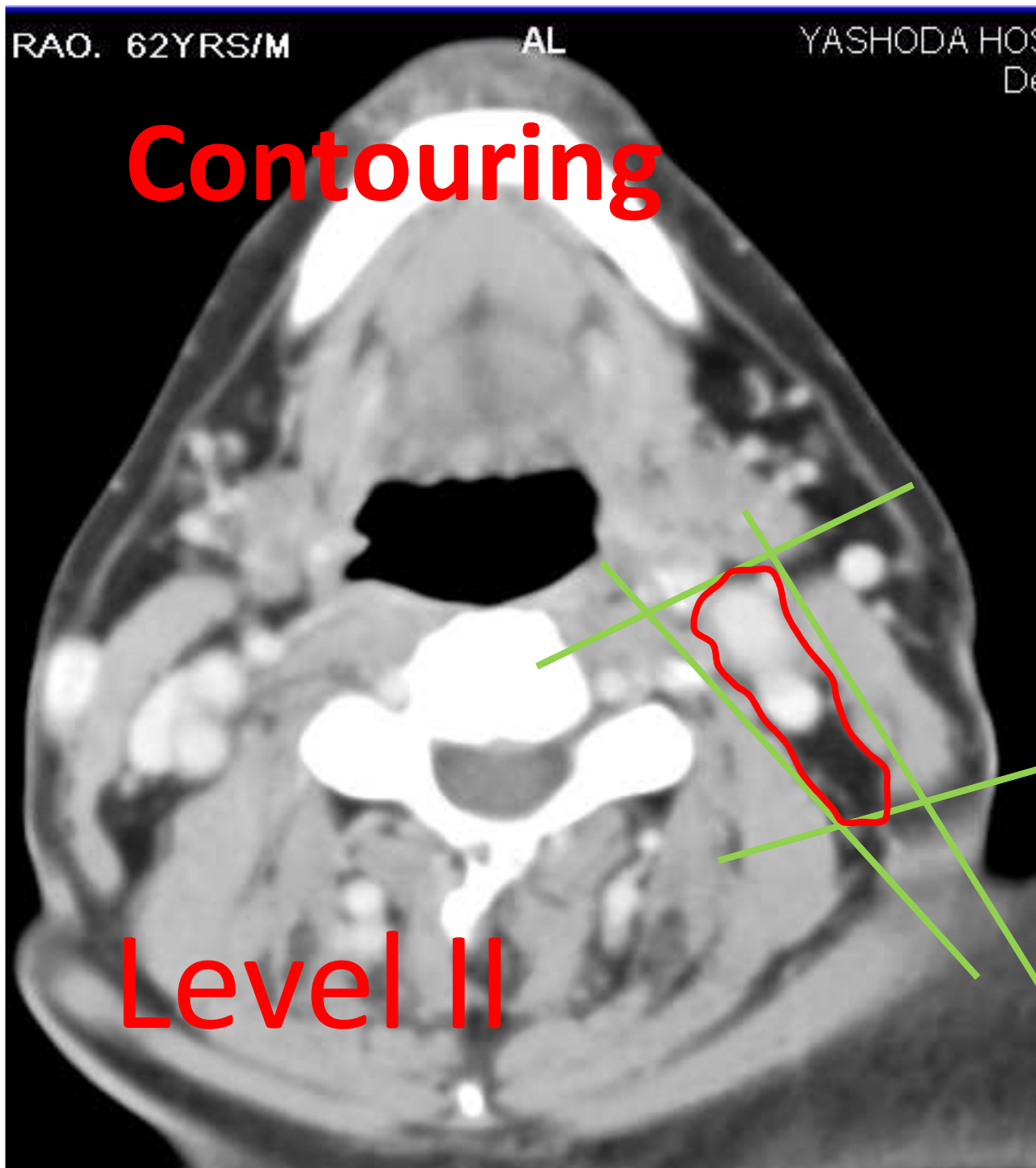
RAO. 62YRS/M

AL

YASHODA HOS
De

Contouring

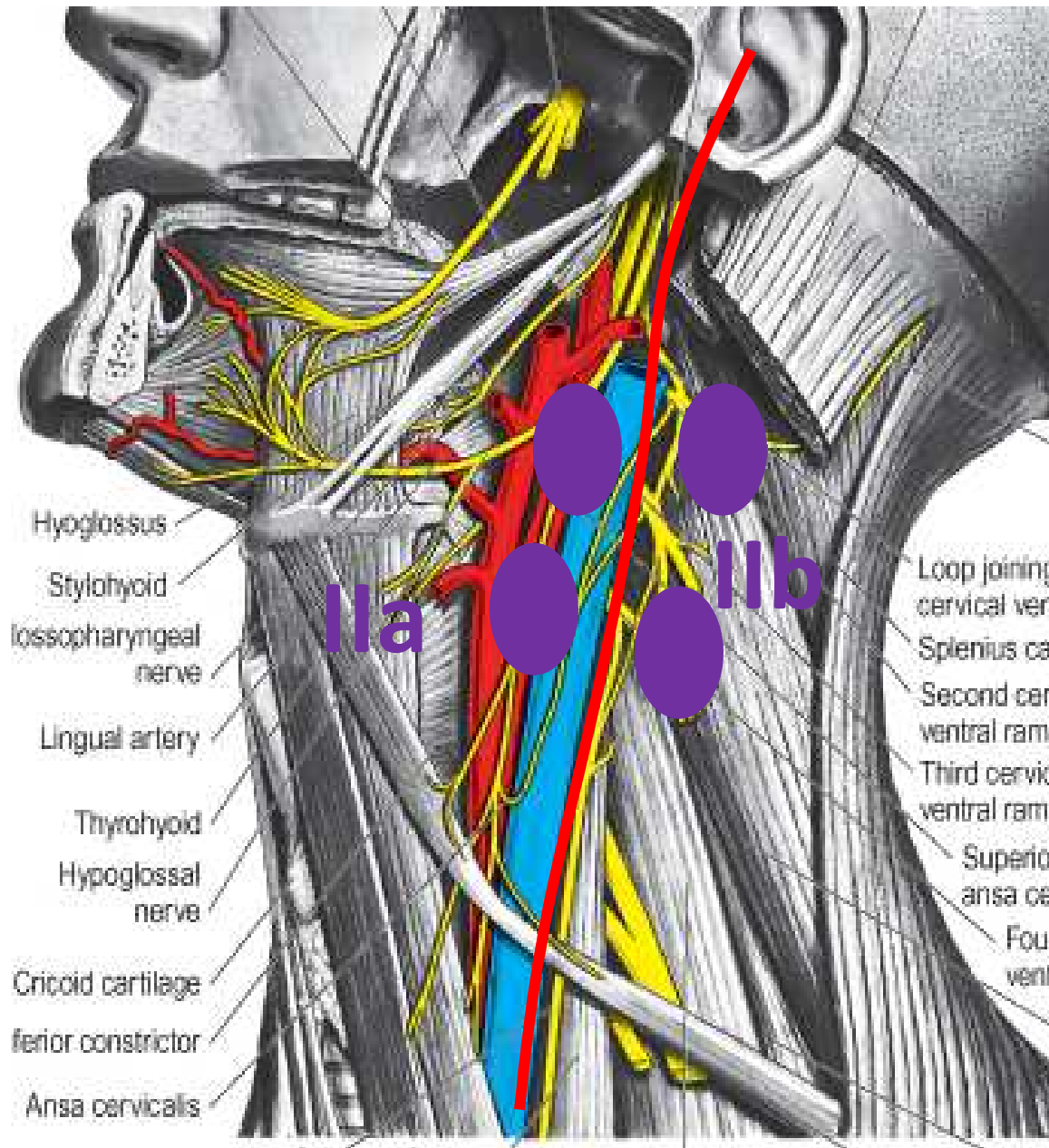
Level II



Primary for II

- Nasal cavity.
- Oral cavity.
- Oropharynx.
- Hypopharynx.
- Larynx.
- Major salivary glands.
- Nasopharynx,

Sub division of Level II

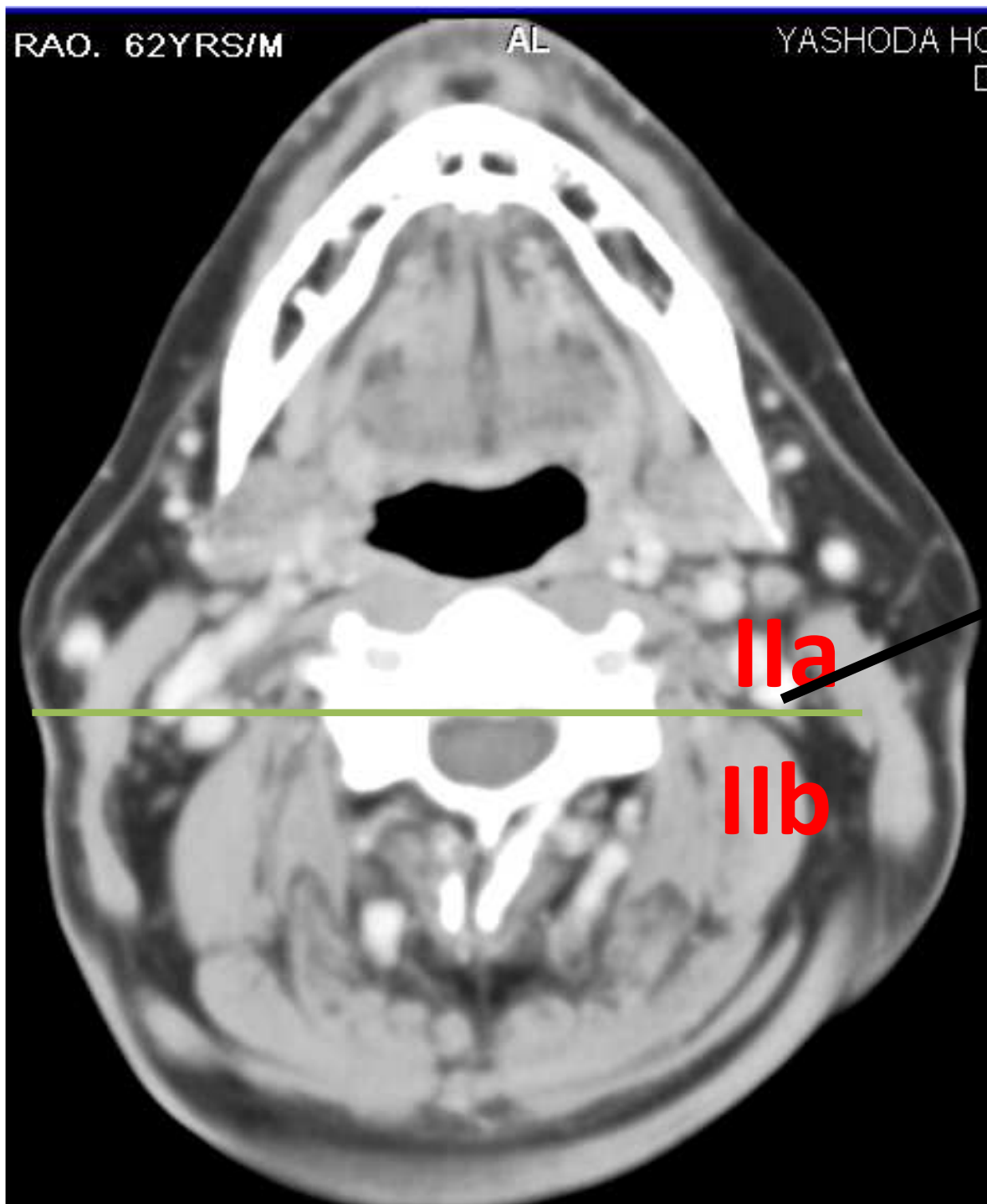


- Level II is further subdivided into two compartments.
 - IIa
 - IIb
- Surgeons demarcate between the two by spinal accessory nerve (SAN).
- From a radiological point of view, the posterior edge of the IJV is taken as the boundary between levels IIa and IIb.

RAO. 62YRS/M

AL

YASHODA HO
D



IIa

IIb

IJV

Level III

- **contains the middle jugular lymph nodes located around the middle third of the IJV.**
- **It is the caudal extension of level II**
- **Primary.**

Oral cavity.

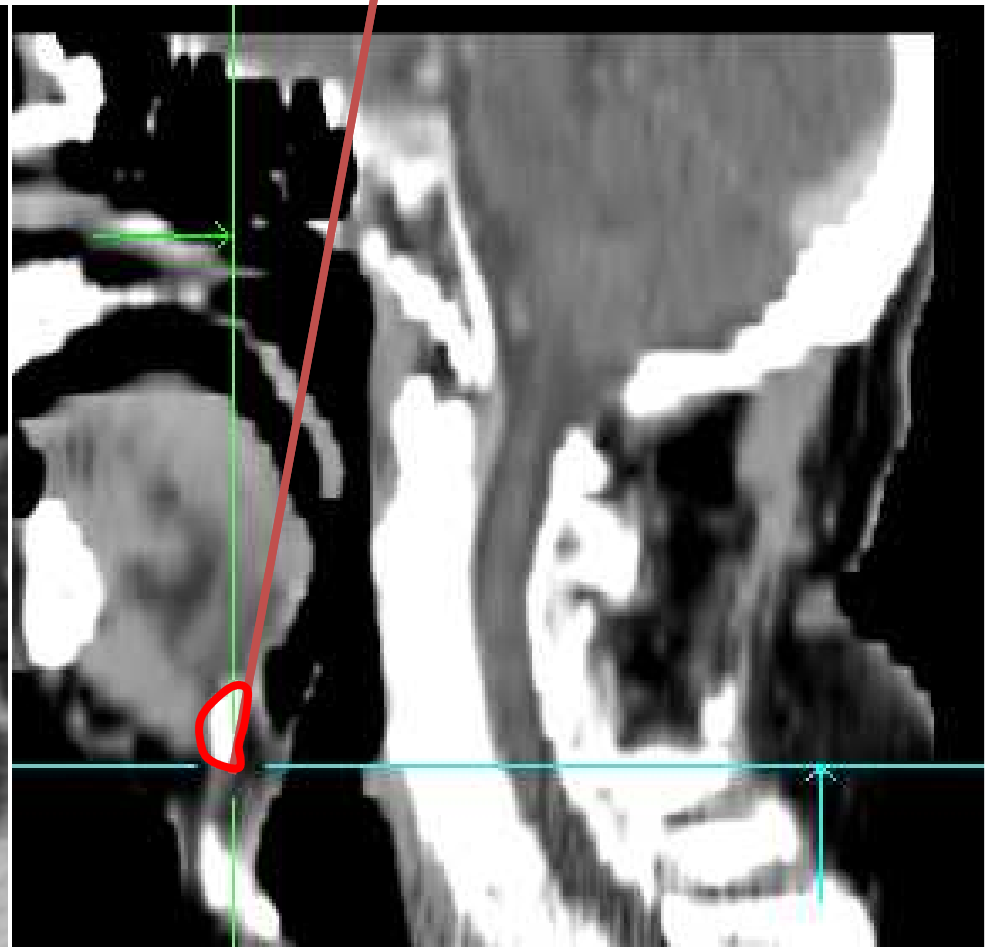
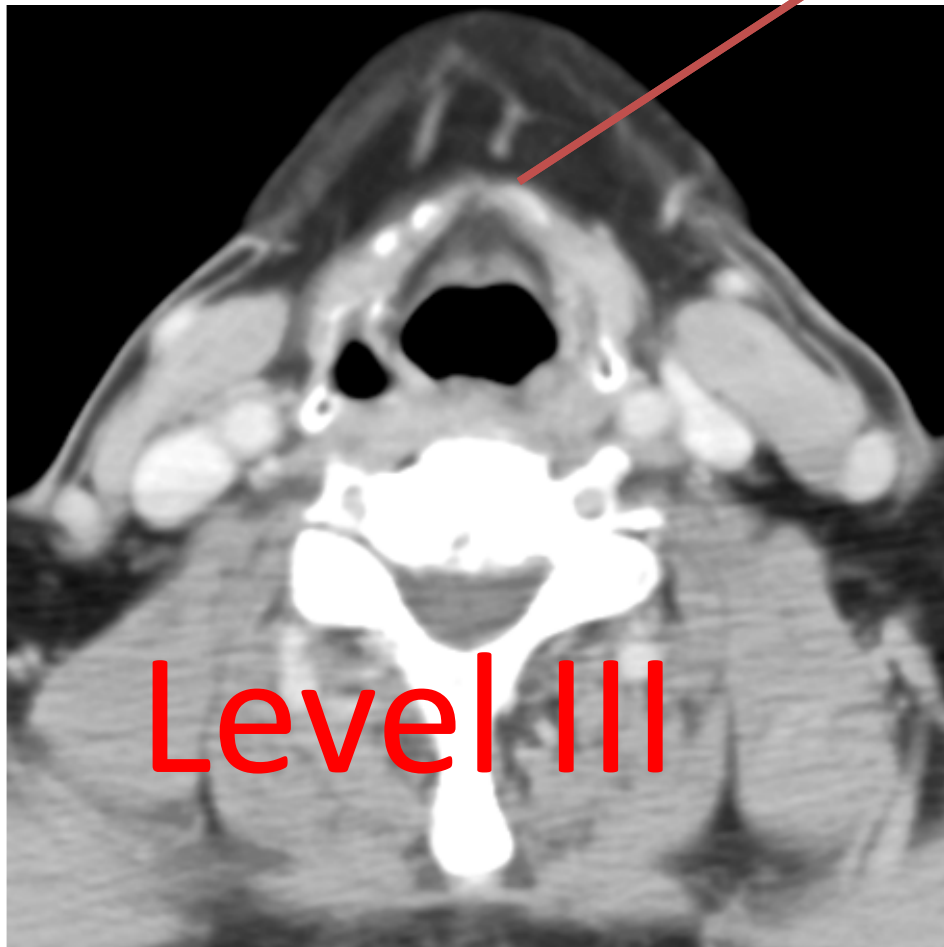
Oropharynx.

Hypopharynx.

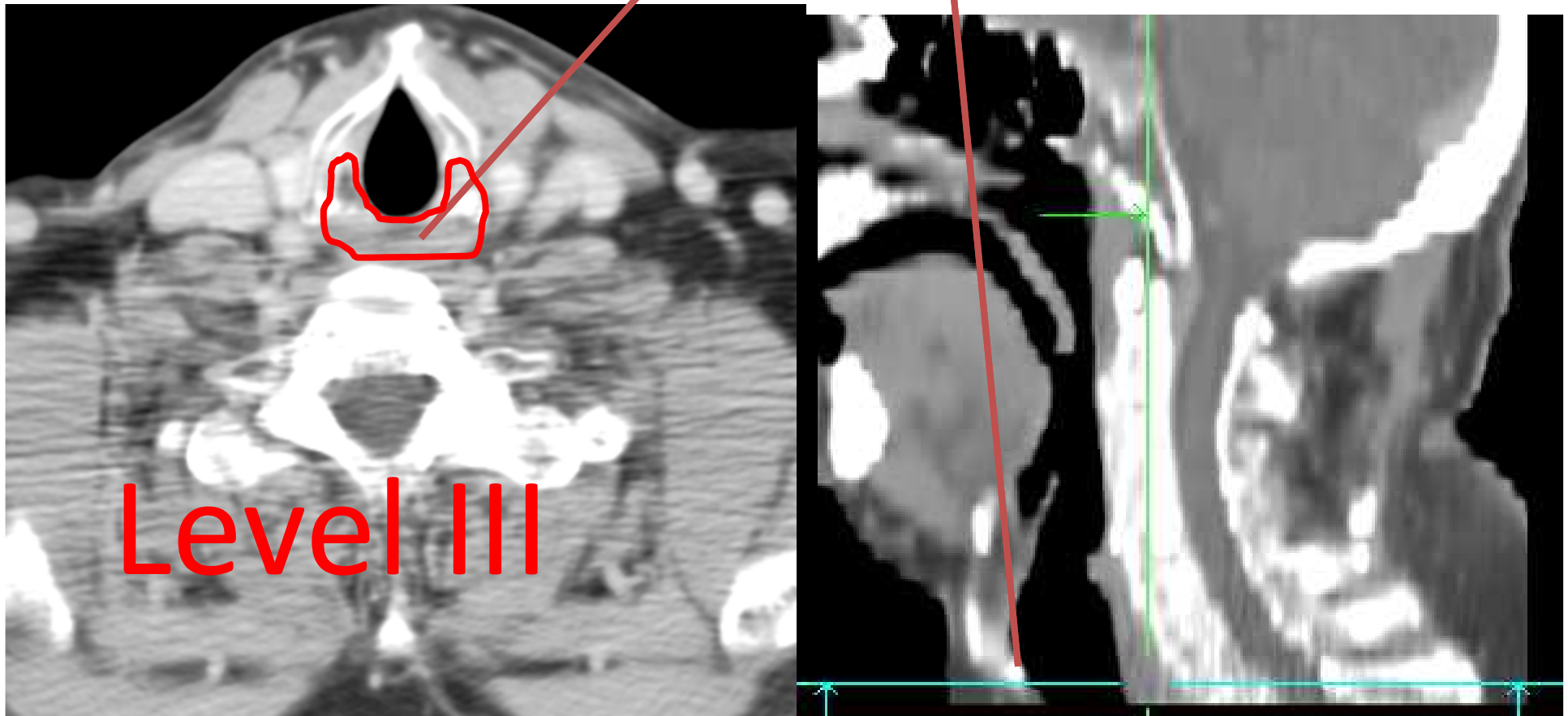
Larynx.

Nasopharynx,

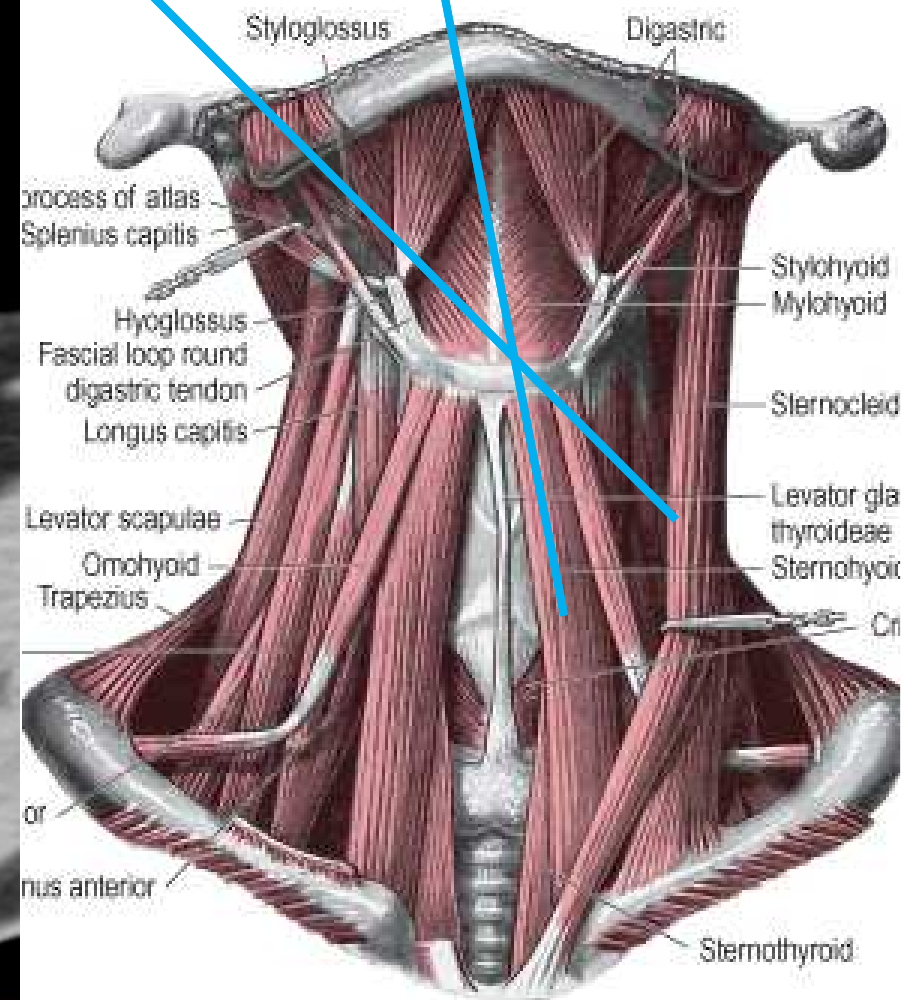
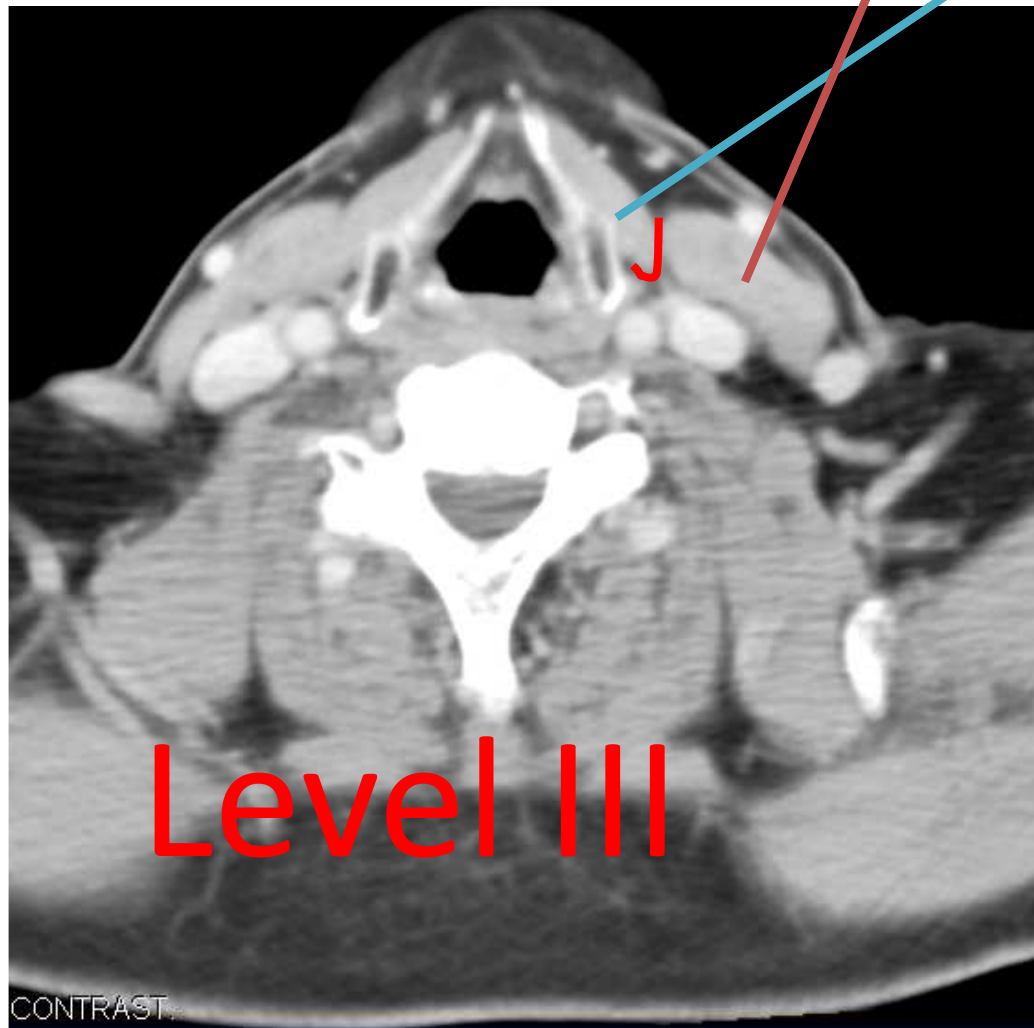
Cranial-> caudal edge of body of the hyoid bone.



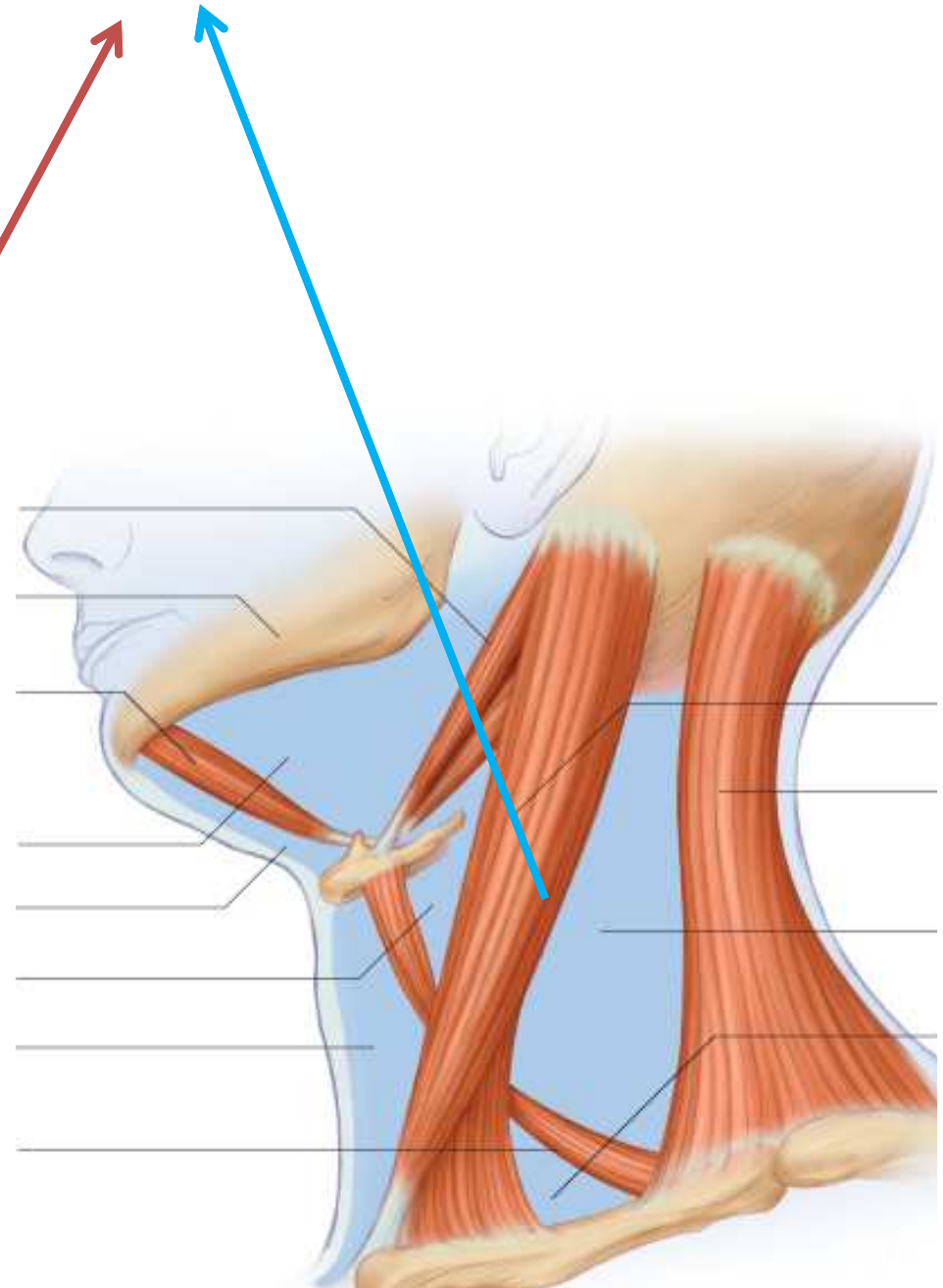
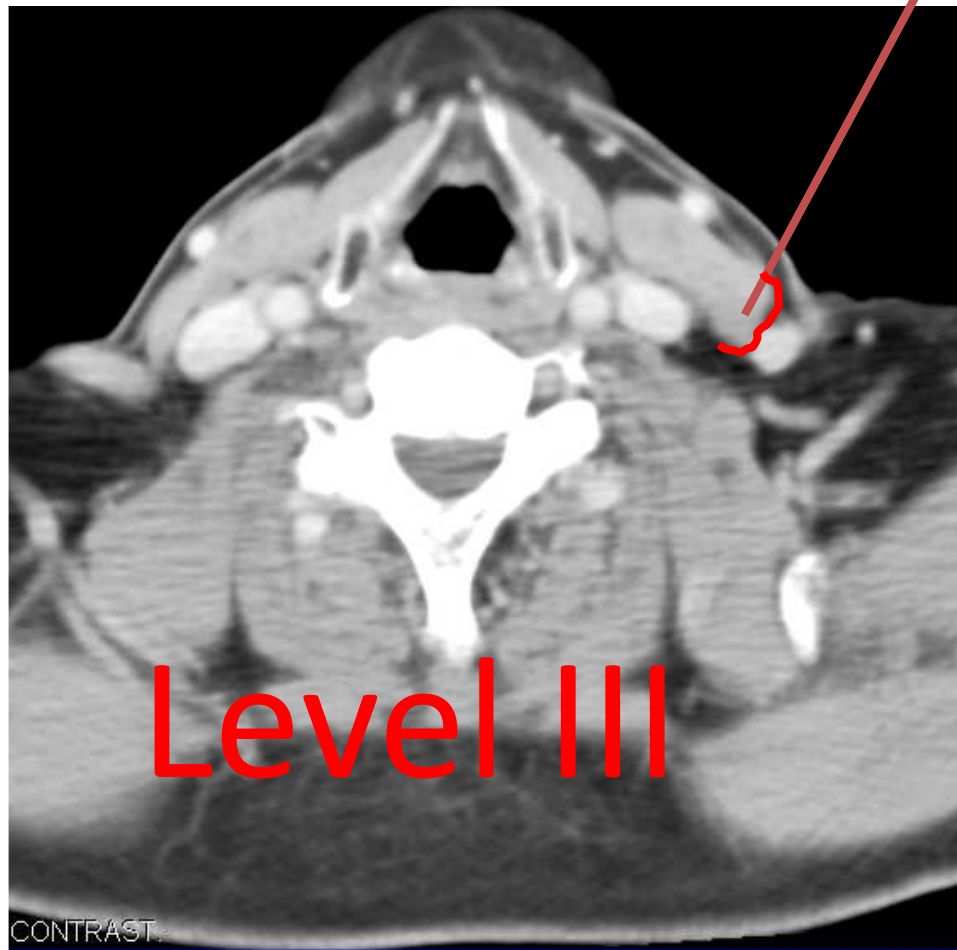
Caudal-> Caudal edge of the cricoid cartilage.



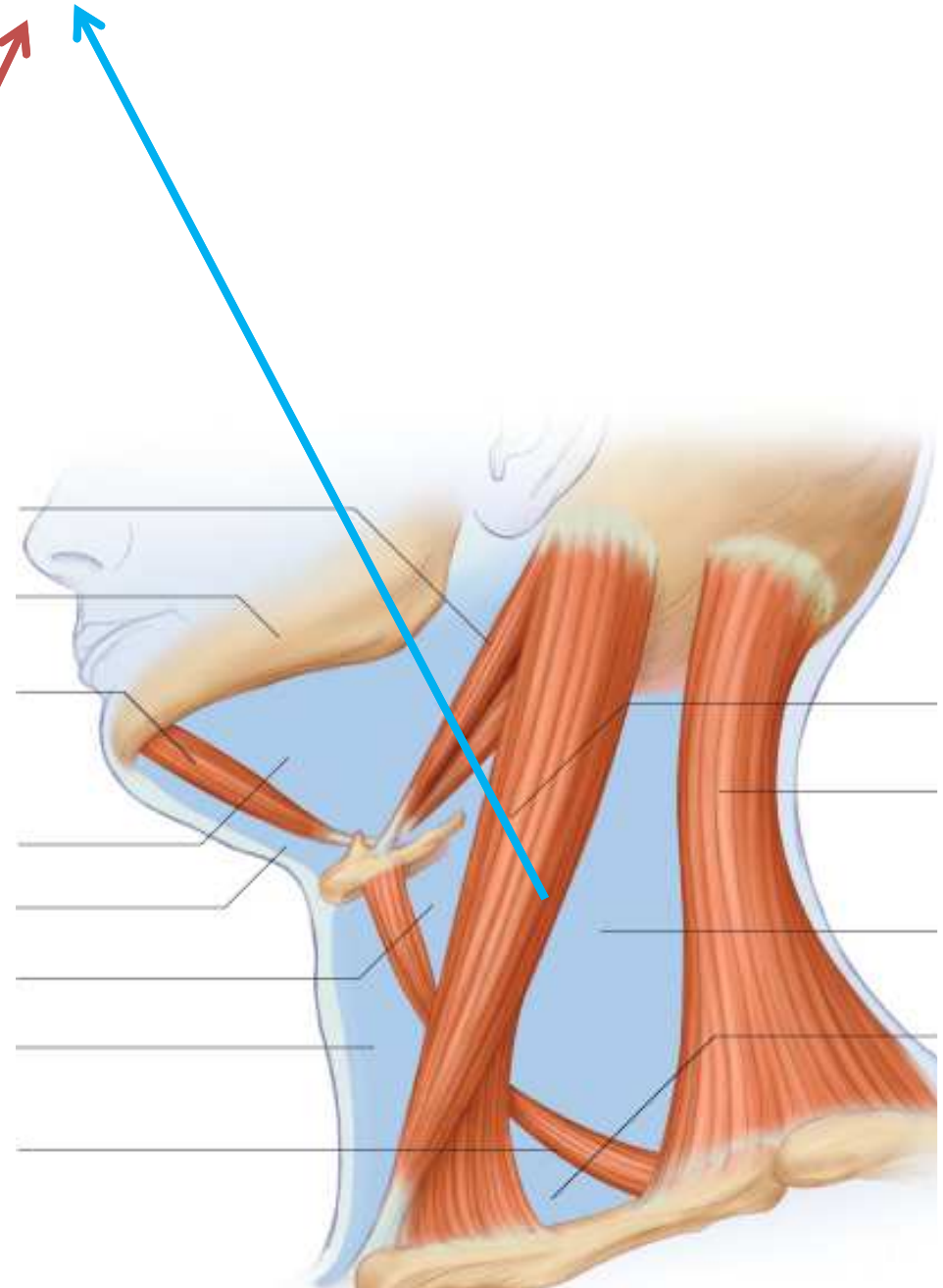
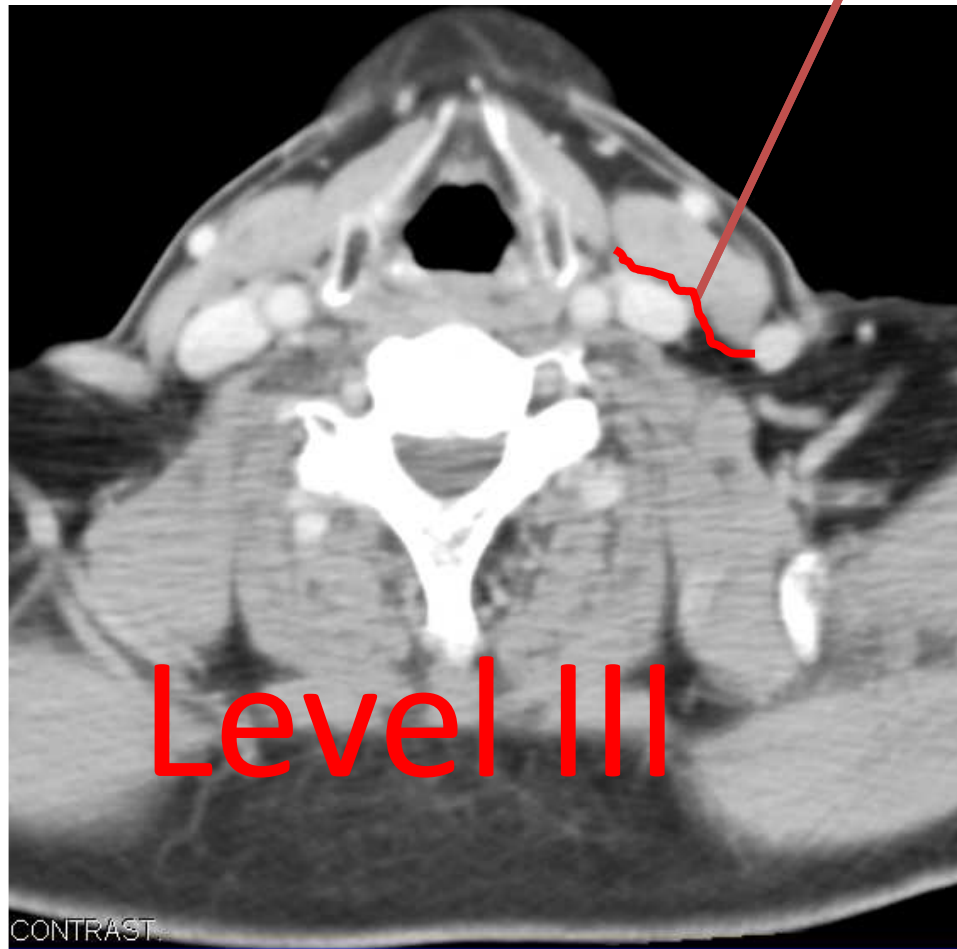
Anterior-> Posterolateral edge of the sternohyoid muscle and the anterior edge of the SCM muscle,



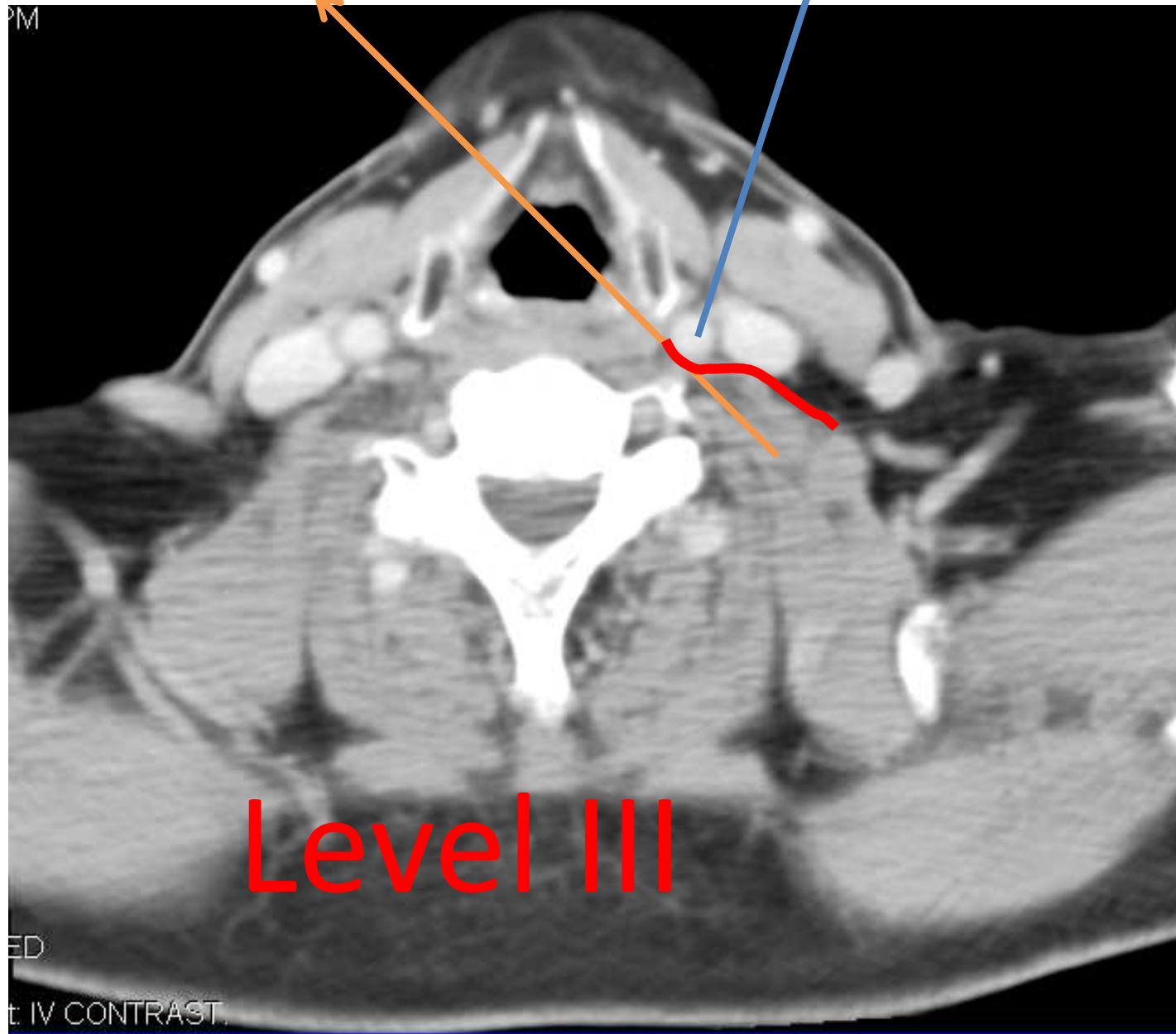
Posterior-> Posterior edge of the SCM muscle



Lateral-> Medial edge of the SCM muscle

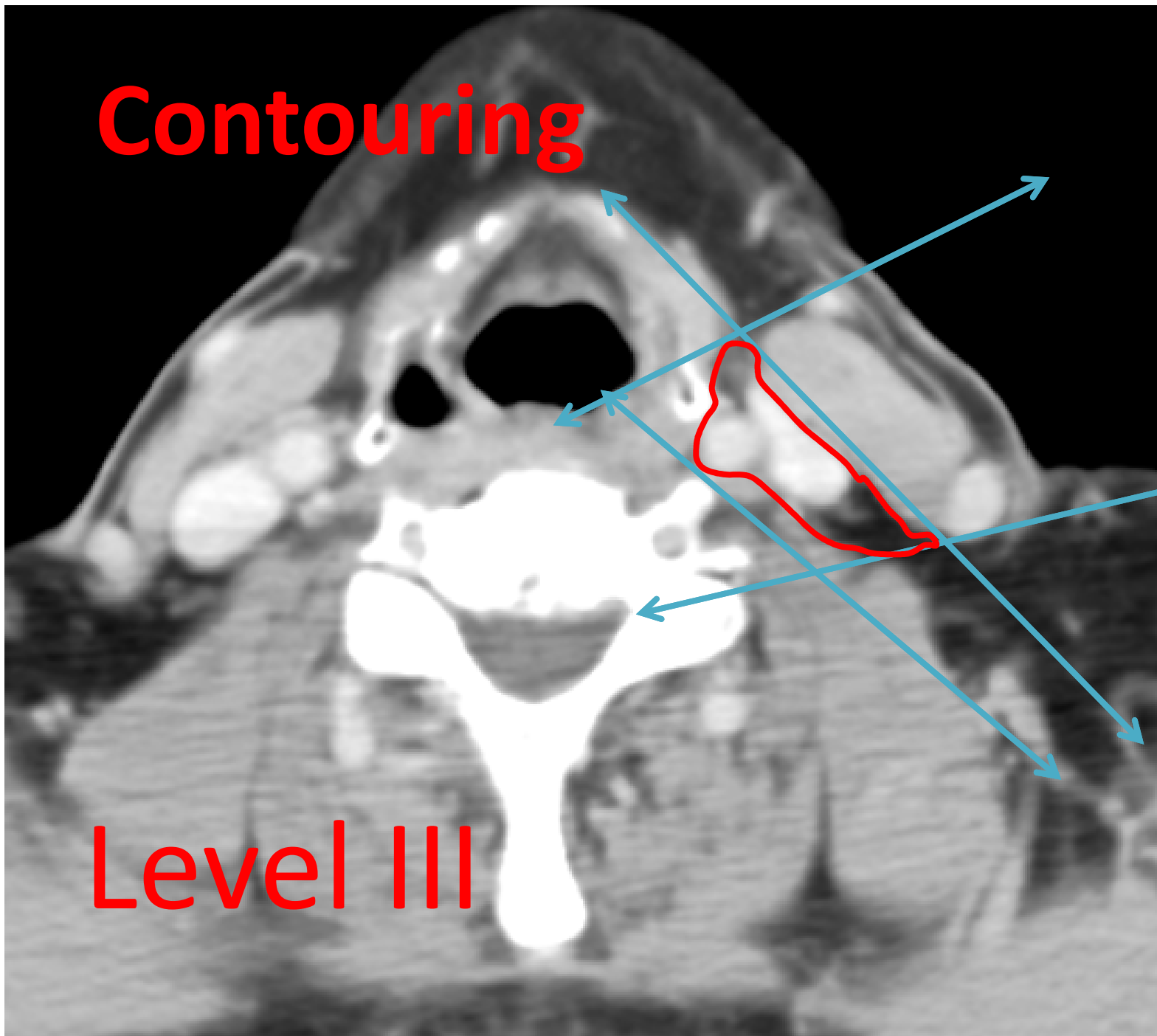


Medial-> Medial edge of the internal carotid artery and the paraspinal muscles (scaleni).



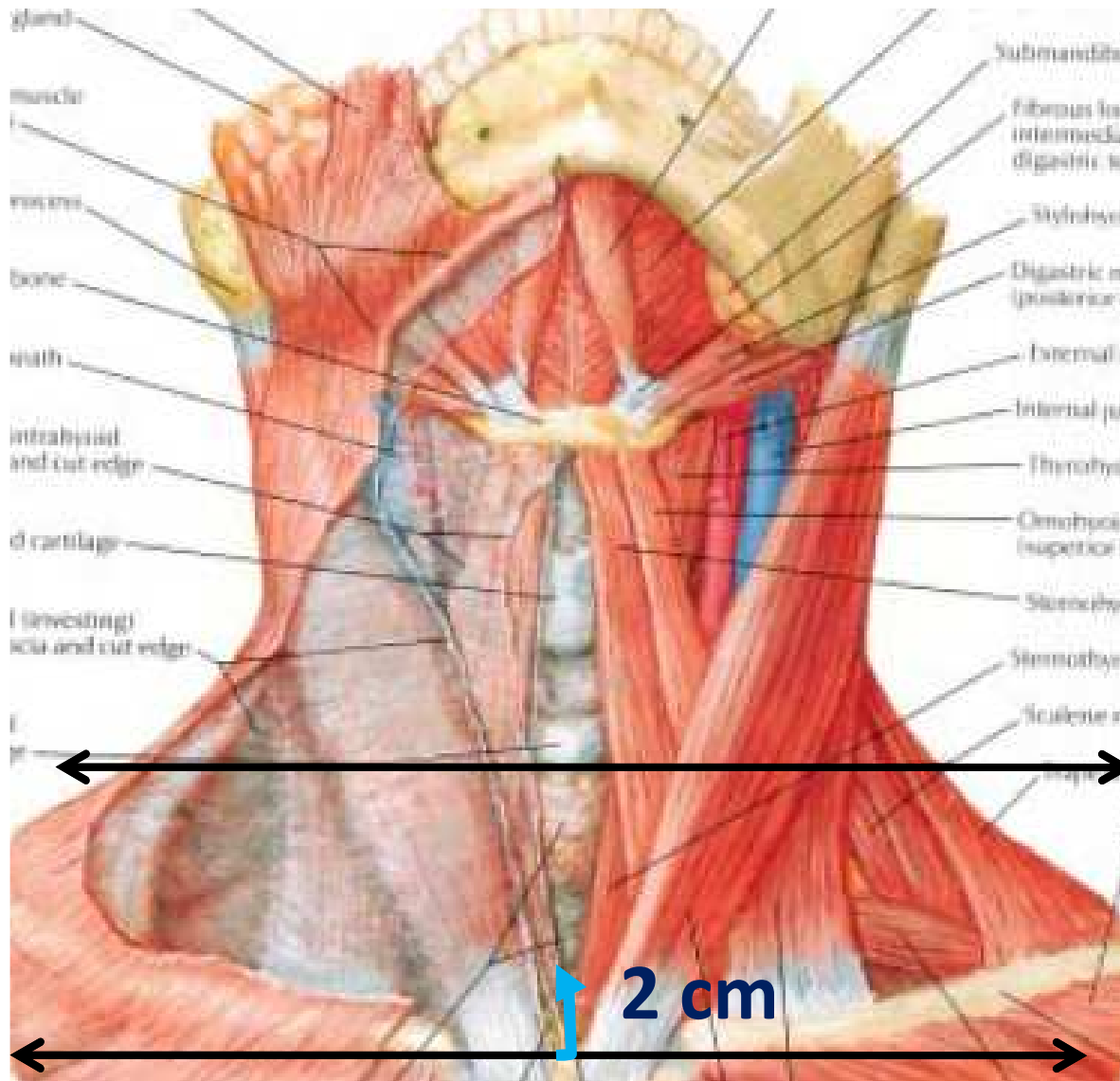
Contouring

Level III

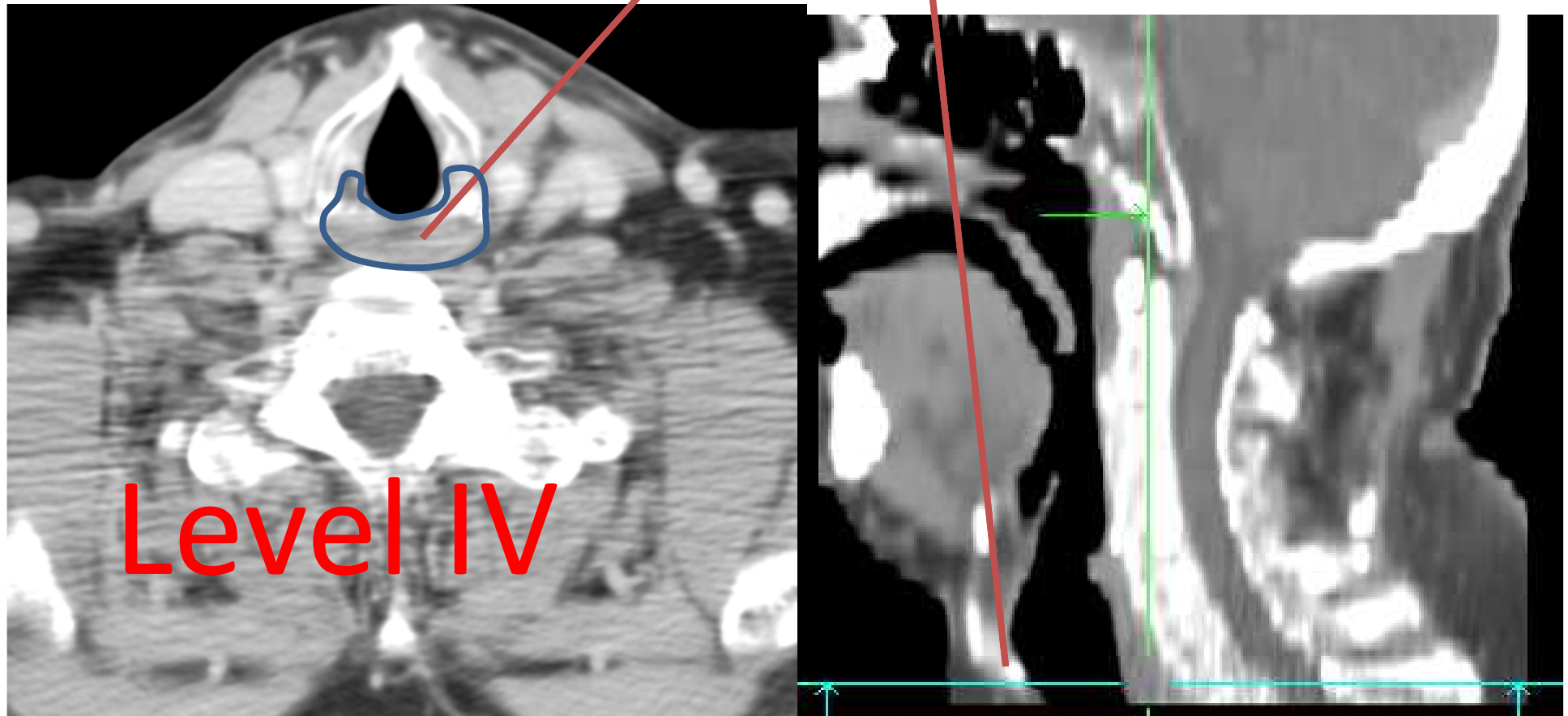


Level IV

- includes the lower jugular lymph nodes located around the inferior third of the IJV.
- According to Robbins, it extends from the caudal limit of level III to the clavicle.
- But since surgeons never dissect up to clavicle so consensus is that the caudal limit is 2cm cranial to the cranial edge of sterno-clavicular joint.

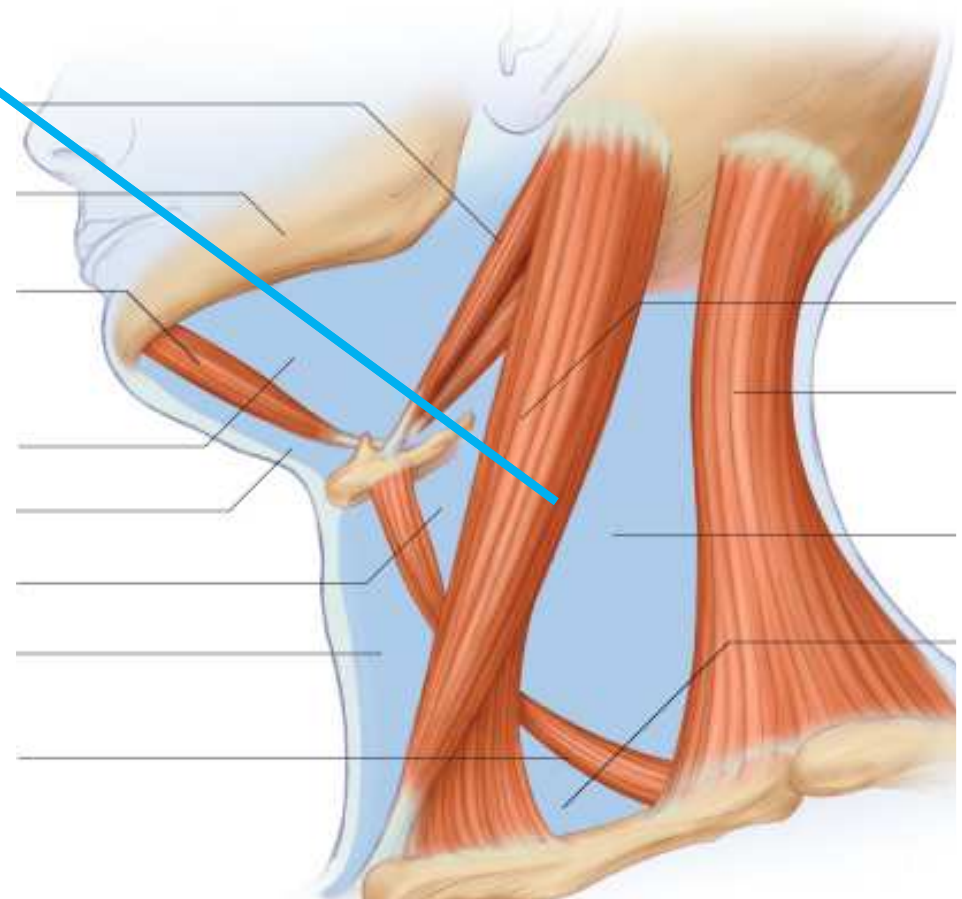
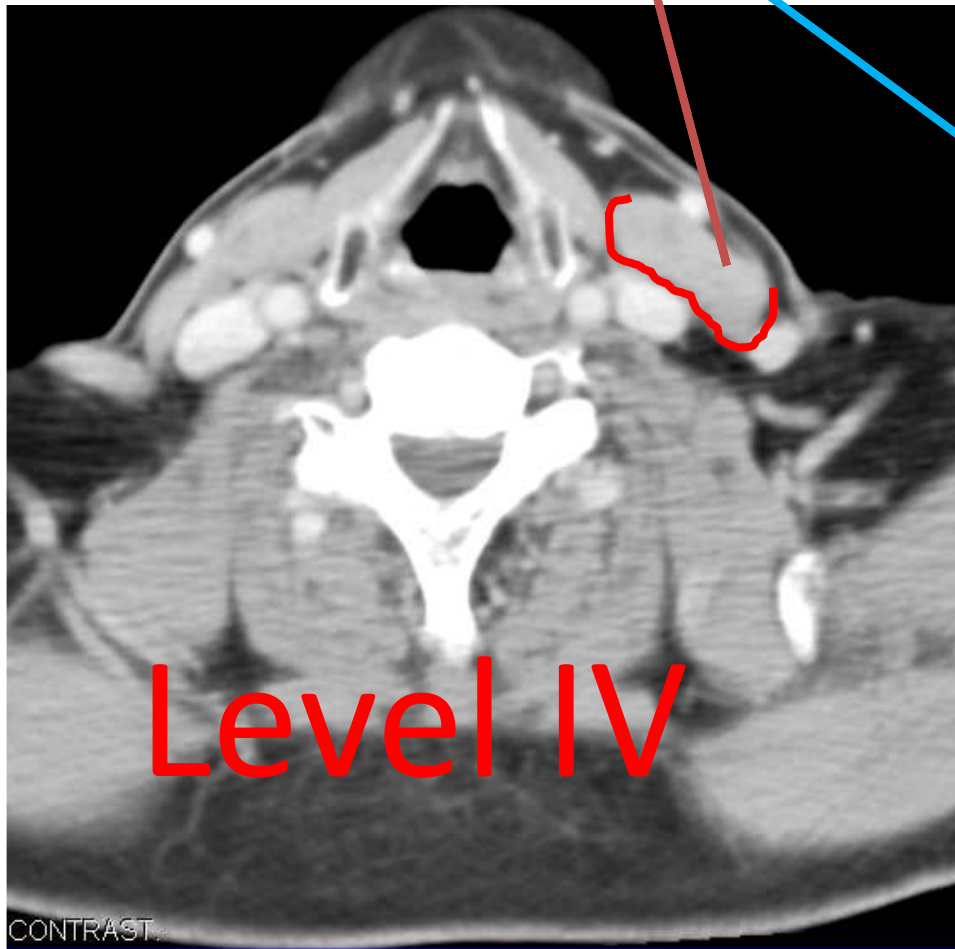


Cranial-> Caudal edge of the cricoid cartilage.

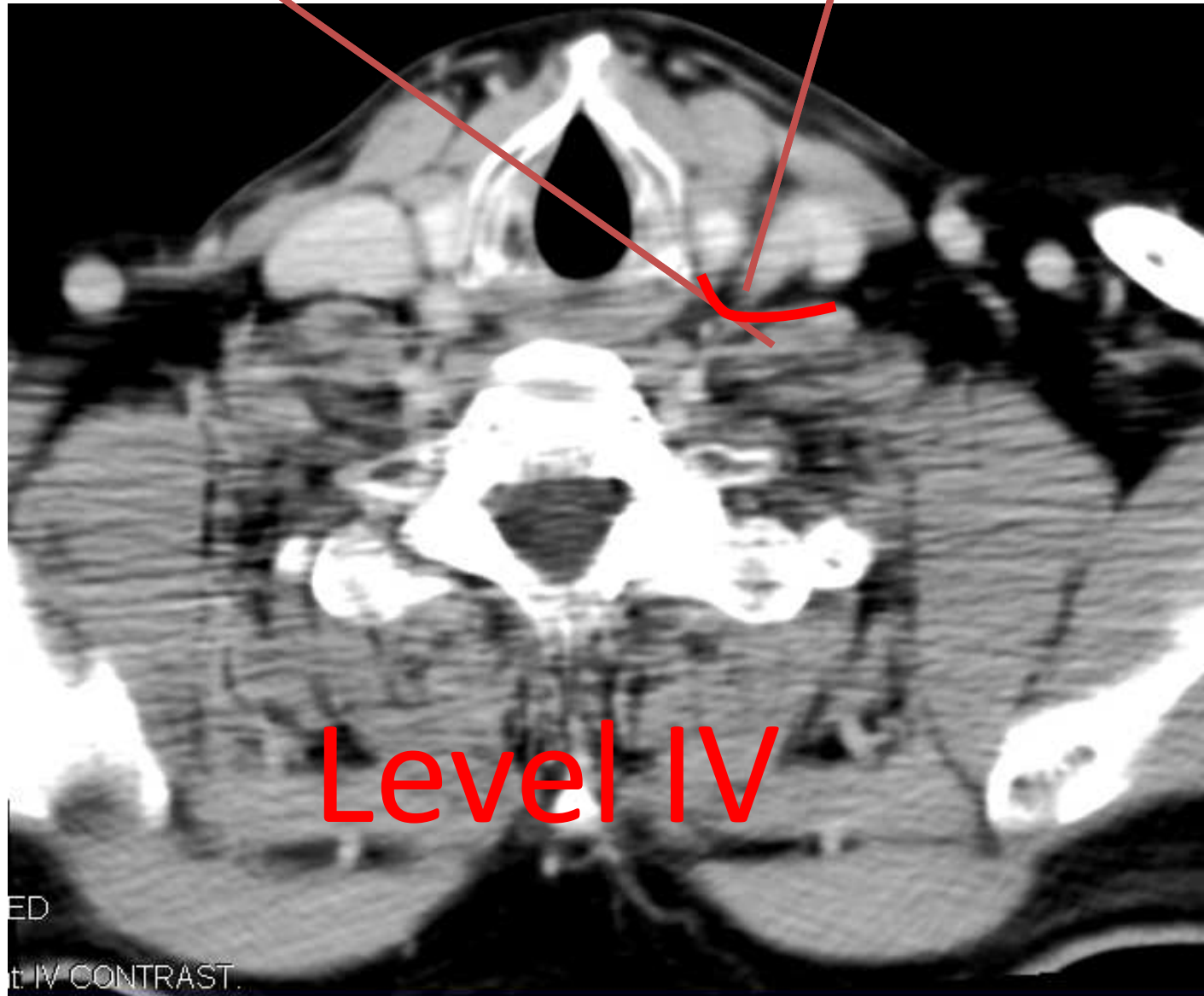


Anterior
Posterior
Lateral.

Anterior edge , posterior edge and medial edge of the SCM muscle, respectively

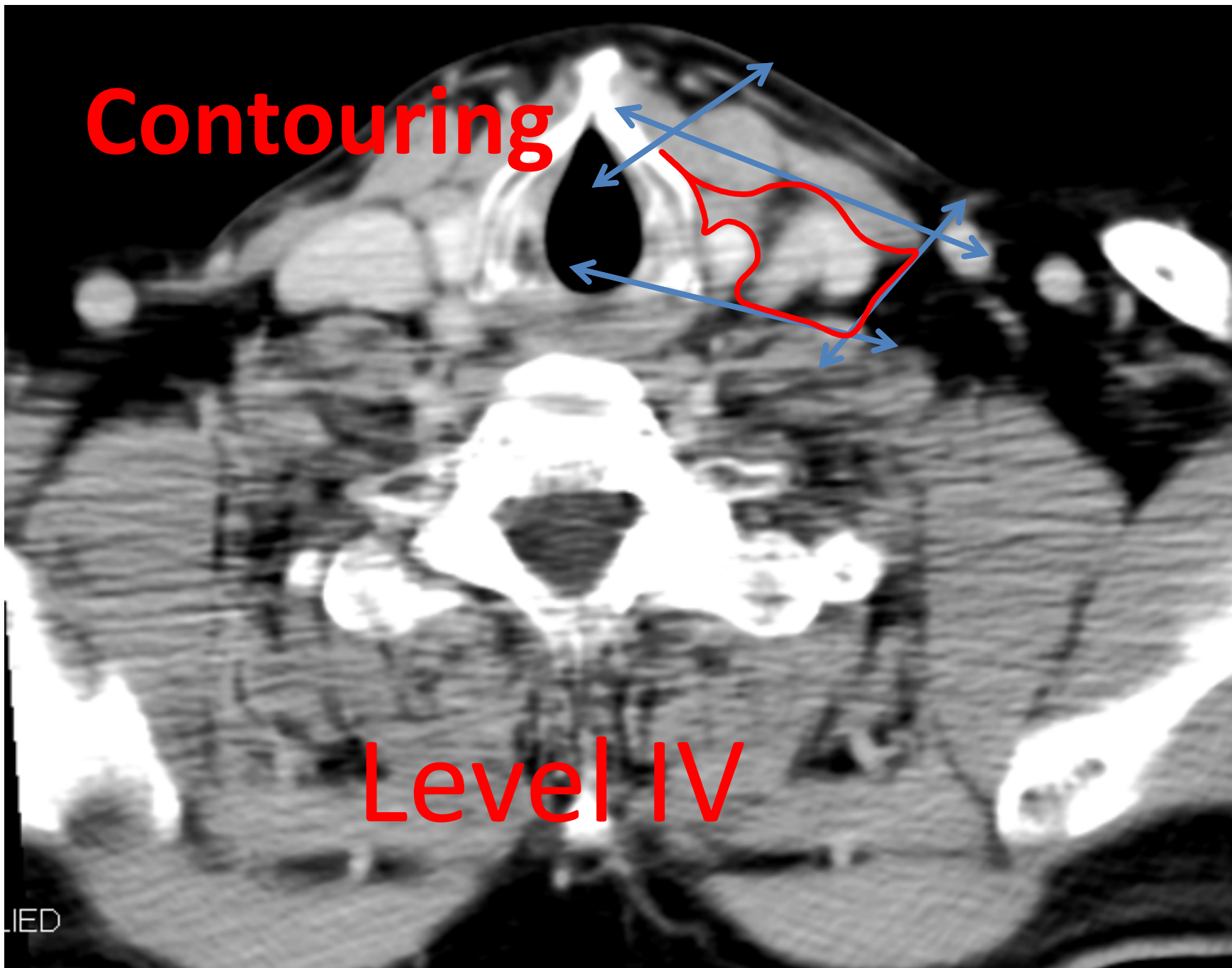


Medial-> Medial edge of the internal carotid artery
and the paraspinal muscles (scaleni)



Contouring

Level IV

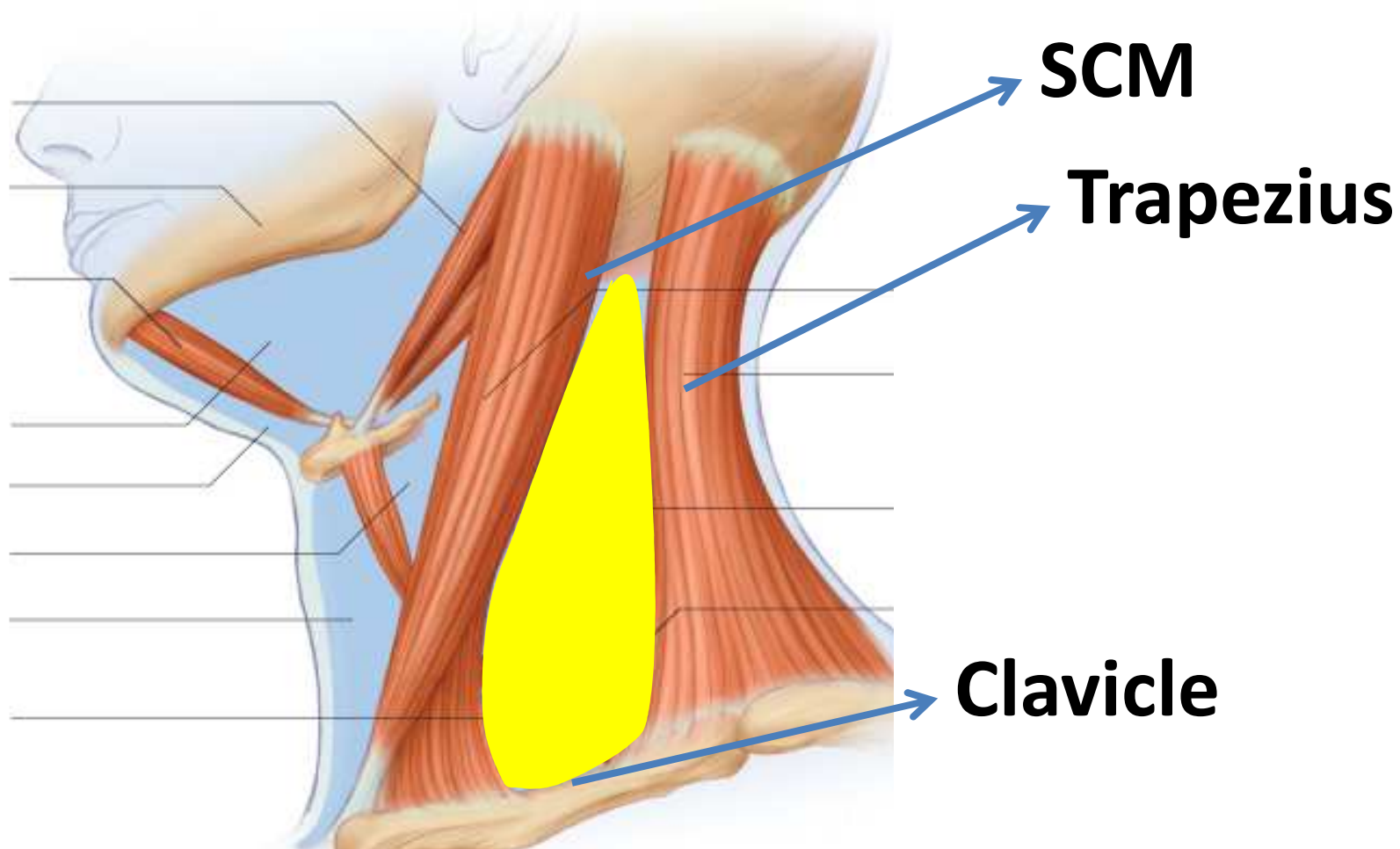


Primary for level IV

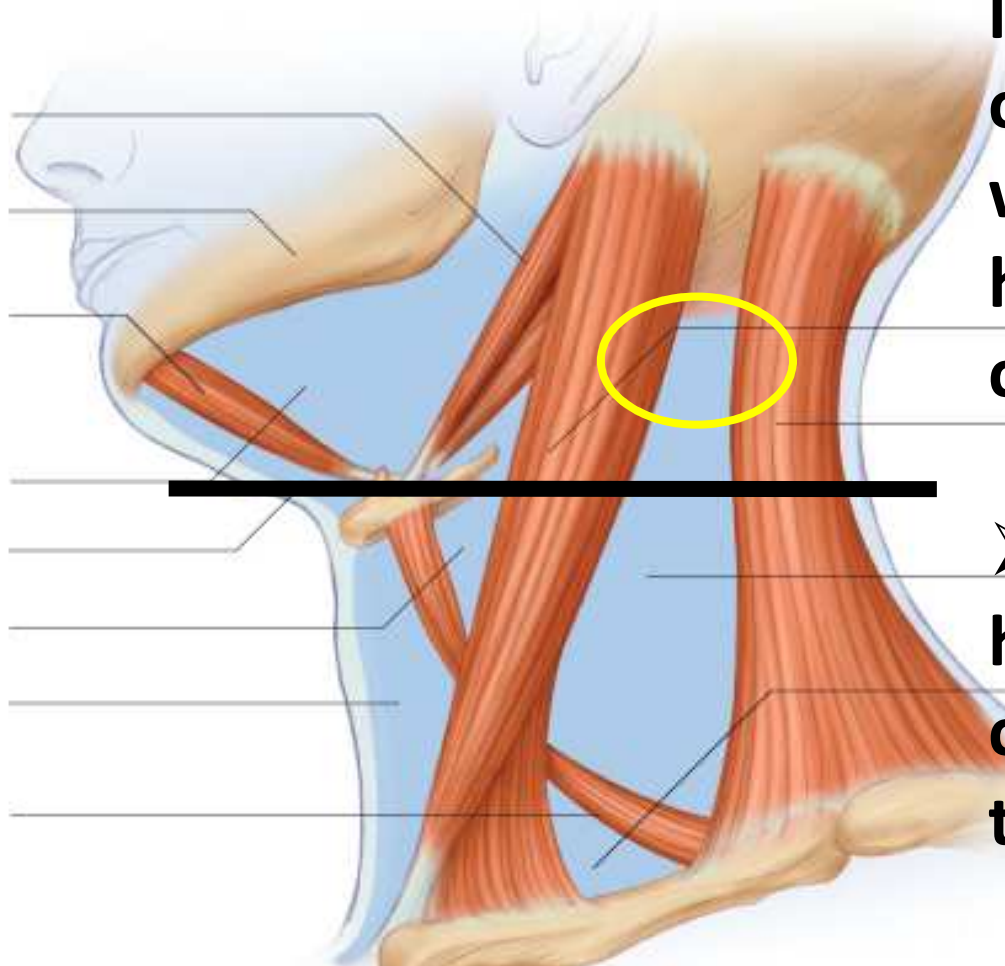
- **Hypopharynx.**
- **Larynx**
- **Oropharynx.**
- **Skip metastasis from ant tongue.**
- **Cervical esophagus**

Level V

Nodes in the posterior triangle



Level V

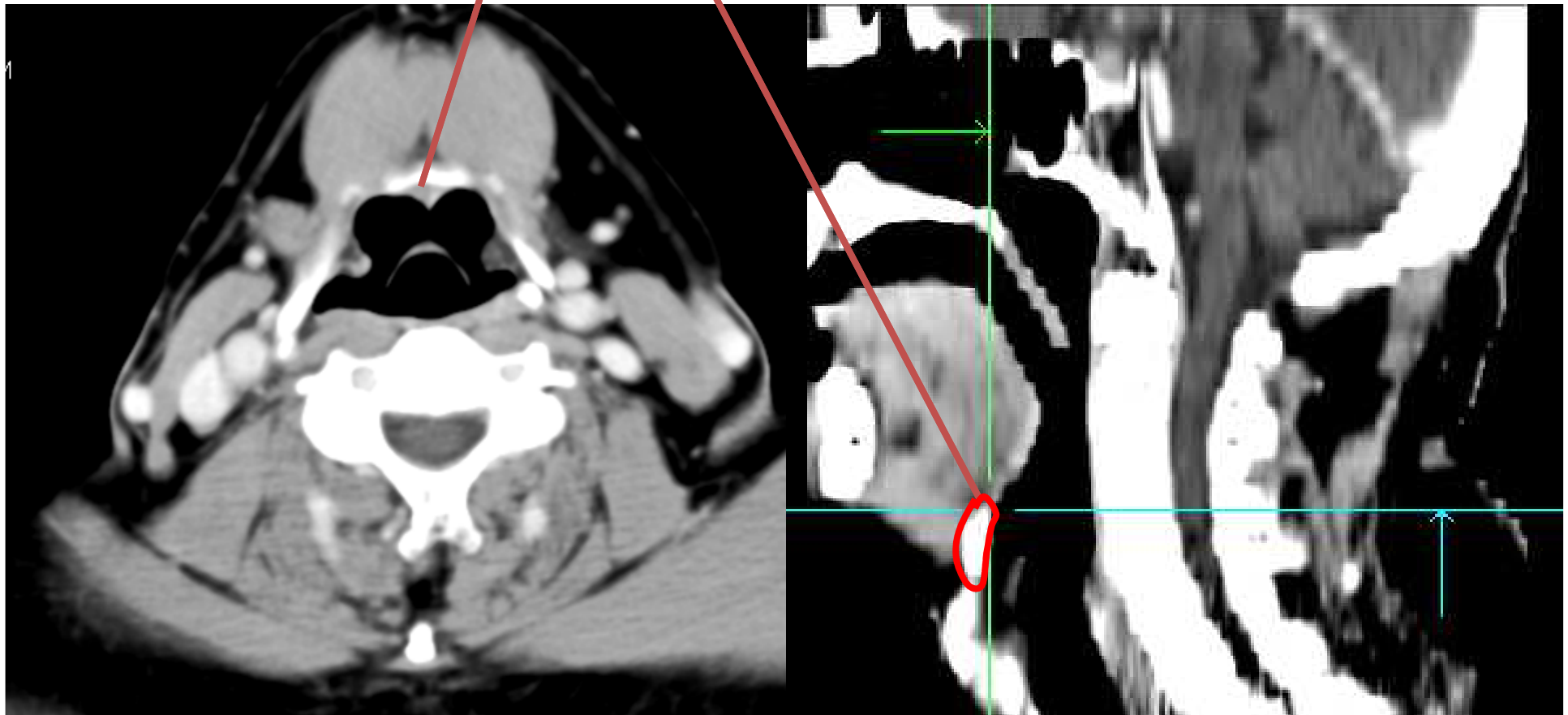


➤ The uppermost part of level V contains superficial occipital lymph node(s), which are not involved in head and neck ca except skin cancer.

➤ So cranial limit is a horizontal plane crossing the cranial edge of the body of the hyoid bone

Cranial -> Horizontal plane crossing the cranial edge of the body of the hyoid bone

Level V

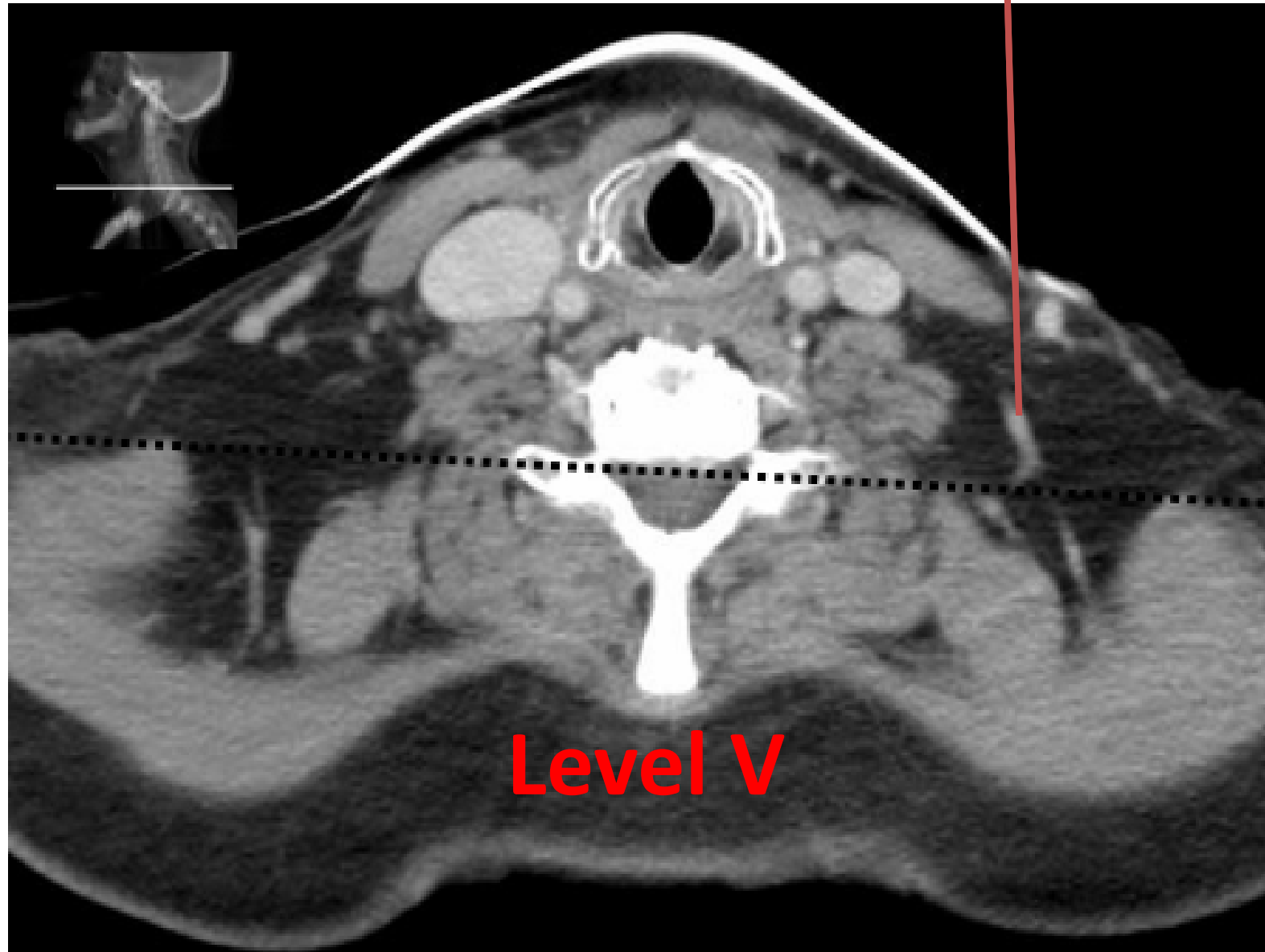


Level V

Caudal

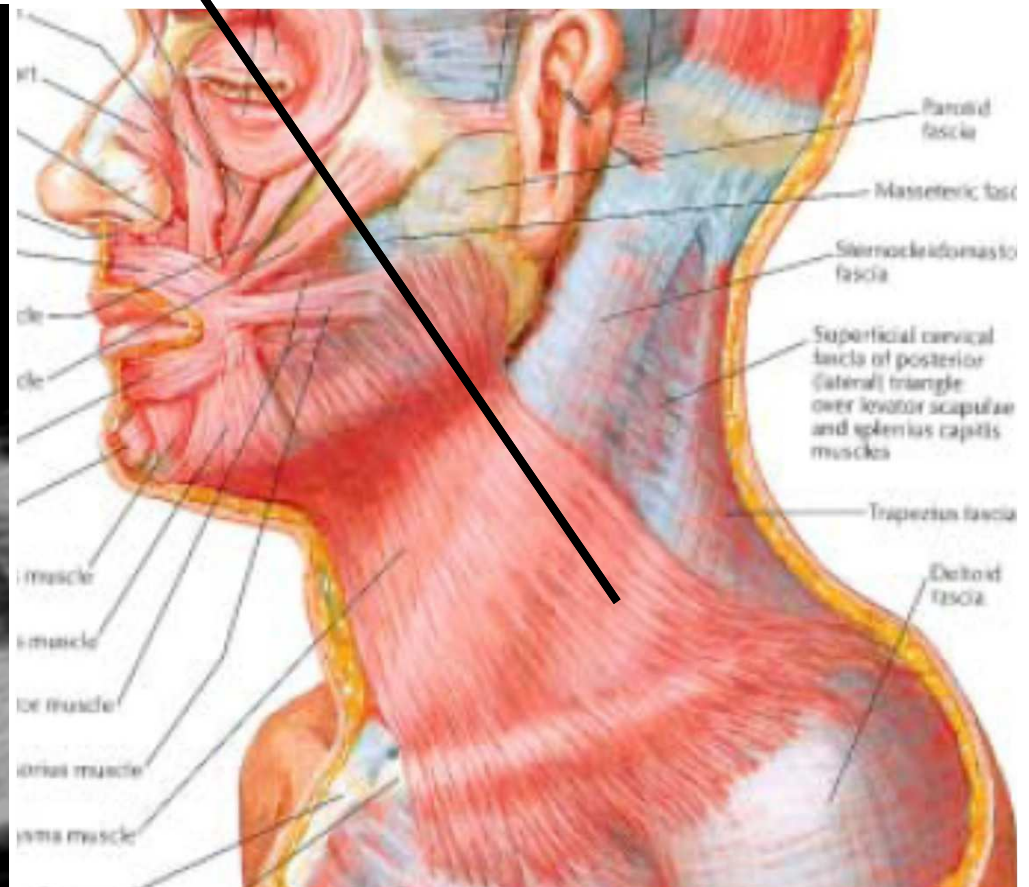
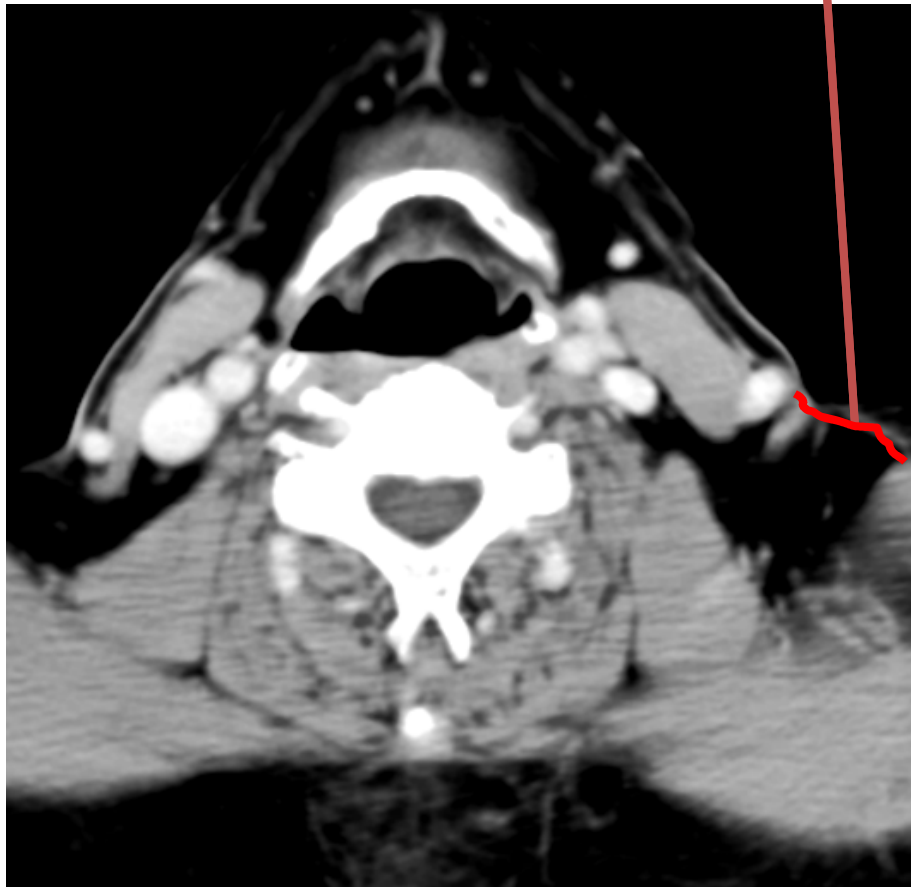
- **For the caudal limit of level V, it appears from critical examination of neck dissection procedure, that surgeons never dissect up to clavicle but go only up to the transverse cervical vessels.**
- **Hence, caudal limit of level V is kept at CT slices encompassing the cervical transverse vessels**

Caudal -> CT slices at the level of transverse Cervical vessels

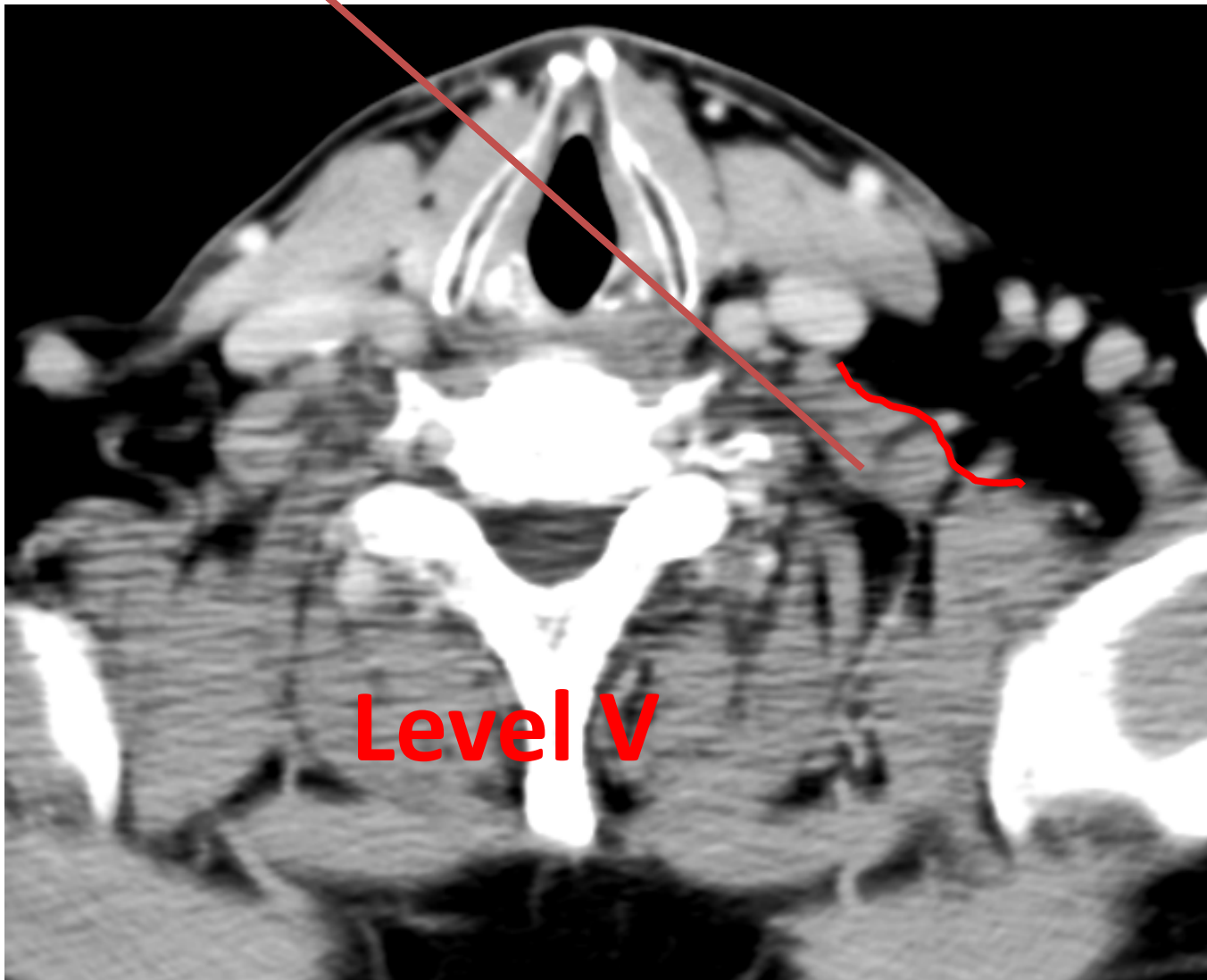


Lateral-> Platysma muscle and the skin,

Level V

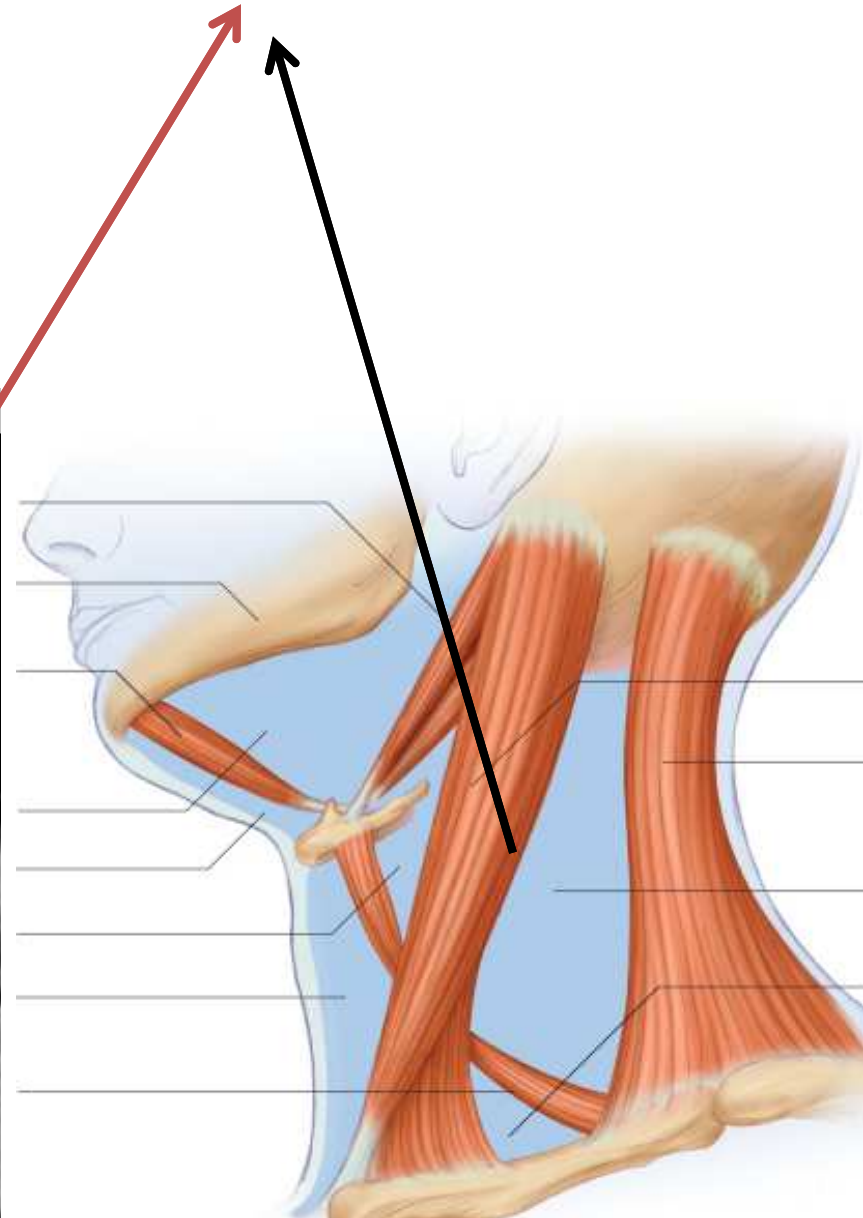
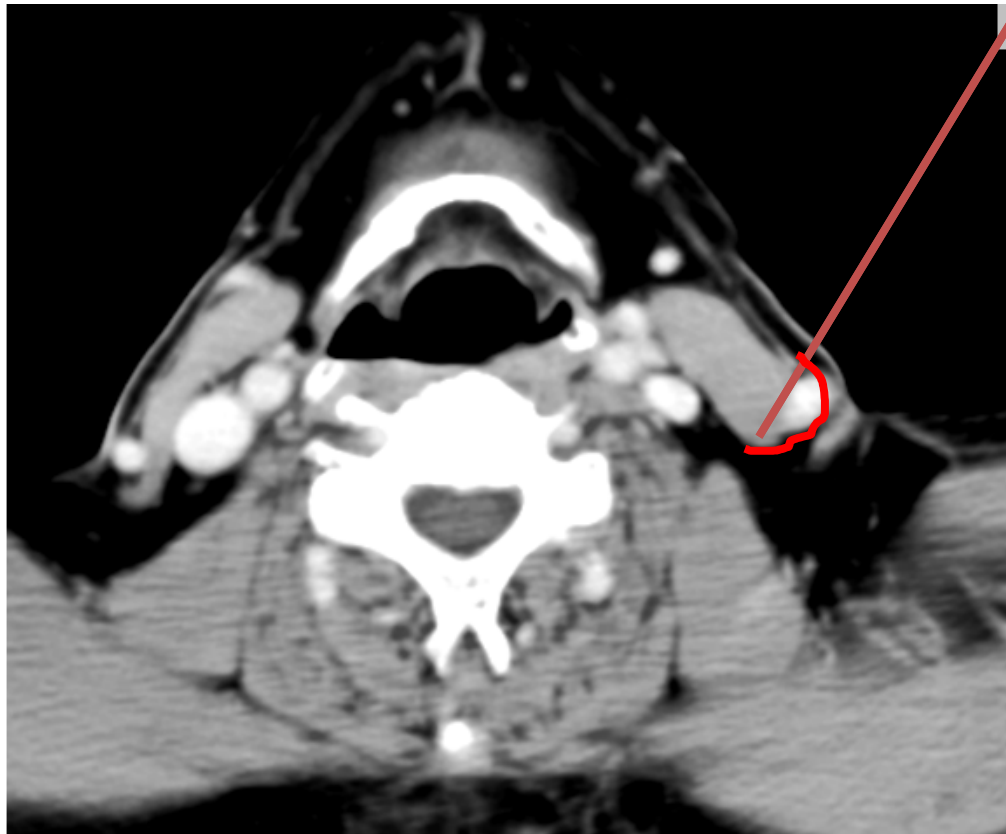


Medial -> Paraspinal muscles (splenius capitis, levator scapulae and scaleni (posterior, medial and anterior) muscles)



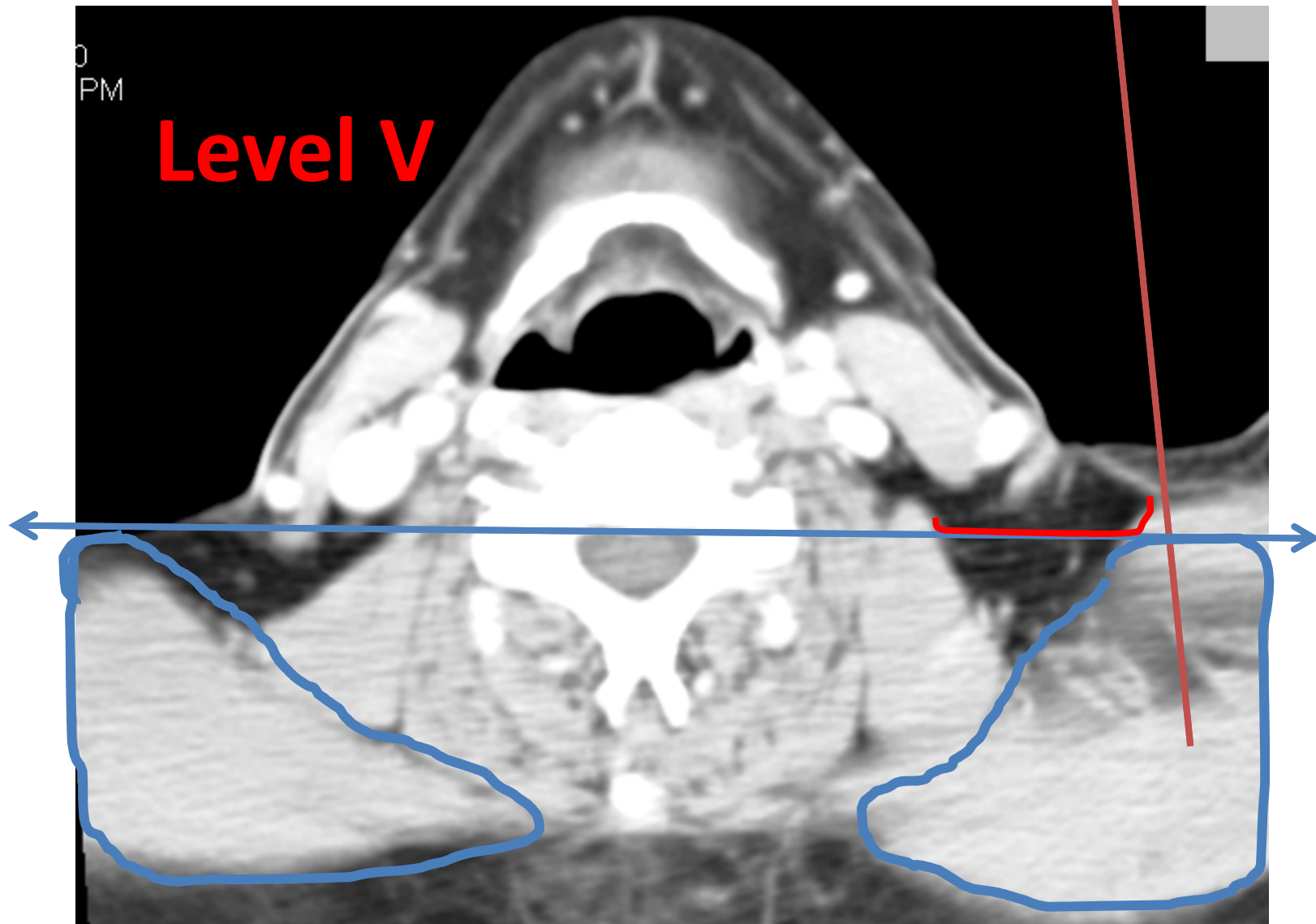
Anterior-> Posterior edge of the SCM muscle

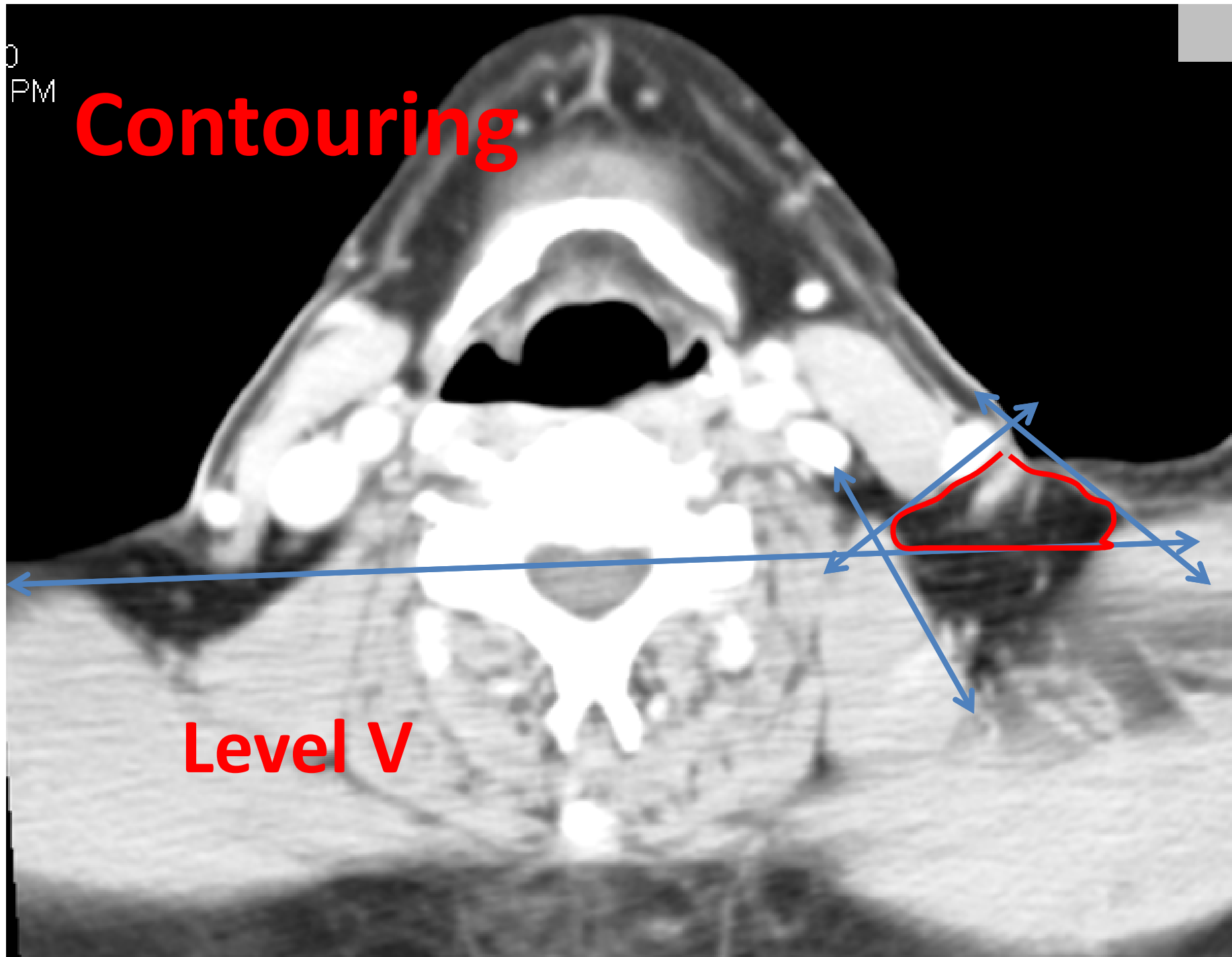
Level V



Posterior -> Antero-lateral border of the trapezius muscles

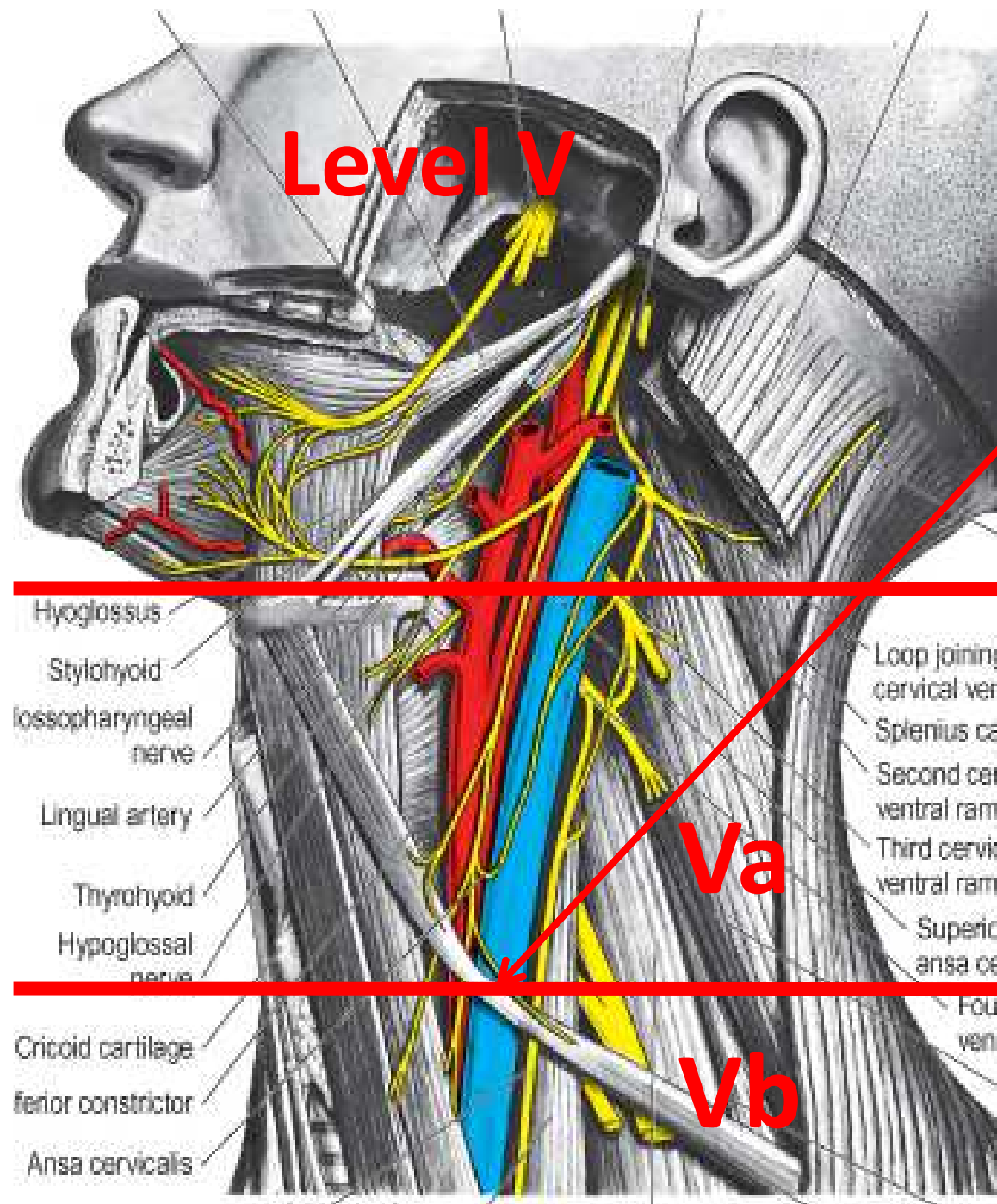
• Practically, a virtual line joining the antero-lateral border of both trapezius muscles can be use to set the posterior limit of level V





Primary for Level V

- **Nasopharynx.**
- **Oropharynx.**
- **Subglottic larynx.**
- **Apex of the pyriform sinus.**
- **Cervical esophagus.**
- **Thyroid gland.**



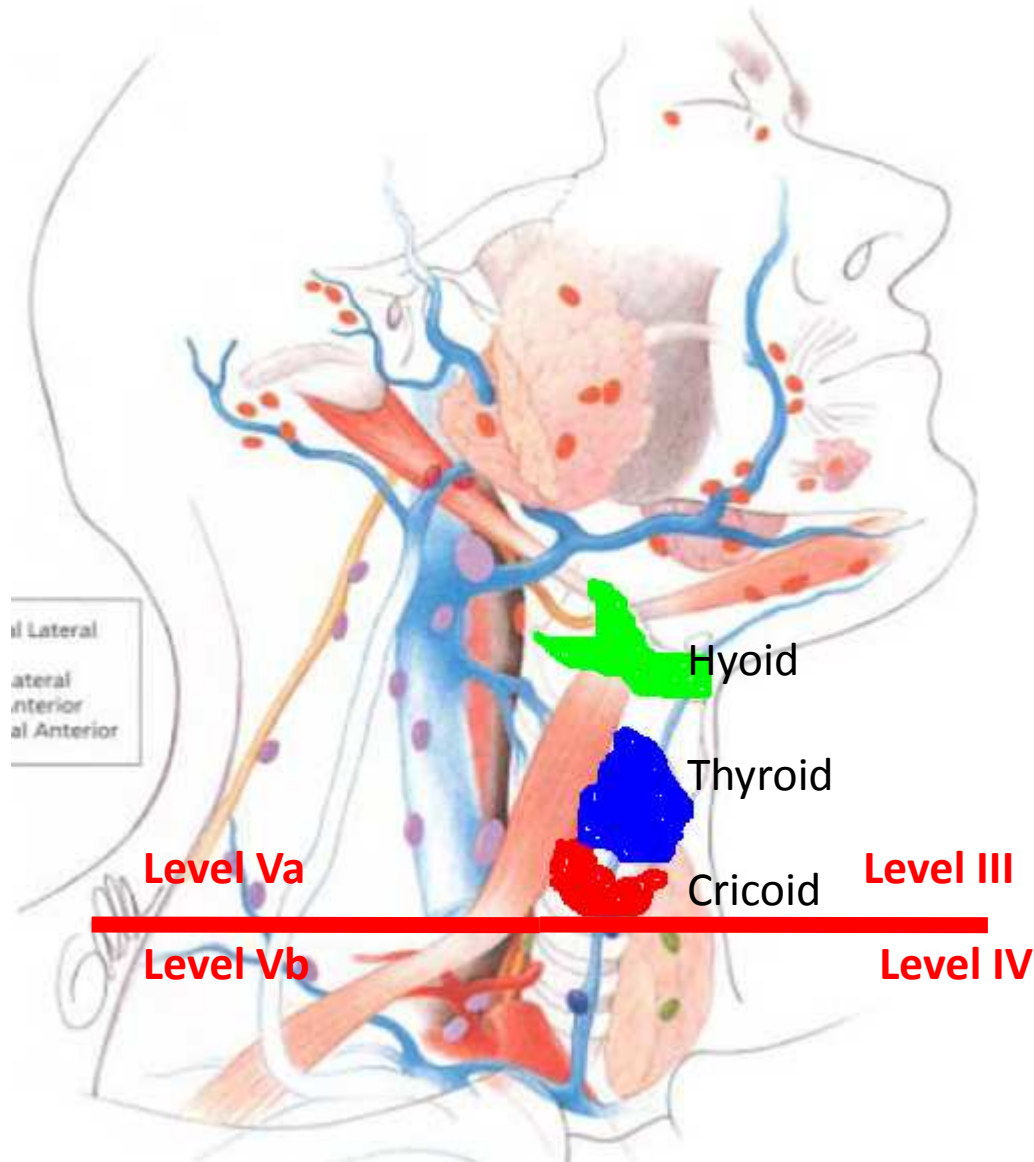
➤ Level V is divided into Va and Vb by omohyoid muscle where it crosses the internal jugular vein.

➤ But this crossing point can not be appreciated on CT film.

Level V

➤ For practical purpose, use of the plane between levels III and IV extended posteriorly is recommended,

➤ which means lower border of cricoid can be taken as dividing line between Va and Vb



Level VI

➤ Located in anterior neck compartment

➤ They are

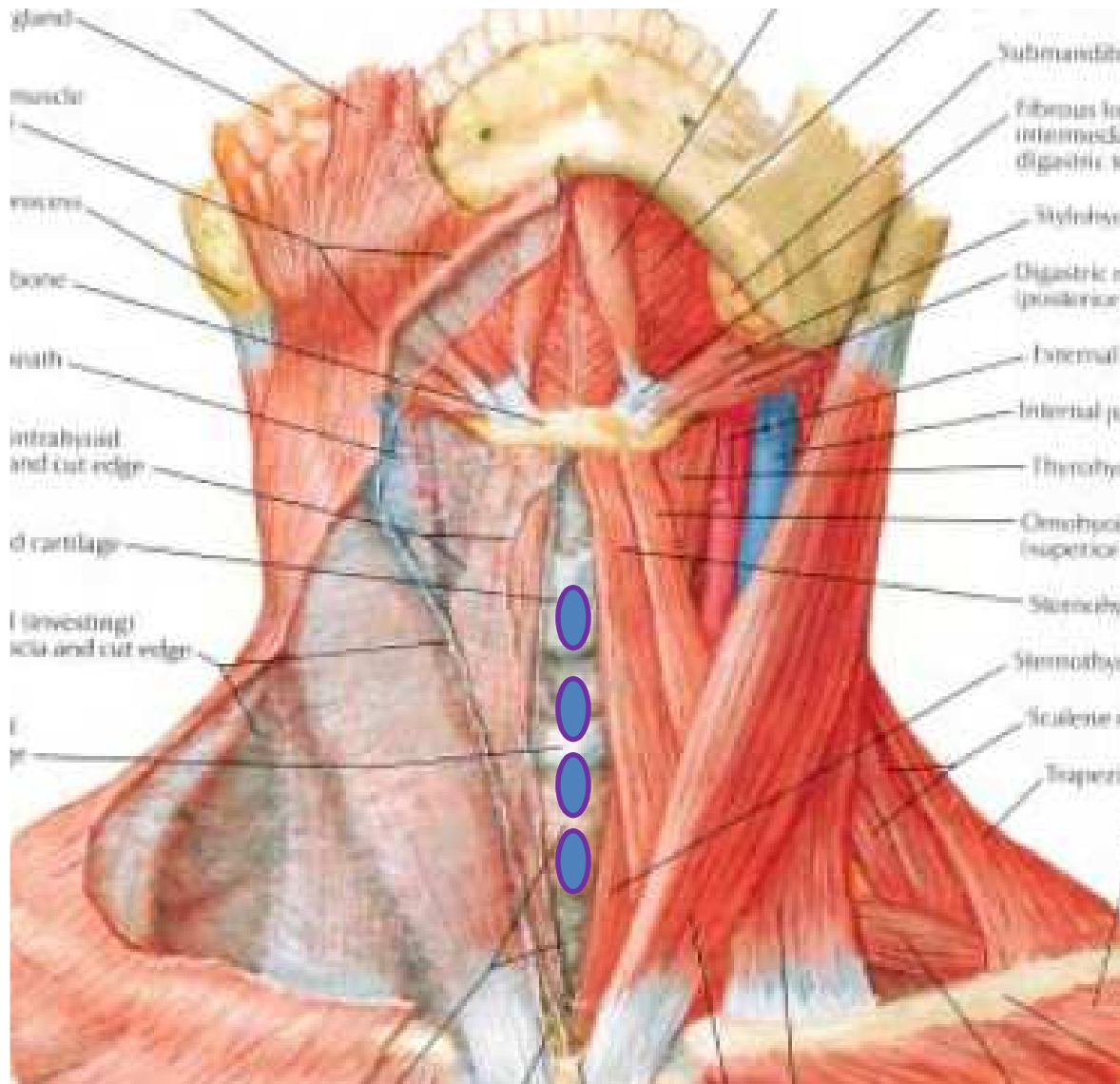
➤ Pre-tracheal

➤ Para-tracheal

➤ Pre-cricoid

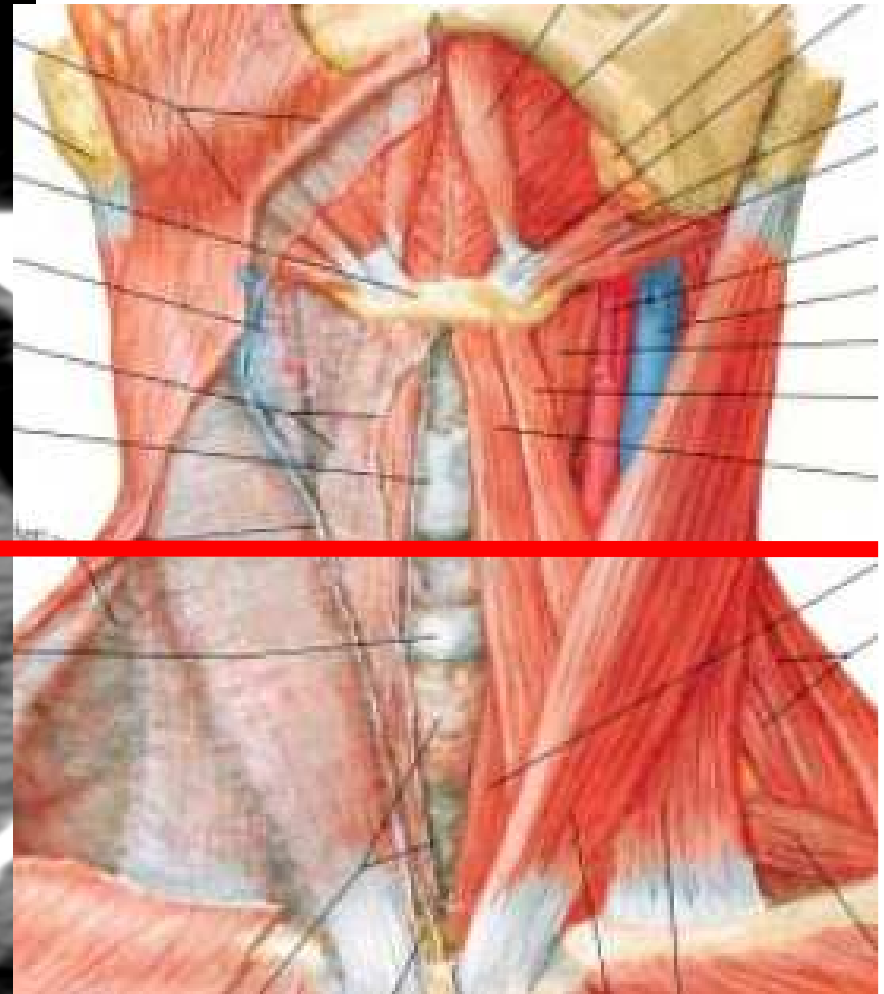
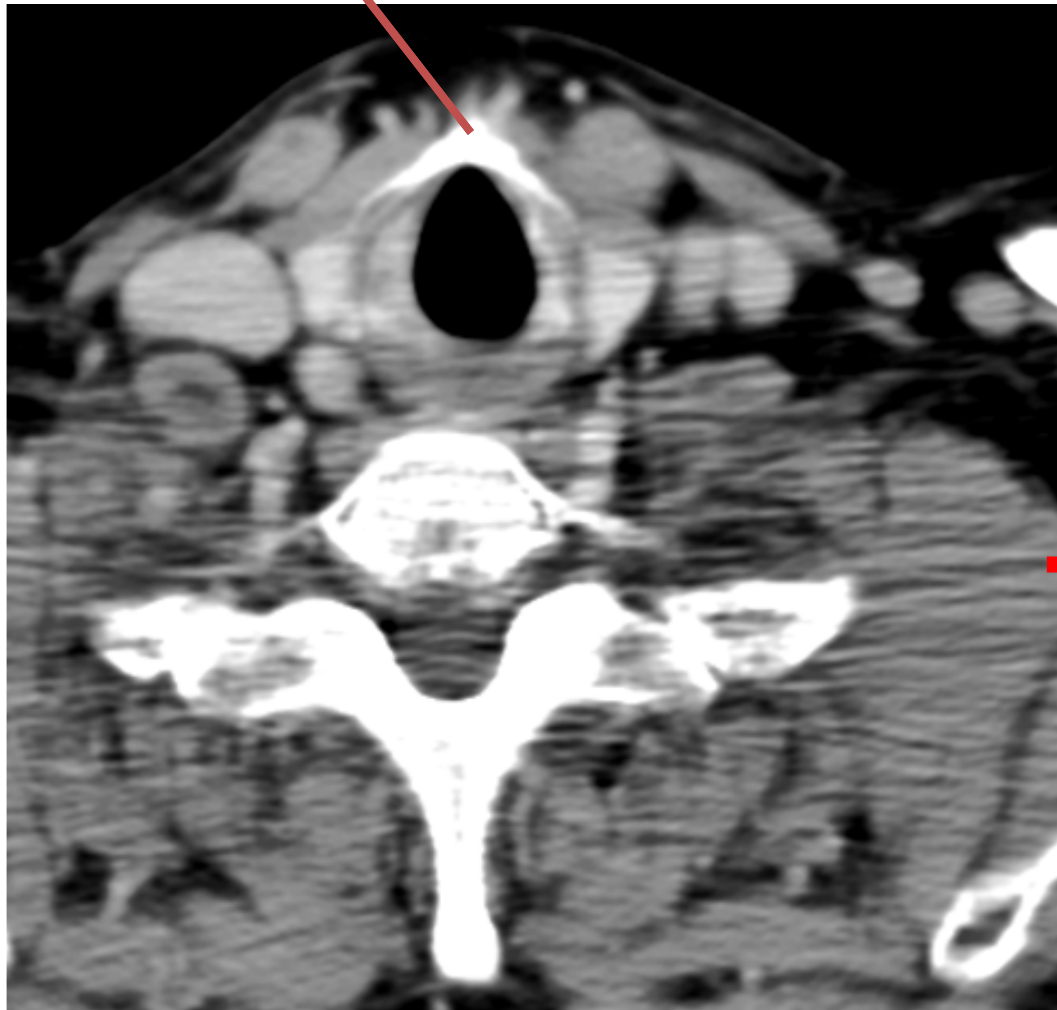
(Delphian)

➤ lymph nodes along the recurrent laryngeal nerves.



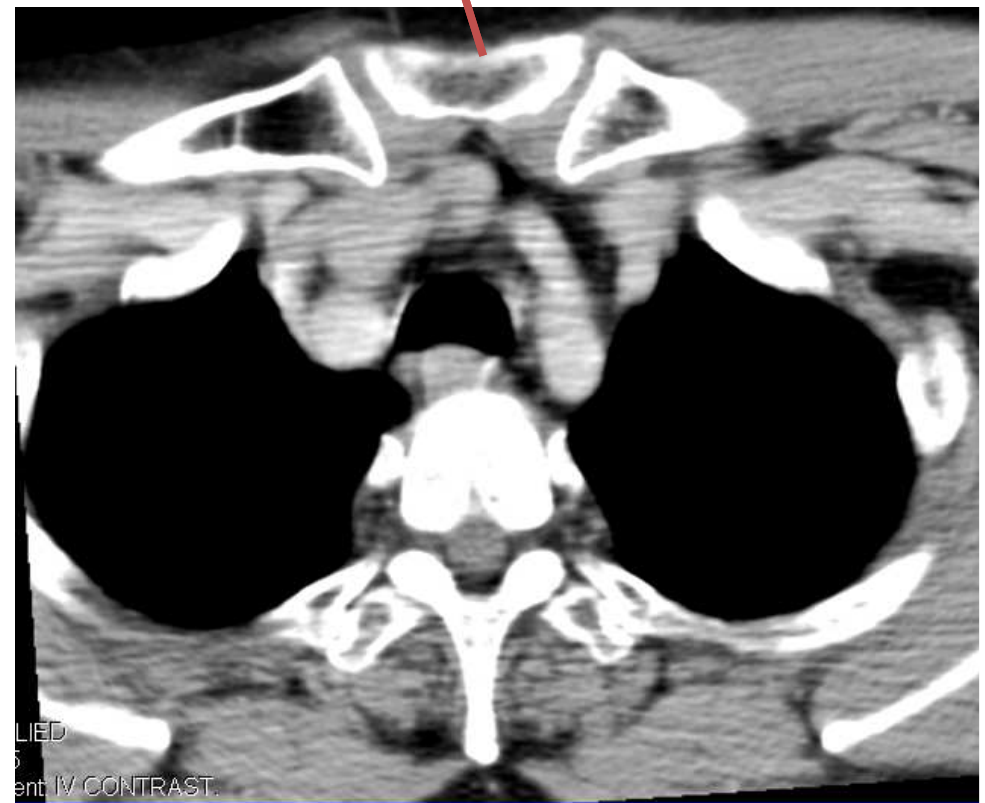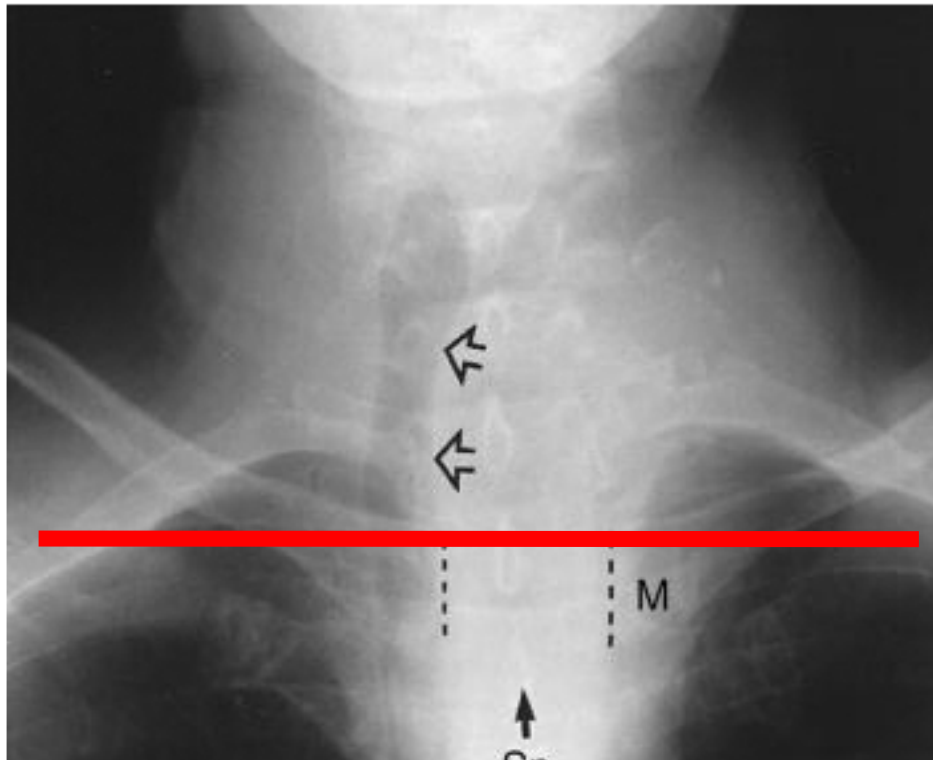
Cranial -> Caudal edge of the body of the thyroid cartilage,

Level VI



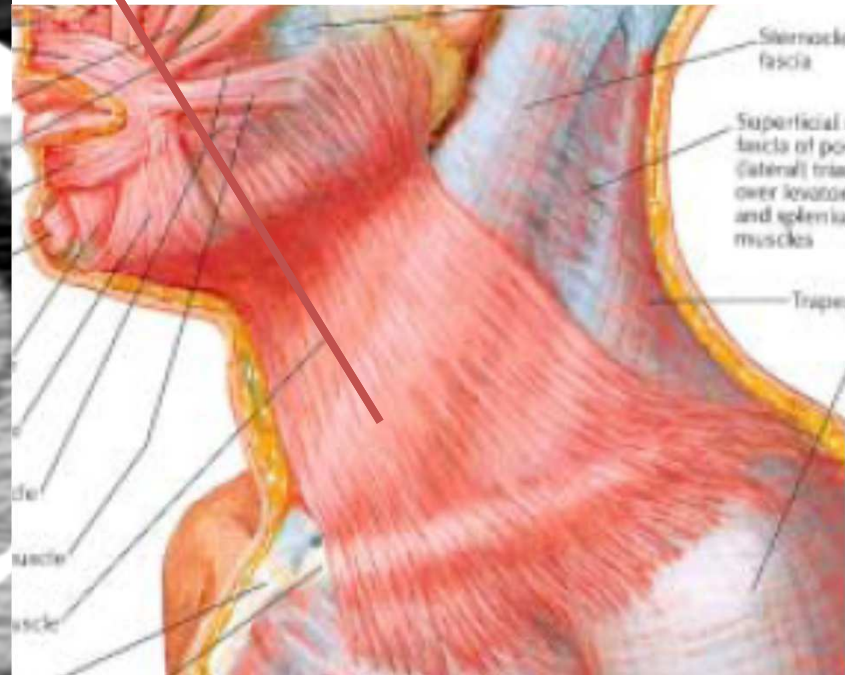
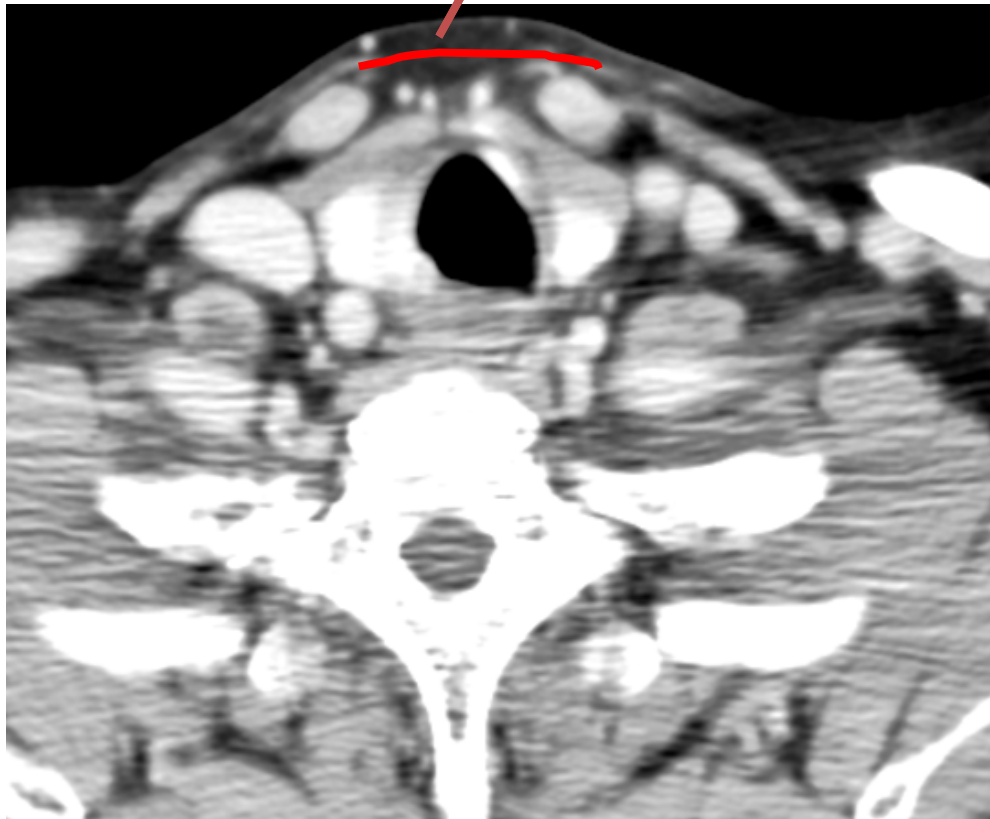
Caudal -> Cranial edge of the sternum manubrium

Level VI

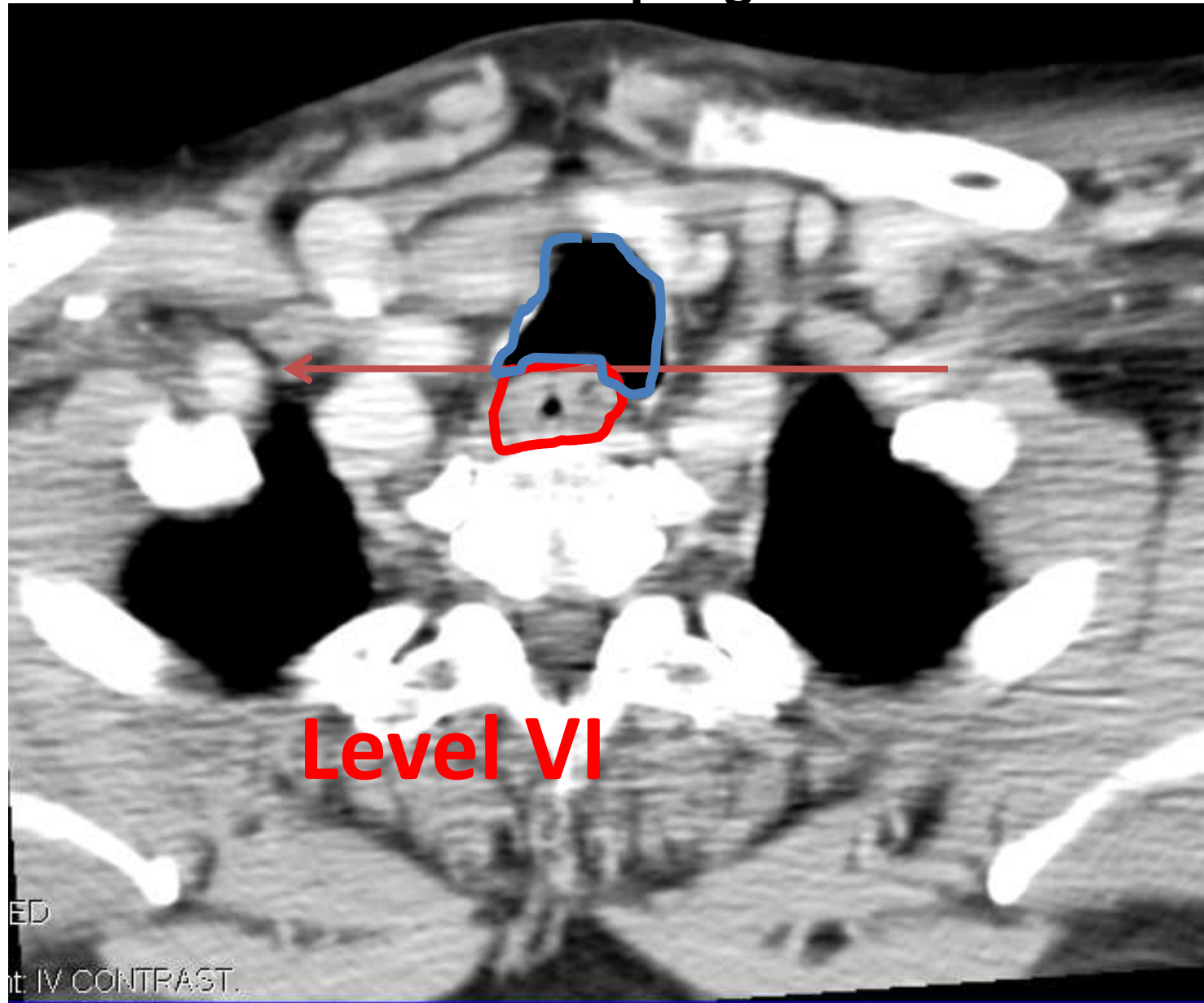


Anterior-> Platysma and the skin

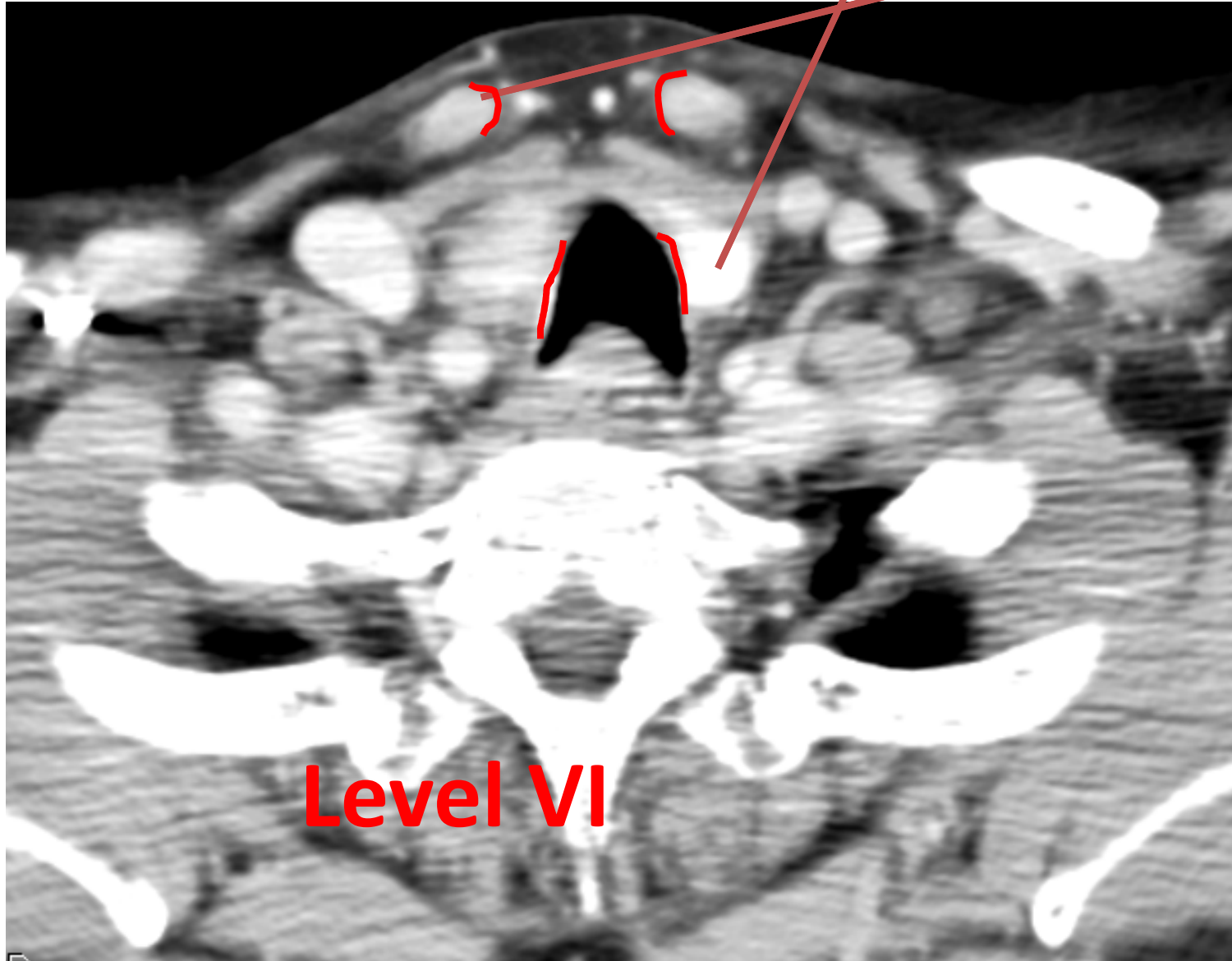
Level VI



Posterior -> Separation between the trachea and the esophagus.



Lateral -> Medial edge of the thyroid gland and the antero-medial edge of the SCM muscle



VENKATESWAR RAO. 62YRS/M

AL

YASHODA HOSPITAL

Definition

ID: 1799822 /SS

* 2/7/1948

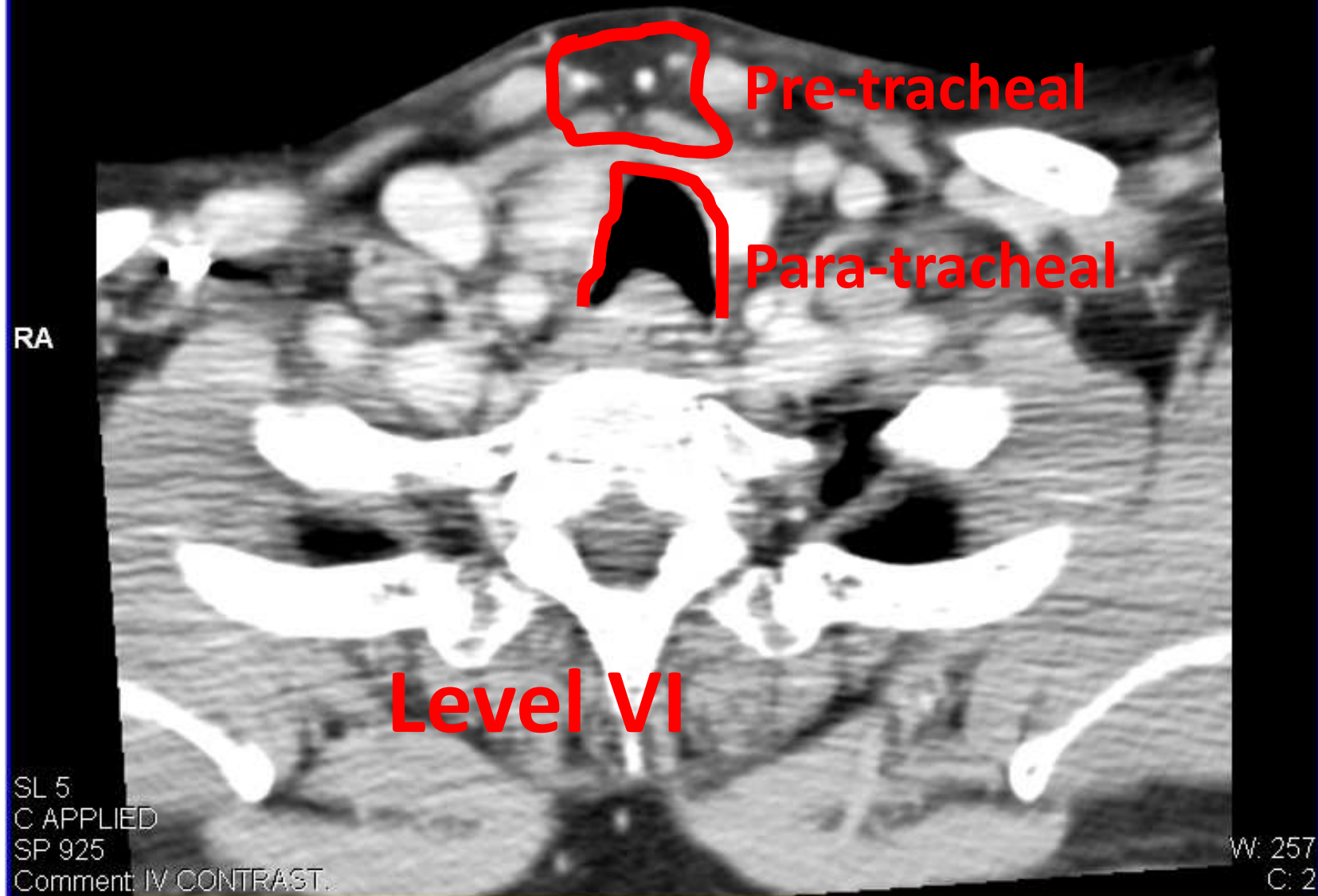
Study 1

2/1/2010

3:44:44 PM

17 IMA

Contouring



Primary for Level VI

Cervical esophagus

Apex of pyriform sinus

Thyroid ca

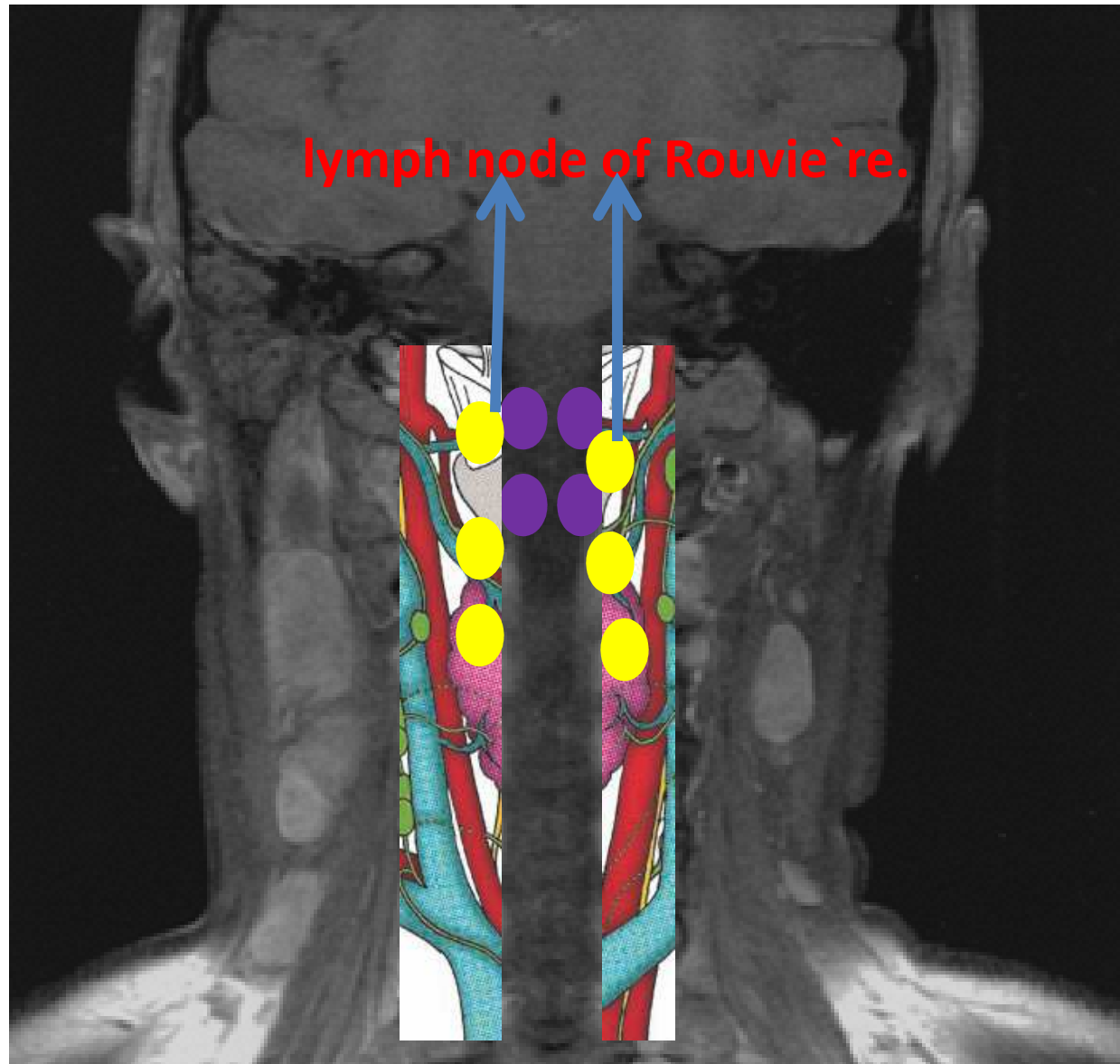
Transglottic extension

Subglottic extension

RP Nodes

➤ Typically, retropharyngeal nodes are divided into

- Medial Group
- Lateral Group.



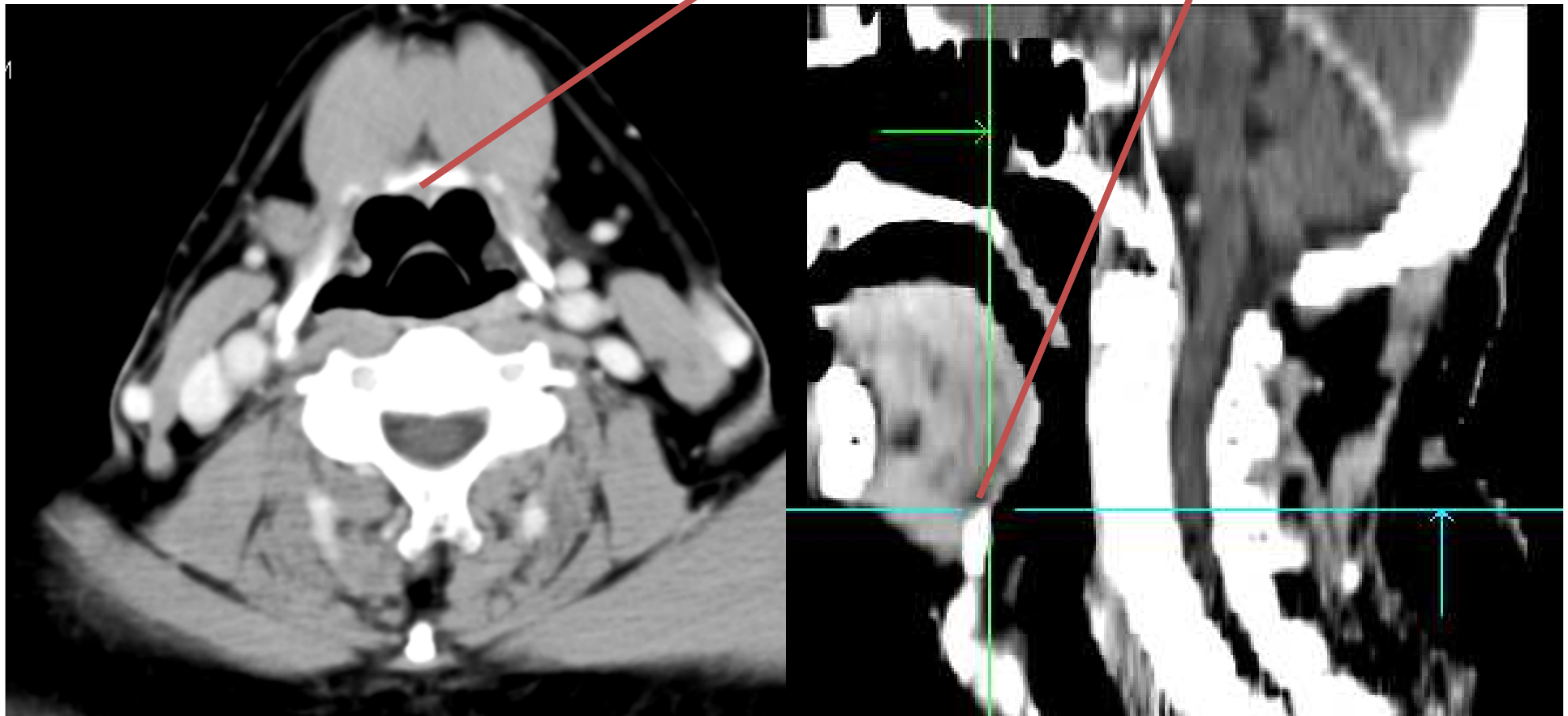
➤ The medial group is an inconsistent group which consist of one to two lymph nodes

➤ The lateral group lies medial to the carotid artery.

➤ The most superior lymph node of this group is also called the lymph node of Rouvie`re.

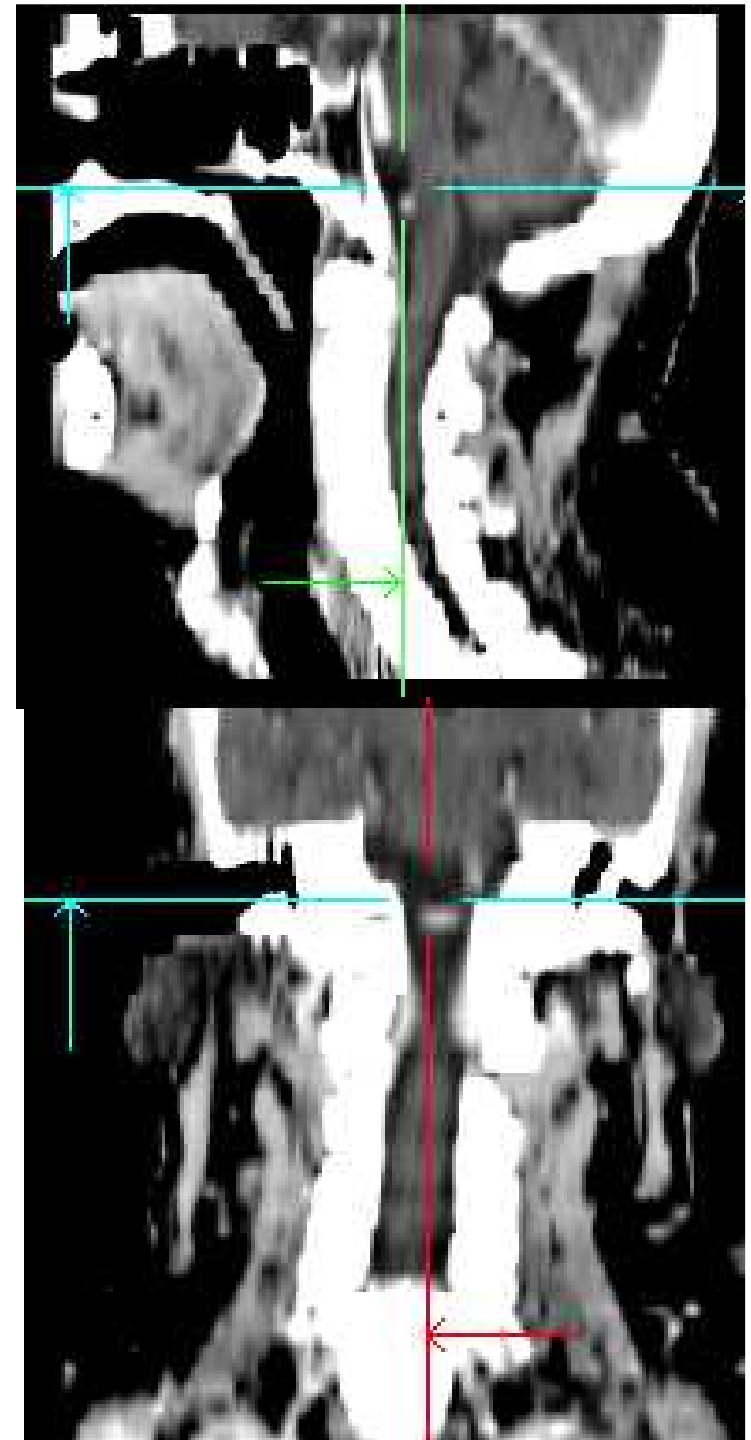
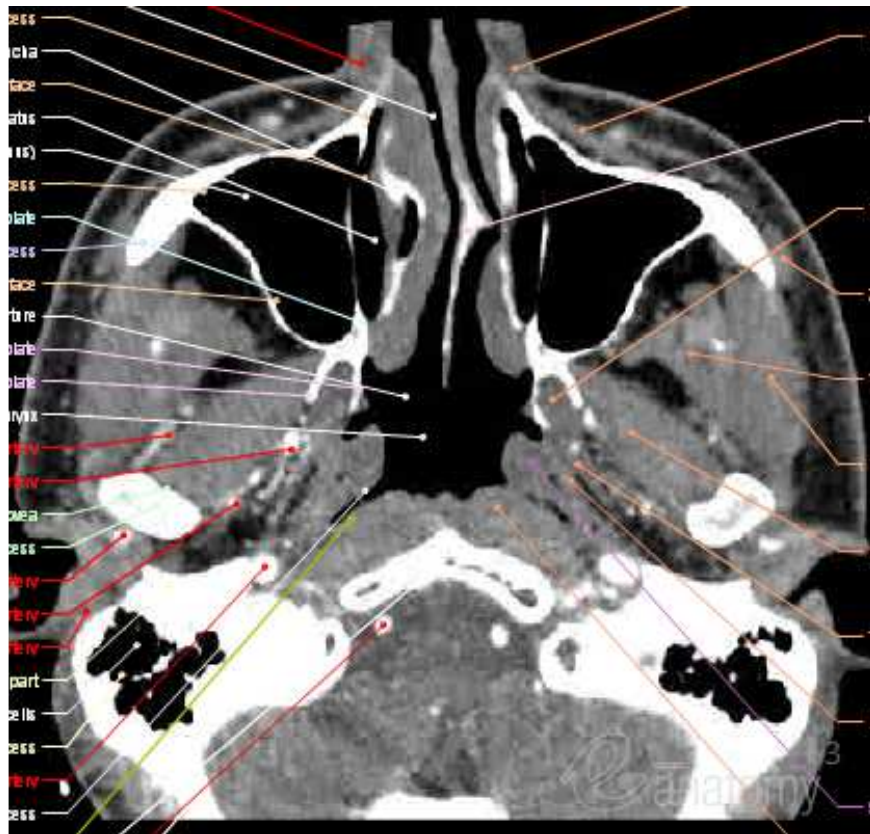
Caudal -> Cranial edge of the body of the hyoid bone

RP nodes

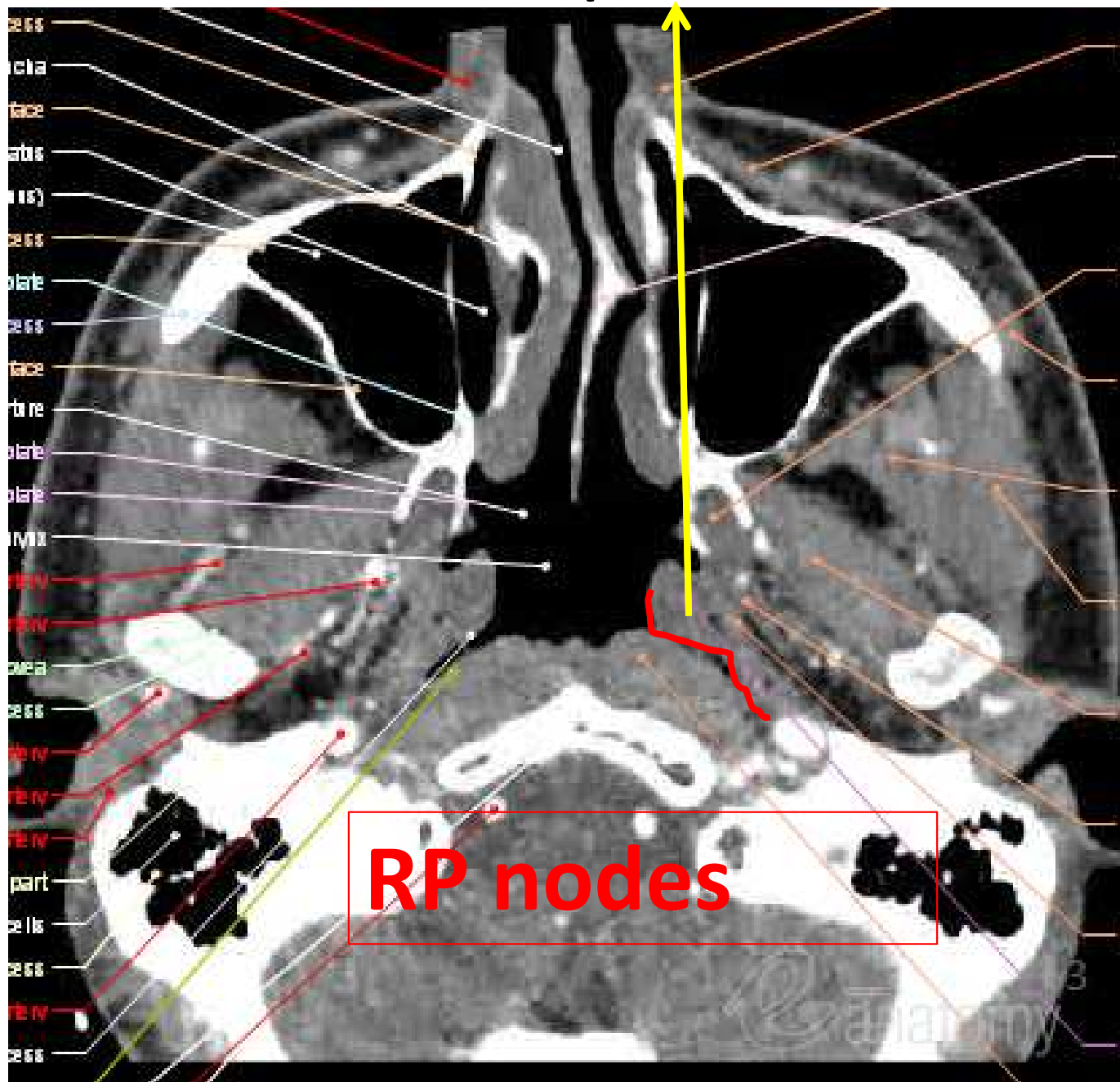


Cranial-> Base of the skull

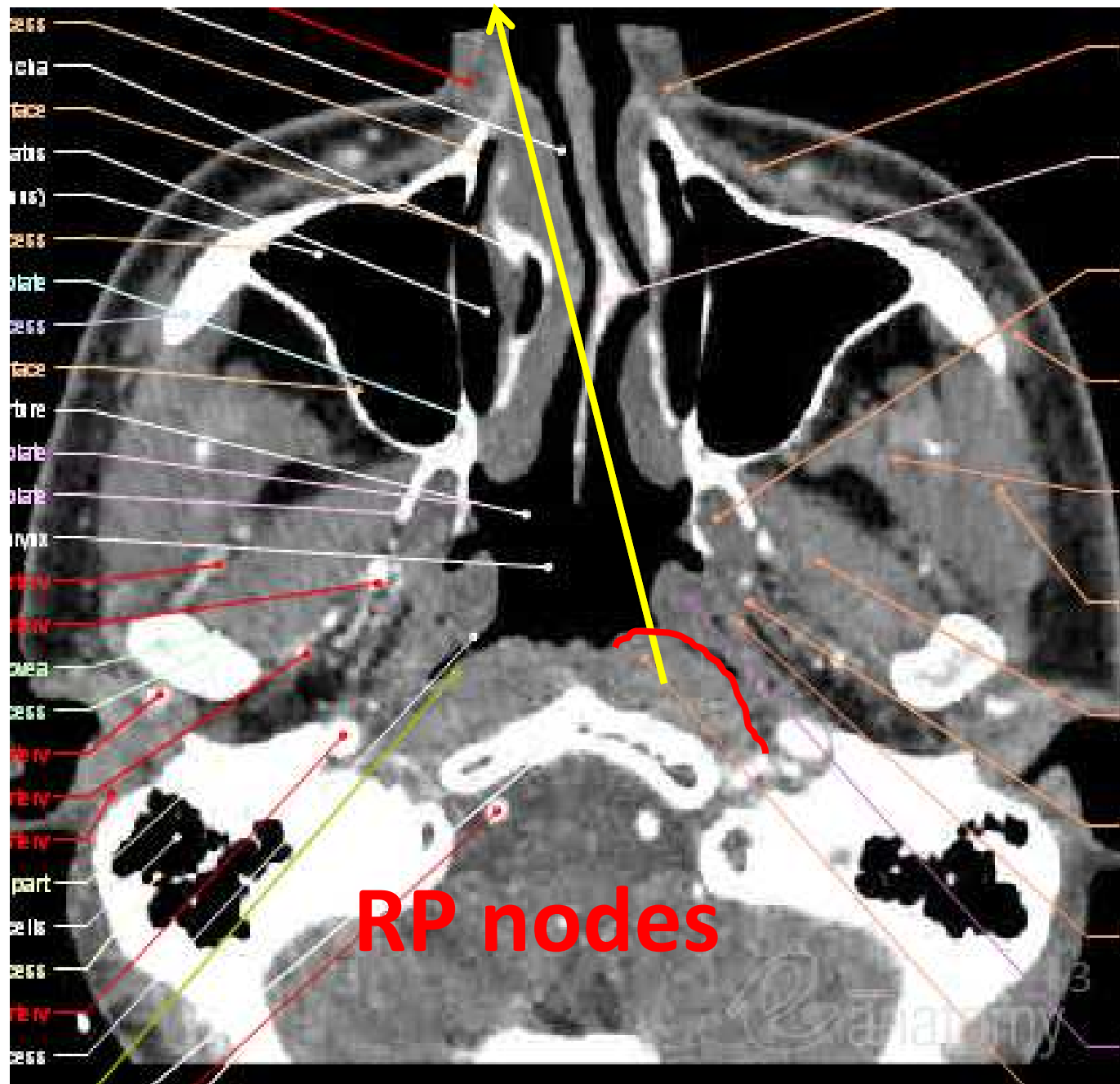
RP nodes



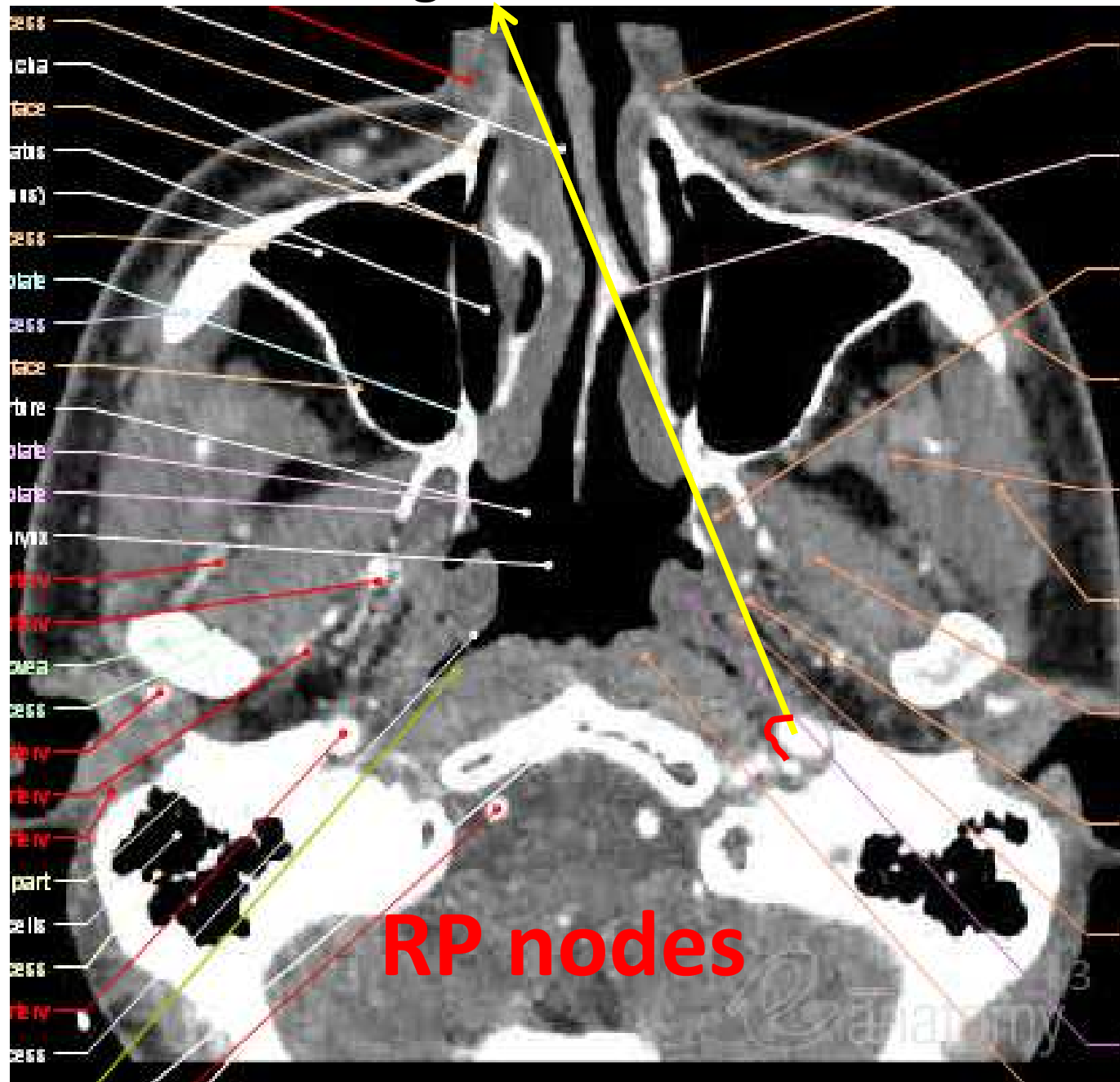
Anterior-> Levator Veli palatini muscle.



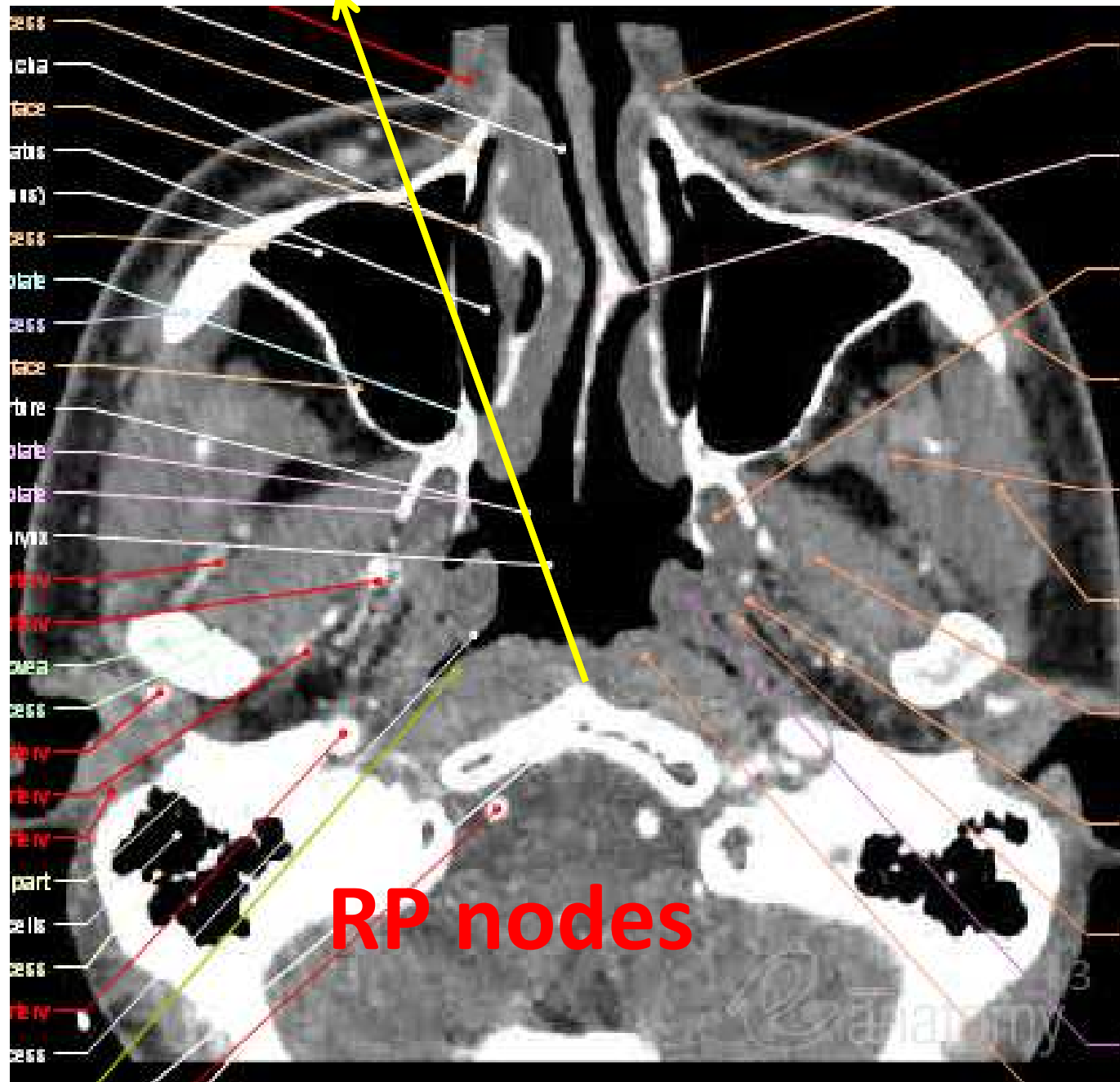
Posterior-> Pre-vertebral Muscles. .



Lateral-> Medial edge of the carotid vessel.



Medial-> Midline



Contouring

RP nodes

This axial CT scan of the chest shows the RP nodes (Retropharyngeal nodes) outlined in red. The image is labeled with various anatomical structures on the left side, including the trachea, esophagus, and various vessels. The RP nodes are located in the retropharyngeal space, posterior to the pharynx and anterior to the vertebral column.

RP nodes



Contents lists available at [ScienceDirect](#)

Radiotherapy and Oncology

journal homepage: www.thegreenjournal.com



Guidelines

Delineation of the neck node levels for head and neck tumors: A 2013 update. DAHANCA, EORTC, HKNPCSG, NCIC CTG, NCRI, RTOG, TROG consensus guidelines [☆]



Vincent Grégoire ^{a,*}, Kian Ang ^b, Wilfried Budach ^c, Cai Grau ^d, Marc Hamoir ^e, Johannes A. Langendijk ^f, Anne Lee ^g, Quynh-Thu Le ^{h,i}, Philippe Maingon ^j, Chris Nutting ^k, Brian O'Sullivan ^l, Sandro V. Porceddu ^m, Benoit Lengele ⁿ

^a Cancer Center and Department of Radiation Oncology, Clinical and Experimental Research Institute, Université Catholique de Louvain, Cliniques Universitaires St-Luc, Brussels, Belgium; ^b Department of Radiation Oncology, The University of Texas MD Anderson Cancer Center, Houston, USA; ^c Department of Radiation Oncology, University Hospital Düsseldorf, Germany; ^d Department of Oncology, Aarhus University Hospital, Denmark; ^e Cancer Center and Department of Otorhinolaryngology, Head and Neck Surgery, Institut de Recherche Experimentale et Clinique, Université Catholique de Louvain, Cliniques Universitaires St-Luc, Brussels, Belgium; ^f Department of Radiation Oncology, University Medical Center Groningen, University of Groningen, The Netherlands; ^g Department of Clinical Oncology, The University of Hong Kong (Shenzhen) Hospital, China; ^h Department of Radiation Oncology, Stanford University School of Medicine, Stanford Cancer Center, Stanford; ⁱ Radiation Therapy Oncology Group (RTOG), USA; ^j Department of Radiation Oncology, Centre Georges-François Leclerc, Dijon, France; ^k Department of Radiation Oncology, Royal Marsden Hospital and Institute of Cancer Research, London, UK; ^l Department of Radiation Oncology, Princess Margaret Hospital, University of Toronto, Canada; ^m Cancer Services, Princess Alexandra Hospital, Brisbane, Australia; ⁿ Cancer Center and Department of Human Anatomy and Plastic & Reconstructive Surgery, Institut de Recherche Experimentale et Clinique, Université Catholique de Louvain, Cliniques Universitaires St-Luc, Brussels, Belgium

CT-based delineation of lymph node levels in the neck (revised version 2013)

Node levels modified from Robbins

Level	Terminology
Ia	submental group
Ib	submandibular group
II	upper jugular group
III	middle jugular group
IVa	lower jugular group
IVb	medial supraclavicular group
V	posterior triangle group
Va	- upper posterior triangle nodes
Vb	- lower posterior triangle nodes
Vc	lateral supraclavicular group
VI	anterior compartment group:
VIa	- prelaryngeal & pretracheal nodes
VIb	- paratracheal & recurrent nerve nodes
VII	prevertebral compartment group:
VIIa	- retropharyngeal nodes
VIIb	- retro-styloid nodes
VIII	parotid group
IX	bucco-facial group
X	Posterior skull group:

Why nodal irradiation in N0 Neck for Head and Neck Ca

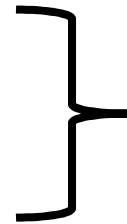
- **Elective irradiation of the cervical lymph nodes has been shown to reduce the incidence of cervical node metastases in the treatment of head and neck cancer by 20–30% .**
- **The survival benefit is estimated at 5–10%.**
- **The dose required to control micro-metastatic disease in cervical lymph nodes is thought to be 44–50 Gy**

Imaging Criteria of Abnormal L.N. SIZE

Level I,II >15mm
Level III to VI > 10mm

HETROGENEITY

Central Region hypodense,
T1-Weighted hypointensity
T2-Weighted hyperintensity



NECROSIS →

METASTASIS

CLUSTERS


Three or more contiguous ill defined nodes with
8-15mm size present together

SHAPE

Normal-----Bean or Elliptical.



Abnormal-----Round




Pattern of Spread

- **Prophylactic neck node irradiation is required if the incidence of occult metastasis is >5%.**

Pattern of Spread

- **Typically, nasopharyngeal and hypopharyngeal tumors have the highest propensity of nodal involvement which occurs in 80 and 70%, respectively.**
- **Interestingly, the node distribution follows the same pattern in the contra-lateral neck as in the ipsi-lateral neck.**
- **Contra lateral level V is usually not involved**

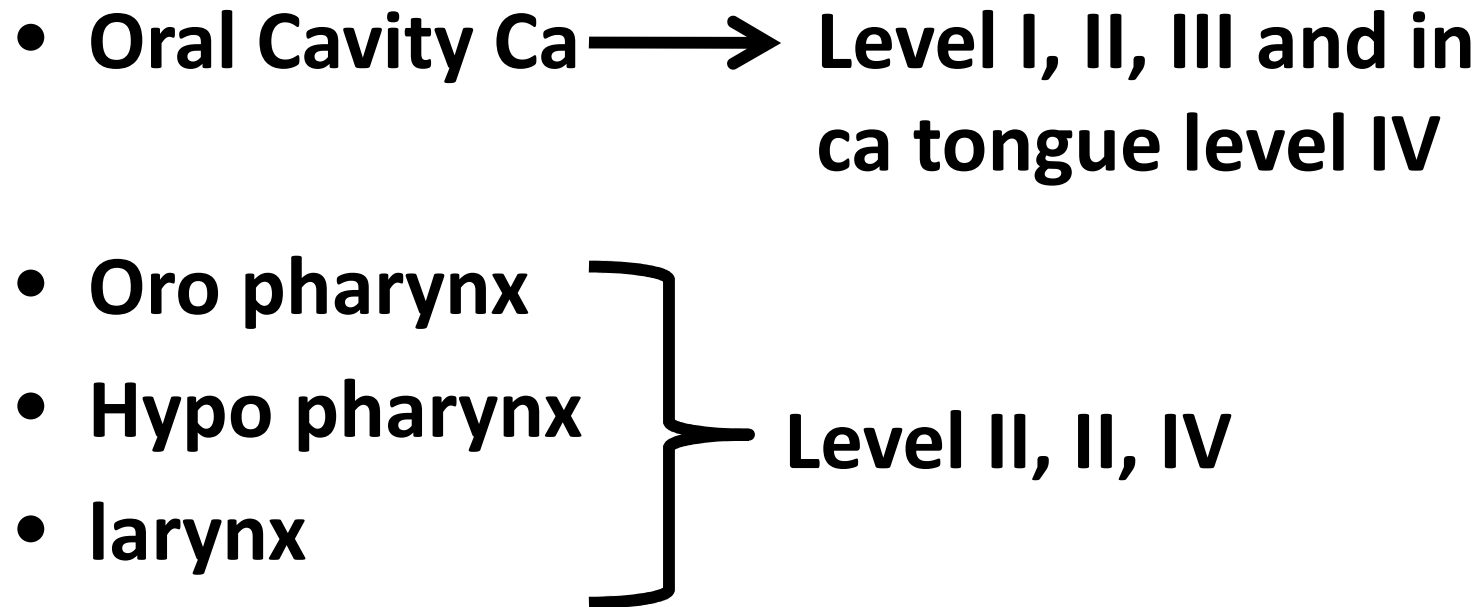
Incidence and distribution of regional metastasis for Levels I–V for clinically N0 neck



Tumor site	Levels involved(%)				
	I	II	III	IV	V
• Oral cavity	20	17	9	3	0.5
• Oropharynx	2	25	19	8	2
• Hypopharynx	0	13	13	0	0
• Larynx	5	19	20	9	2.5

- In non-nasopharyngeal cancers of head and neck, level V is not included in N0 neck as incidence of involvement is <5%.
- Similarly, in oro-pharynx, hypo-pharynx and larynx, level I is not included as again incidence of occult metastasis is <5%.

Non Nasopharyngeal N0 Neck

- Oral Cavity Ca → Level I, II, III and in
ca tongue level IV
 - Oro pharynx
 - Hypo pharynx
 - larynx
- Level II, II, IV
- 
- ```
graph LR; A[Oral Cavity Ca] --> B[Level I, II, III and in
ca tongue level IV]; C[Oro pharynx] --- D{ }; E[Hypo pharynx] --- D; F[larynx] --- D; D --> G[Level II, II, IV];
```

## Incidence and distribution of regional metastasis for Levels I–V for clinically N+ve neck

- Tumor site
  - Levels involved (%)
  - Oral cavity
  - Oropharynx
  - Hypopharynx
  - Larynx
  - Nasopharynx\*
  - In non-nasopharyngeal cancers of head and neck, level V is included in N+ve neck except in ca oral cavity where incidence is <5%.
  - Similarly level I should be included in neck positive disease except in +/- larynx.
- |              | I  | II | III | IV | V  |
|--------------|----|----|-----|----|----|
| Oral cavity  | 48 | 39 | 31  | 15 | 4  |
| Oropharynx   | 15 | 71 | 42  | 27 | 9  |
| Hypopharynx  | 10 | 75 | 72  | 45 | 11 |
| Larynx       | 6  | 61 | 54  | 30 | 6  |
| Nasopharynx* | 13 | 95 | 60  | 21 | 44 |

# **N +ve neck**

**One adjacent extra nodal level is also at high risk of occult metastasis and should be treated.**

**Oral Cavity      Level I,II & III    + Level IV**

**Pharynx            Level II,II & IV    + Level I & V**

**Larynx            Level II,II & IV    + Level I & V**



# **Involvement of level V in post-op neck**

- **1% when pathologically one confirmed node in level I-III.**
- **16% when pathologically one confirmed node observed in level IV.**
- **Incidence increases with more than one level are involved reaching 40% if all level from II to IV are infiltrated.**

# When to Treat Level V ?

- In node negative neck only in *ca nasopharynx*.
- In node positive patients all sites except *ca oral cavity*.
- In Post op. setting, more than one positive node in level I to level III or level IV positive node.

# Primary site for RP Nodes inclusion

Incidence of retropharyngeal lymph nodes in head and neck squamous cell carcinomas

|                             | N0 neck | N+ neck |
|-----------------------------|---------|---------|
| Oropharynx                  |         |         |
| pharyngeal wall (n=93)      | 16%     | 21%     |
| soft palate (n=53)          | 5%      | 19%     |
| tonsillar fossa (n=176)     | 4%      | 12%     |
| base of tongue (n=121)      | 0%      | 6%      |
| Hypopharynx (n=136)         | 0%      | 9%      |
| Supraglottic larynx (n=196) | 0%      | 4%      |
| Nasopharynx (n=474)         | 17%     | 47%     |

From McLaughlin, Chua, Chong

**N0 Neck → Nasopharynx and Pharyngeal Wall**

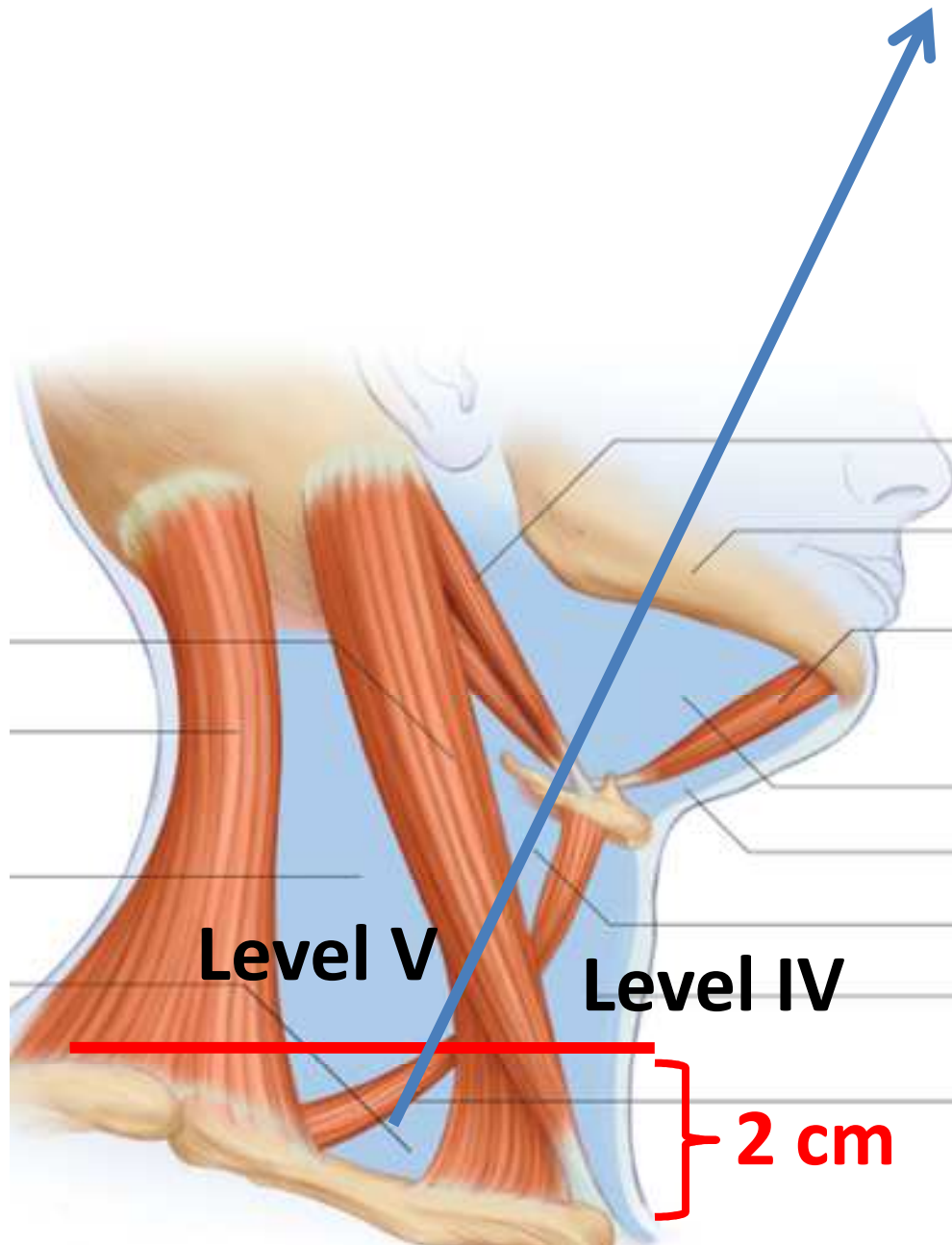
**N+ Neck → All sites except larynx**

**In non nasopharyngeal cancers usually lateral RP nodes are involved**

# **RP nodes**

- **In non nasopharyngeal cancers with risk of metastasis to RP nodes, even the lesion is ipsilateral, RP nodes should be contoured bilaterally, contra lateral recurrences are known.**
- **Most of the patients with non nasopharyngeal tumors have risk of metastasis only in lateral RP nodes.**
- **So only lateral should be included. This can save superior constrictor muscle, thus better swallowing after RT**

# Supra clavicular fossa.



In case of lower neck infiltration, this region should be included by contouring the level IV and V up to Sterno clavicular joint.

## Guidelines for the treatment of the neck of patients with HNSCC: unilateral - bilateral?

### Unilateral treatment

- lower gum
- lateral border of mobile tongue
- lateral floor of mouth
- retromolar trigone
- Cheek
- tonsillar fossa / tonsillar pillars
- lateral wall of piriform sinus



# Oral Cavity Tips

- **Bilateral Neck to be treated except T1 and T2,N0, Buccal mucosa and RM trigone where same side of neck to be treated.**
- **Level I-III nodes are to be treated in N0 except in oral tongue ca where I-IV are treated.**
- **With multiple nodes include level V also(Level I-V), level V can be omitted if only I-III are involved.**

# Pharynx Tips

- **In Pharyngeal tumors:-**
  - Treat bilateral neck except T1 and T2 tonsil with N0.
  - N0:- Level II-IV
  - With single node <6cm, also include level V and RP nodes (Level II-V with RP)
  - With multiple nodes or >6cm size also include level I also(I-V with RP)
  - With Pyiform sinus apex and esophageal extension also include level VI.
  - With N0, IIb may be omitted

# Larynx Tips

- **Laryngeal Tumors:-**
  - Treat bilaterally
  - With N0, level II-IV.
  - With single node <6cm size, also include level V(II-V)
  - With multiple nodes or >6cm size also include level I also (I-V).
  - With trans glottic and sub glottic ext also include level VI
  - In No, IIb may be omitted

## **Post op. RT to neck**

- **irradiation of levels I to V will be typically performed.**
- **For laryngeal tumors, level I could be omitted.**
- **For oral cavity tumors, postoperative irradiation of level V could be omitted in the case of metastatic nodes located in level I and/or II only.**

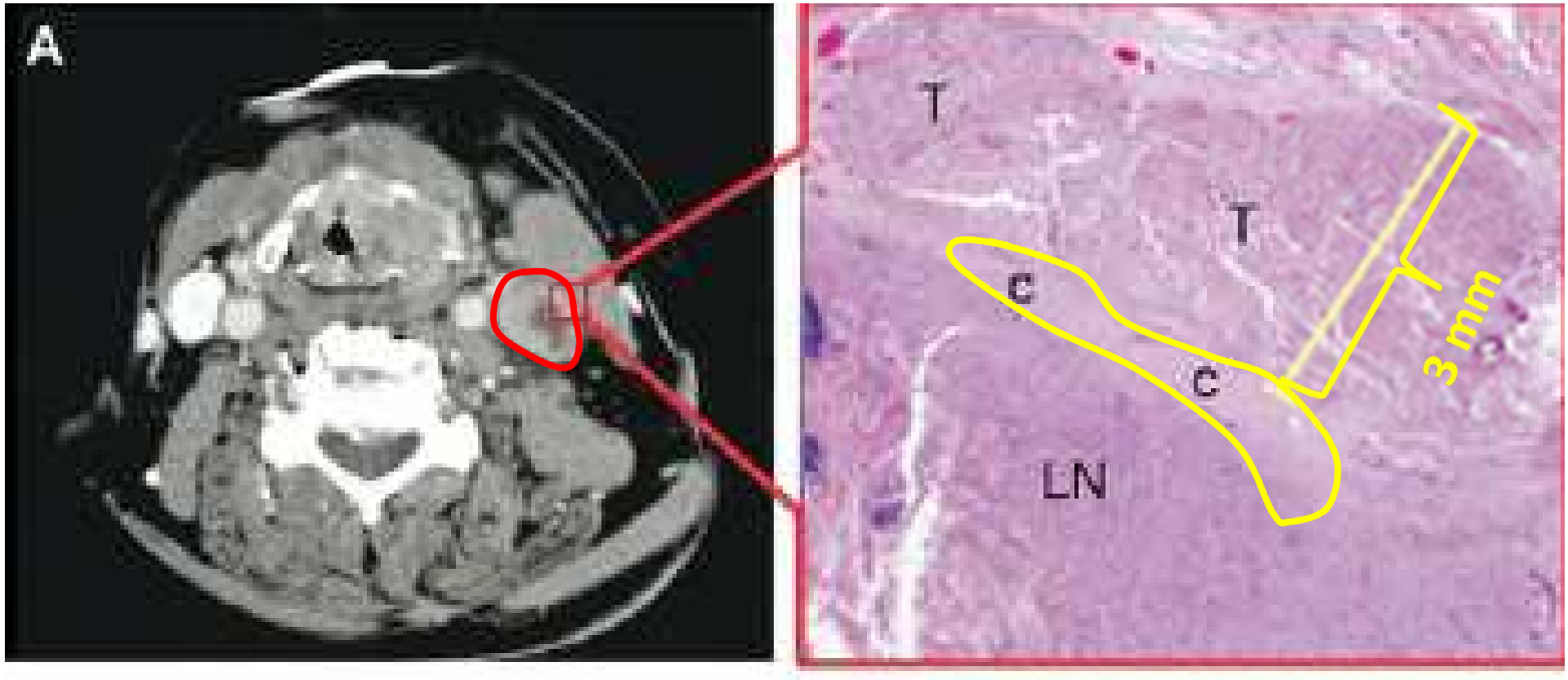
# Extra Capsular Extension(ECE)

- Incidence of ECE is 20 to 40% in metastatic node <1cm size while goes up to 75% if size is >3 cm.
- So in case of ECE, generous portion of the muscles adjacent to node should be included at least till prophylactic doses.

## Imaging Criteria

- Capsular Enhancement.
- Ill defined nodal margins
- Obliterated Fat Plane
- Edema or thickening of adjacent soft tissue

# Extra Capsular Extension(ECE)



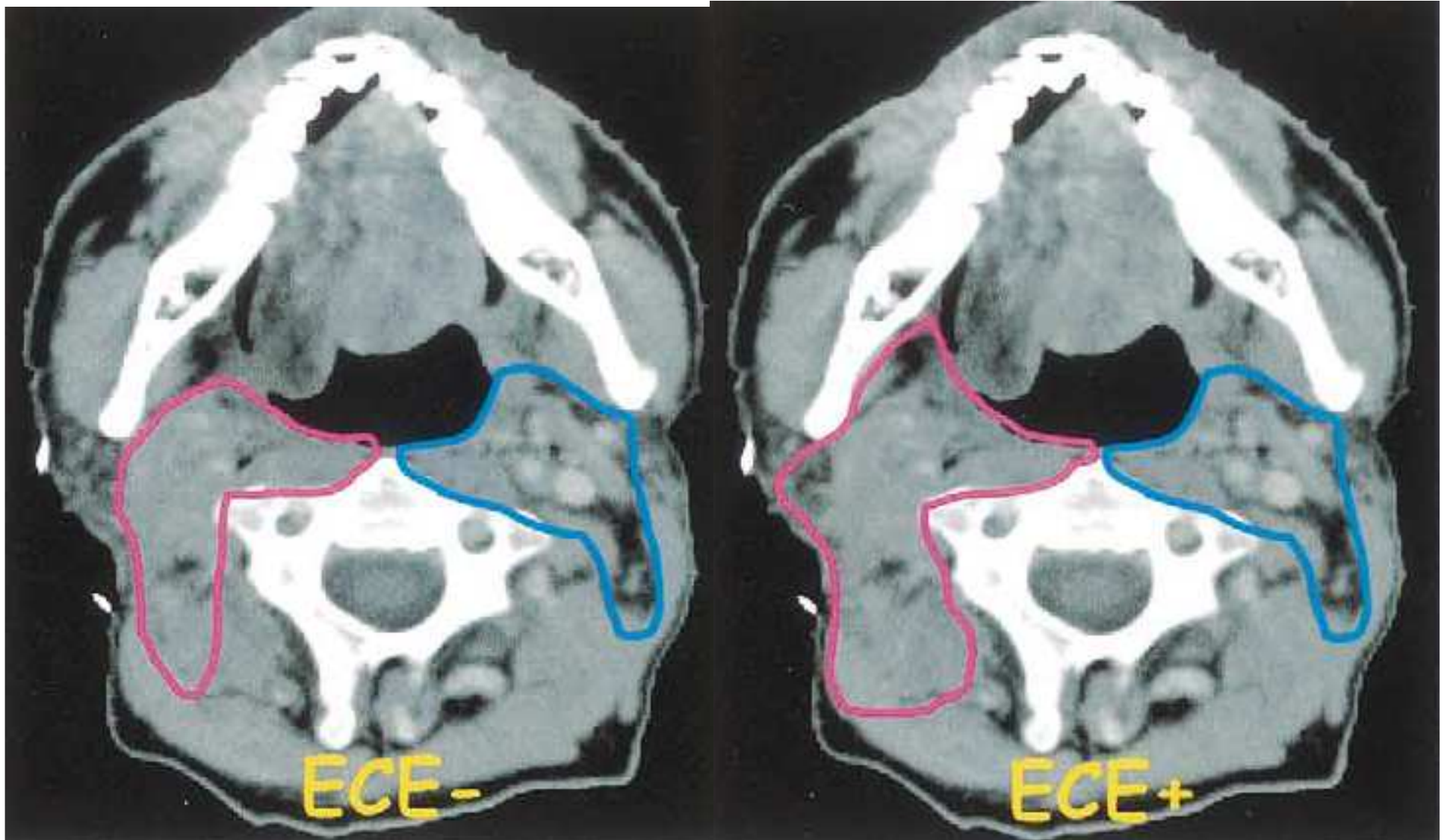
The majority of the ECE extend <5mm from the capsule of node.  
None extend >10mm



# **Extra Capsular Extension(ECE)**

- **Margins of 1 cm from the nodal GTV to the CTV would be sufficient to fully cover any ECE for lymph nodes smaller than 3 cm.**
- **1 cm CTV margins are too constrictive for patients with larger or matted lymph nodes, particularly ones that infiltrate the musculature.**
- **In the case of lymph nodes with gross muscular involvement, it is recommended using more generous CTV margins around the nodal GTV**

## Post op CTV with ECE + and ECE -ve



# **General Guide lines**

- **Neck disease should be treated with the modality used to treat the primary.**
- **If neck is treated by surgery the post op RT is indicated in patients with..**
  - **More than one positive node**
  - **Extra Capsular Extension**
- **If the neck is treated with RT the surgery is indicated in patients with...**
  - **Patients with N2 or N3 disease**
  - **Patients with residual nodal disease irrespective of N stage**

# FDG-PET-CT: Regional Control

**Accuracy PET for detection of lymph node metastases is interval dependent:**

| Author        | Interval after chemoradiation | Negative Predictive Value |                              |
|---------------|-------------------------------|---------------------------|------------------------------|
| Rogers        | 4 weeks                       | 14%                       | (95%CI: 3%–45%)              |
| McCollum      | 4–12 weeks                    | 73%                       | (95%CI: 46%–99%)             |
| Yao; Porceddu | > 8 weeks                     | 97% – 100%                | (95%CI: 87%–99% en 96%–100%) |

Rogers JW *et al.* Int J Radiat Oncol Biol Phys 2004;58:694-7

McCollum AD *et al.* Head Neck 2004;26:890-6

Yao M *et al.* Int J Radiat Oncol Biol Phys 2005;63:991-9

Porceddu SV *et al.* Head Neck 2005;27:175-81

VU university medical center



# Clinical or Imaging Abnormality

**PET-CT / MRI at 12 weeks**

```
graph TD; A[PET-CT / MRI at 12 weeks] --> B[positive]; A --> C[negative]; B --> D[Neck Dissection]; C --> E[Observation]
```

**positive**

**Neck Dissection**

**negative**

**Observation**



# Thanks

