



What to look into pathology reports??



**DR. NEETI SHARMA
ASSOCIATE PROFESSOR
ATRCTRI, BIKANER**

22ND ICRO-AROI Teaching Course Series

Acharya Tulsi Regional Cancer Treatment and Research Institute, Bikaner

Start from the top of report:

Name : Mr. xxxxx

Age : 35 Years

Gender: Male

Collected: 11-03-2016 00:00:00

Received: 14-03-2016 11:42:01

Reported: 29-03-2016 19:09:17

- Age
- Sex
- Post-operative interval status:
- Neo-adjuvant therapy status

Why the post operative histopathology report detailed study required??

Postoperative RT reduces the risk of local–regional failure and probably improves survival.

Need of selective irradiation??

- To get better treatment outcome with minimum toxicity by irradiating selective part.

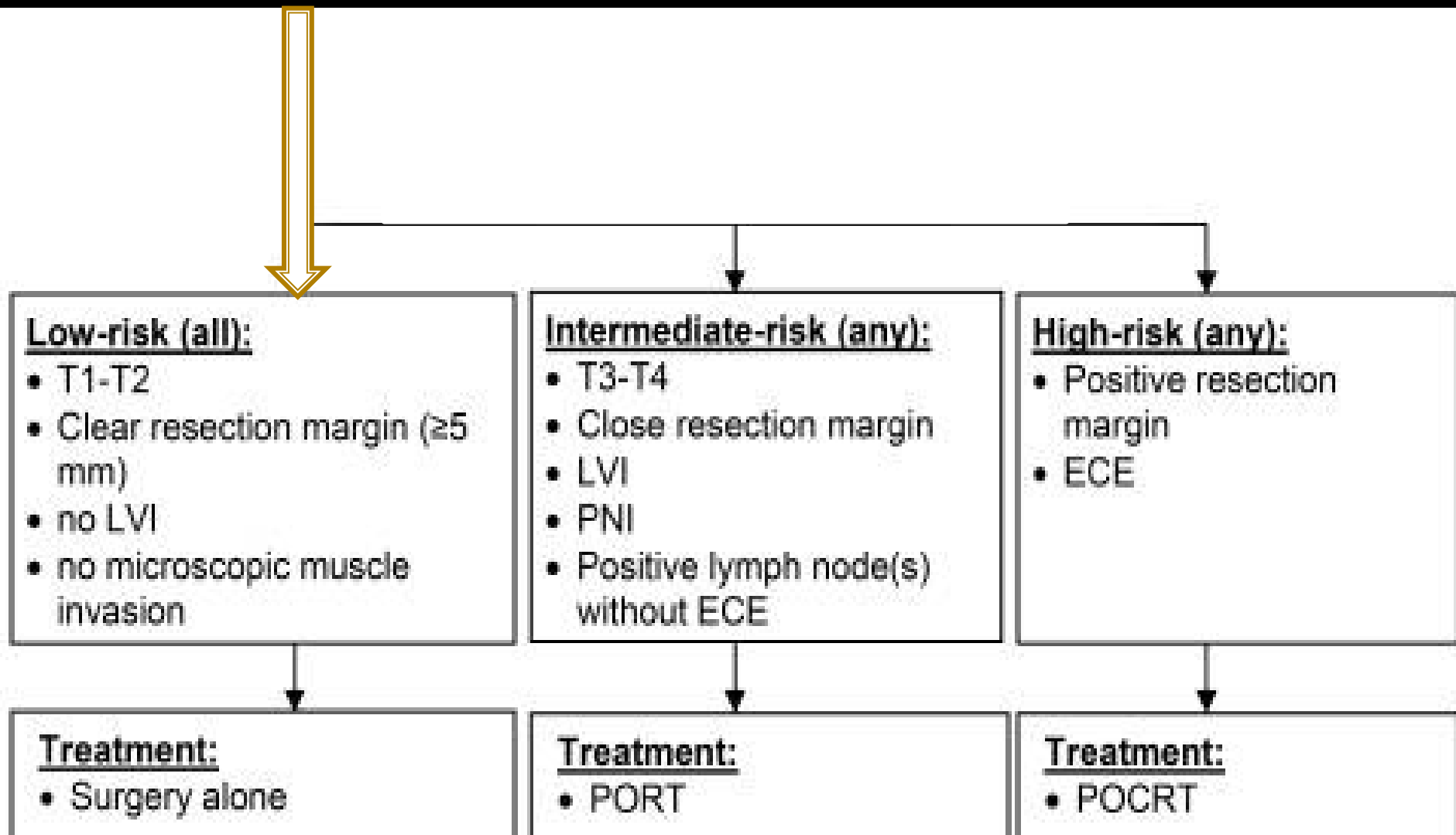
What to look for?

Pathologic factors predictive for Post op radiotherapy delivery

A. Primary Tumour

B. Cervical Node

When to say no to RT?



Primary tumour: Important parameters include

- ❖ pT₃* or pT₄ primary
- ❖ Close (<5 mm) or Positive margins (Preferred option is resection if possible)
- ❖ Perineural invasion
- ❖ Lympho-vascular invasion
- ❖ Tumor thickness (cut off point was 4 mm according to [Huang SH et al](#))

Cervical node parameters

- ❖ Single node positive with extracapsular extension
- ❖ Two or more positive lymph nodes

Bilateral Irradiation

Lesion involving midline structures or crossing midline

- Tip of Tongue
- Central arch
- FOM
- Soft Palate
- Hard palate
- Tumor crossing midline (i.e Ant 2/3 of tongue) etc.

Indication for adjuvant CCRT

1. Extracapsular nodal spread
2. Positive resection margins.

Dose escalation

- $\approx 60\text{Gy}$: Generally planned dose in Postoperative condition
- $>66-70\text{Gy}$: Gross residual disease ,Extra capsular nodal extension

Question

- A 54 year-old women recently had a resection of a squamous cell cancer of the supra-glottis with B/L neck dissection. The pathology shows a T2 lesion, which was completely excised with negative margins but having PNI and LVI. There are 2 of 28 lymph nodes (Level II) positive with ECE on right side and no node positive on left. What is the most appropriate for this patient?
- A) Observation
- B) Radiation
- C) Chemotherapy only
- D) Chemo-radiation

- Nodal area irradiation ???
 - In phase I
 - In Phase II
 - IN Phase III

Thank you

