

Management of Vaginal and Vulval Cancers

Dr. Manish Gupta,
Associate Professor, Department of Radiation Oncology
MGIMS, Sevagram
DAY I, SATURDAY,
OCT. 24, 2015
1135 – 1155

- Vaginal Cancer
- VAIN
- Vulval Cancer

- Introduction & Epidemiology
- Presentation
- Diagnostic Workup
- Staging
- Treatment
- Outcomes

Vaginal Malignancy: introduction

- 1-2 %
- Primary vaginal malignancy: Rare
- Defined: a lesion that arises in the vagina without involving the cervix or vulva.
- Common: Metastatic from other gynecologic malignancies or direct extension from adjacent sites
- A diagnosis of primary vaginal cancer excludes any tumors involving the cervix or vulva. (FIGO)

- Pathology: squamous cell carcinomas (SCC).
- Posterior Vaginal lesions more common than anterior & the anterior are more common than lateral lesions.
- Peak Age: sixth and seventh decades of life
- Incidence increasing in younger women: HPV infection or other sexually transmitted diseases.
- An overall decrease incidence: earlier detection and to implementation of strict exclusion criteria in the FIGO staging system.
- Treatment recommendations : Individualized

Epidemiology

- Risk Factors: (as in VAIN)
 - HPV infection,
 - History of CIN,
 - Vulvar intraepithelial neoplasia,
 - Immunosuppression, and
 - History of pelvic radiation (controversial)
- early onset of intercourse, increased number of lifetime sexual partners, and smoking.

26% stage I,
37% stage II,
24% stage III,
and
13% stage IV.

- HPV DNA detectable :
 - 80% of patients with in situ disease and
 - 60% of those with invasive disease, and
 - 30% of patients reported a history of treatment for invasive malignancy, most commonly cervix or in situ anogenital neoplasia
- 75% of specimens : positive for HPV.
- HPV-16 : 72% of positive samples.

Clinical Presentation

- Extend the vaginal walls
 - Along the wall
 - Radials
 - Anterior wall lesions
 - Posterior wall lesions
- Presents as
 - nodular,
 - ulcerated,
 - indurated,
 - exophytic, or
 - endophytic lesions
- Most frequently site: the superior one-third of the vaginal canal

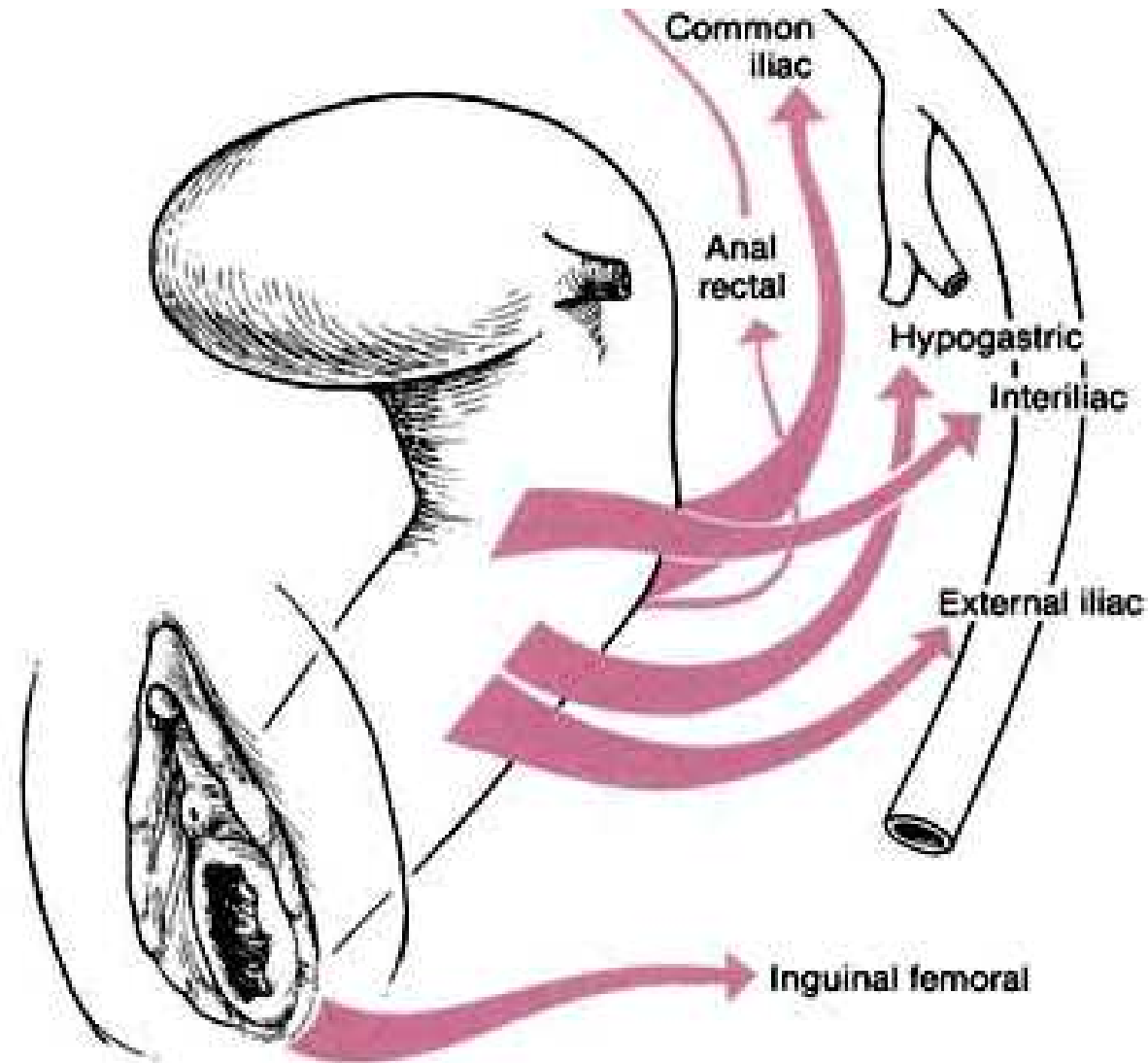
- 65% : irregular vaginal bleeding as primary symptom
- Vaginal discharge : the second most common 10% to 15%
- Locally advanced disease symptoms:
 - the presence of a mass;
 - Pain;
 - urinary symptoms, including frequency, dysuria, or hematuria; or
 - gastrointestinal complaints such as tenesmus, constipation, or melena.
- 20% of women : asymptomatic at the time of diagnosis

- Verrucous carcinoma : a distinct histologic variant of vaginal SCC that commonly presents as a well-circumscribed, soft, cauliflower-like mass that is microscopically well differentiated, with a papillary growth pattern and acanthotic epithelium
- Less aggressive behaviour and rarely metastasizes
- Considered a distinct entity from other vaginal SCC.

Patterns of Lymphatic Drainage

- Complex: considerable crossover drainage
- True incidence of positive lymph nodes: difficult as main treatment with radiation therapy
- Location of the primary tumour: not a reliable indicator
- The upper vagina : obturator and hypogastric nodes (as cervix).
- The lower vagina : inguinal, femoral, and external iliac nodes
 - posteriorly situated lesions : inferior gluteal, presacral, or perirectal nodes
- The risk of nodal metastasis appears to increase significantly with stage
 - 0% to 14% in stage I and
 - 21% to 32% in stage II
 - stages III and IV : 78% and 83%, respectively
- Hematogenous metastasis : the lung, liver and bone.

Lymphatic Drainage of Vagina



Diagnostic Workup

- History and physical examination with careful pelvis Exam.
- Examination under anaesthesia: recommended for complete assessment of tumour extent and assessment of vaginal walls
- Speculum examination: obscure the anterior and posterior walls :::::::::: rotate
- Bimanual examination with careful digital palpation
- Biopsy of suspected lesions
- Inguinal nodes
- Laboratory tests: a complete blood count with differential and assessment of renal and hepatic function.
- Chest x-ray, barium enema
- Cystoscopy or Proctosigmoidoscopy : bladder or rectal infiltration.

- CT & MRI : FIGO stage not affected; commonly used.
- MRI : for treatment planning
- MRI Advantages: superior soft tissue contrast resolution, allowing accurate assessment of tumour volume and extent of local invasion, and accurate assessment of pelvic-nodal involvement.
- Positron emission tomography (PET):
 - detect the extent of primary tumour and abnormal lymph nodes in vaginal cancer with higher sensitivity than CT
 - detects primary tumour and abnormal lymph nodes
 - empty bladder prior to imaging,

Staging: F.I.G.O.

Prognostic Factors

- Stage at time of presentation

Treatment:

- Definitive radiation is the treatment of choice
- Surgery :
 - highly selected patients with early-stage lesions
 - previously irradiated patients
- Types of Surgery:
 - A wide local excision
 - radical hysterectomy, upper vaginectomy, and bilateral pelvic lymphadenectomy,
 - a total vaginectomy with radical hysterectomy, pelvic lymphadenectomy, and possibly vulvovaginectomy and inguinofemoral lymphadenectomy.
- Exenteration
 - Anterior exenteration
 - Posterior exenteration
 - A total exenteration

Treatment: Radiation

- Stage I: brachytherapy alone (60 to 70 Gy 5 mm vaginal mucosa i.e vaginal surface 80 to 120 Gy)
- More failures with brachytherapy alone: EBRT with or without brachytherapy
- The entire length of the vagina treated :
 - a mucosal dose of 60 to 65 Gy, with an additional mucosal dose of 20 to 30 Gy delivered to the area of tumor involvement
- LDR,
 - treatment can be delivered in two applications, with the first designed to treat the entire vaginal wall and a second application to cover the tumor volume.
 - This can be delivered with a shielded vaginal cylinder to treat the tumor with a 2-cm margin and block uninvolved mucosal surfaces.
- HDR can also be used to treat superficial lesions.
 - In general, the vaginal mucosa is treated to a dose of 21 to 25 Gy, prescribed to a depth of 5 mm, in weekly fractions of 5 to 7 Gy each. An additional 21 to 25 Gy, prescribed to a depth of 5 mm, is delivered to the tumor via shielded vaginal cylinder, with weekly fractions of 5 to 7 Gy, to bring the total dose to 42 to 50 Gy.

- For lesions thicker than 5 mm:
 - Intracavitary + interstitial brachytherapy
 - a vaginal cylinder typically delivers 45 Gy (LDR) or 21 to 25 Gy (HDR) to a depth of 5 mm into the vaginal mucosa.
 - Subsequent therapy is delivered via interstitial implant, to deliver an additional dose of 25 to 35 Gy (LDR) to the tumour volume
- More extensive stage I lesions:
 - A combination of EBRT and brachytherapy is suggested for that exhibit greater infiltration or poor differentiation
- Incorporating EBRT into treatment of all stage I patients, except for those with very small, superficial lesions

Stage II

- Radiation is the primary treatment for stage II disease
- A combination of EBRT and brachytherapy (interstitial or intracavitary)
 - The pelvis dose 45 to 50.4 Gy in 1.8 Gy fractions
 - Parametrial boost if there is extensive primary infiltration or high suspicion of nodal disease.
 - Inguinal lymph nodes included for lesions involving the distal vaginal canal.
- Coverage of the entire tumour volume is critical for optimal outcome.
- Brachytherapy :
 - Tumors >5 mm in depth (interstitial technique, ideally with three-dimensional (3D) imaging for treatment planning)
 - Extensive tumors, or deeply infiltrating tumors with non-distinct margins : poor candidates for brachytherapy.
- Conformal techniques or intensity-modulated radiation therapy (IMRT): boosting tumors
- The tumour volume should receive a minimum of 75 to 80 Gy using combined EBRT and brachytherapy

Stages III and IVA

- The primary treatment: EBRT +/- Brachytherapy (certain cases additional dose to the parametrium)
- Brachytherapy is not feasible: IMRT is the choice
- Selected patients with small volume stage IV disease: pelvic exenteration can yield good long-term control

Role of Chemotherapy and Radiation

- Preoperative chemotherapy
- Concurrent Chemotherapy
- Palliative Chemotherapy

Outcomes

- 5-year disease-specific survival rates
 - 84% for stage I,
 - 75% for stage II, and
 - 57% for stage III or IV.

RADIOTHERAPY TECHNIQUES

- Techniques:
 - EBRT,
 - Brachytherapy
 - A combination of the two.
- Conformal radiation therapy: dose escalation
- Brachytherapy: Intracavitary or interstitial approaches (LDR or HDR techniques)
 - 3D-based image guided brachytherapy treatment planning for excellent outcomes.

External-Beam Radiotherapy

- Primary therapy
- Individualized: The treatment technique, dose prescription, and selection of the appropriate energy level
- The distal tumour margin important
- CT simulation : contouring of vessels as a surrogate for lymph node localization
- Inguinal nodes: a “frog leg” position
- Use of oral and intravenous contrast :
 - delineation of vascular structures
 - the contouring of bladder, small bowel, and rectum.
- Fusion of diagnostic pelvic MRI or PET-CT to the treatment planning CT : defining the tumour
- Techniques:
 - Two-Dimensional Treatment Planning
 - Three-Dimensional Conformal Treatment
 - Intensity-Modulated Radiation Therapy

Brachytherapy

- Suitability : Re-examined after EBRT
 - Superficial disease and ≤ 5 mm in thickness : Intracavitary treatment,
 - Thicker lesions : interstitial brachytherapy.
- Intracavitary
 - monotherapy
 - VAIN and
 - highly selected stage I
 - Boost
- Types as per Dose rate:
 - Low-dose-rate Intracavitary brachytherapy (LDR-ICB) vaginal cylinder loaded with cesium-137 radioactive sources.
 - High-Dose-Rate Intracavitary Brachytherapy

Interstitial Brachytherapy

- Any paravaginal extension at the time of diagnosis
- Lesions thicker than 5 mm,
- Distal vaginal extension, or
- Vagina unable to accommodate standard Intracavitary applicators.
- Interstitial brachytherapy : delivered after completion of all EBRT.
- Recently guidelines for vaginal interstitial brachytherapy from the American Brachytherapy Society : A total dose between 70 to 85 Gy EBRT is given along with LDR brachytherapy

- Brachytherapy Versus External-Beam Boost
- Limited literature on stereotactic body radiotherapy (SBRT)
- SBRT is not recommended instead of brachytherapy for vaginal cancer.

CONCLUSIONS

- Rare disease with a poor prognosis.
- Improvements in local control will yield superior patient outcomes.
- Optimizing delivery of radiation to tumor volumes while minimizing treatment toxicity remains critical for progress.
- 3D imaging, conformal external-beam treatments, and image-guided brachytherapy in gynecologic malignancies should optimize the efficacy and precision of radiation dose delivery.
- randomized clinical trials Difficult: the low incidence of vaginal cancer
- Single-institution series : important in guiding our understanding and management of this disease.

Vaginal Intraepithelial Neoplasia(VAIN)

Vaginal Intraepithelial Neoplasia(VAIN)

- Definition: the presence of squamous cell atypia without evidence of invasion
- Incidence: 0.2 to 0.3 cases per 100,000
- Peak incidence between 40 and 60 years of age
- Risk factors include:
 - low sociocultural level, history of genital warts, hysterectomy at an early age, history of cervical intraepithelial neoplasia, immunosuppression, prior pelvic radiation, smoking, exposure to diethylstilbestrol (DES), and history of sexually transmissible diseases (STDs) or HPV infection.
- Increase in risk of invasive vaginal cancer
- 2% to 20% of patients with VAIN progressing to invasive vaginal cancer
- Asymptomatic ; commonly detected after cytologic evaluation as part of surveillance in patients with a history of CIN or invasive cervical carcinoma

- Classification:
 - VAIN1: lower one-third
 - VAIN2: two-thirds
 - VAIN3: greater than two-thirds of the epithelium
- CIN encompasses the full epithelial thickness and is included under VAIN-3.
- VAIN is frequently multifocal and most commonly involves the upper portion of the vagina.
- Histopathologically, most lesions are epidermoid and exhibit full-thickness alterations with atypical mitoses and hyperchromatism
- Diagnosis: Vaginal smear, colposcopy, biopsy (even after hysterectomy).

Treatment of VAIN:

- Heterogeneous: no consensus on optimal treatment modality
- an individualized approach.
- Options:
 - Surgery: local excision, partial or total vaginectomy,
 - Laser vaporization,
 - Electrocoagulation,
 - Topical 5% fluorouracil (5-FU) administration,
 - Radiation
- VAIN-1 : close surveillance. (regress spontaneously)
- VAIN-2 : individualised based on disease extent and associated patient factors.
- VAIN-3 : more aggressive, as there is a higher likelihood of progression to invasive disease, including occult invasive disease

Radiation therapy and VAIN:

- Reserved for patients who relapse after more conservative treatments.
- Drawbacks to radiation include potential under treatment of occult invasive disease,
 - the risk of secondary malignancy and
 - long-term morbidity, although there are no prospective data available regarding the impact of treatment on sexual function and quality of life.
- LDR : an intracavitary vaginal cylinder (cesium-137; a dose of 60 Gy prescribed to the vaginal mucosa)
- HDR:
 - 34 to 45 Gy to the vaginal surface, in 8.5-Gy fractions delivered twice a week or 4.5-Gy fractions delivered 4 times a week.
 - dose of 23.3 Gy (range, 15 to 30 Gy); most treatments were delivered in 5 fractions using two ovoids, with dose calculated to a point 1 cm superior to the vaginal apex.

Vulval Cancers

Vulval anatomy

The vulva (external genitalia) includes:

- Mons pubis
- Clitoris
- Labia majora and minora
- Perineum: the vaginal orifice to the anus ; covering the perineal body; length is 2-5 cm or more.
- Vestibule: a forecourt or a hall next to the entrance. It is the area of smooth skin lying within the L. minora & in front of the vaginal orifice.
- Hymen.

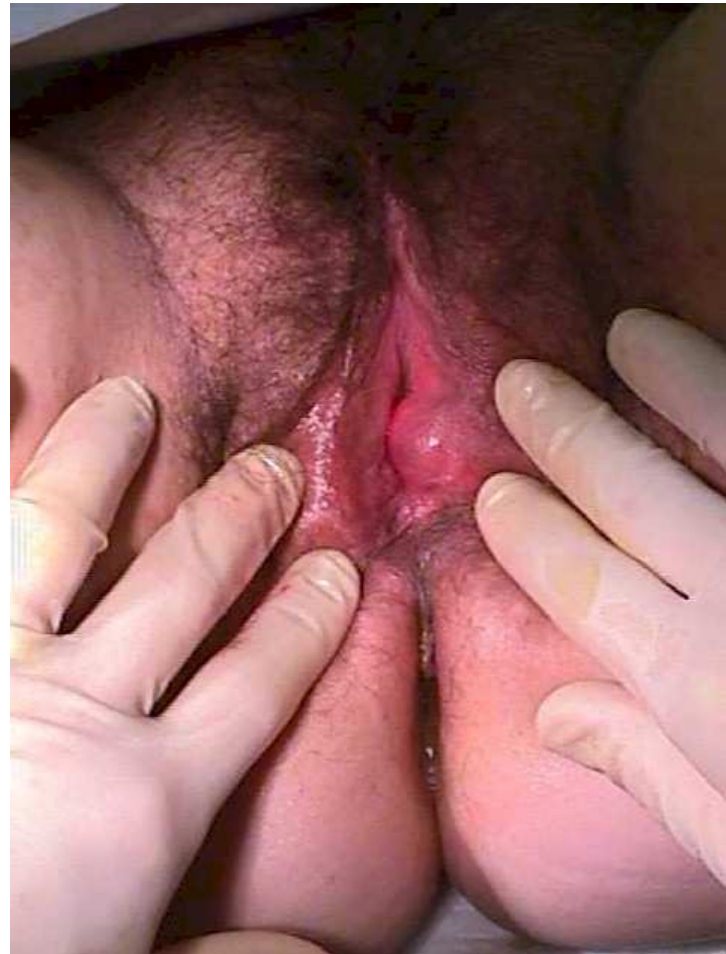Non-neoplastic epithelial disorders

Classification:

1. Lichen sclerosis.
2. Squamous cell hyperplasia (formerly: hyperplastic dystrophy).
3. Other - dermatoses.
 - lichen planus.
 - psoriasis.
 - seborrhoeic dermatitis
 - inflammatory dermatoses.
 - ulcerative dermatoses.

Bartholin Duct Cyst

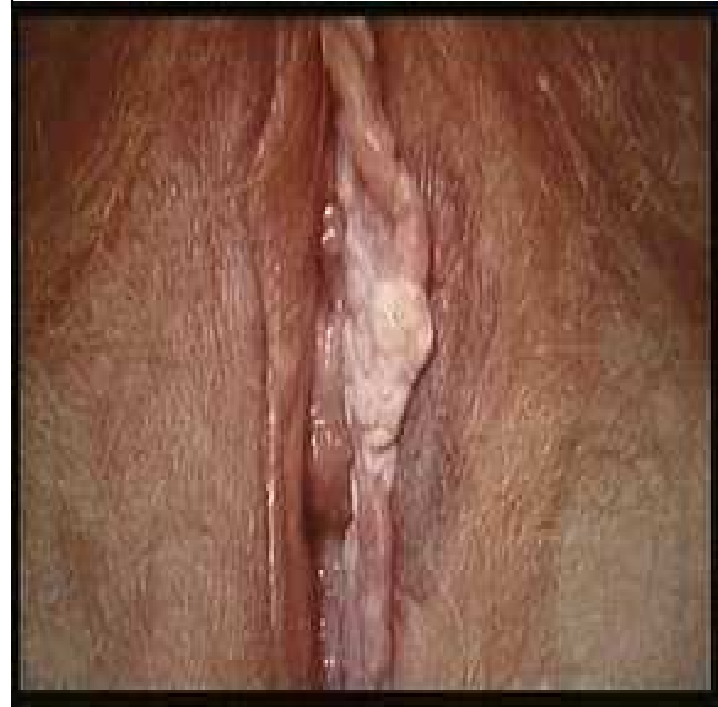- Most common Vulval cyst.
- Usually unilateral, on the posterio-lateral side of the introitus.
- usually about 2 cm & contains sterile mucus.
- Usually asymptomatic
- secondary infections : Bartholin's abscess.
- Rx: excision or Marsupialization.



Vulval Carcinoma

- Rare (1000 new cases/year in UK).
- Epidermal origin
- 60-75 years (Biphasic Distribution)
- 20% in patients UNDER 40 and appears to be increasing
- Melanoma : second most common type (4-9%).

- 85% Squamous Cell Carcinoma
- 5% Melanoma
- 2% Sarcoma
- 8% Others



Aetiology

- Vulval dermatomes (lichen sclerosis): HPV 16 & 33
- Vulval Intraepithelial Neoplasia (VIN) :
 - 80% will lead to invasive cancer at 10 years if not treated & 7-8% if treated.
 - VIN3 is a pre-invasive condition.
- Human papilloma virus (HPV):
 - 30% of Vulval cancer
 - 80-90% of Vulval cancer in women less than 50 years of age.
- Smoking: co-factor of HPV & VIN development.
- VIN affects mainly Labia minora & perineum.

Lymphatic Drainage

- Inguinofemoral nodes:
 - the triangle formed by the inguinal ligament superiorly, the border of the sartorius muscle laterally, and the border of the adductor longus muscle medially.
- Superficial inguinal lymph nodes:
 - along the saphenous vein and its branches between Camper's fascia and the cribriform fascia overlying the femoral vessels.
- Labial lesions : superficial inguinal and femoral lymph nodes
- Fourchette and perineum: follow the lymphatics of the labia

- sites:
 - 70% labia majora and minora,
 - 15% in the clitoris,
 - 5% in the perineum and fourchette,
 - 5% in the prepuce Bartholin's glands and urethra,
and
 - 5% are too extensive at presentation to classify

Symptoms/signs

- Pruritus
- Mass
- Pain
- Bleeding
- Ulceration
- Dysuria
- Discharge
- Groin Mass

- Three types of growth pattern of squamous carcinoma:
 - confluent,
 - compact, and
 - spray or finger-like growth

Clinical Staging (F.I.G.O.):

PROGNOSTIC FACTORS

- Lymph node metastasis
- Inguinal node metastases: 50% reduction in long-term survival
- Pelvic nodal metastasis: more profound negative effect on survival

Diagnostic Workup

- History and physical examination with careful pelvis Exam.
- Multifocal: whole genitourinary exam.
- Special attention : inguino-femoral basins
- Biopsy of suspected lesions
- Laboratory tests: a complete blood count with differential and assessment of renal and hepatic function.
- Chest x-ray, CT & MRI
- MRI : for treatment planning
- Positron emission tomography (PET):

Treatment of Vulval Carcinoma

- Challenging
 - Older and have comorbidities.
 - easily involve adjacent organs such as the bladder and the rectum,
 - nodal involvement high.
 - major psychosexual impact
- Multimodality therapy (in sequence and/or in combination)
 - Chemotherapy,
 - Radiation, and
 - Surgery
- Surgical refinements in the surgical technique
 - primary closure of the perineal wound,
 - the use of the sartorius muscle, and
 - the use of separate incisions for the primary tumour and the inguinal nodes.
- Recent Technical advancement in Radiotherapy

Surgery: Early Disease

- Primarily Surgical:
 - Wide Local Excision
 - Radical Excision
 - Radical Vulvectomy with Inguinal Node Dissection
 - Unilateral
 - Bilateral
 - Possible Node Mapping (investigational)
- Positive Nodal Status Post-op:
 - 1 or 2 microscopic nodes < 5mm
 - 3 or more or >5mm

Surgery: Early Disease

- Small, favorable lesions, ≤ 2 cm in diameter and ≤ 5 mm in depth:
 - wide local excision Vs a radical vulvectomy
- Anterior lesions close to the clitoris: a radical vulvectomy to obtain satisfactory margins
- Higher risk for inguinal node metastasis : both groins evaluated and managed
 - Poorly differentiated tumors with >5 -mm invasion and vascular space involvement
 - Centrally located lesions within 1 cm of the introitus: (midline lesions) : both groins are at risk
- A deep node dissection is recommended if the superficial nodes are involved
- Primary tumors >2 cm: radical vulvectomy and bilateral groin dissection

Radiation

- Higher risk of local recurrence at the primary site: PORT
 - lymphatic-vascular invasion (LVI),
 - depth of invasion >5 mm,
 - margins <8 mm, and
 - microscopically positive margins
 - extracapsular extension (ECE) of tumour in the nodes
 - residual disease in the inguinal areas
- Definitive Radiation (+/- chemotherapy)
 - tumors close to the urethra, clitoris, or anal sphincter.
- Nodal involvement: Adjuvant radiation
- one pathologically positive node (<12 nodes submitted) :
PORT
- Brachytherapy: as a boost to the primary tumour and/or to the lymph nodes

Advanced Disease

- Standard of care: multimodality
- Concurrent Chemoradiotherapy:
 - definitive settings
 - preoperative
 - postoperative
- Exenterations : considered only for patients with advanced local recurrences after initial therapy and for whom there is no other alternative

- Local Recurrence in Vulva
 - Re-excision or radiation and good prognosis if not in original site of tumor
 - Poor prognosis if in original site
- Distal or Metastatic
 - Very poor prognosis
 - Palliative chemotherapy

- Special Tumor
 - Verrucous Carcinoma
 - Indolent tumor with local disease, rare mets UNLESS given radiation, becomes Highly malignant and aggressive
 - Excision or Vulvectomy ONLY

Thanks