

# **HDR Intracavitary Brachytherapy**

## **with USG Guidance**

**Dr. S.K Shrivastava**  
**Dr. Umesh Mahantshetty**  
**Dr. Supriya Chopra**

**TATA MEMORIAL CENTRE, MUMBAI.**

# Patient & Tumour

---

## Patient:

60 years old, diabetic  
No pallor / SC nodes

## Tumour:

Histological type: SQ CA  
FIGO Stage: IIA

---

## Initial clinical findings:

## Cystoscopy:

Not done

**Portio: Ulcero-proliferative disease 5x4 cm,  
involving both lips of cervix**

**Vagina: Fornices: all involved**

## USG:

**Cx mass: 4 x 4 cm**

**No pelvic / PA LN pathy**

**Kidneys: normal**

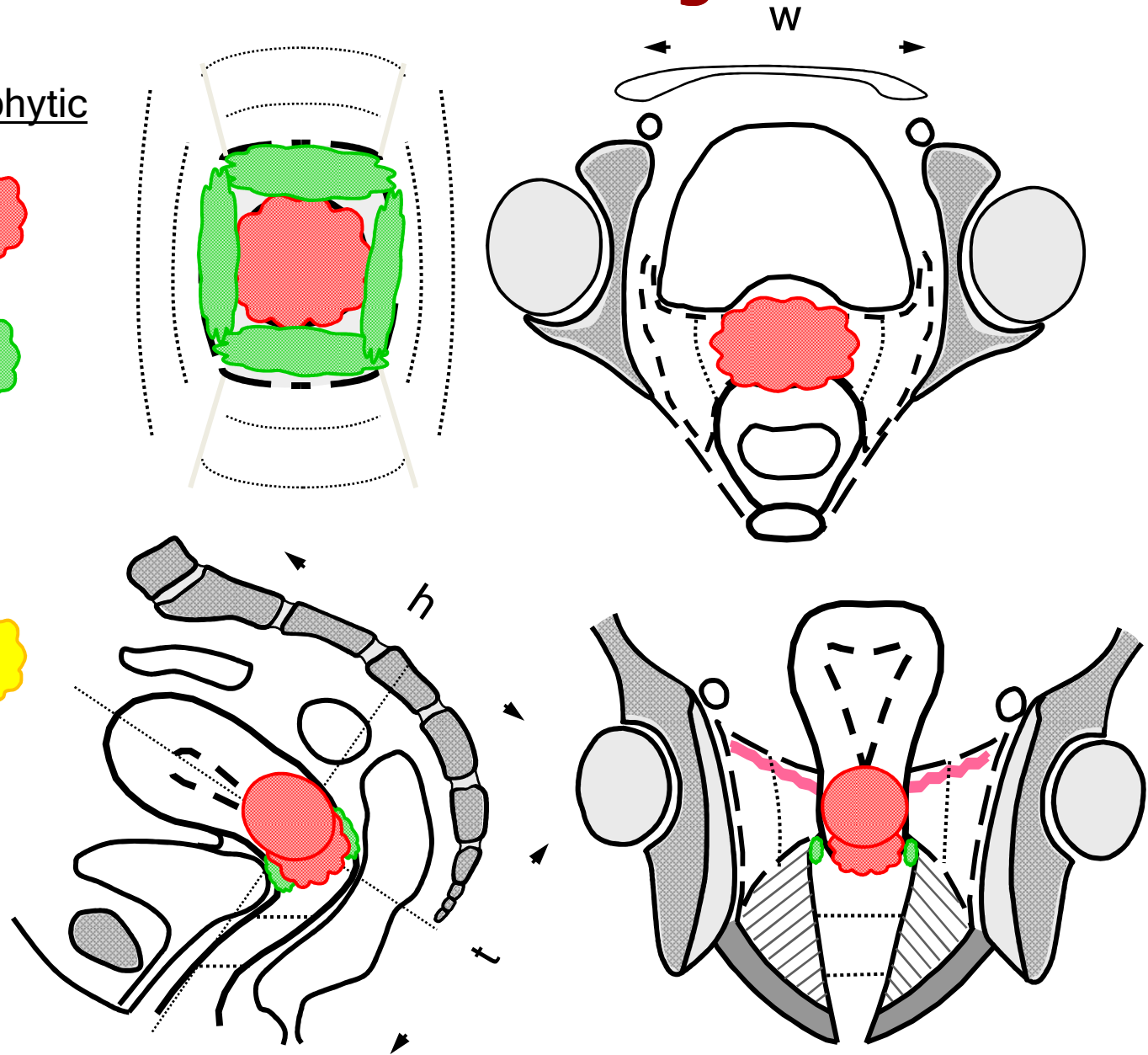
## Parametria:

Right: supple

Left: supple

# Initial clinical drawings

	<u>Infiltrative</u>	<u>Exophytic</u>
Cervix		
Vagina		
Parametria		
Rectum or Bladder		



**DIAGNOSIS: Carcinoma Cervix FIGO Stage IIA**  
**Rx PLAN : Radical Concomitant Chemo-radiation**

- Has completed till 15<sup>th</sup> September 2011
  - 30 Gy/ 15 # EBRT with 3# of weekly CDDP injections (40 mg/m<sup>2</sup>)
- **Response so far:**


Cervix bulky 2x2 cm growth over the cervix and left fornix.  
Bilateral parametria and rectal mucosa are free

# At Brachytherapy


## Clinical drawings

Infiltrative   Exophytic


Cervix



Vagina




Parametria



Rectum or

Bladder

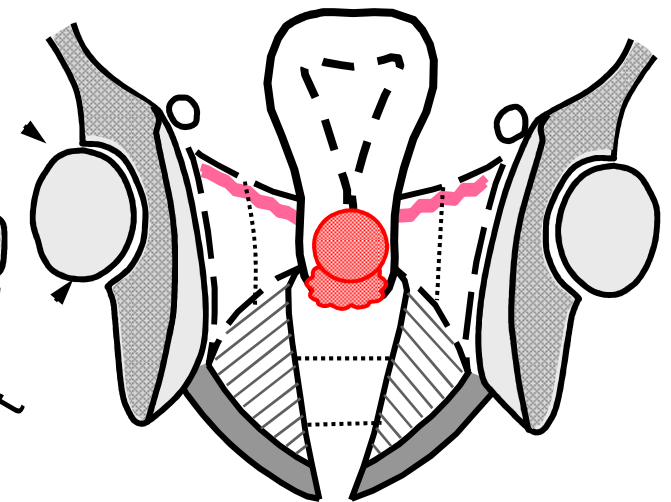
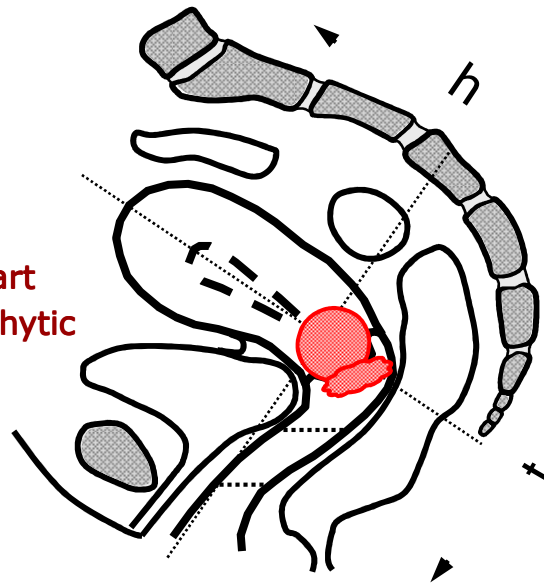
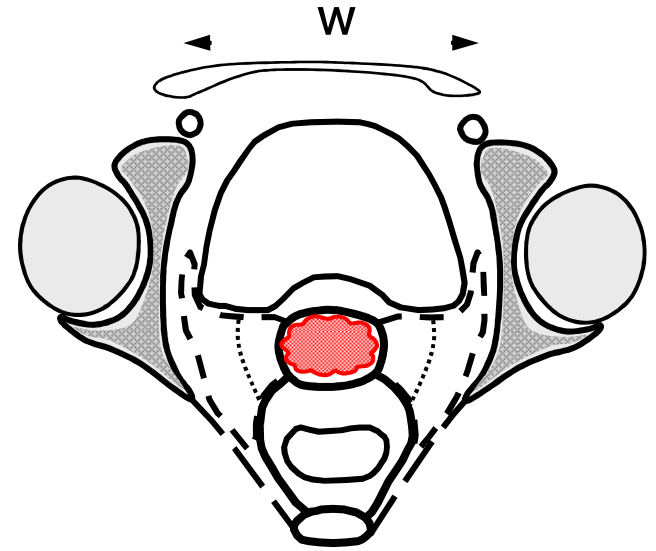
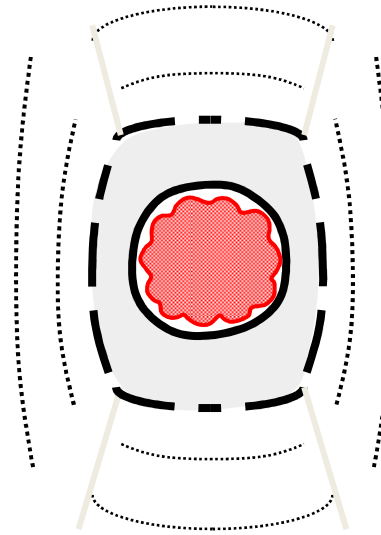


**Portio:**

- Significant regression of exophytic part
- Lower uterine segment bulky (endophytic residual disease)

**Vagina:**

- diameter (implications for selecting applicator diameter): **medium**



**LIVE PROJECTION**

**from**

**RADIATION ONCOLOGY O.T**