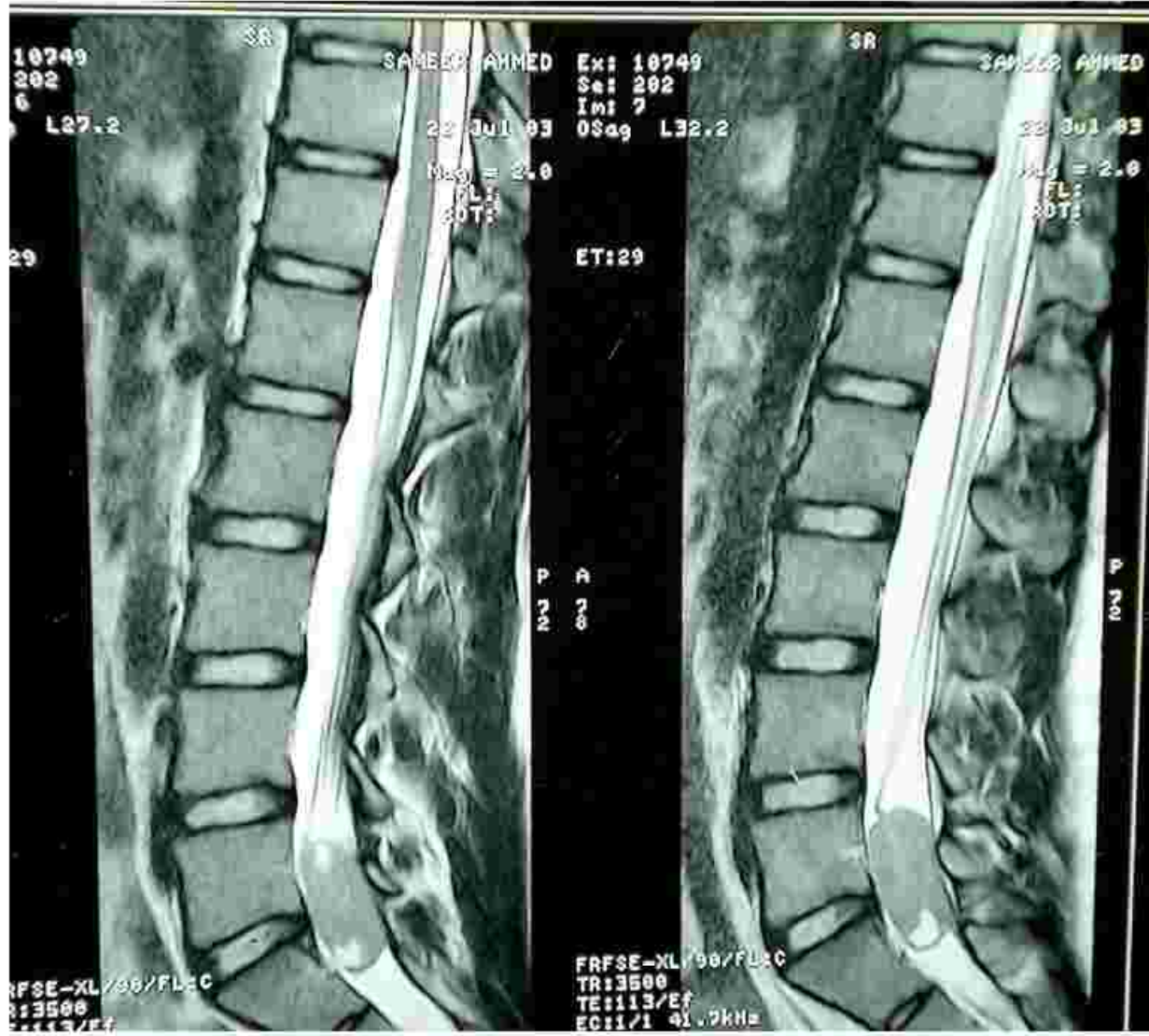

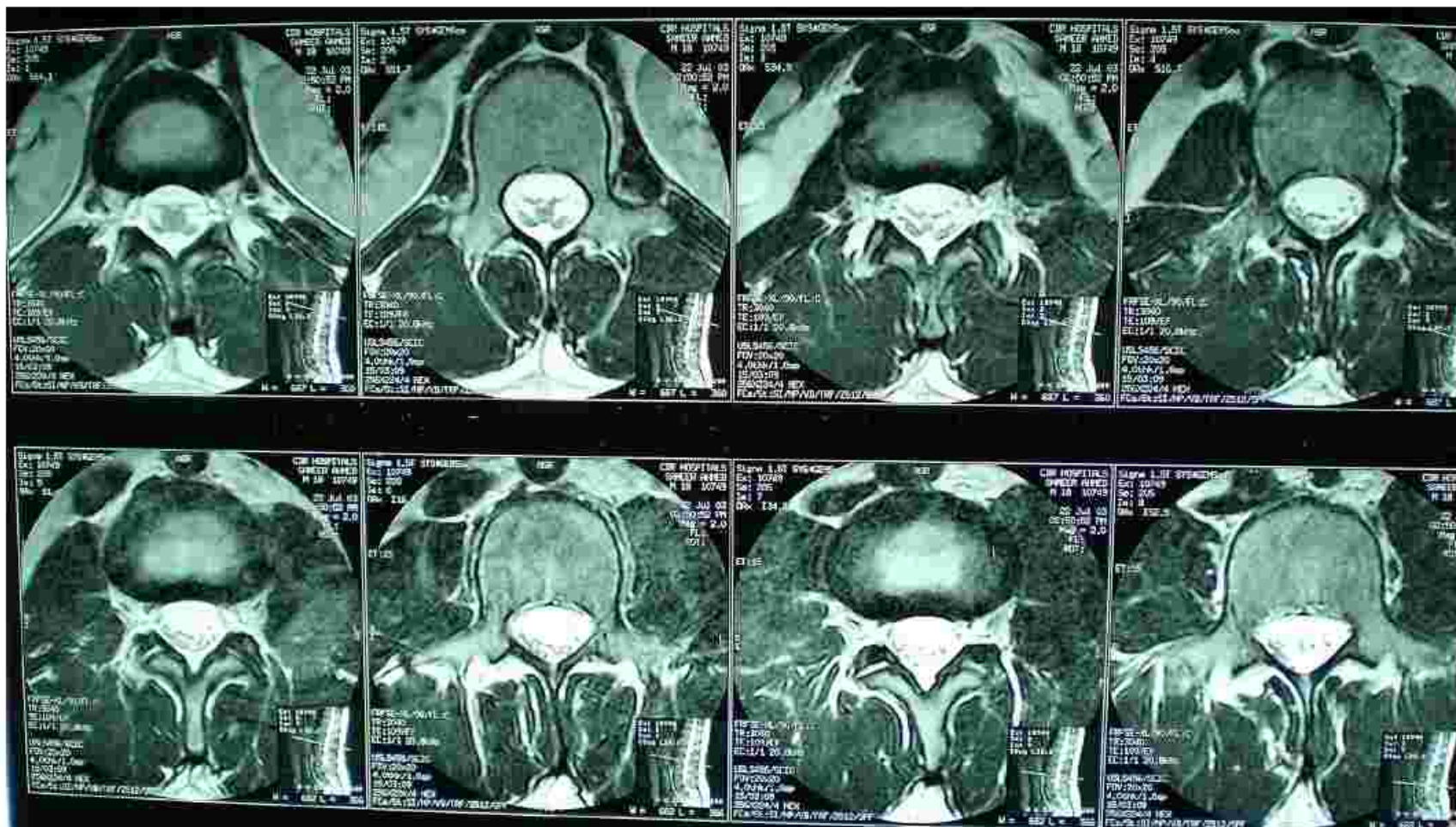
Mr. Sameer Ahmed 21,M

Pain in both lower limbs, early 2003,  
not responding to analgesics

# MRI, LS spine 22-7-2003



# MRI, LS spine 22-7-2003

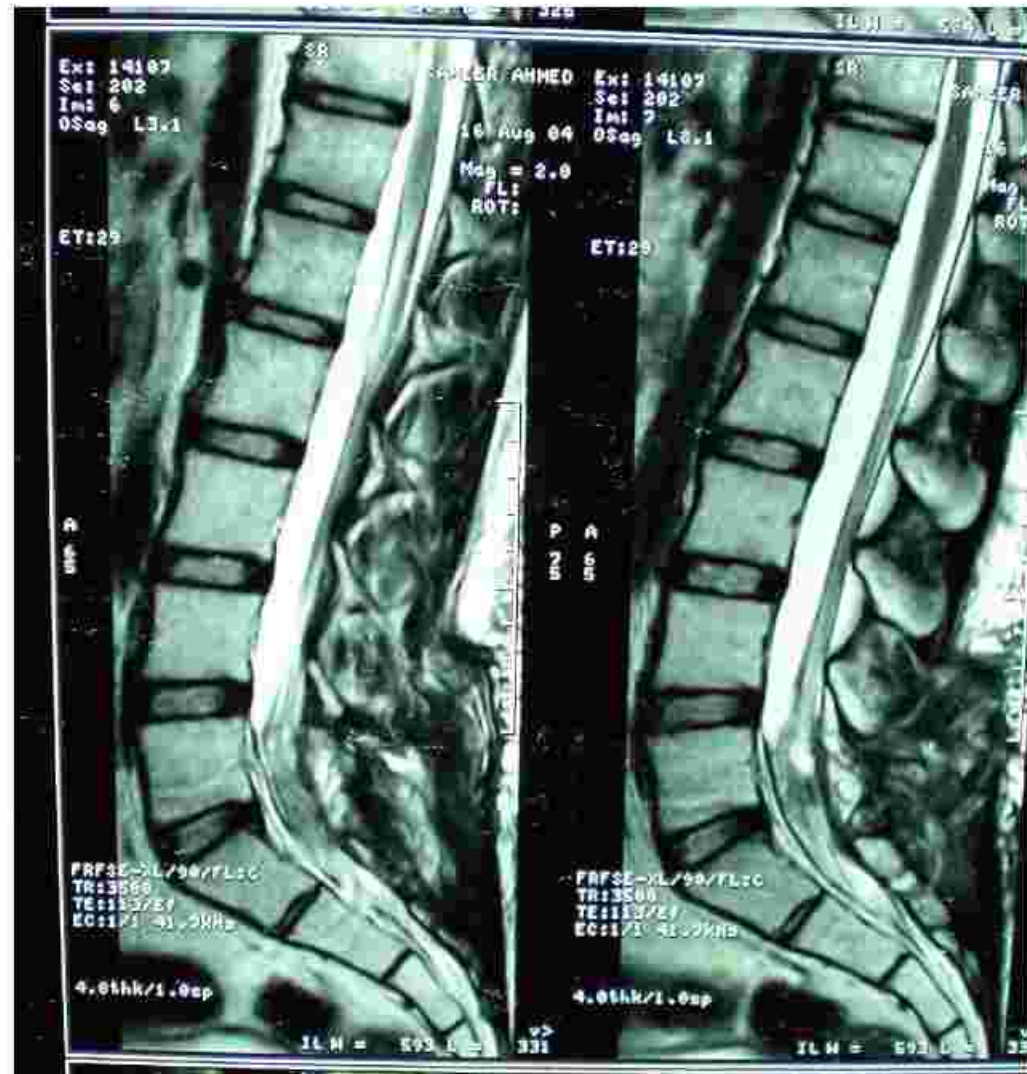



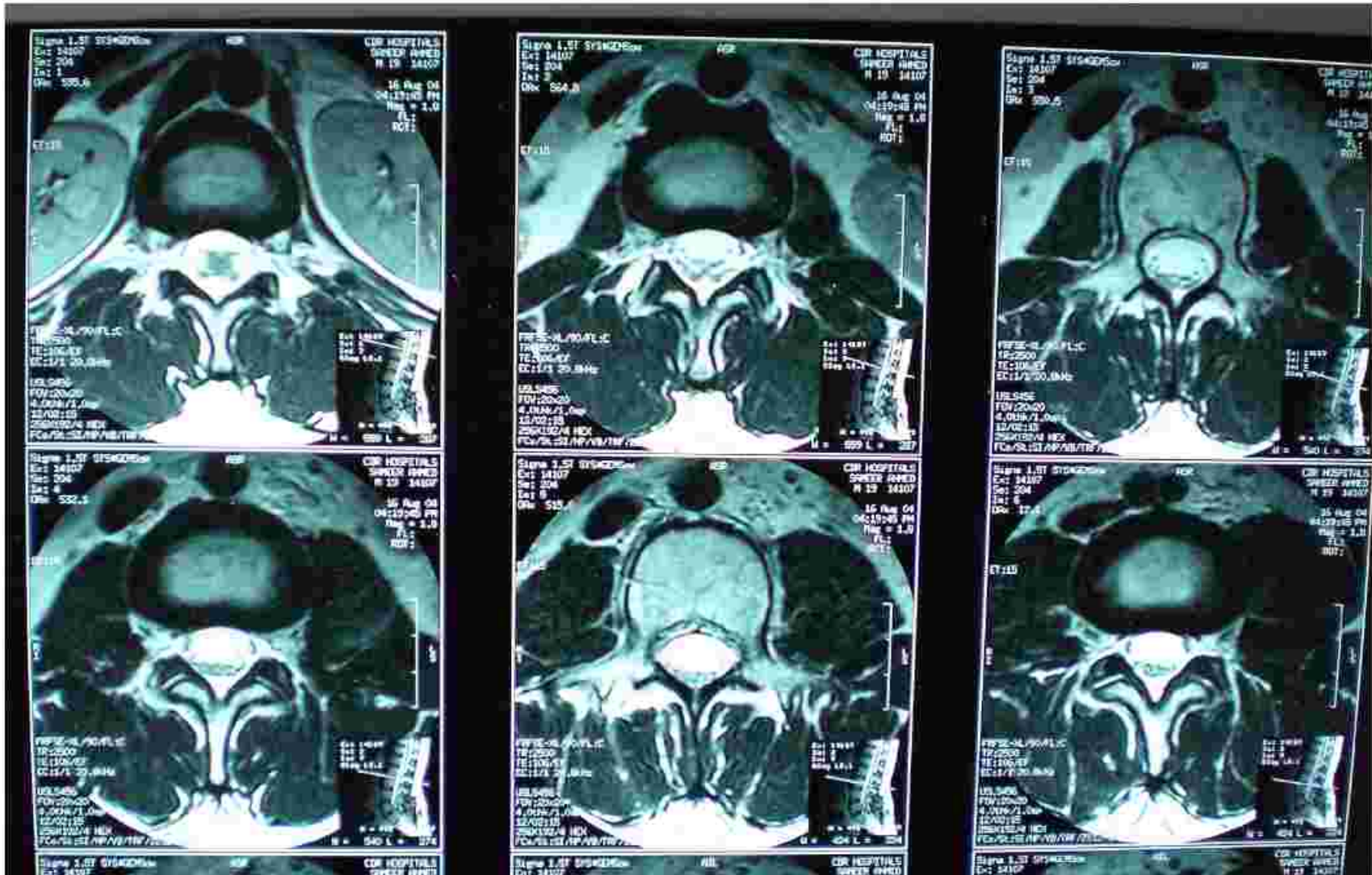
**Post Laminectomy and  
apparent complete  
removal, diagnosed as  
PNET.**

**Underwent Chemotherapy  
and radiotherapy (no  
details).**

**Post-treatment MRI, Aug,  
2004.**

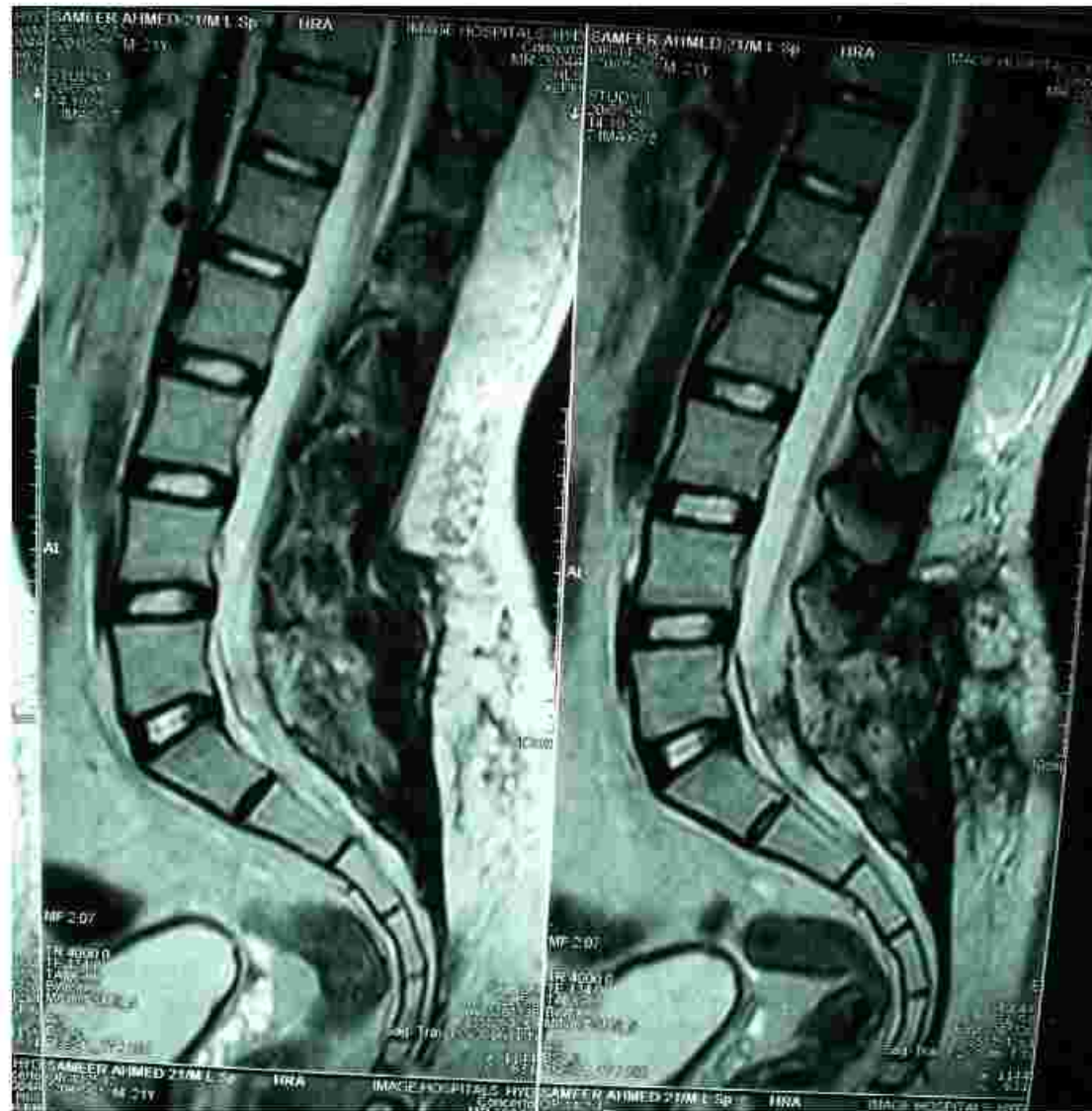

# Post-treatment MRI, Aug, 2004.

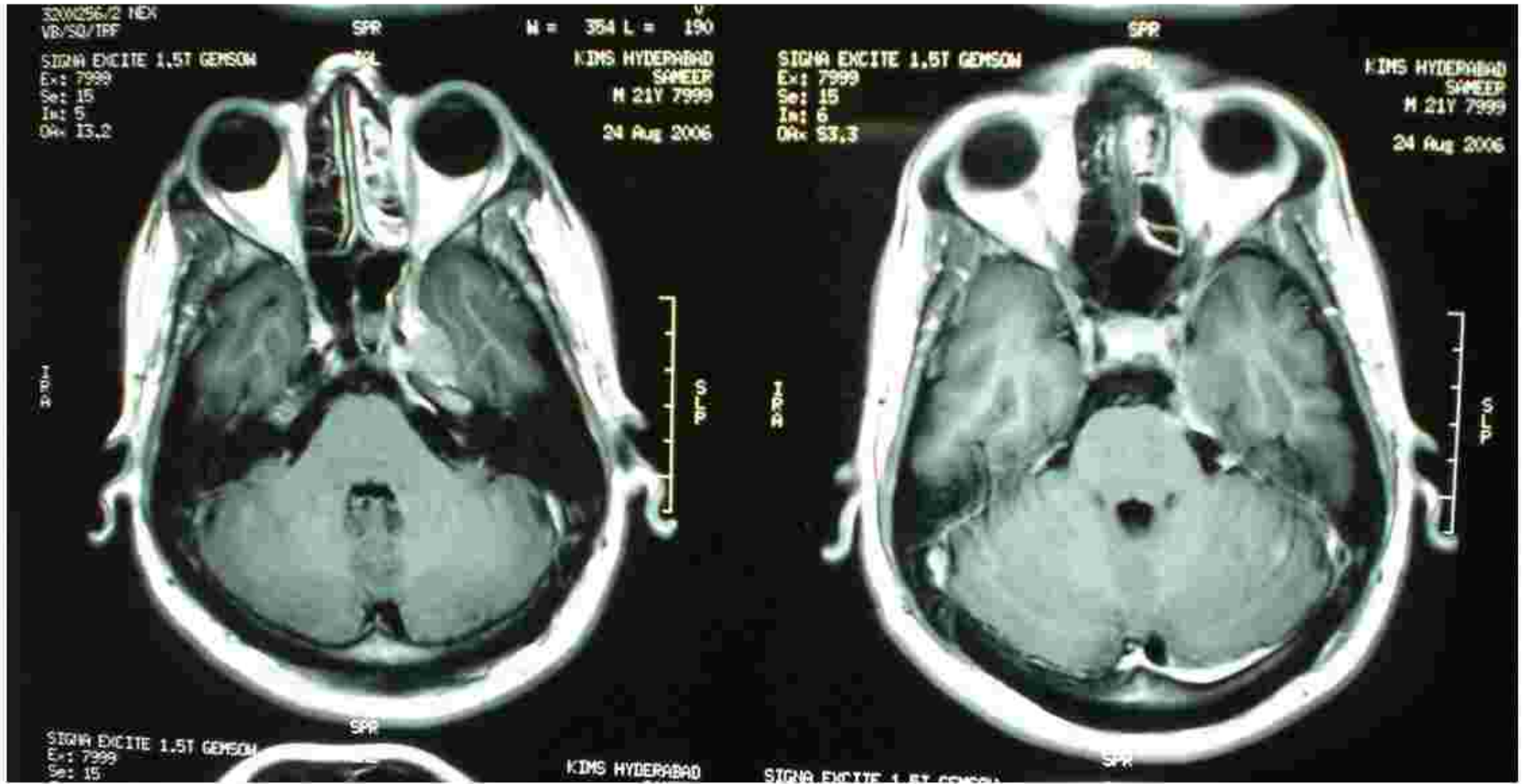



Post-treatment MRI,  
still on FU Aug, 2005.



**Numbness in (L) face and tongue Aug 2006. MRI 15-08-2006**



Underwent surgery on 16-9-06. Post-op MRI 22-09-2006

