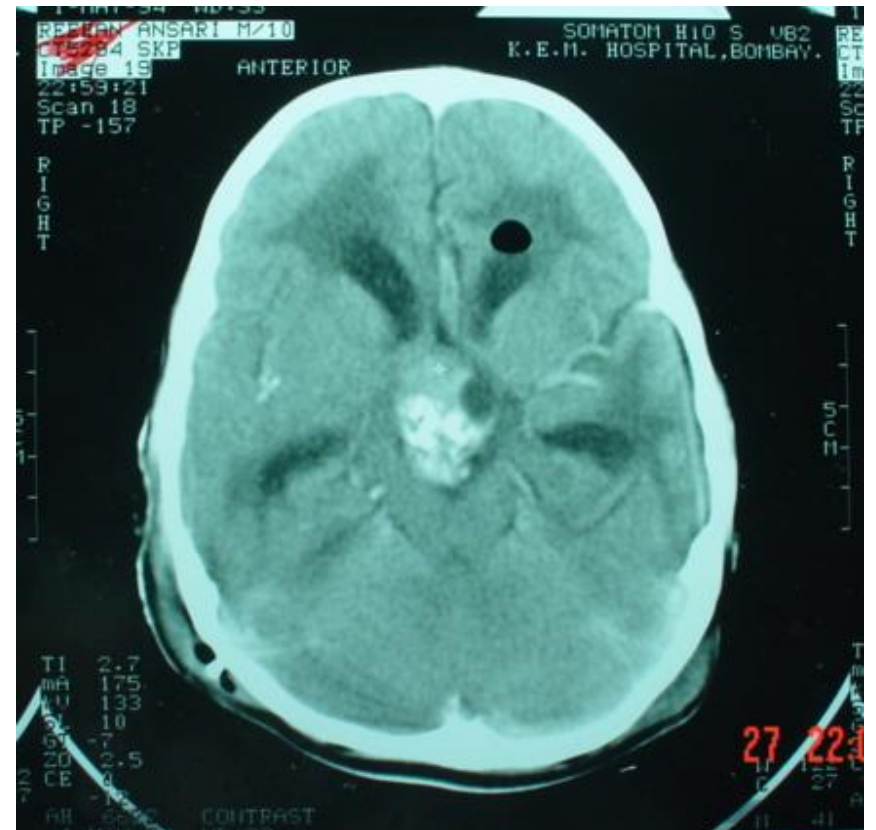
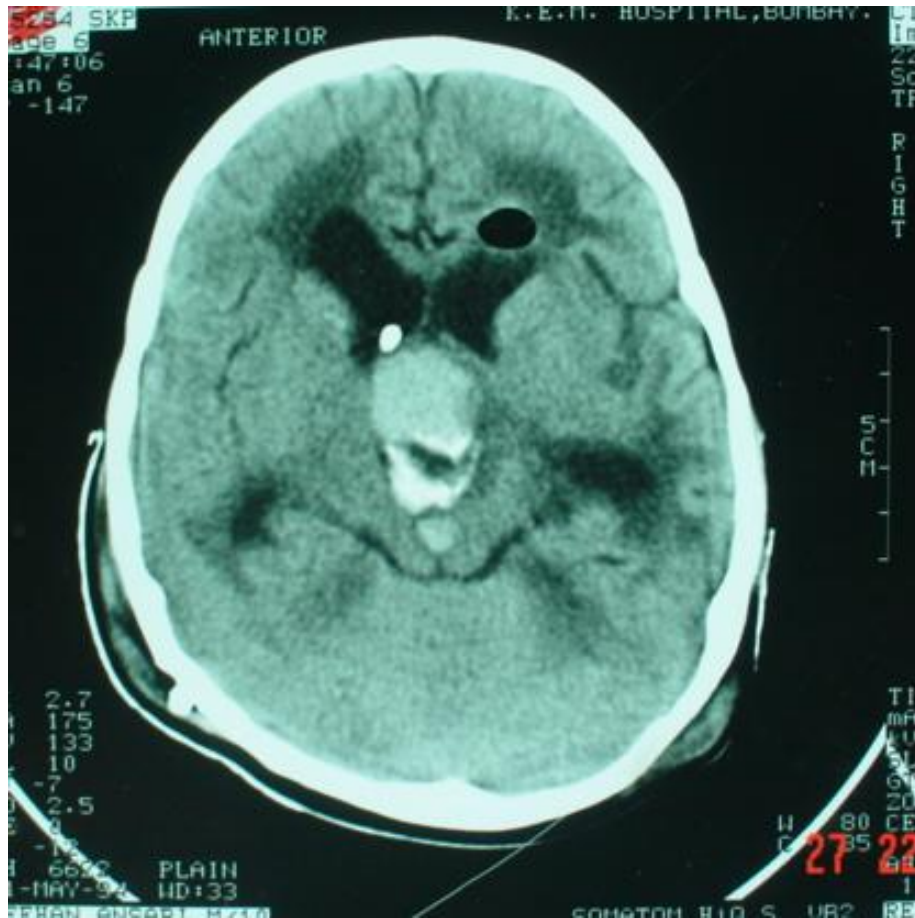

Case 2

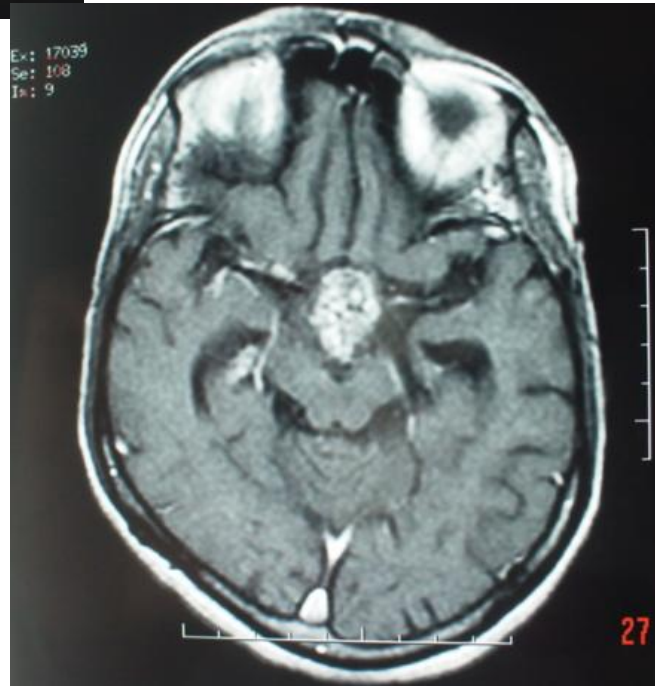
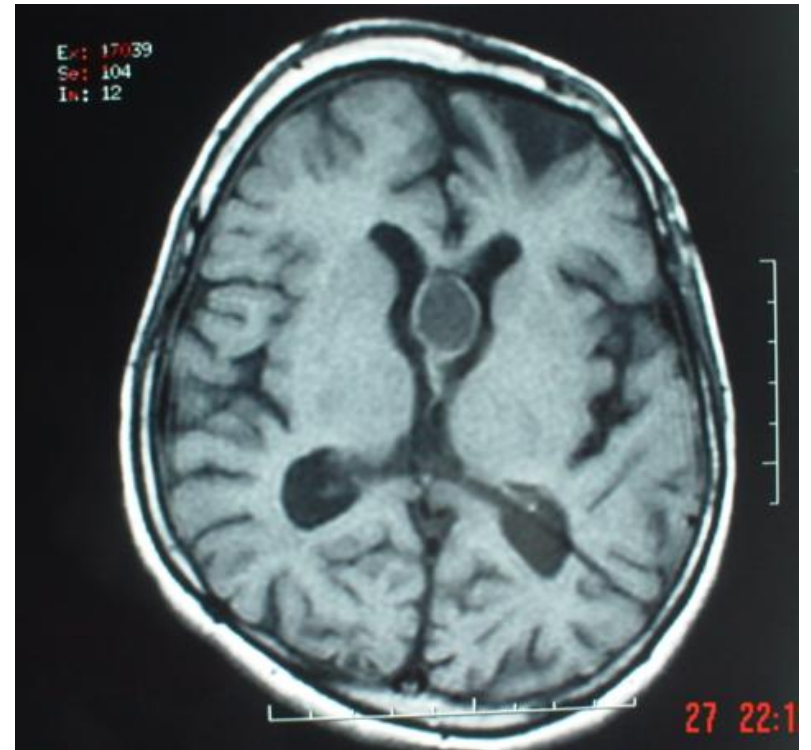
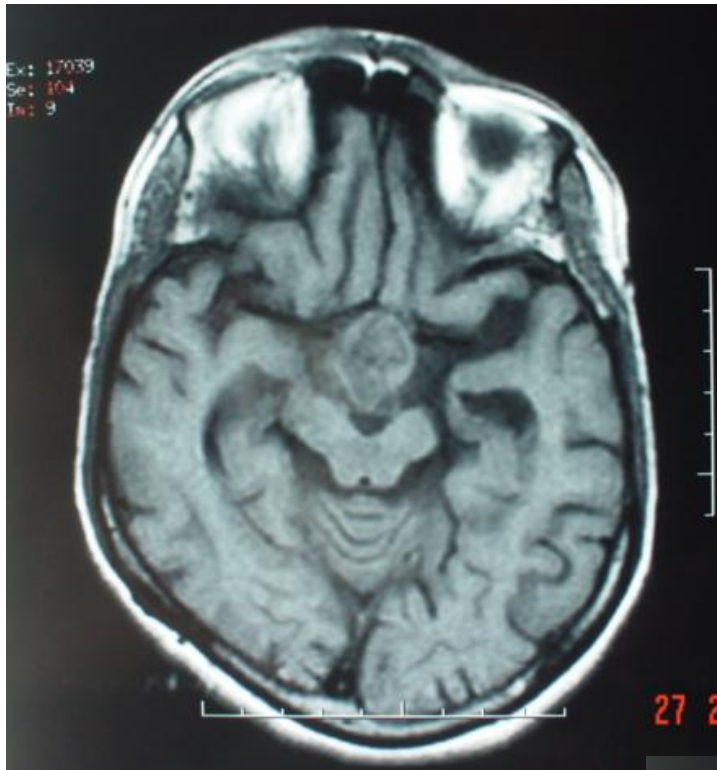
- **Ma. Rehan Ansari**, 20yr/ M
- **Apr 1994** – headache, vomiting since 2yrs
progressive deterioration of vision since 1 month
RE – FC 6 ft, LE – no PL
- **CT scan 25.04.1994** – cystic densely calcified suprasellar lesion
- **Sx 10.05.1994** - Lt frontal craniotomy with subtotal excision (tumour in proximity to pitutary stalk was left behind)
- **HPR** – craniopharyngioma
- **RT** – 5040cGy/ 28# with B/L portals till 22.09.94
- **VP** shunting done in V/O headache & vomiting



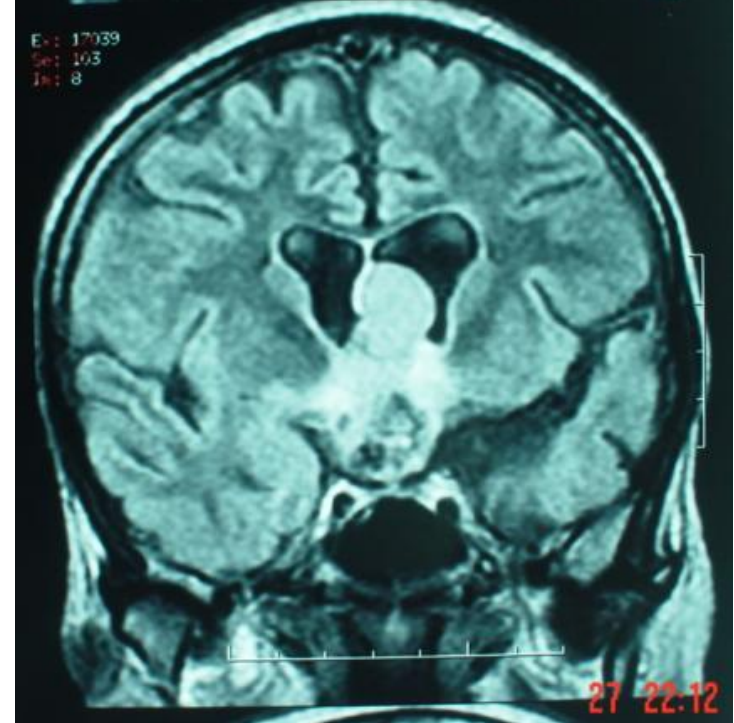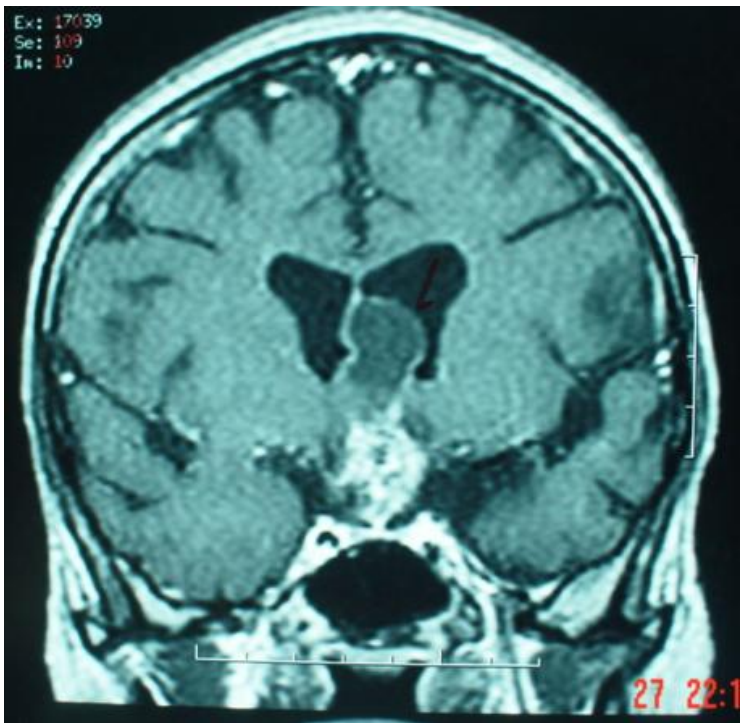
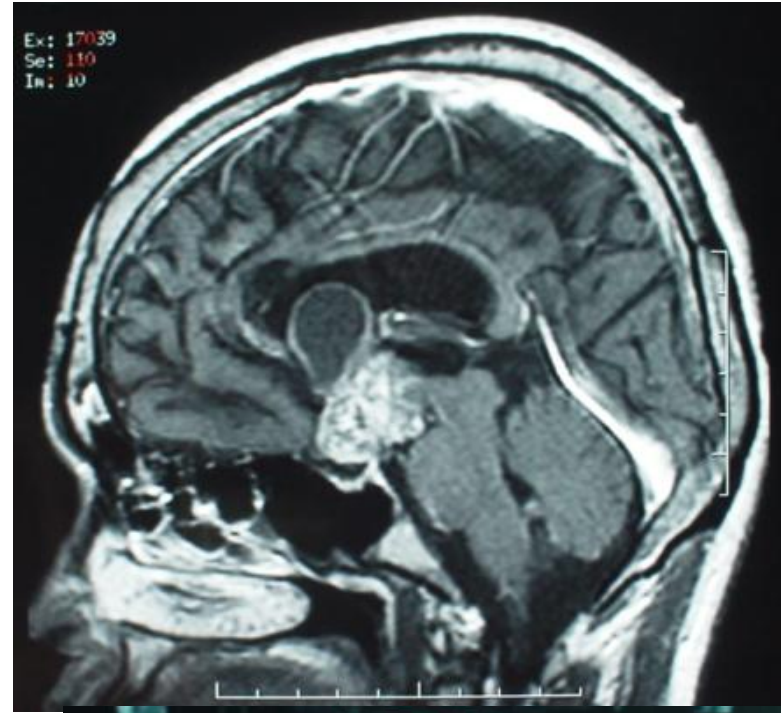
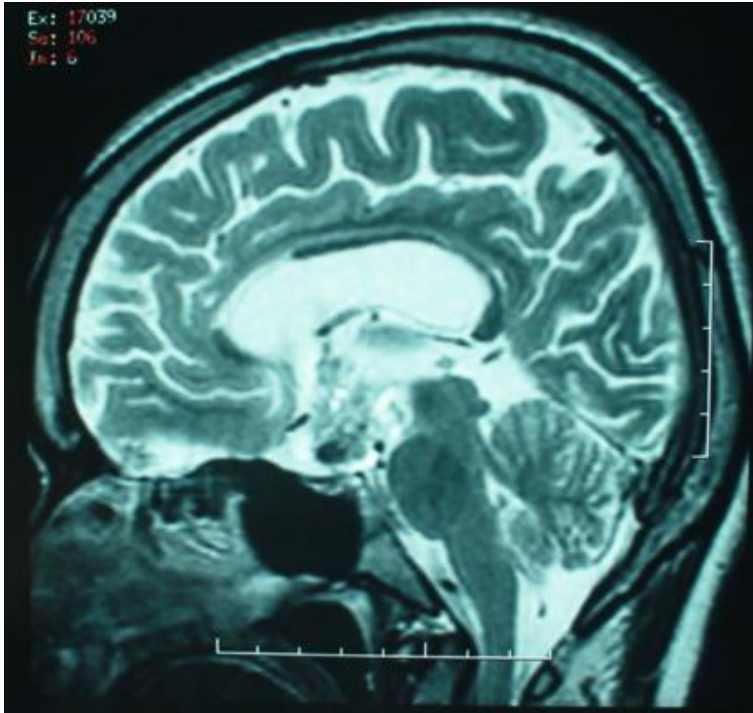
Pre op CT 25.04.1994

- **On regular follow up** without vision improvement till 1997, then lost to follow up.
- **2005** – h/o ? GTC. Started on Tab Eptoin
- **May 06** – headache & further deterioration of vision
- **MRI & CT 01.05.2006** – recurrence of lesion with calcification causing compression of optic chiasma & mild hydrocephalous.
- Stereotactic aspiration of cyst twice – transiently better
- **Sx 24.08.2006** – Excision of rec cranioph
- **Intraop** – calcification adherent to It optic nerve & ACA complex

- No improvement in vision, developed DI which responded to vasopressin
- No added neurodeficit
- ? To re irradiate



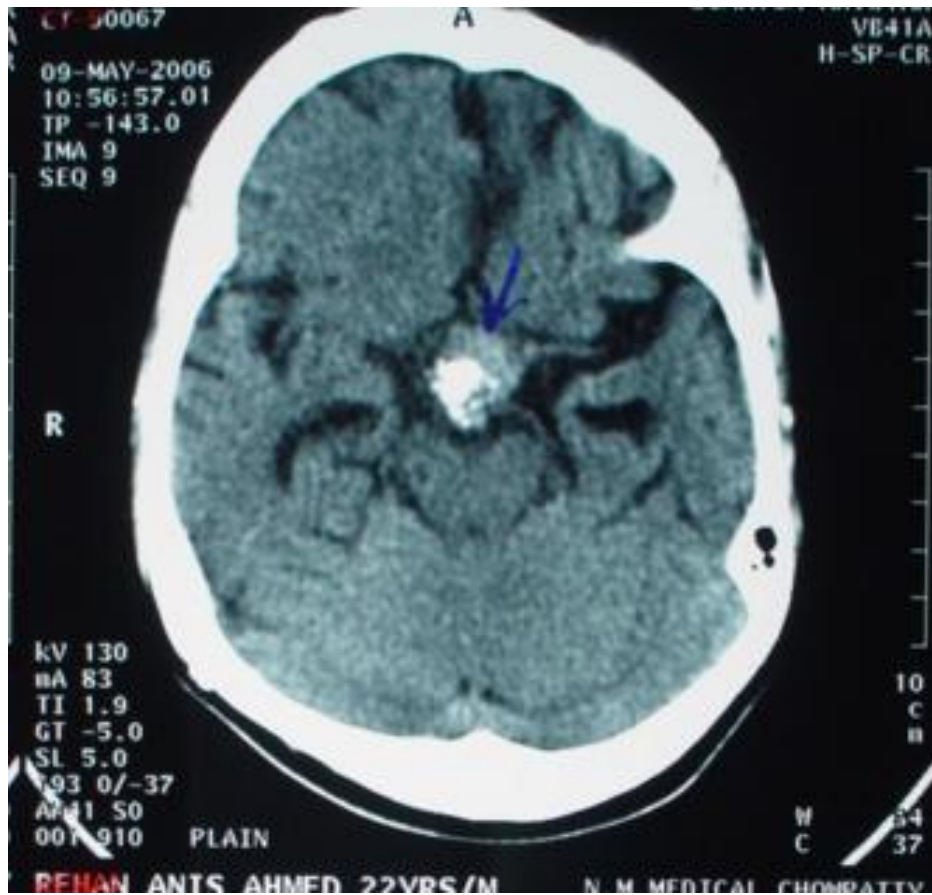01.05.2006



01.05.2006

27 22:1

27 22:12



09.05.2006

