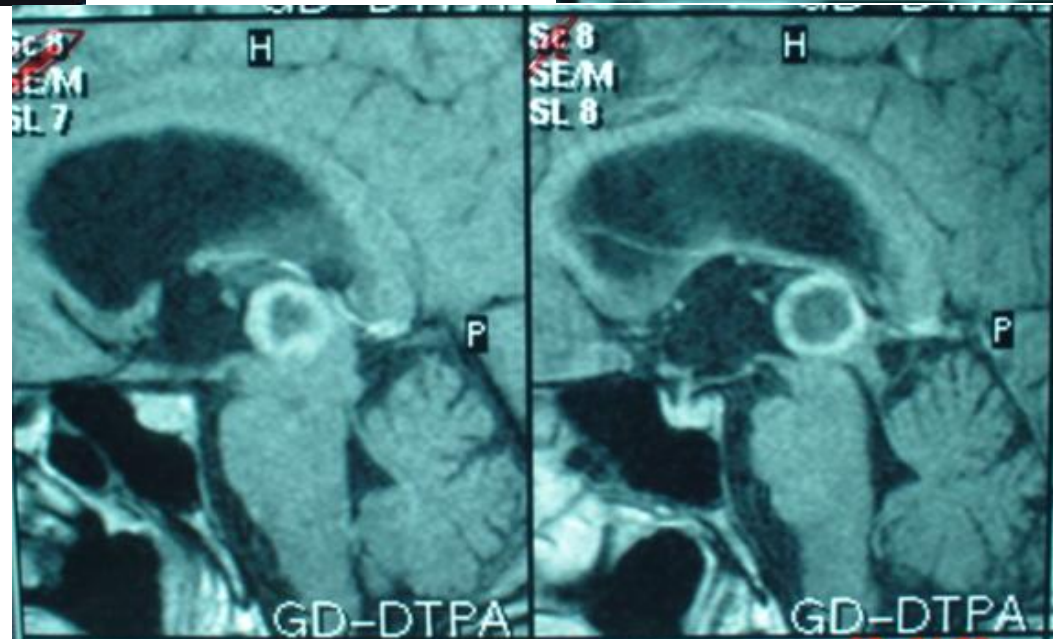
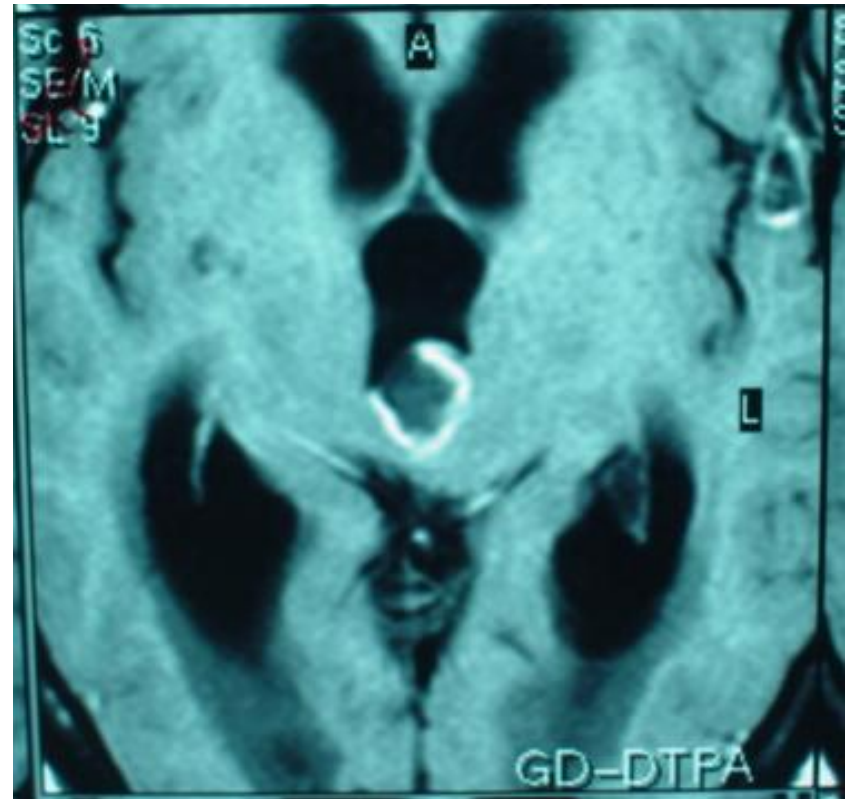
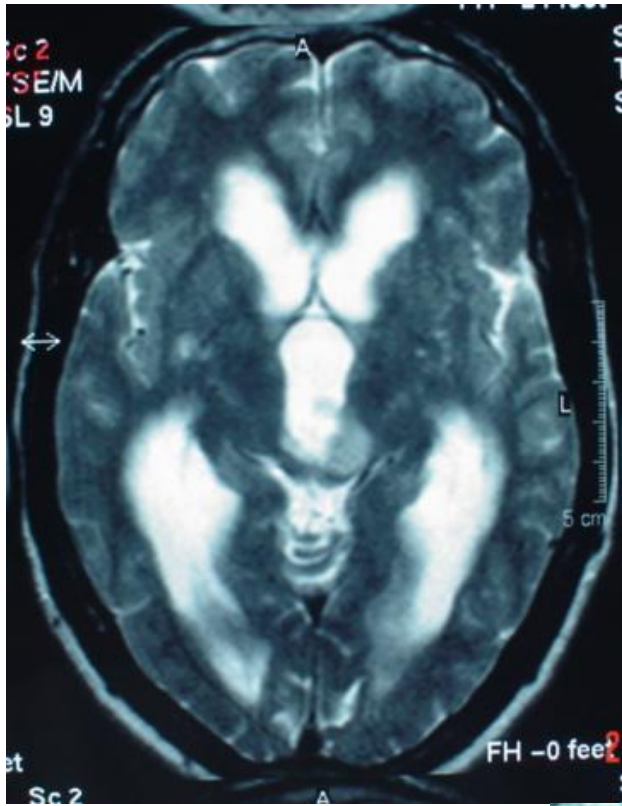
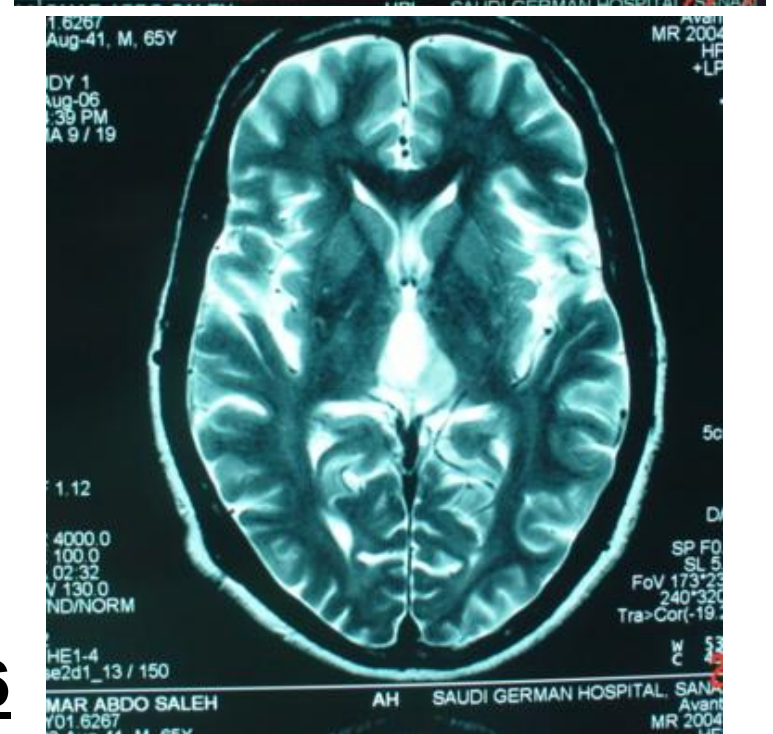
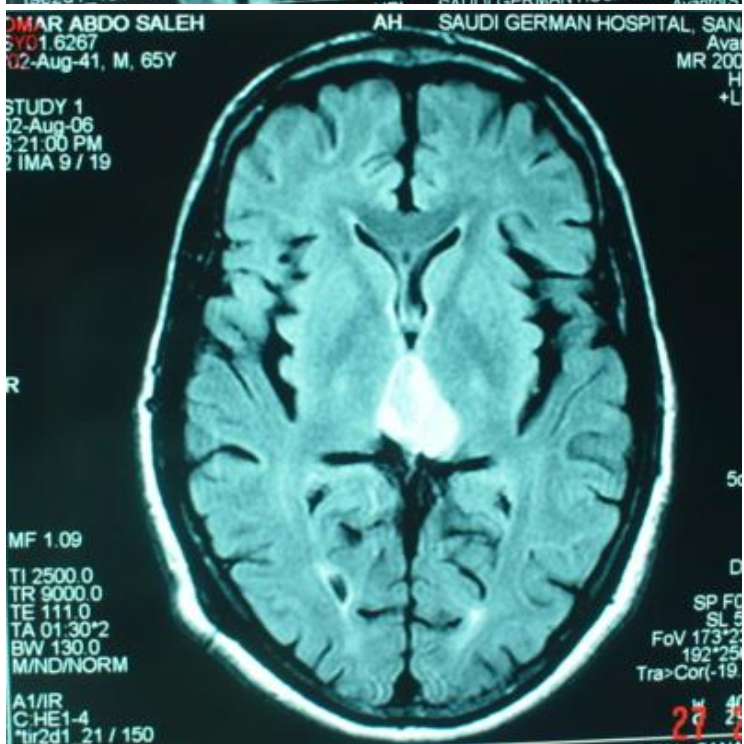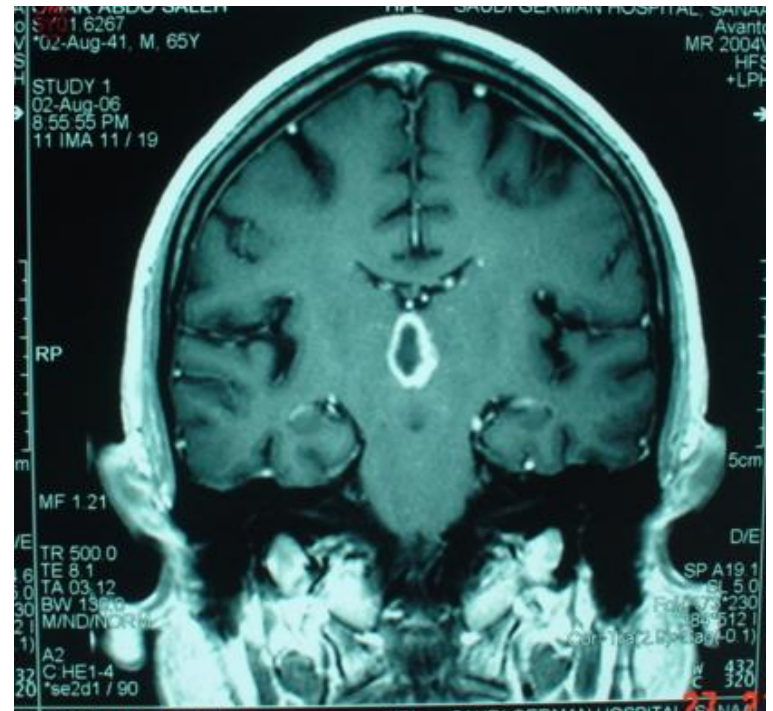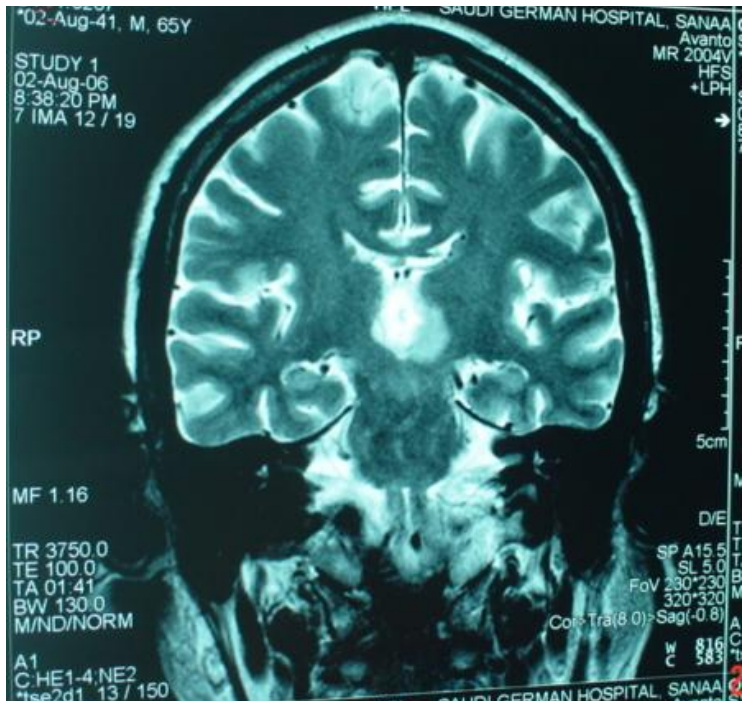


Case 4

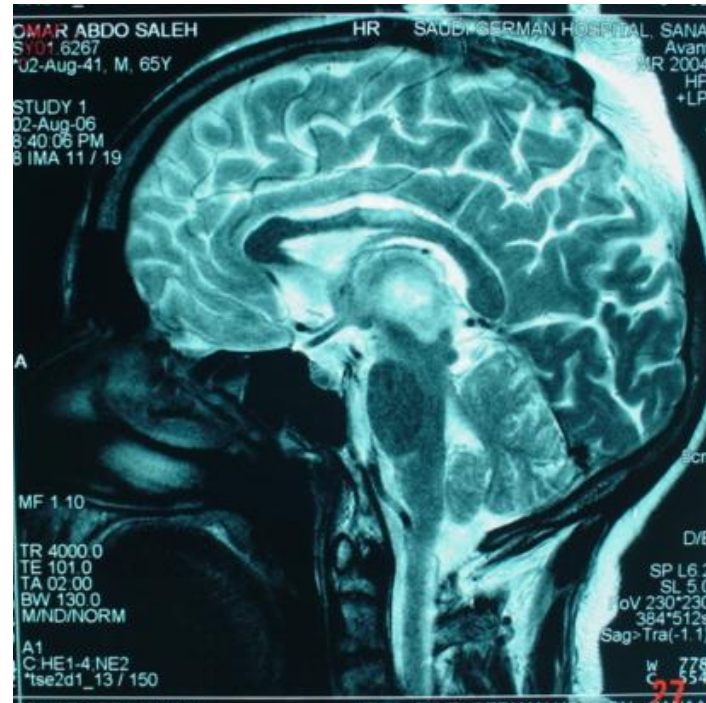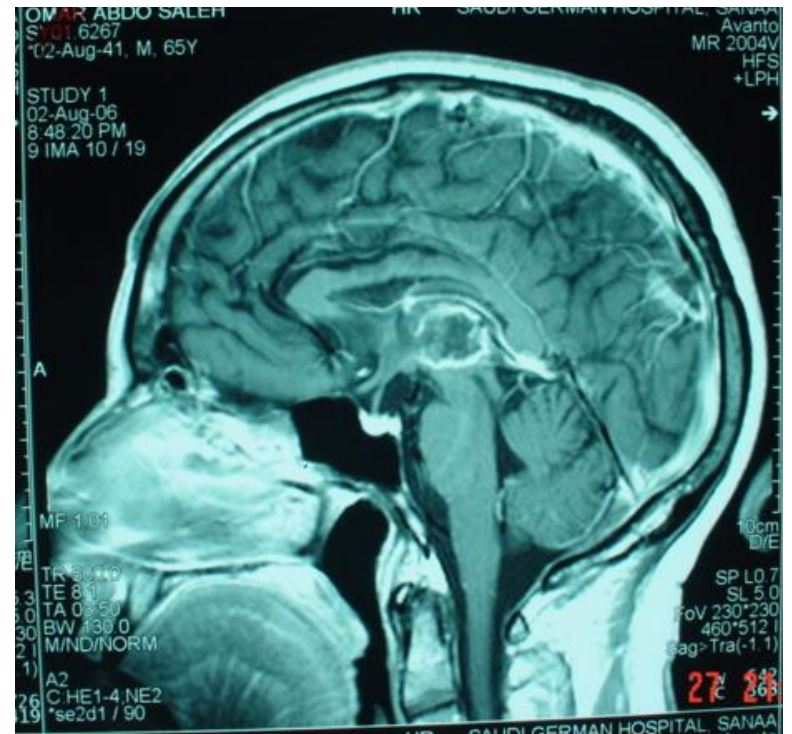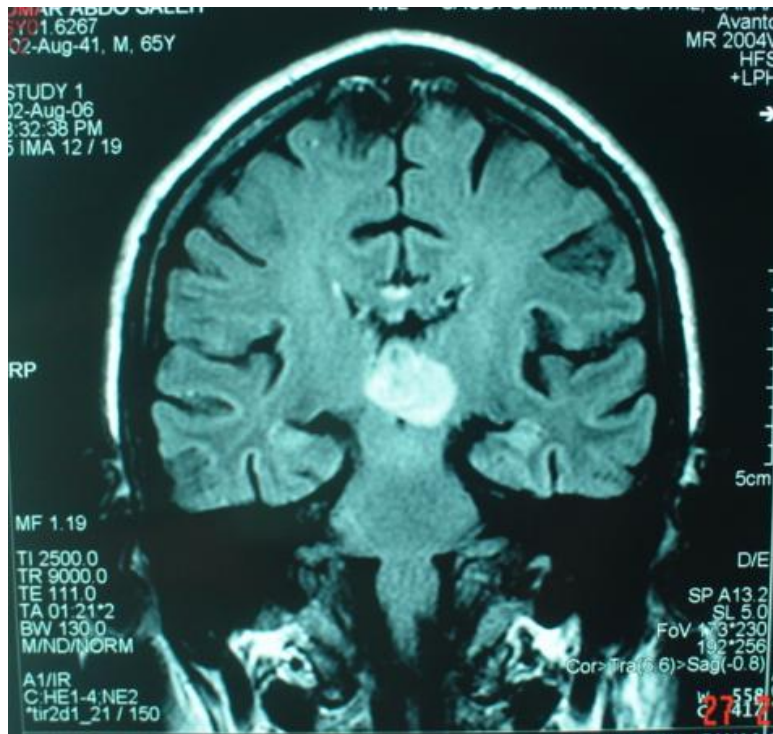
- Mr. Omar Abdullah, 68/ M
- Imbalance, loss of recent memory, two falls (? Loss of consciousness, seizures) since 5 mths
- CT& MRI brain May 2006 – glioma of midbrain
- May 06 – stent placement for hydrocephalus
- MRI 03.08.2006 –
- MRI 04.09.2006 –
- Sx 13.09.2006 – hypervascular tumour, multiple biopsies taken
- Post op – no neurological deficit
- HPR – HG Astro



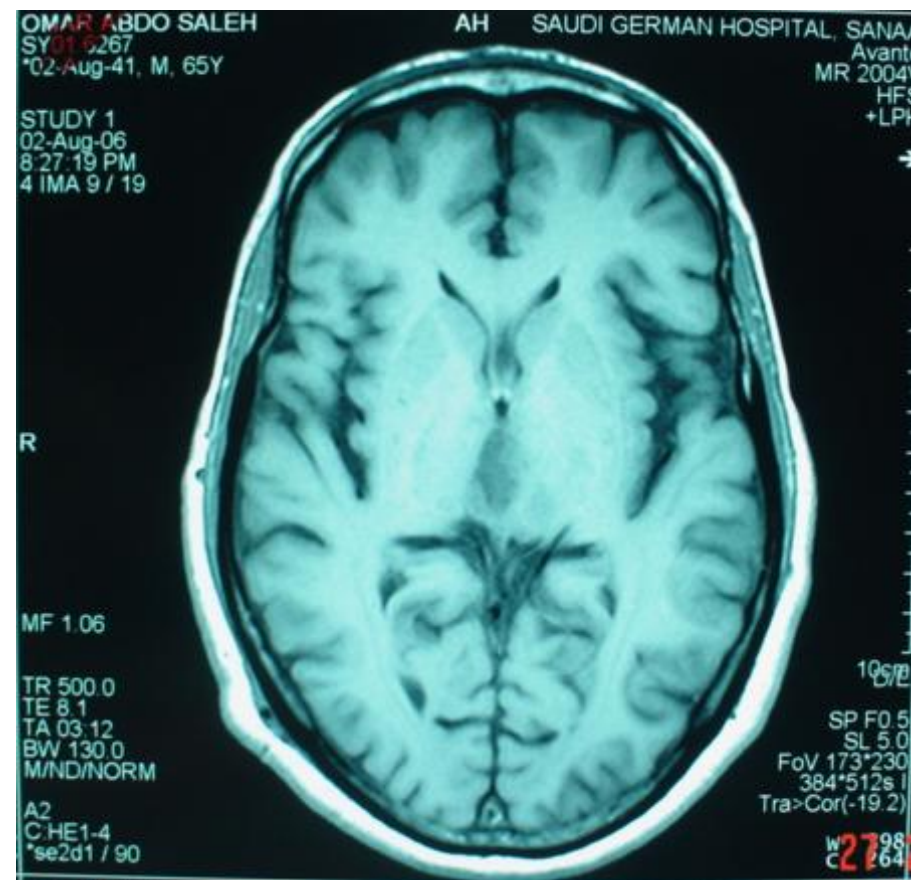
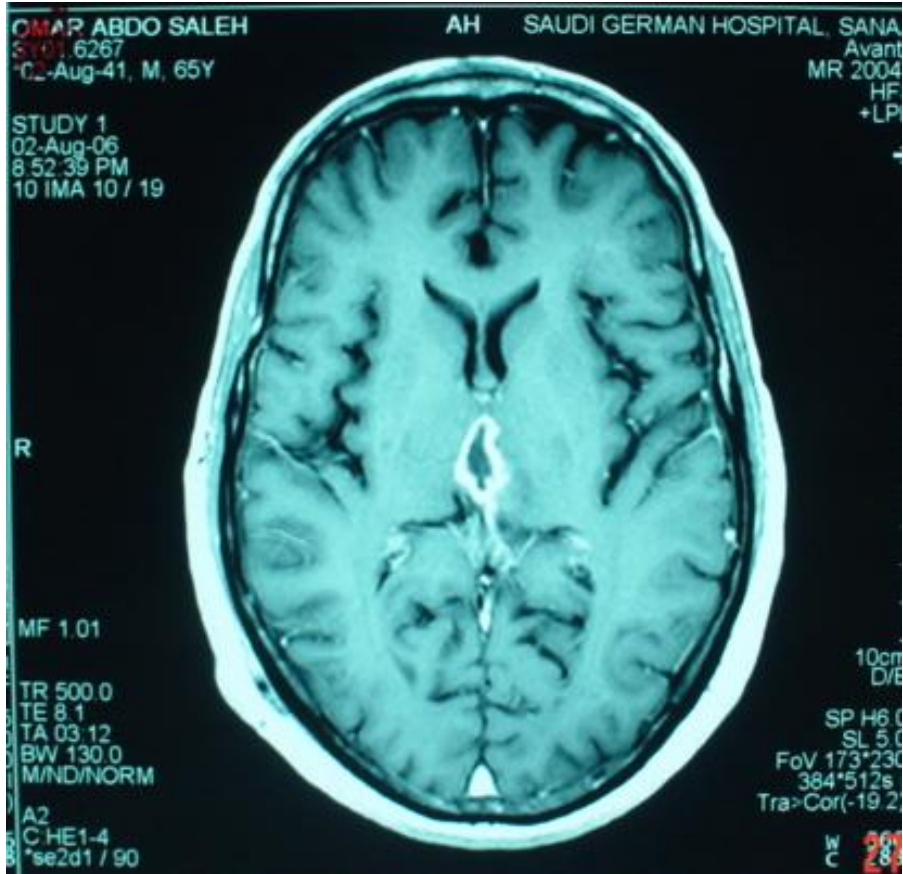16.05.2006



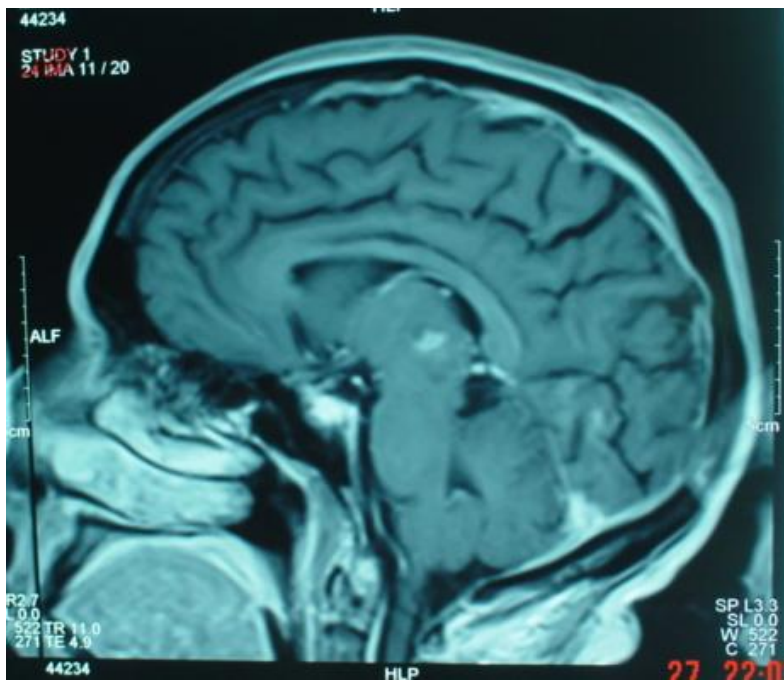
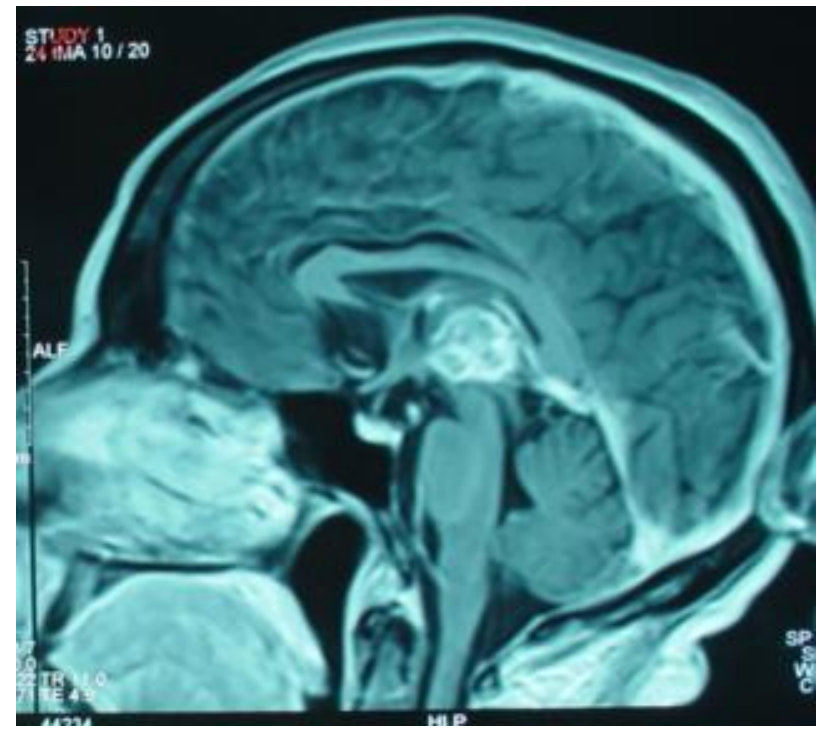
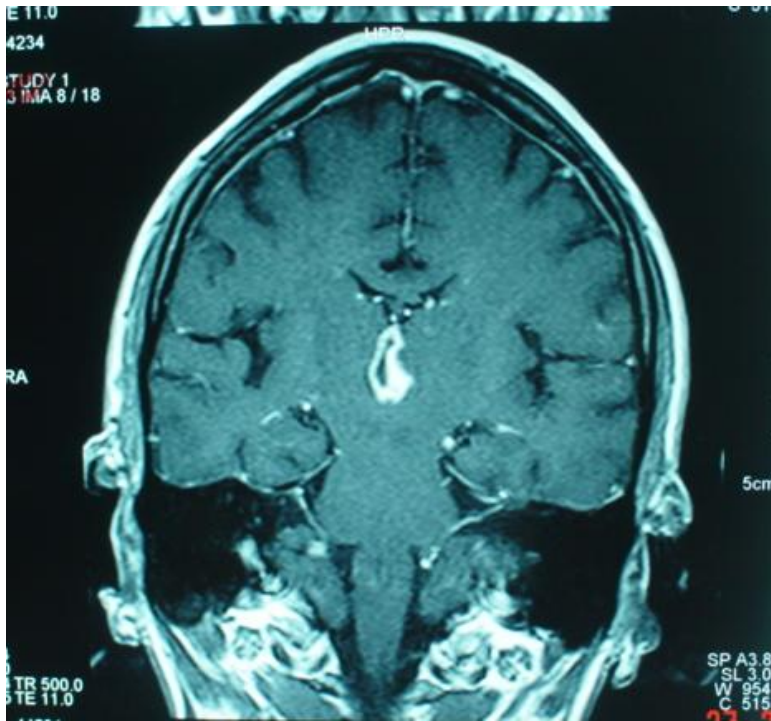
03.08.2006



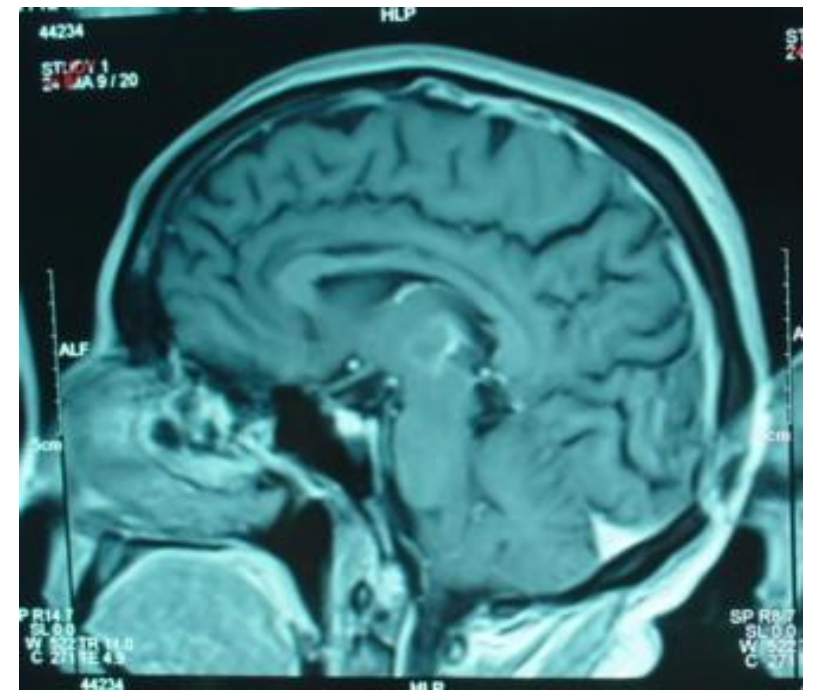
03.08.2006

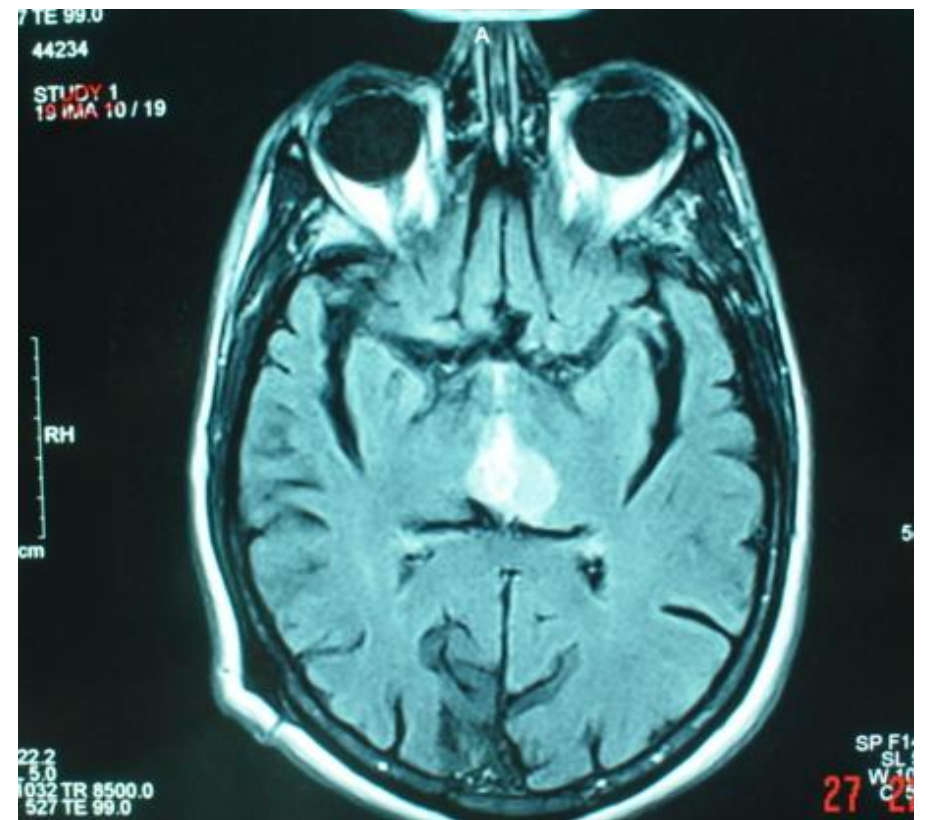
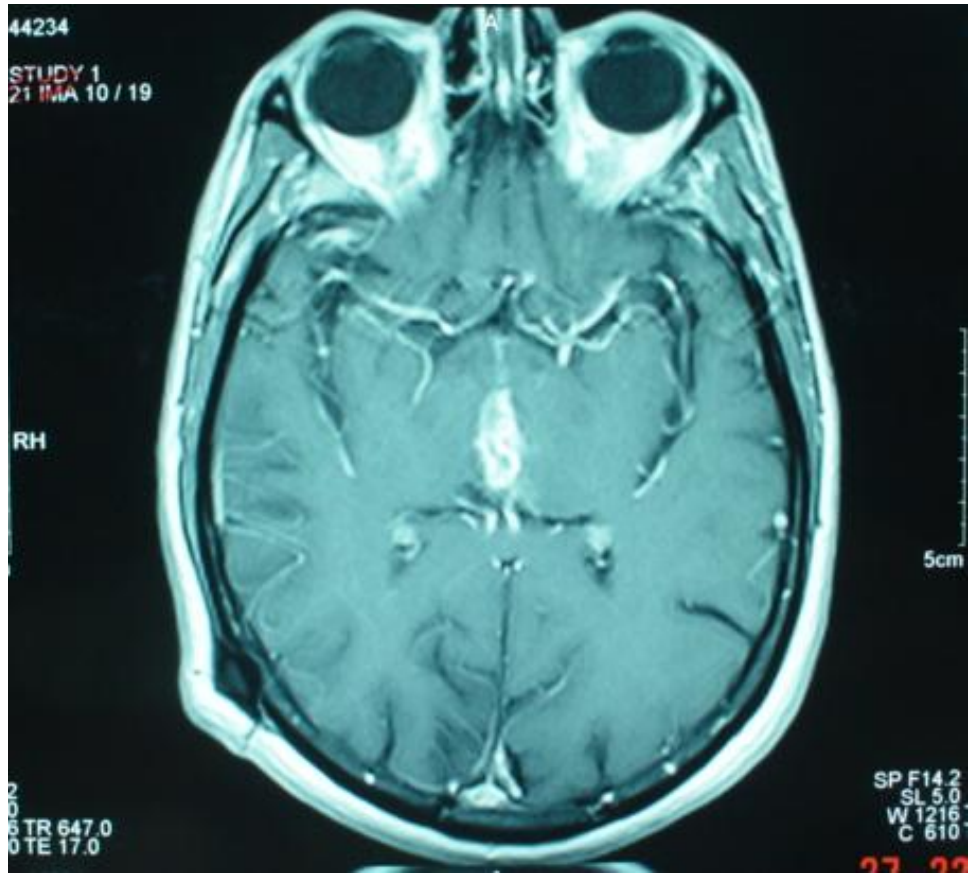


03.08.2006



04.09.2006





04.09.2006

- Post op CT 16.09.2006 - ? Haemorrhage ? Res disease
- ? PLAN