

# Immobilisation and CT cuts in CNS radiotherapy

Anusheel Munshi

Department of Radiation Oncology

Tata Memorial Hospital

# IMMOBILIZATION in CNS tumours



Not as difficult, for sure!!

# Immobilization: What is the need?



- ❖ To accurately position target
- ❖ To minimise the dose to surrounding normal tissue as far as possible.
- ❖ Reduces the time for and the errors in daily patient setup
- ❖ Makes the patient feel more secure and less apprehensive

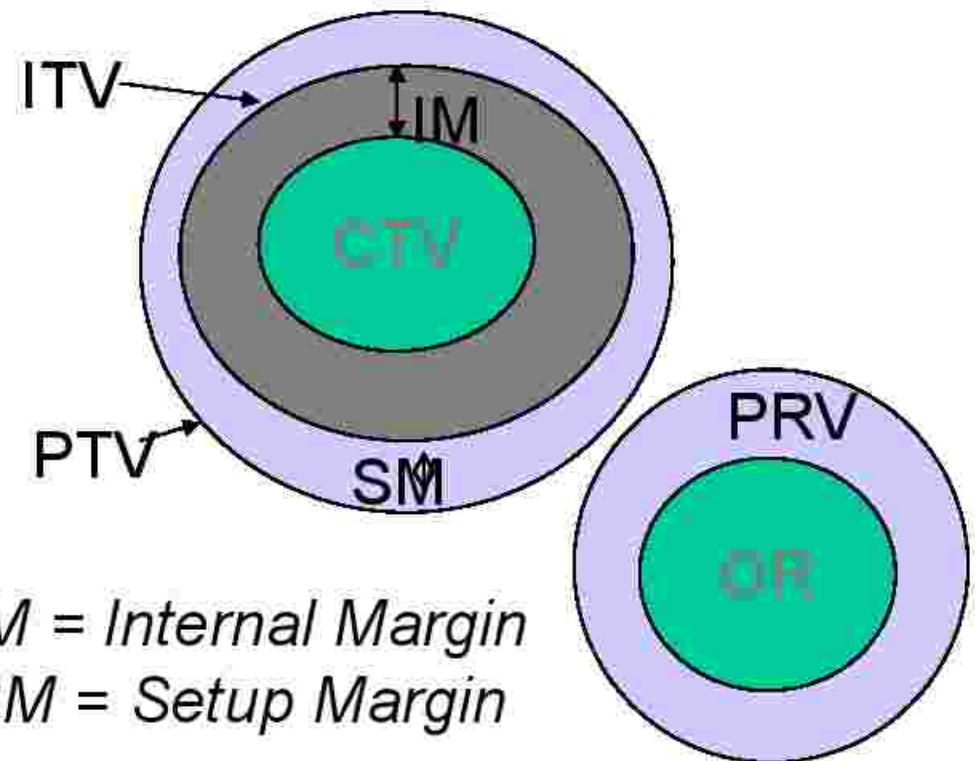
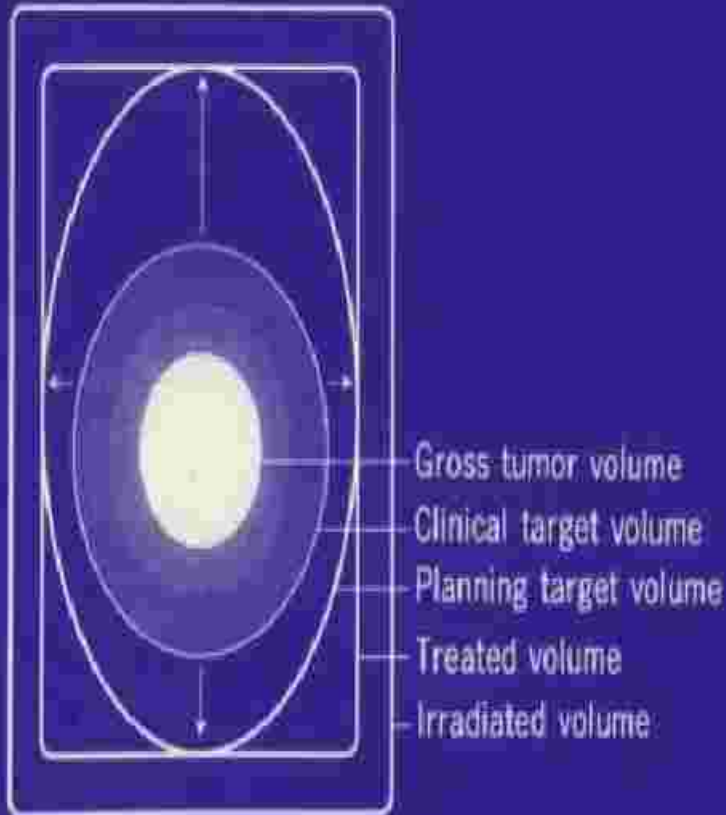
# Immobilization: What is the need?



- ❖ Especially in CNS tumours (small fields, critical adjacent structures)
- ❖ Reduces the reliance on patient cooperation and alertness
- ❖ Immobilisation techniques can influence **PTV margins** ( $PTV = 2 \times \text{Systematic Error} + 0.7 \times \text{Random Error}$ ) Stroom IJROBP 1999

# Physical Rationale: Target Volume Margins

## ICRU REPORT 50

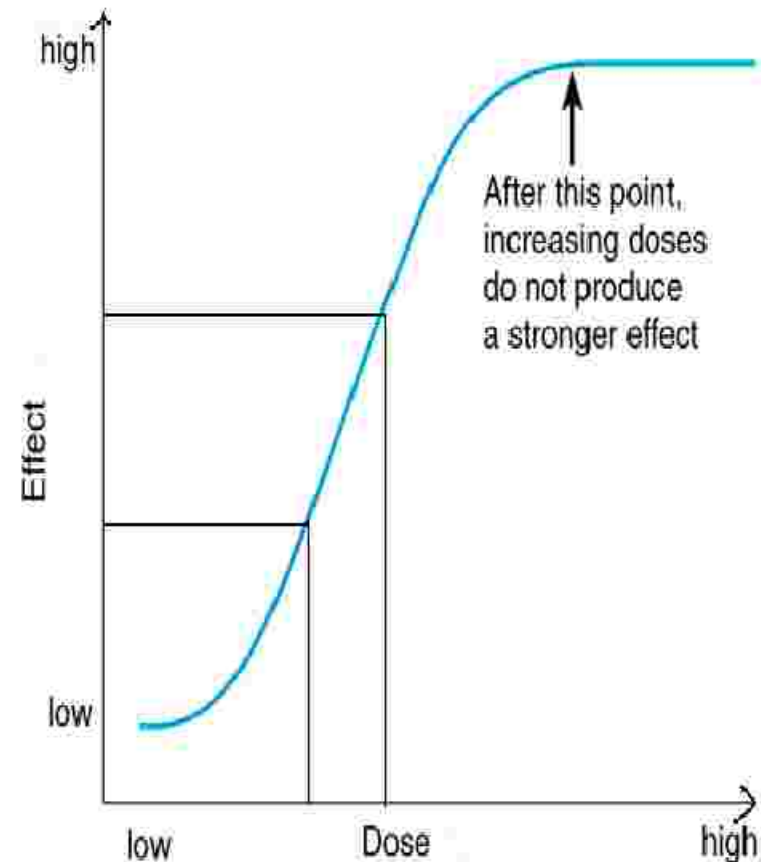


*IM = Internal Margin*  
*SM = Setup Margin*

**Margin between CTV & PTV depends upon extent of immobilization & accurate positioning methods**

# Radiobiological Rationale

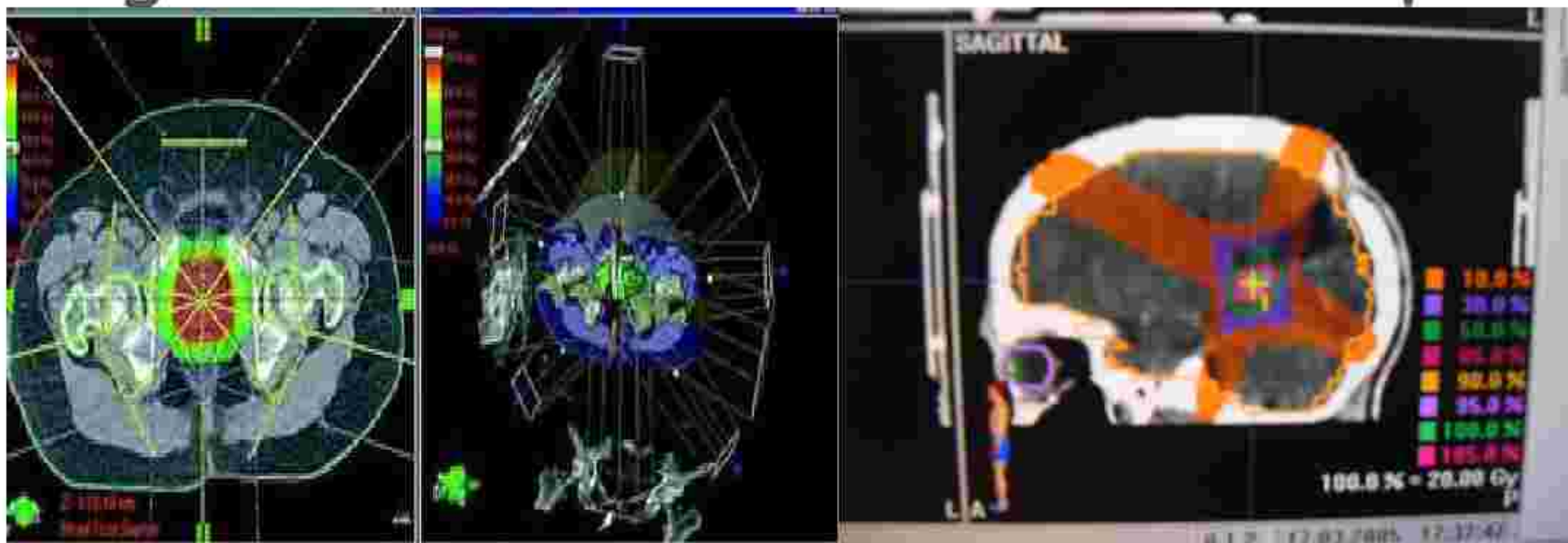
- ❖ Slope of dose response curve of many tumors is sufficiently large, i.e. little change in dose will significantly reduce tumor control probability.
- ❖ Strong co-relation between local recurrence and inadequate coverage of defined target volume within high dose region



Doss et al, CALGBworkshop, N Y 1979  
Kinzie et al, Cancer,52:2223-2226,1983

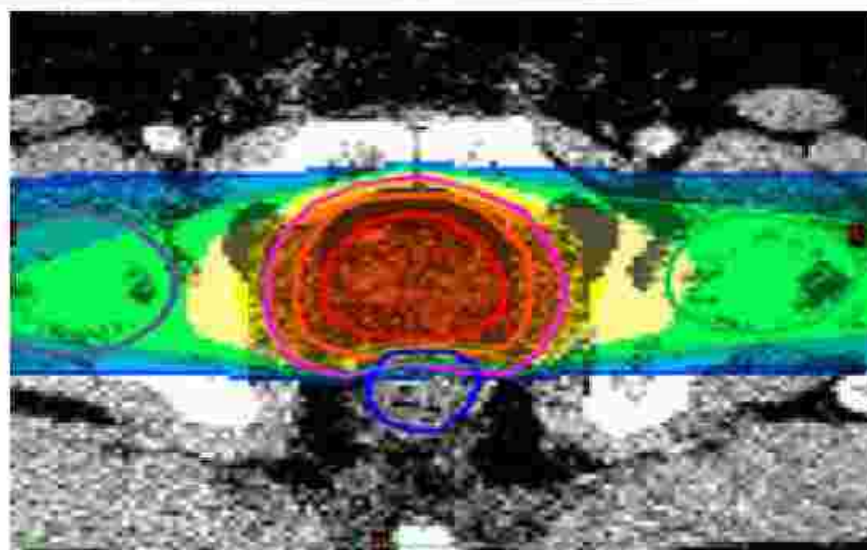
# Precise Rationale!

## High Precision Treatment Techniques



IMRT

SRT



T/t with charged particles

## Immobilisation in CNS radiotherapy

- ❖ Prerequisite for all cases of CNS radiotherapy
- ❖ The more precise the radiotherapy technique, the better the immobilisation should be

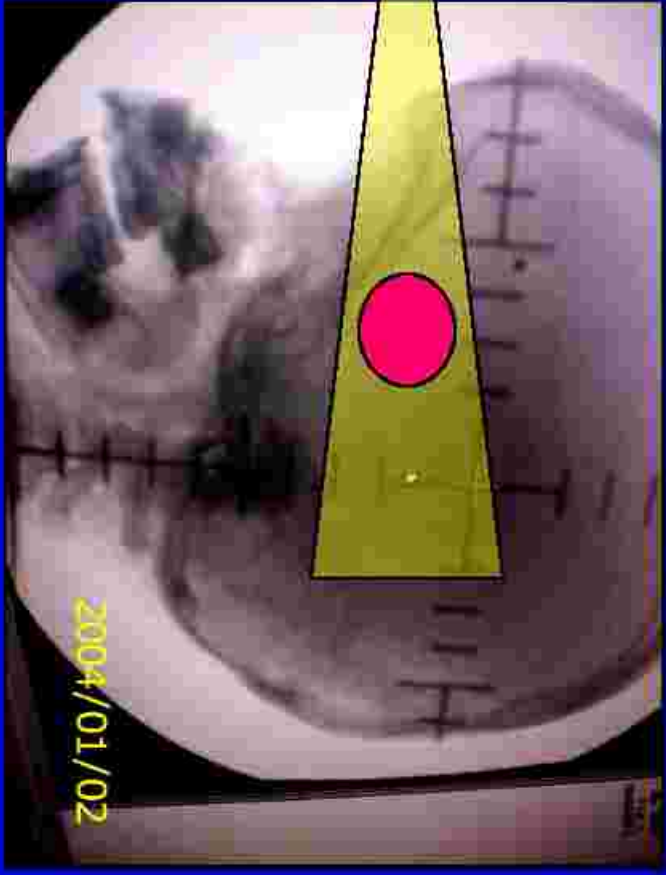


# Positioning and Immobilisation

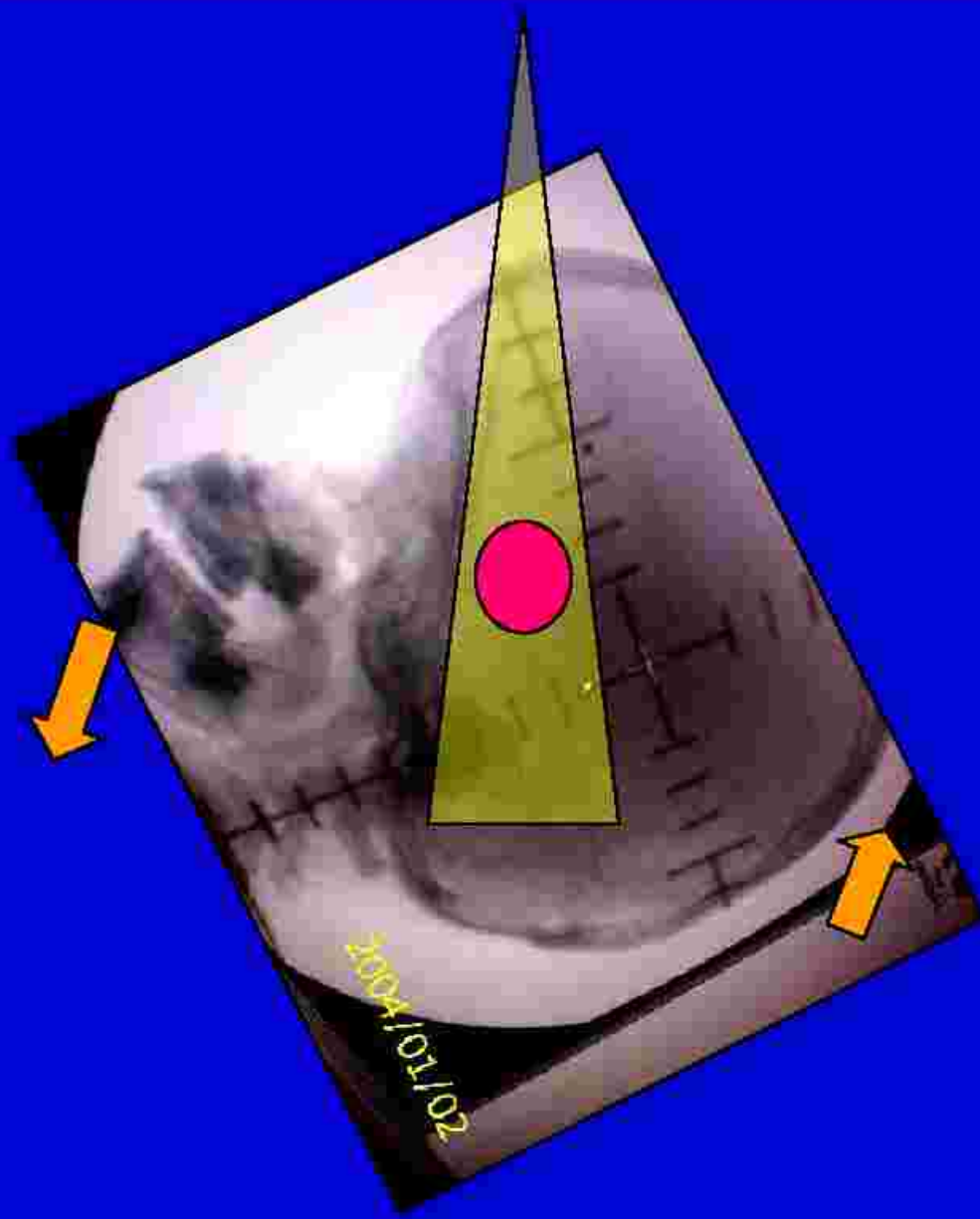
- ❖ Fully supported in a comfortable and relaxed position
- ❖ Device conforms to patients body contour
- ❖ Should be sturdy and maintain shape over time
- ❖ See the target Volume to be treated and structures to be spared
- ❖ Treatment portal arrangement
- ❖ General condition and comfort of patient

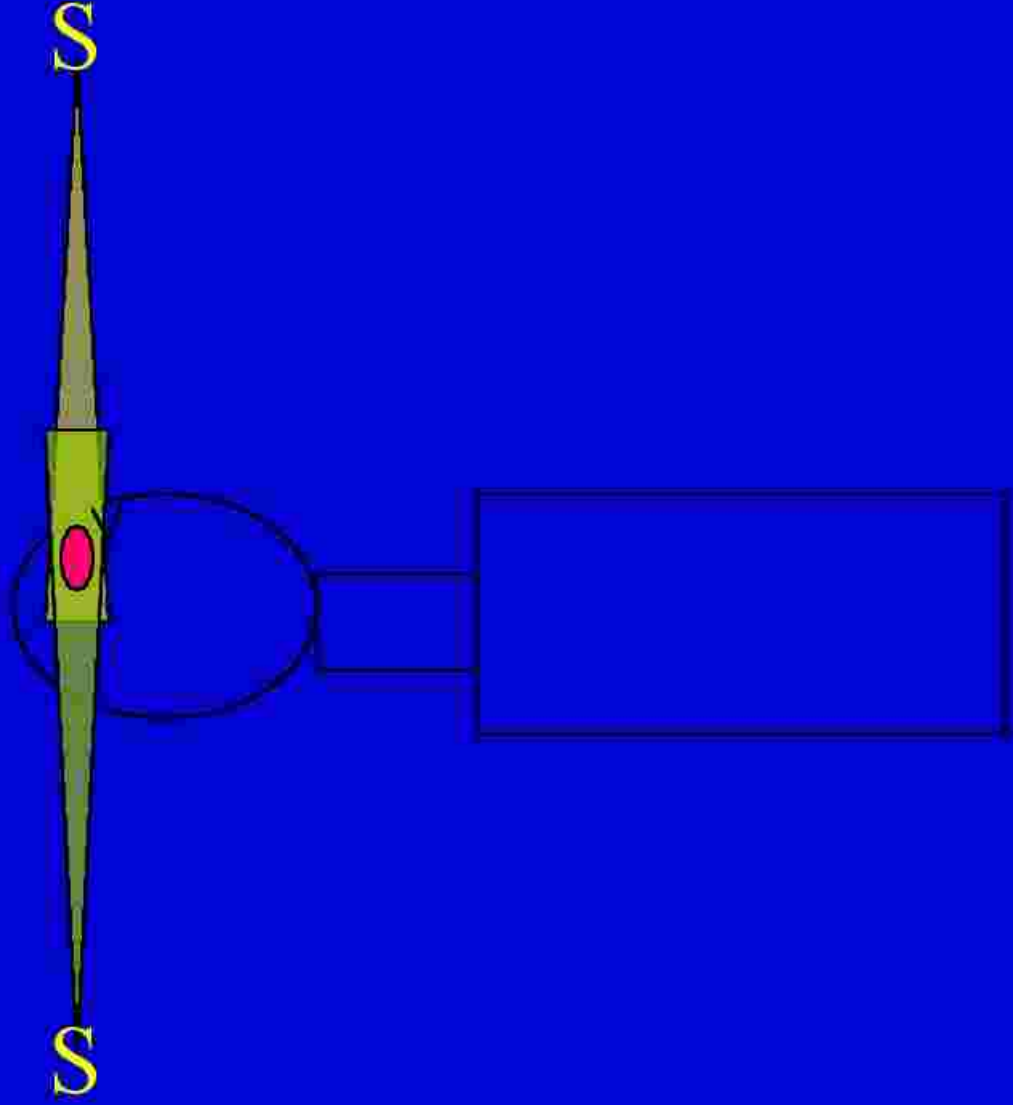
## Immobilisation in CNS radiotherapy

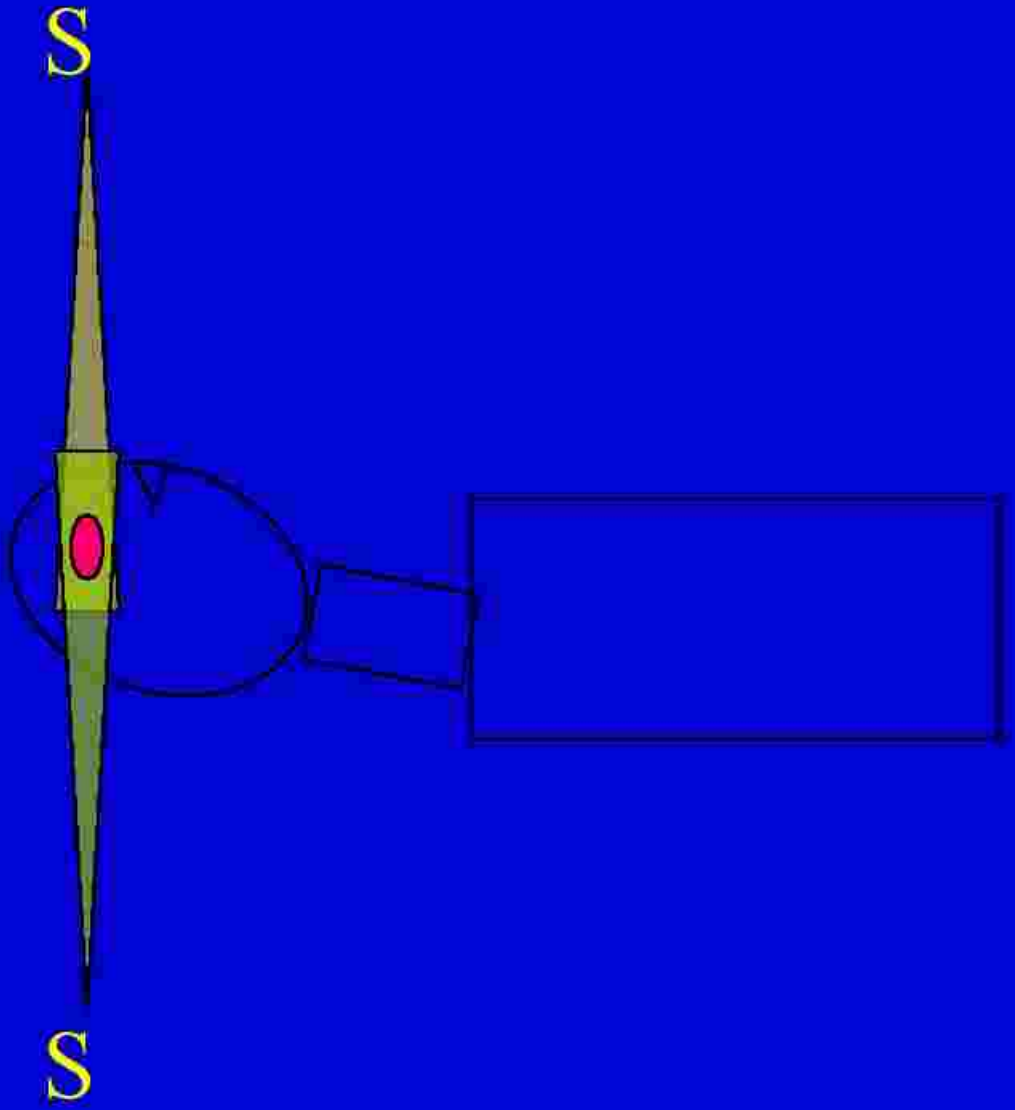
- ❖ Immobilisation position for head: neutral, max flex, prone
- ❖ Predominantly influenced by tumour location
- ❖ Temporal lesion, pituitary adenomas(max flex)
- ❖ Prone position in medulloblastomas for Post fossa boost planning



2004/01/02







# Immobilisation devices/aids


# History of Immobilization methods.

- ❖ **Early Days:**
  - Plastic head cups(doggy dish)
  - Standardized neck roles
  - Masking tapes
  - Not to move during T/ t
  - Hold the breath
- ❖ **1960 -1970 :**
  - Skin marks
  - Plaster of paris cast
  - Polyurethane foam molds,
  - Bite blocks
  - Vacuum molded plastic masks
- ❖ **Early 1980 and onwards:.....**



# Laser

Make use in aligning the patient for immobilisation



# Base plate



# Indexer



Carbon Fiber SecureFit™ Bar (RT-7010)




SecureFit™ Bar (RT-5010A)



SecureFit™ Sliding Attachment (RT-5015)



SecureFit Bar™ II (RT-5012A)



Siemens™ Bar (RT-5016)



Elekta™ Bar (RT-5018)

# Head supports

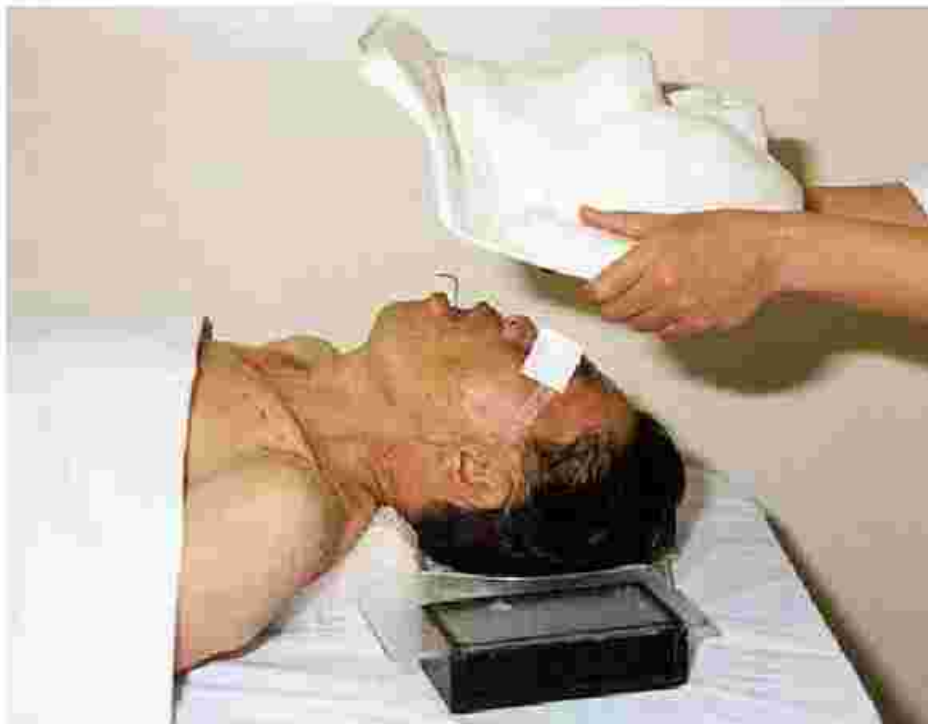
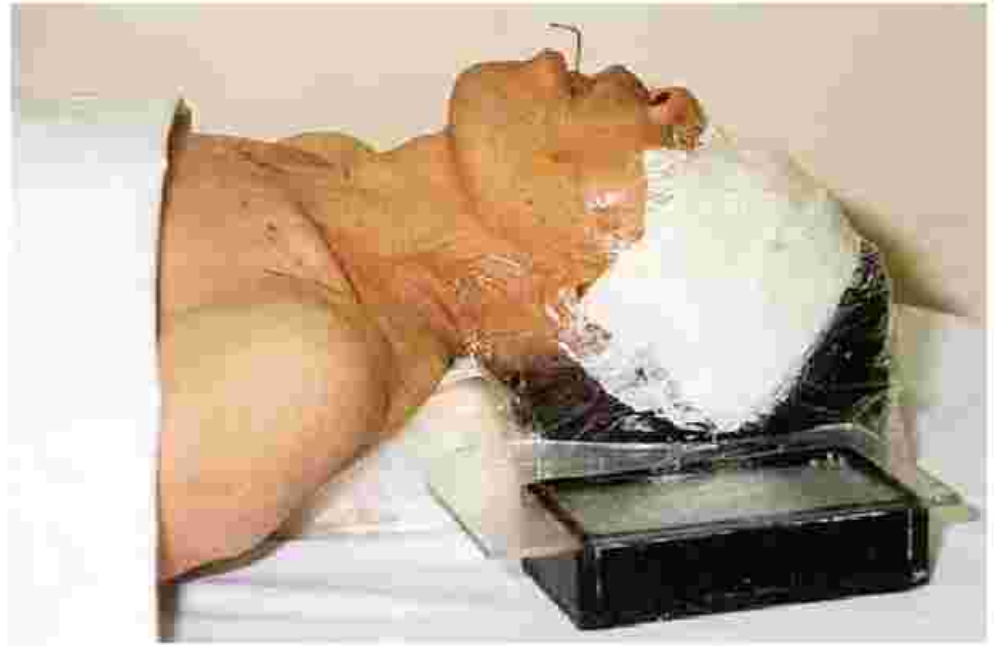
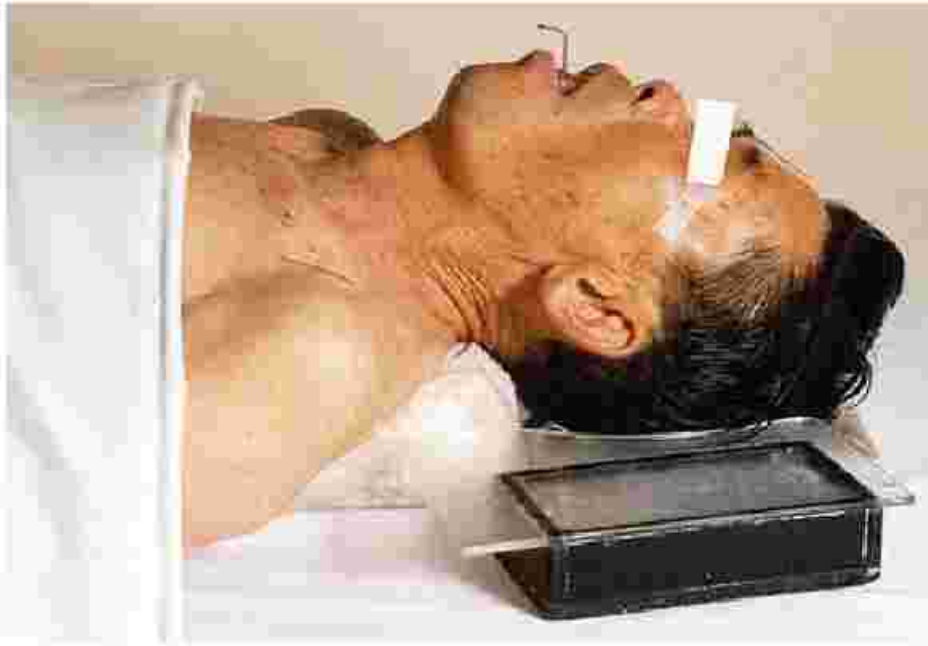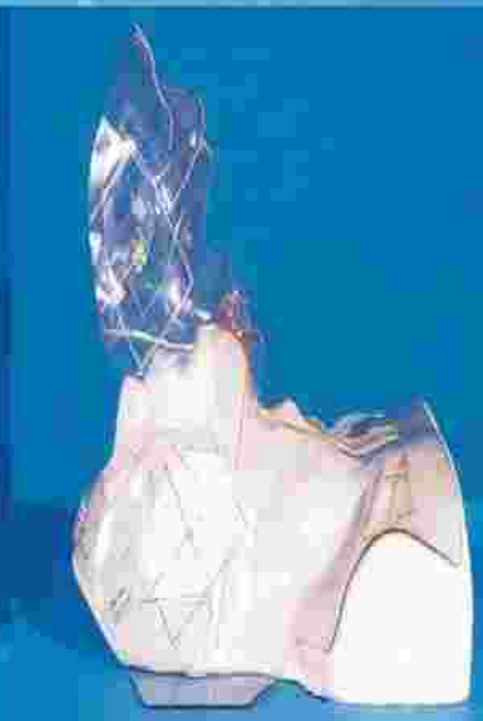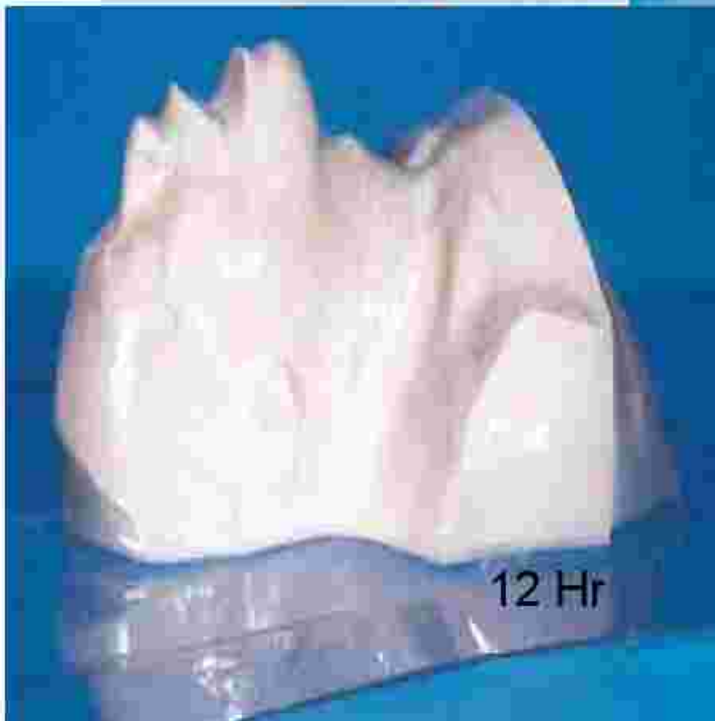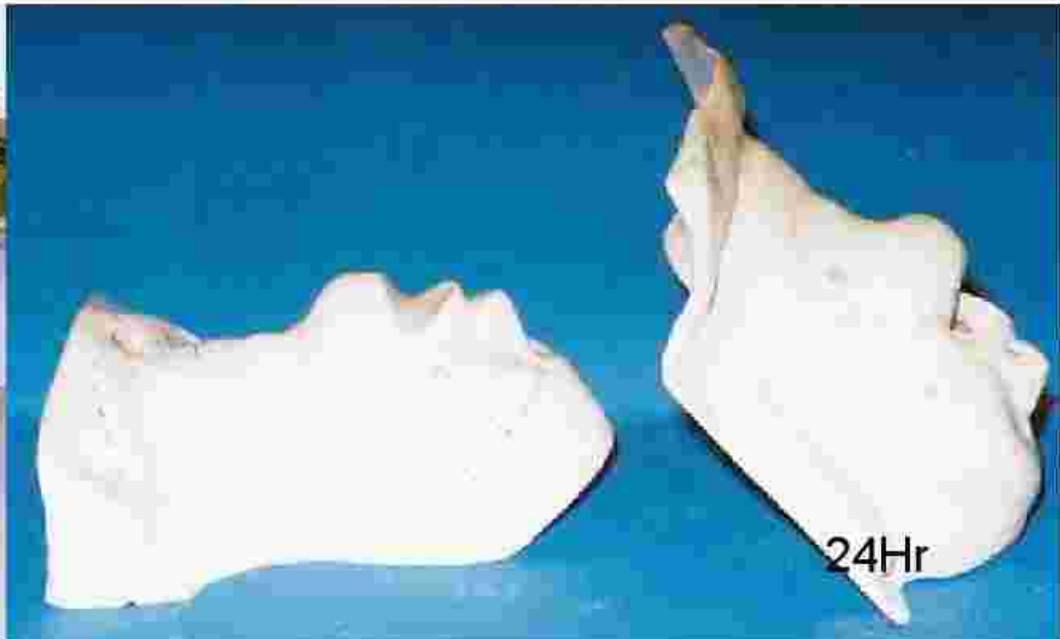# Head supports



# Acrylic Mould / cobex cast

- ❖ Made from perspex sheets
- ❖ It forms hard nonmalleable material when mixed and allowed to set.
- ❖ **Materials required** : plaster of paris bandage, plaster of paris powder  
Perspex sheet, vaseline, base plate, head rest







❖ Advantages :


- Effective fixation
- Close conformity between body surface and mould.
- Portals can be marked.
- Windows may be cut.
- Can be used for CT/MRI without causing any distortion of image.

❖ Flip side :

- Difficult and cumbersome to make .
- Relatively delicate, with use / rough handling it may get fractured.
- expensive.
- Cannot be reused.

# Thermoplastic Mould

- ❖ Is a heat sensitive material (cellulose acetate / polyvinyl chloride).
- ❖ Available in form of various precut shapes, size and thickness (1.6-4.2mm).
- ❖ Soften by heating in water bath at minimum 70 degree Celsius.

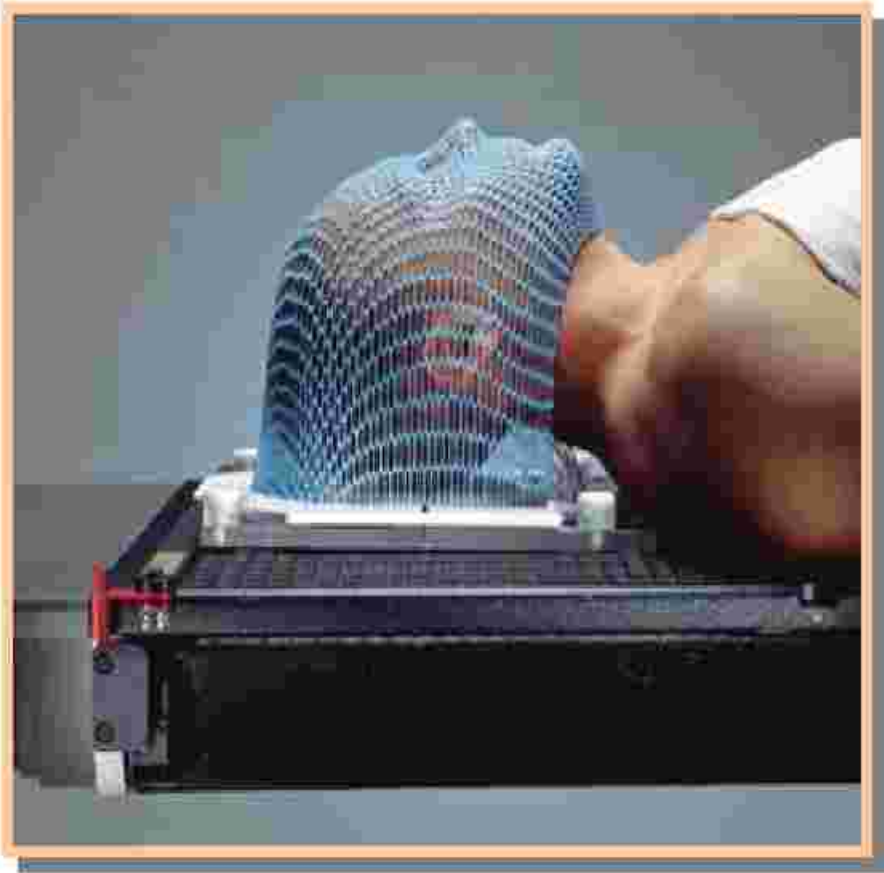


- ❖ Advantages : can be used practically for all body parts
  - Can achieve very close conformity between body surface and mould.
  - Relatively easy to make and less time consuming.
  - Portals can be marked on surface with ease.
  - Treatment windows can be cut.
  - Wax bolus can be fixed to surface.
  - Can be used with CT/MRI scan .
  
- ❖ Flip side : expensive(Rs1500-3500)
  - Windows cut can not be reused
  - When old becomes brittle and too soft when activated
  - Material ages in direct relation to circumstances.

# Thermoplastic mask

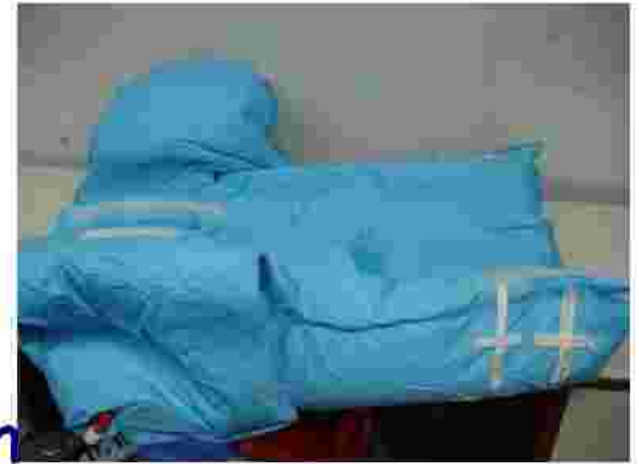- ❖ Uniframe and clamped versions
- ❖ 3 clamp for most neurooncological malignancies
- ❖ 4 clamp needed for CSI

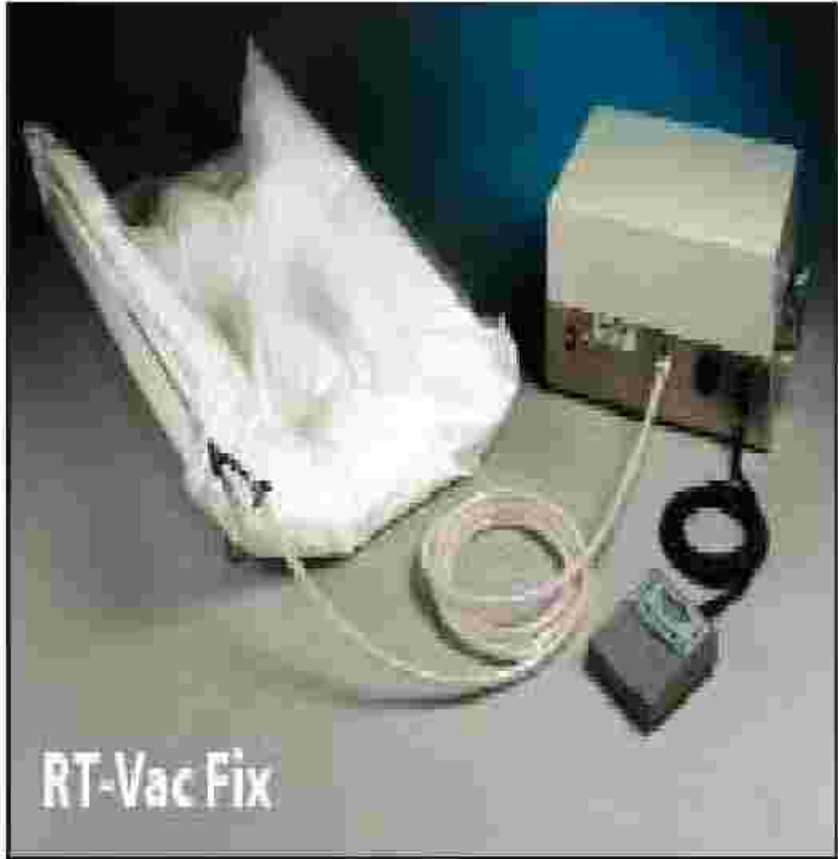# Thermoplastic mask



# Vacuum Mould

- ❖ Easy to use.
- ❖ Rugged radiotranslucent cushion
- ❖ Vacuum pillow ....filled with plastic pellets
- ❖ Polyurethane foam....filled with tiny polystyrene beads (40 / 25 Lit).
- ❖ Is air equivalent.
- ❖ Washable, reusable.
- ❖ Occasional use in CSI/paediatric patients





# Thermoplastic mask for stereotactic radiotherapy

Materials required : Specially designed thermoplastic sheets, clips and spacers, klin-foil, U-frame, couch mounts, water bath with thermostat.

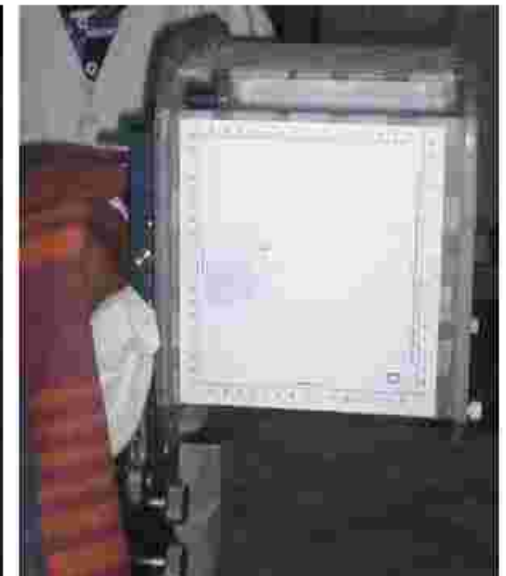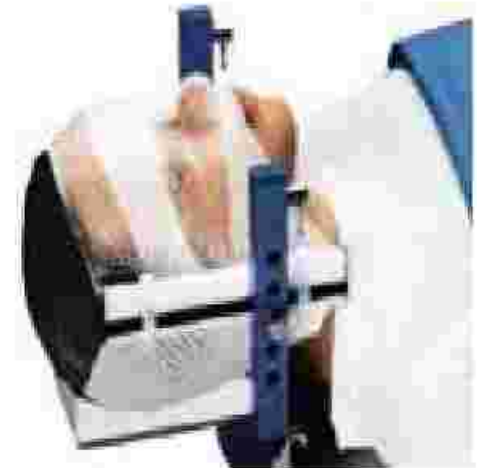❖ Advantages : Very rigid.

Produces accurate immobilization.

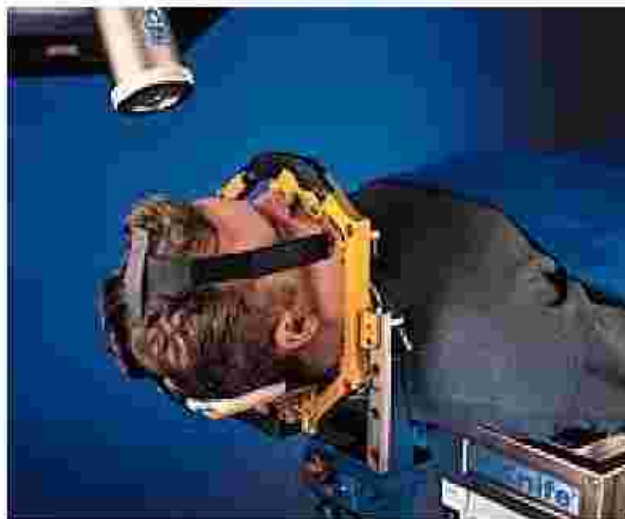
❖ Disadvantages : Can not be reused  
expensive.



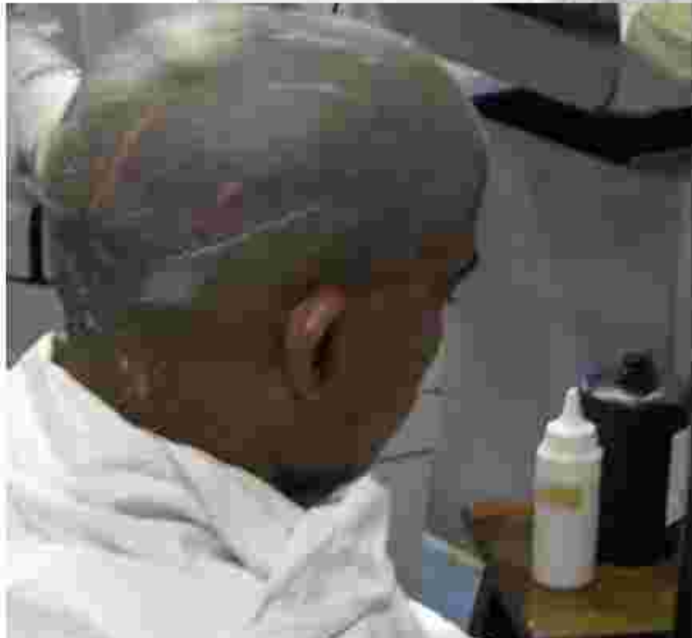
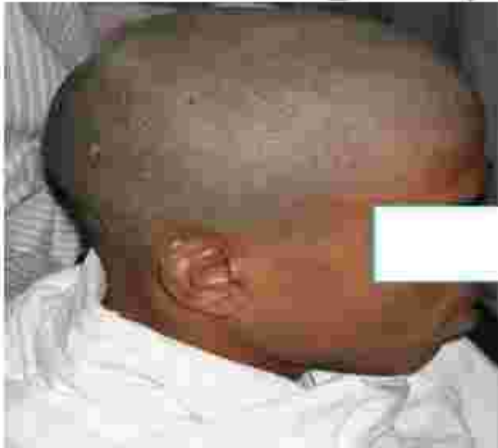# Immobilization for stereotactic radiotherapy

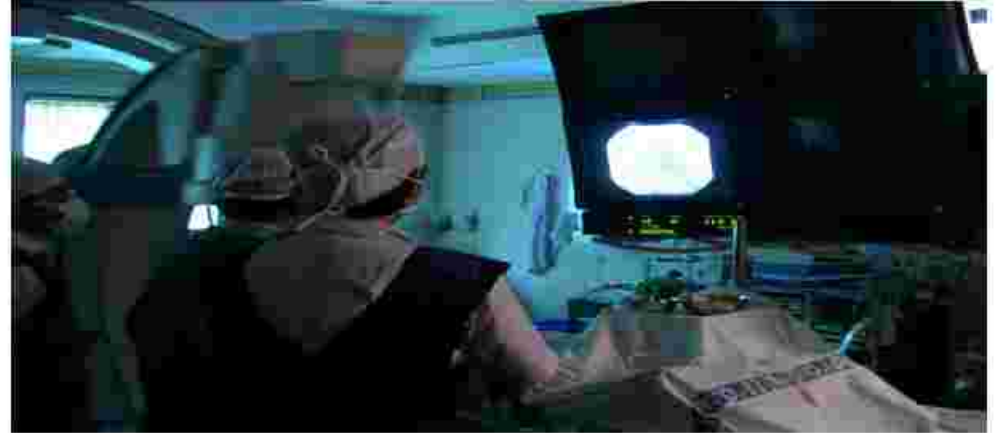
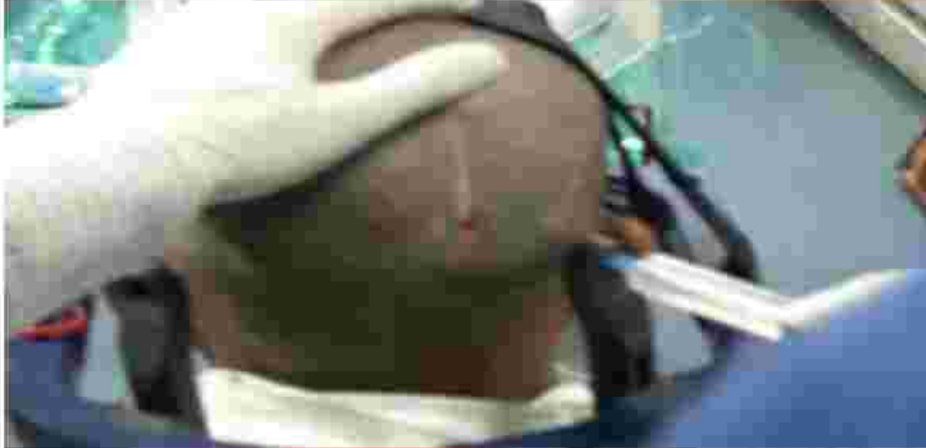
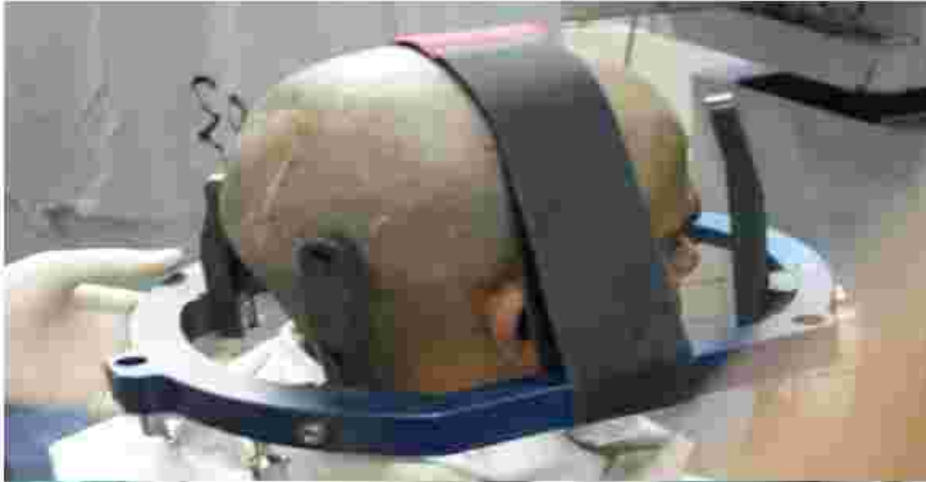# Immobilisation devices in stereotaxy of brain tumours

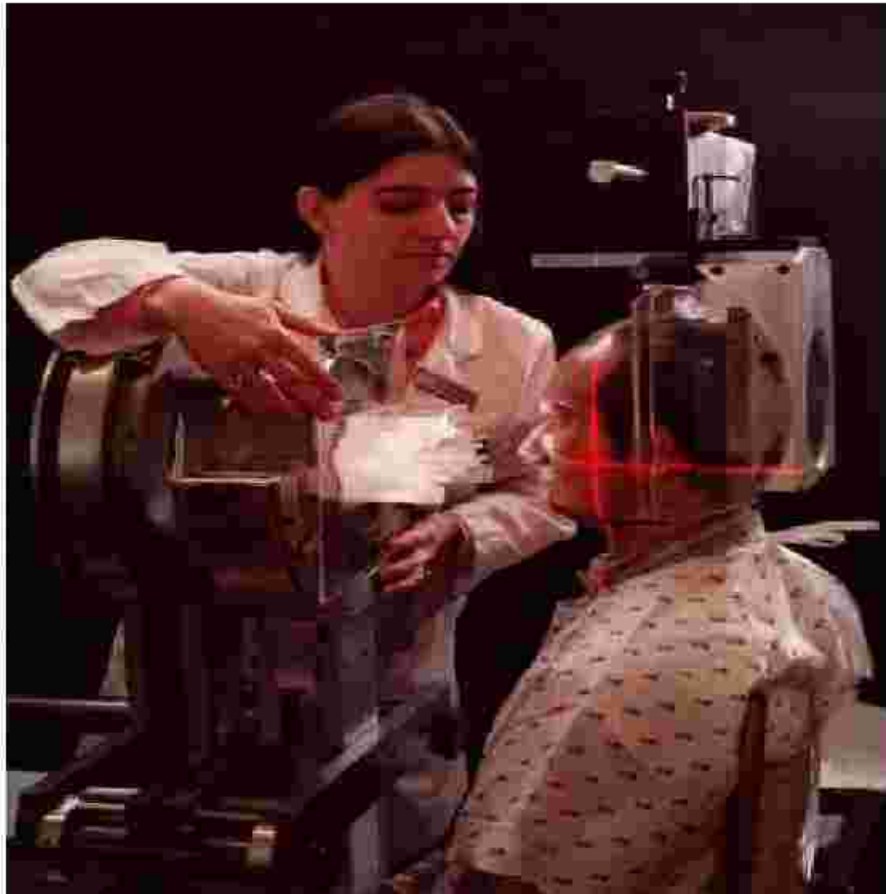

# Immobilization for Stereotactic Radiosurgery





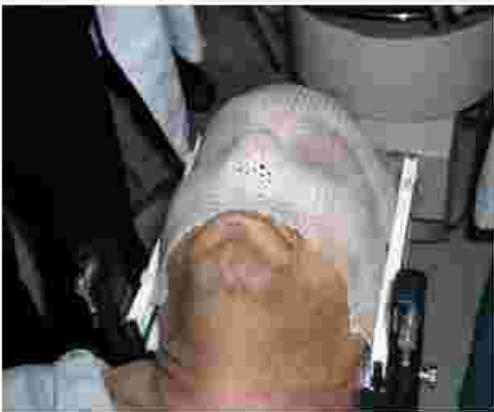# Irradiation Stereotactic Apparatus for Human (ISHA)



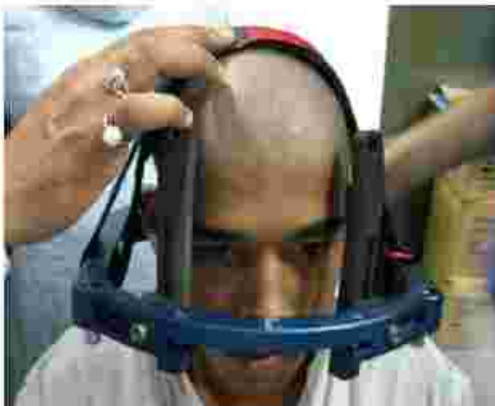# Immobilisation accuracy



Conventional mask:  
3- 5mm



Stereotactic frame (noninvasive):  
1-1.5mm



Stereotactic frame (invasive):  
<1 mm

# Sources of errors in proper immobilization

- ❖ Shrinkage of thermoplastic mask after being prematurely lifted off

*The thermoplastic head mask was shown to shrink 1.5 +/- 0.3 mm in the first day after fabrication Tsai et al:IJROBP 1999*

- ❖ Mechanical short comings eg Laser misalignment
- ❖ Fixation related problems

# Immobilisation in CNS radiotherapy

Immobilisation should be used in all patients undergoing CNS radiotherapy

Thermoplastic mask appropriate for most situations

Precision treatments (SRS, SRT) need more rigid and accurate immobilisation

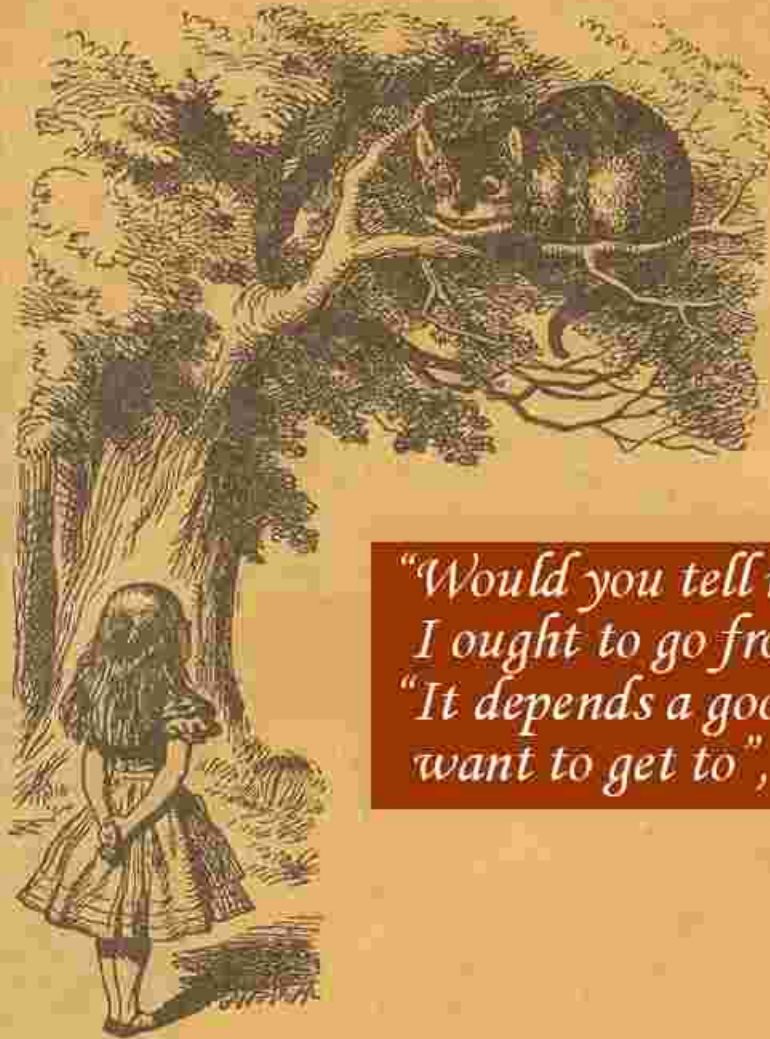
Modern techniques such as proton beams require even more precise and sharp immobilisation

*"It depends a good deal on where you want to get to", said the Cat.*





# Immobilisation in CNS radiotherapy



*"Would you tell me please, which way  
I ought to go from here."  
"It depends a good deal on where you  
want to get to", said the Cat.*

*Alice in Wonderland  
by Lewis Carroll*

\*Quote from 'Alice in Wonderland' by Christine Bonn

A photograph of a CT scanner in a clinical setting. The scanner is a large, white, cylindrical machine with a circular opening. A patient is lying on a table in front of the scanner, partially visible. The room has white walls and shelves in the background. The text "Emotion" is visible on the scanner's console. The text "Taking CT cuts for CNS radiotherapy Technique and pitfalls" is overlaid in the center of the image.

Taking CT cuts for CNS  
radiotherapy  
Technique and pitfalls

# Planning CT cuts in CNS radiotherapy

Aim for taking a planning CT in neurooncology

To obtain a stack of images which can be used

- ❖ For 3DCRT, IMRT, SRT, SRS(have to be exported to planning station. Plan implementation in conventional simulator/treatment machine)
- ❖ For doing virtual simulation(exported to V sim station. Isocenter exported back to CT simulator by moving lasers)



# Taking planning CT slices in neurooncology

## The commandments:

- ❖ Different from diagnostic imaging
- ❖ Know your machine/system well!
- ❖ Use appropriate immobilisation device
- ❖ Image the patient in treatment position
- ❖ No gantry tilt please

# Definitions

## Pitch in CT scan=

Distance table moves in one complete rotation of the X ray tube

---

slice thickness

Increasing pitch (by increasing the table speed) reduces dose and reduces scanning time, but at the cost of decreased image resolution.

# Definitions

Aperture: The diameter of the bore in  
The CT gantry

FOV(Field of vision): The actual region  
within the aperture scannable by CT

# The machine

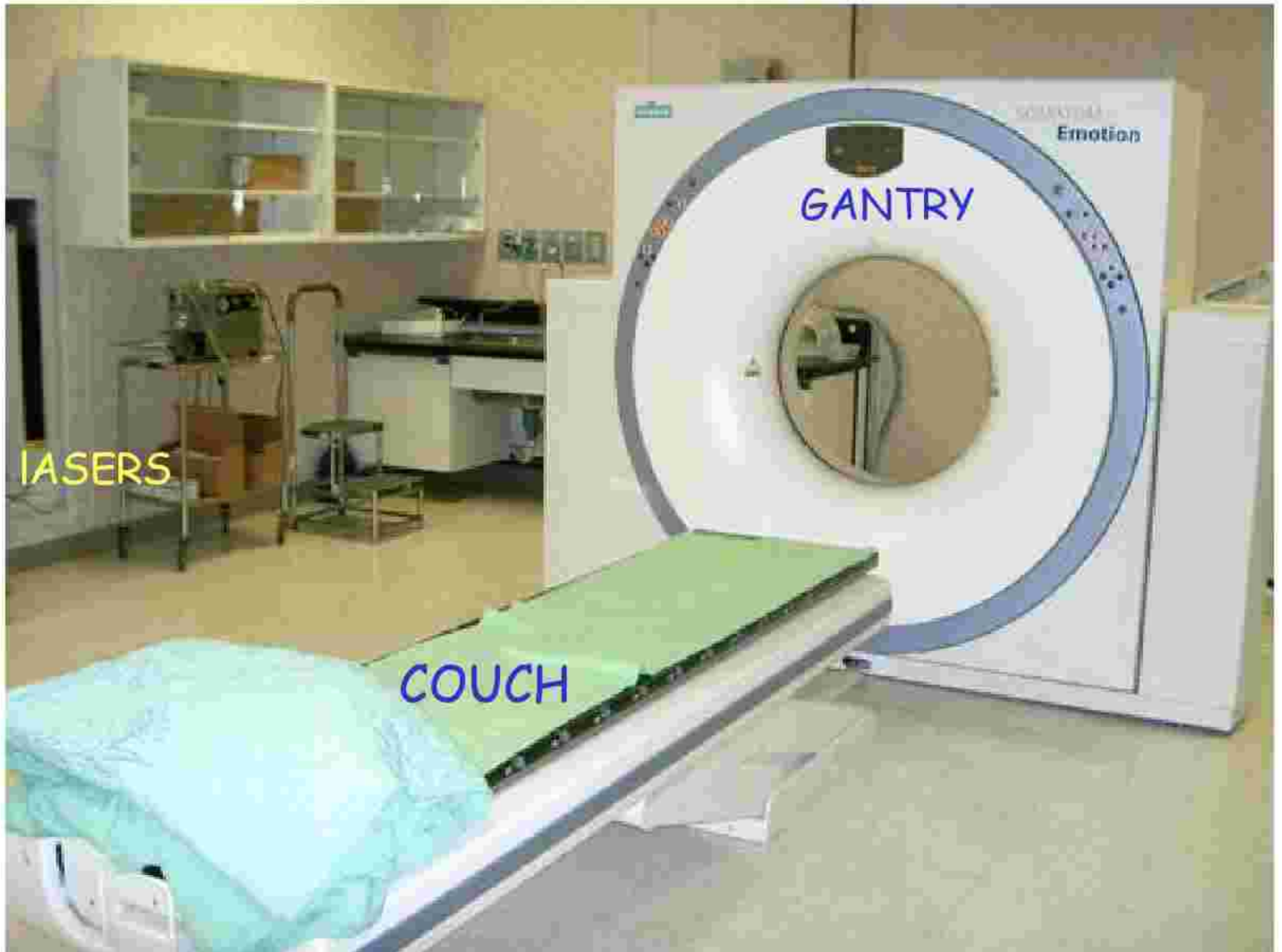CT simulator	Simulator CT
Basically a CT scanner with virtual simulation	Conventional simulator with capability of taking CT section
Multiple slices per rotation	Single slice per rotation
Can be used for CT cuts for 3 D CRT/IMRT etc	Not possible

# The machine

Present generation of CT simulators

- ❖ larger aperture and field of vision
- ❖ Multiple rings of detectors (so multiple images per rotation)
- ❖ Incorporate virtual simulation planning station with moving set of lasers



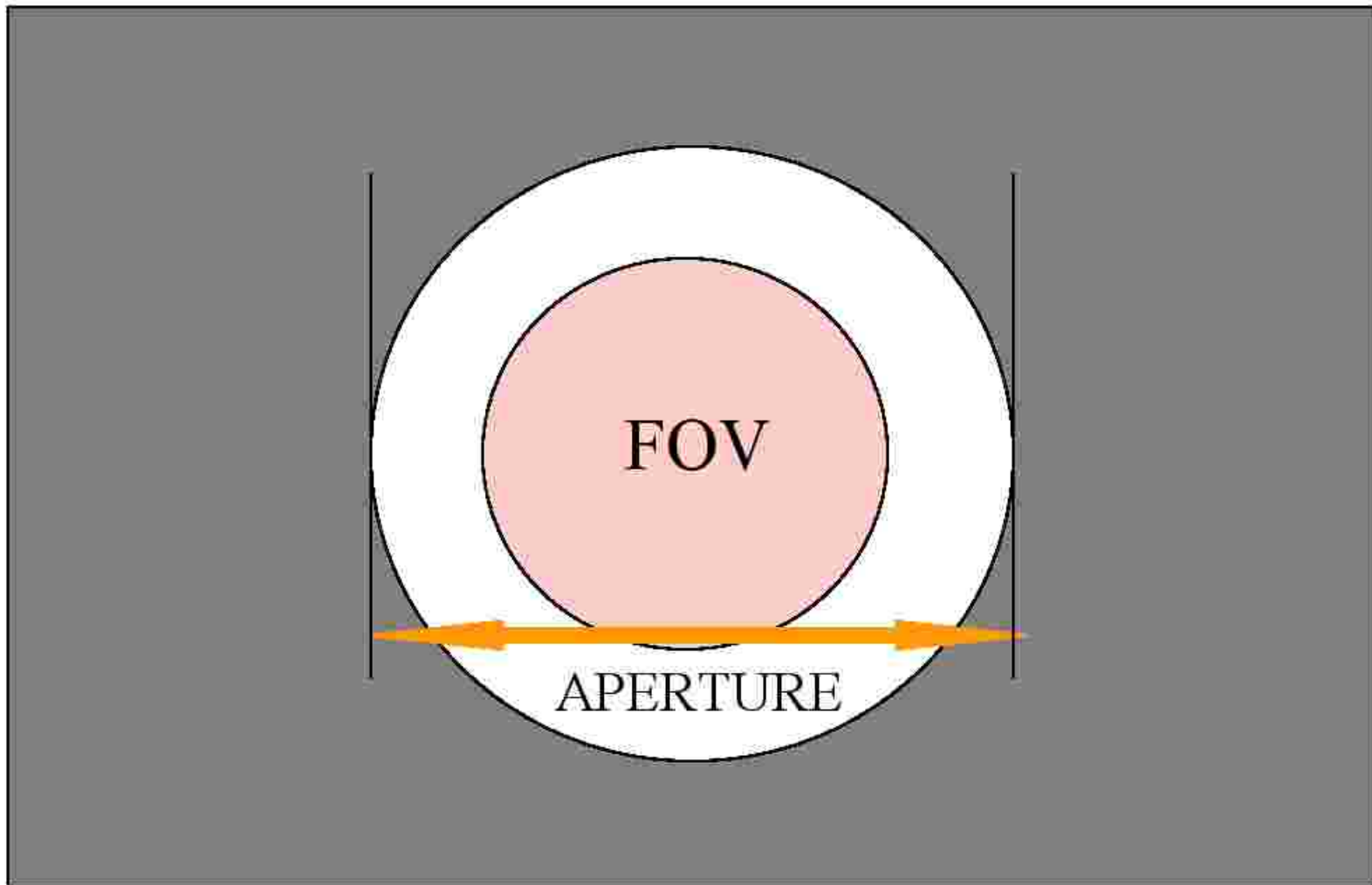


LASERS

GANTRY


COUCH

# The machine



# The machine

- ❖ Usually 4 cuts per rotation of CT gantry
- ❖ Present generation CT simulators have 16 sets of detectors (16 cuts per rotation)



# Contrast media

- ❖ Iodine or non ionic contrast.
- ❖ Gadolinium(paramagnetic contrast) for MRI
- ❖ Double contrast in brain met patients for SRS
- ❖ Inject fast and scan soon!

# Contrast media

- ❖ Should be used in all possible situations
- ❖ Exceptions : Non enhancing low grade gliomas
- ❖ Non ionic preferred

# Air equivalence!

- ❖ IDEAL : To keep everything air equivalent
- ❖ List of articles : couch, head rest(NNR), base plate
- ❖ Can prioritise depending on possible beam arrangement e.g. air equivalent NNR and base plate would be of lesser importance in pituitary adenoma (beam arrangement bilateral and anterior/vertex)

# Sources of Artifacts

- ❖ Remove sources of artefacts (metal pieces, chains)
- ❖ Copper markers give less artefacts compared to lead
- ❖ Beware of metal portions in couch

# Putting markers

Usually in the form of small lead balls/copper wire etc.


## Method 1

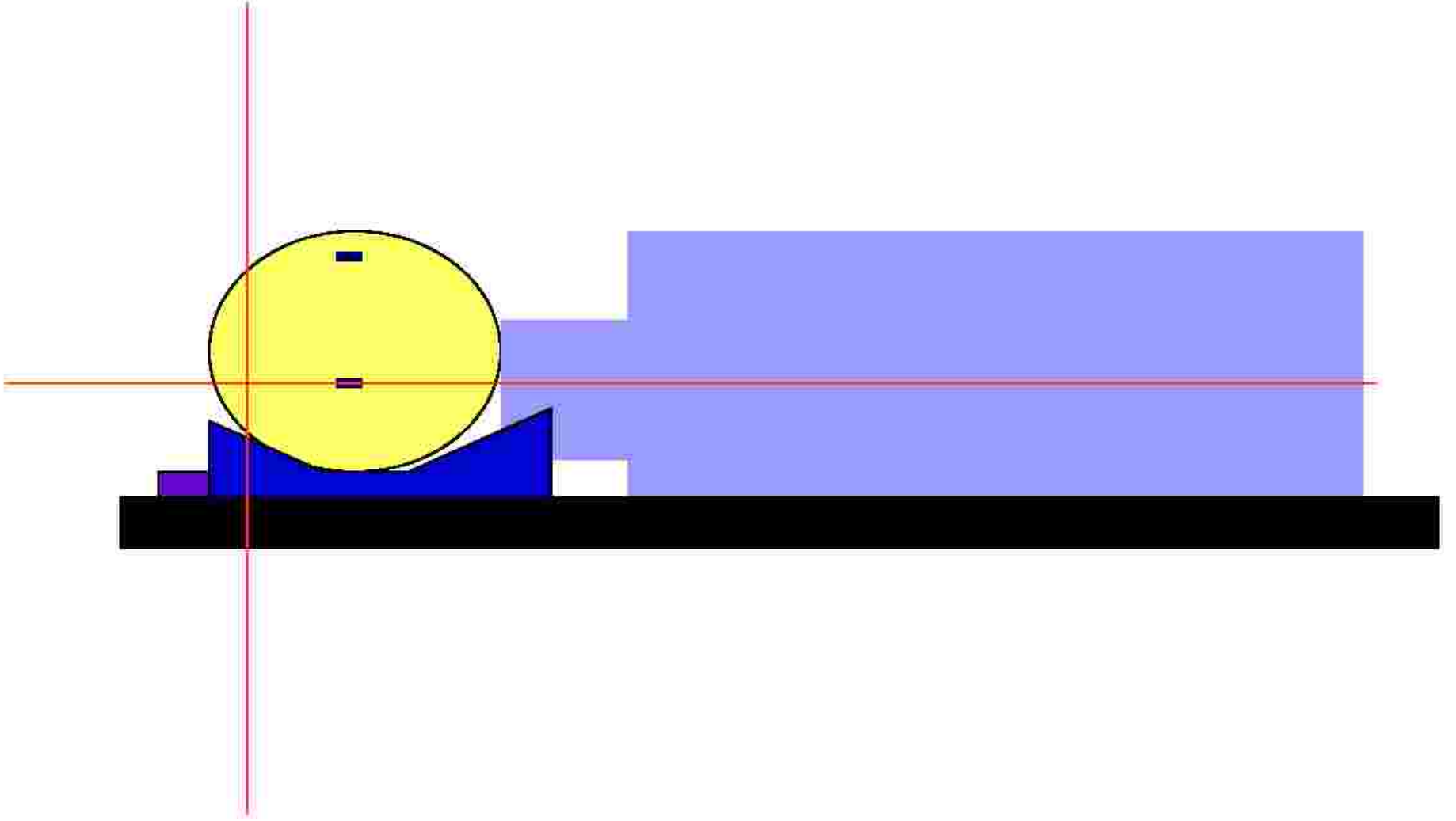
Lead balls stuck to the thermoplastic mask at three points (one ant and two lateral laser intersections on the CT simulator)

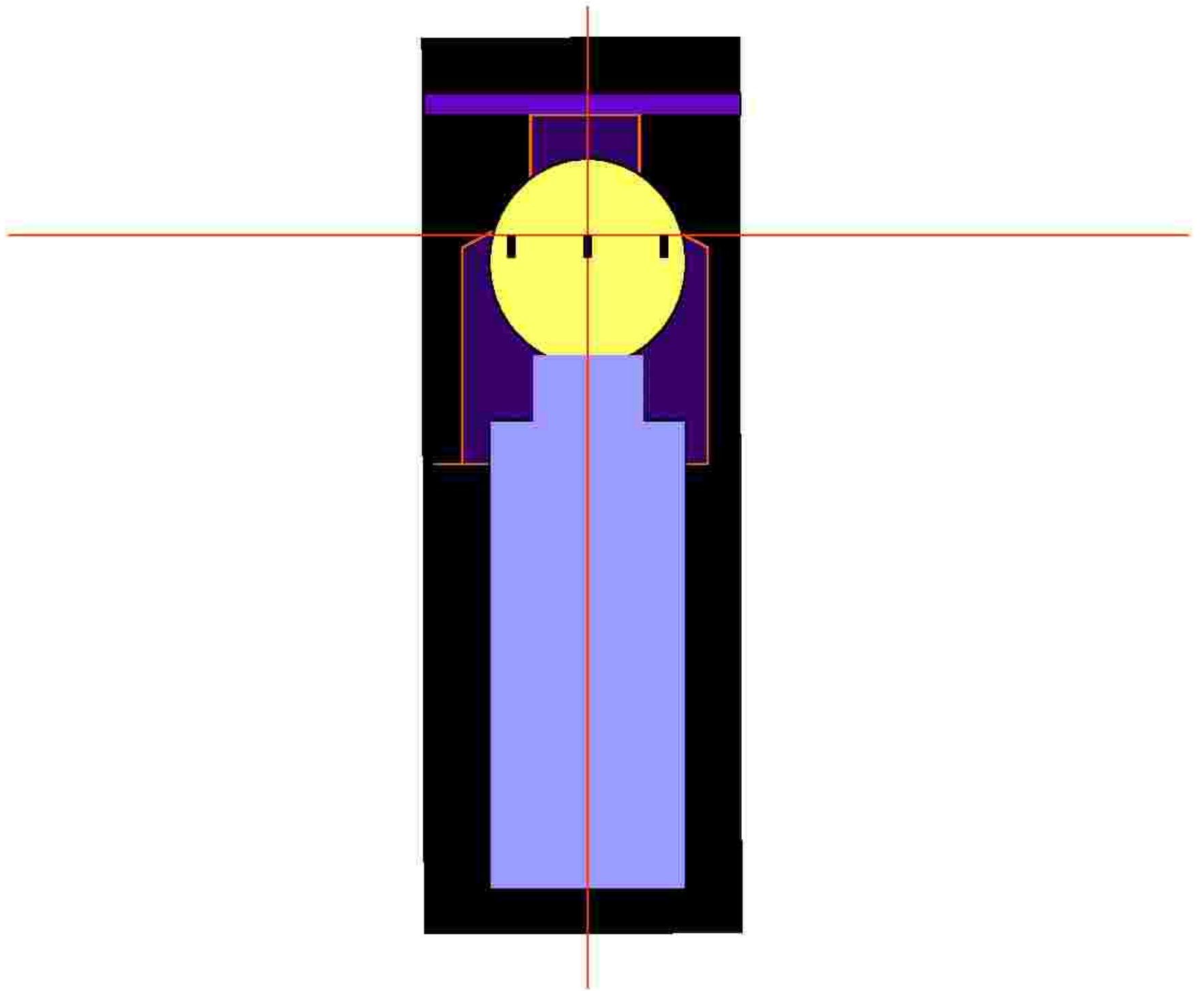
## Method 2

Fix 5mm copper wire bits to the mask at the same position as above. The superior tips of the wires should be at intersections and should be in a straight line (at laser level)









## On the console

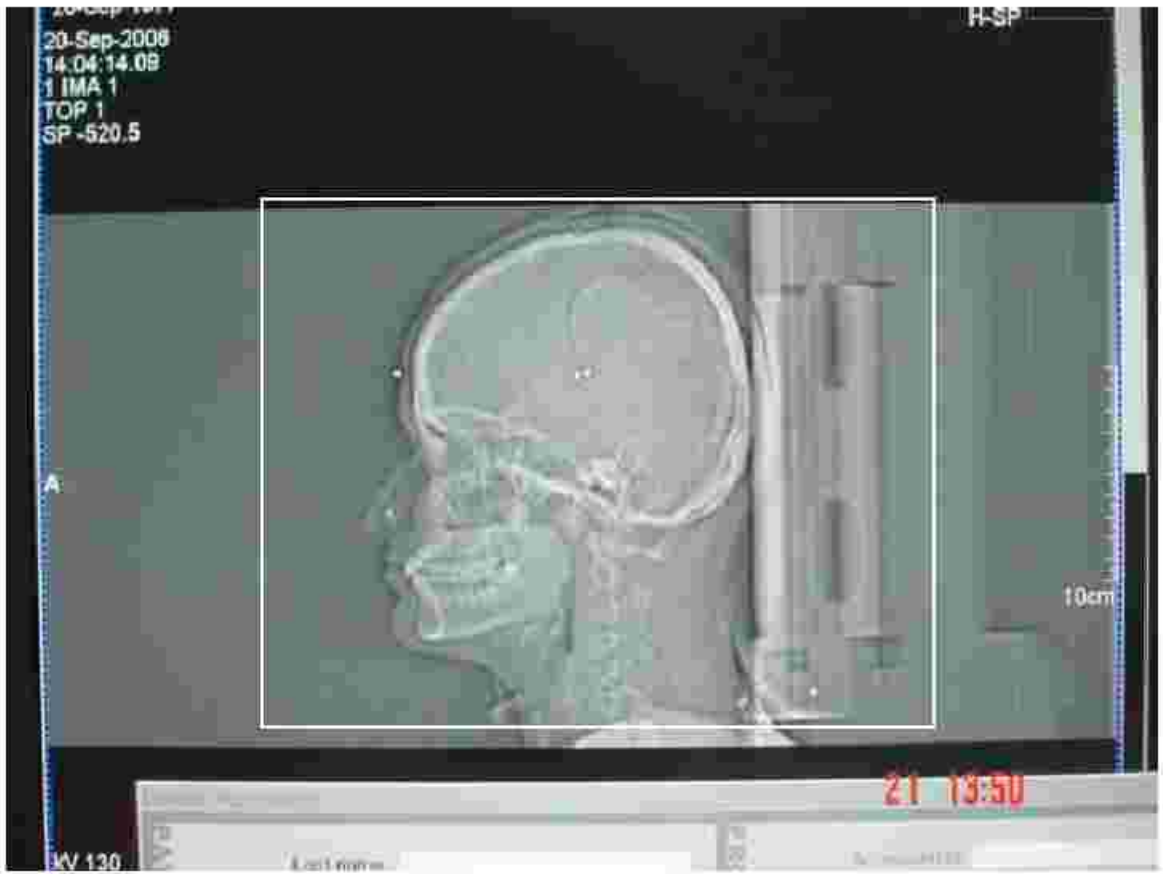- ❖ Register the patient on console
- ❖ Specify Topogram length
- ❖ Take Topogram and adjust FOV
- ❖ Specify slice thickness, sequential/spiral mode, patient position(prone/supine)

# Slice thickness in planning CT scans

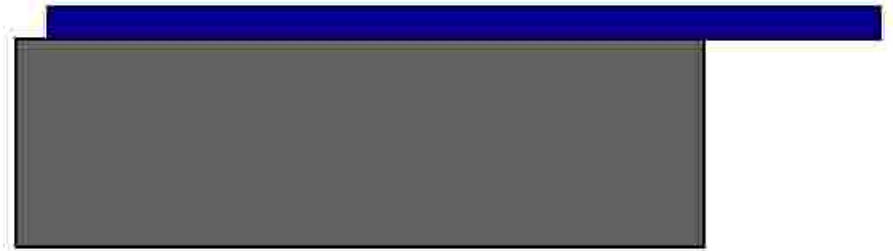- ❖ 3-5mm Majority of brain tumours
- ❖ 2 mm small lesions e.g. pituitary adenomas, craniopharyngiomas
- ❖ 1-2 mm for SRS/SRT

# Topogram


- ❖ To adjust according to size and site of lesion
- ❖ May need to take cranial border in air in superiorly placed lesions or in lesions planned for non coplanar beams/IMRT
- ❖ Take enough cuts above and below the lesion site to allow beam modifications in the planning system(better safe than sorry!)



G  
A  
N  
T  
R  
Y

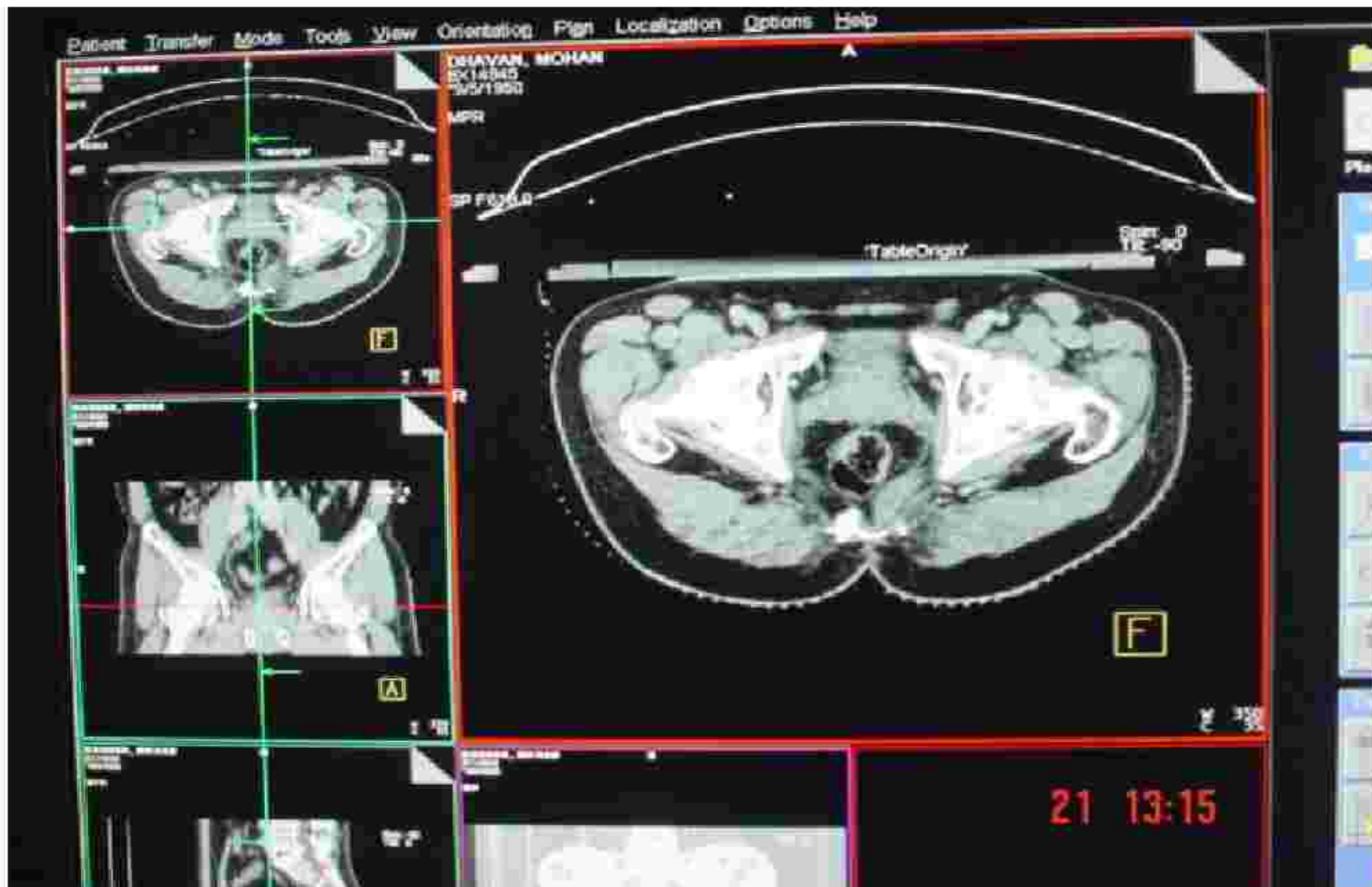




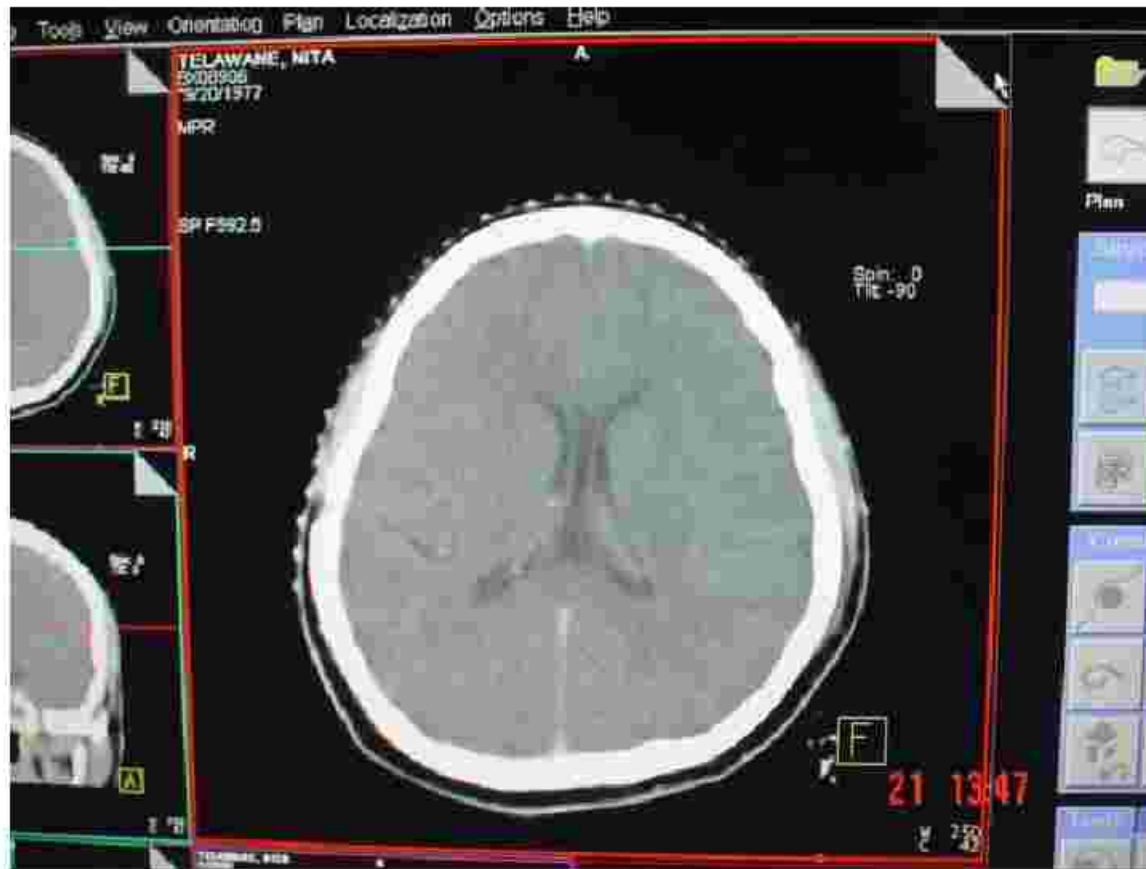
You can follow the proper path or  
else....

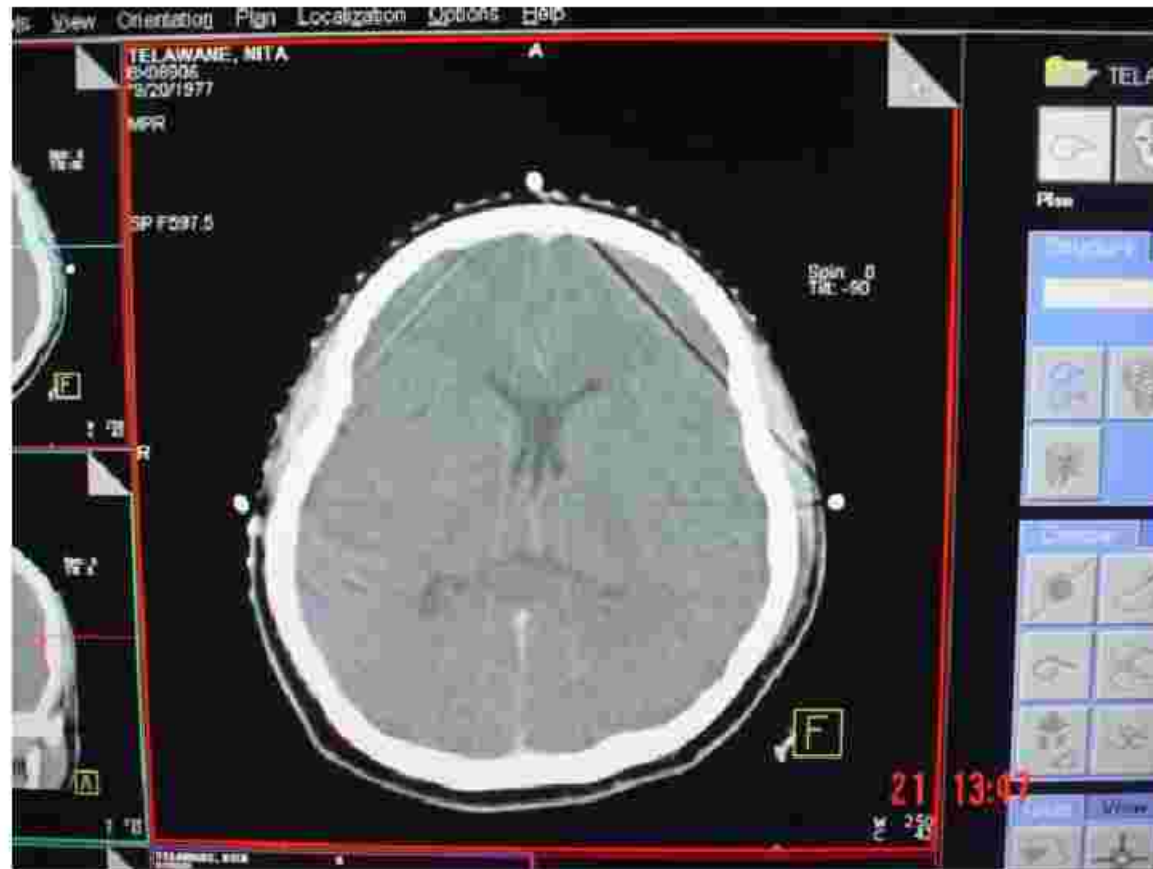... land up with this !



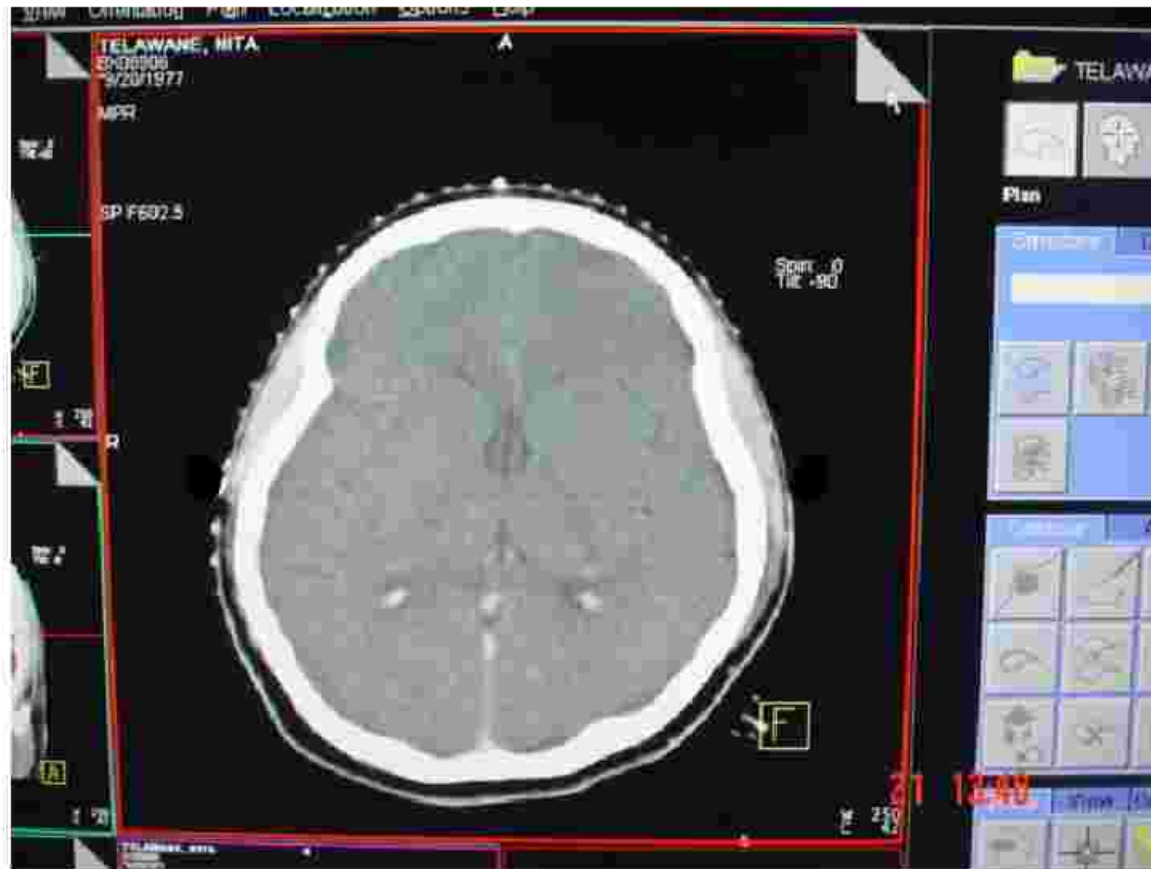# The markers: Cut 1 (nowhere !)



# Cut 2!(appear !)



# Cut 3!(disappear!)



## Planning CT cuts in CNS tumours

Proper immobilisation and alignment a must

To ensure correct position of head based on the tumour location

Confirm correct placement of markers

Use contrast in most situations



The fault, dear Brutus, is not in our stars,  
but in ourselves.....

*Julius Caesar, William Shakespeare*