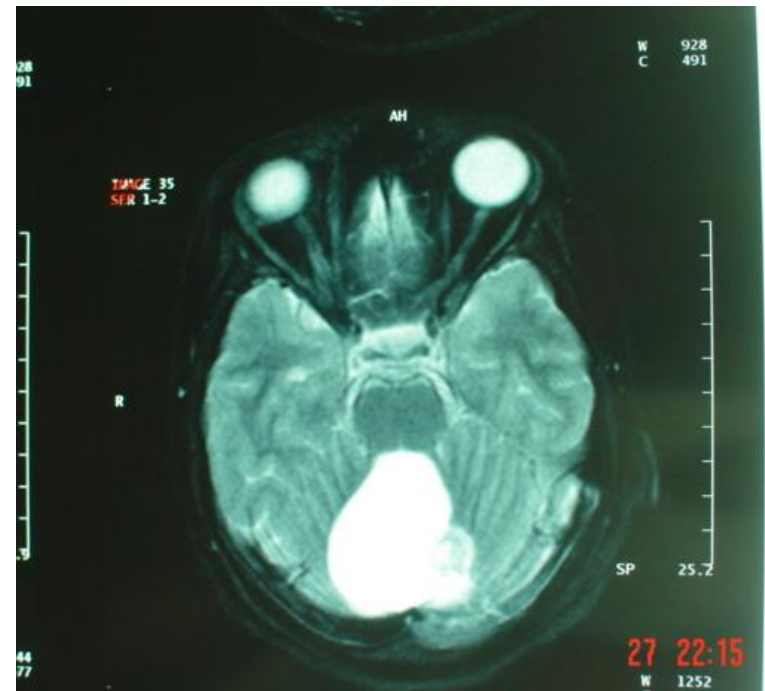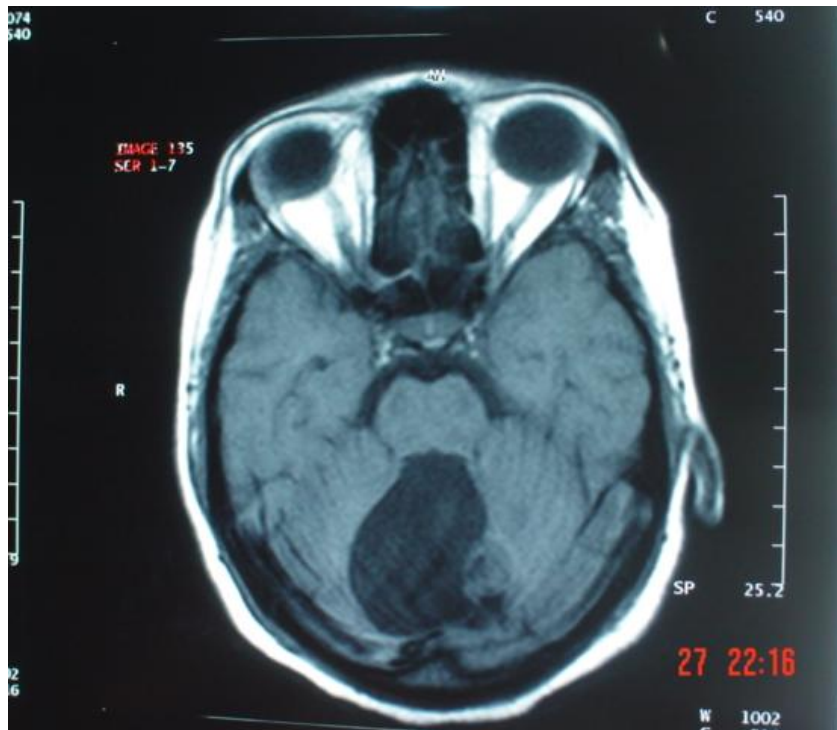
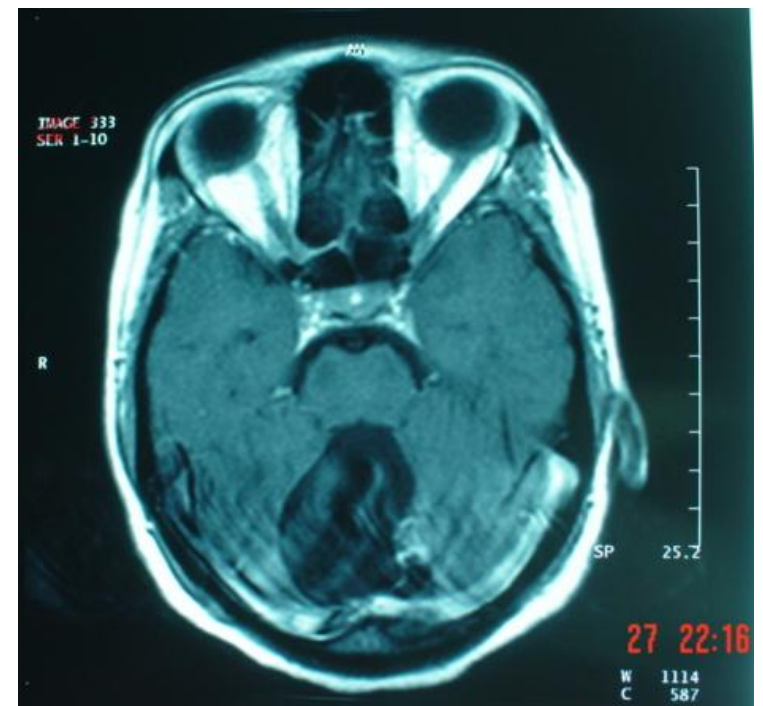


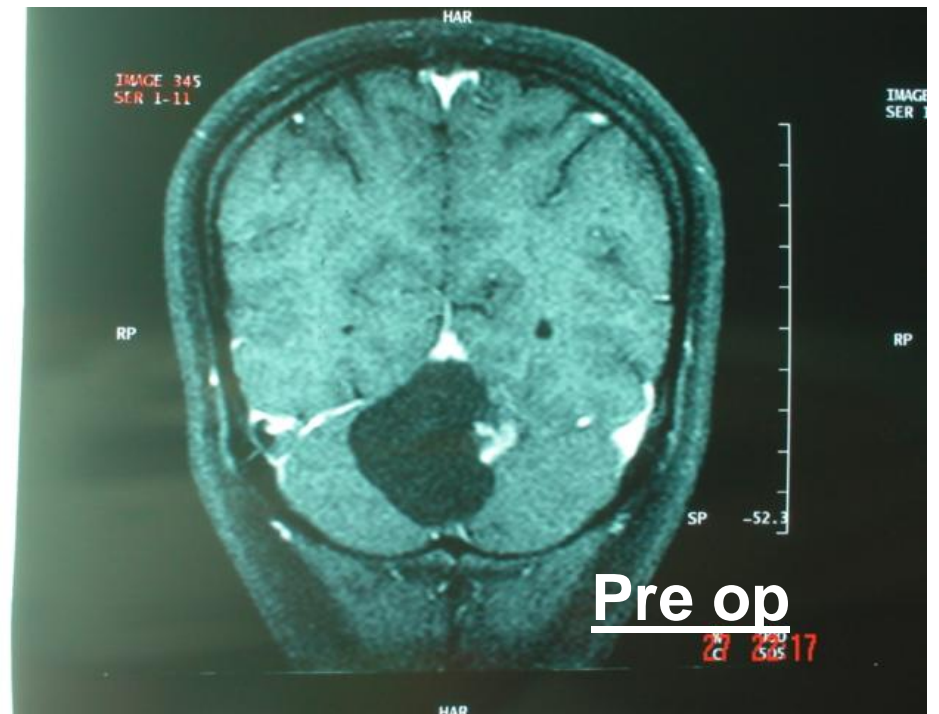
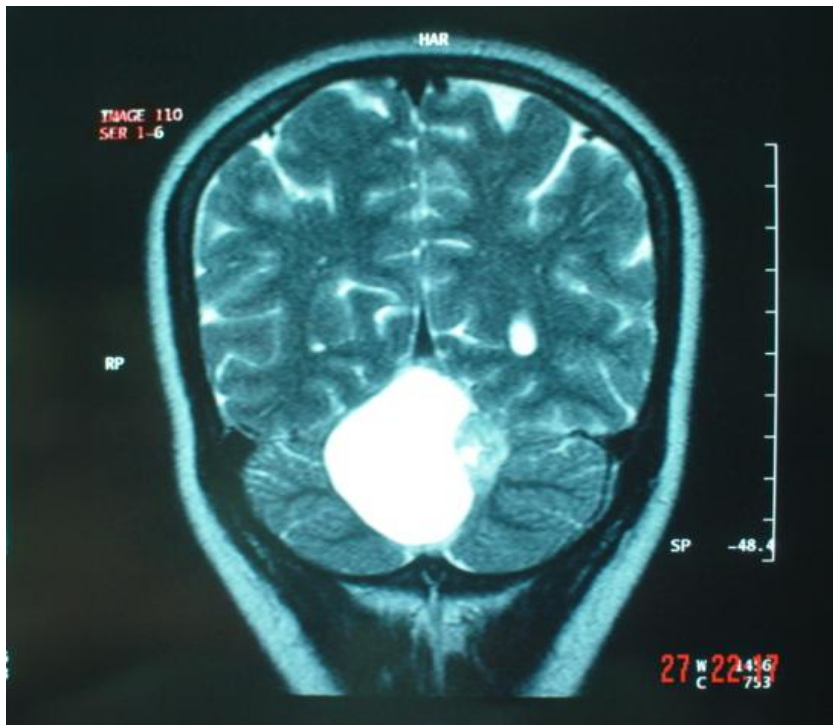
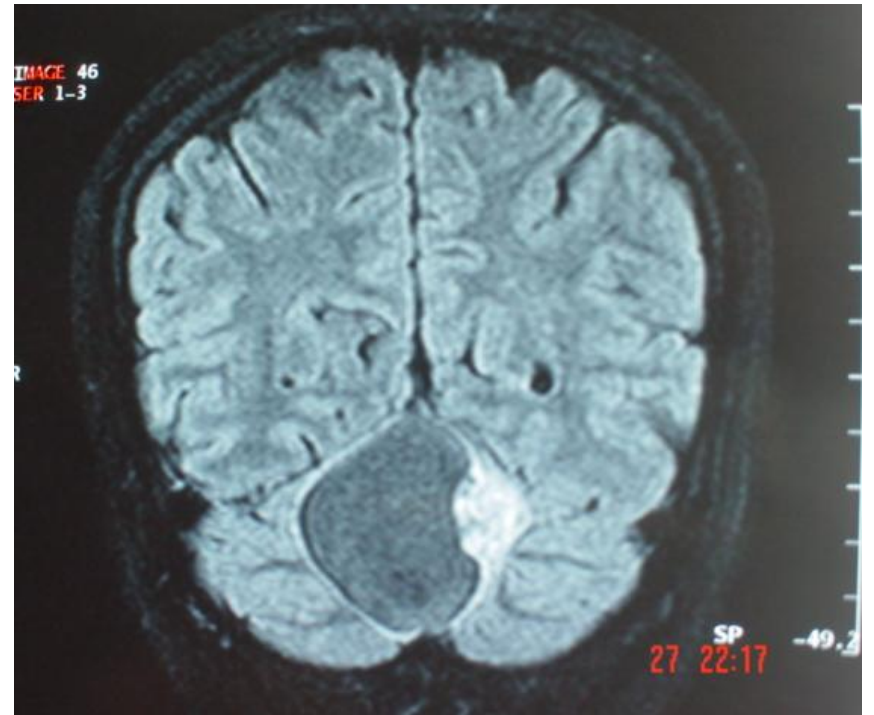
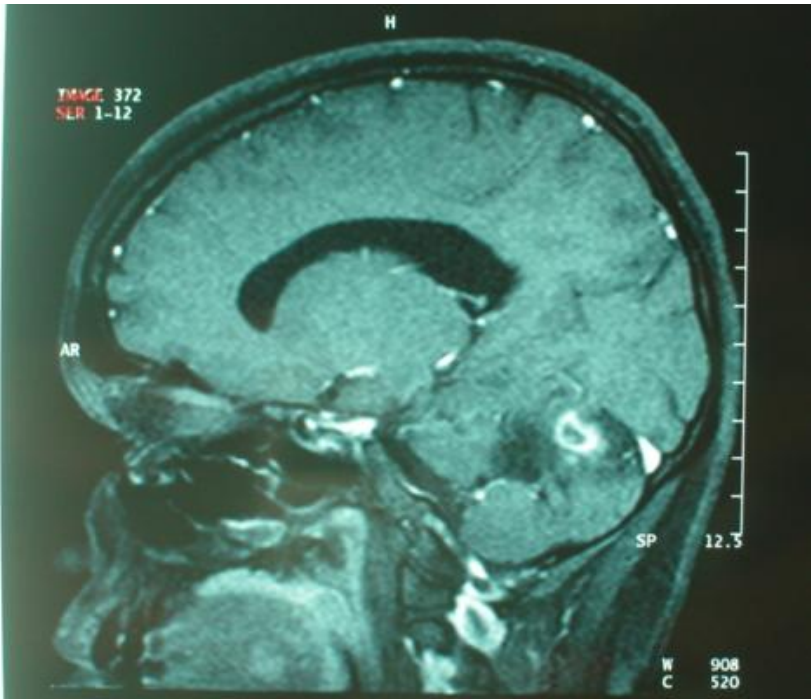
## Case 3

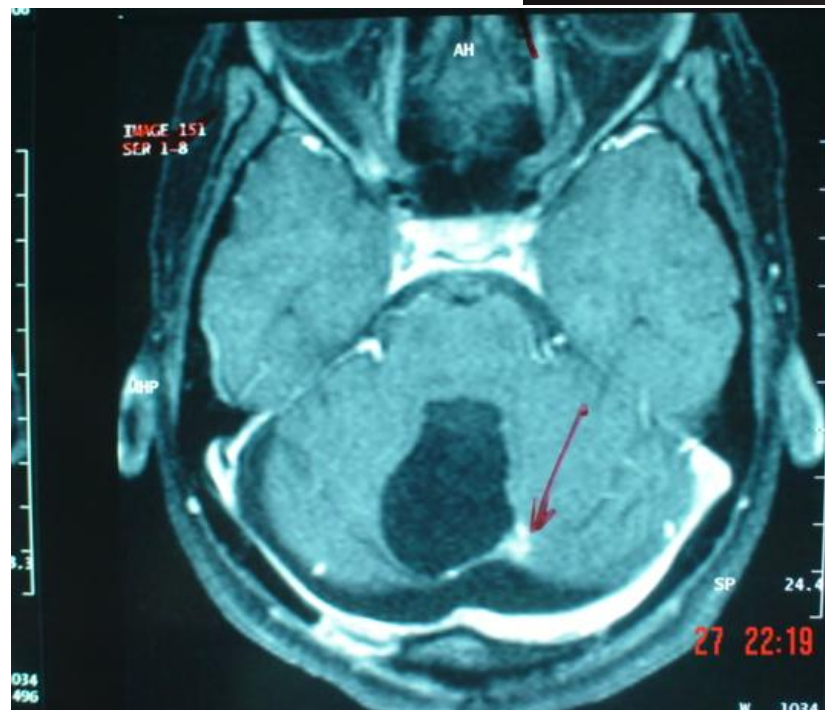
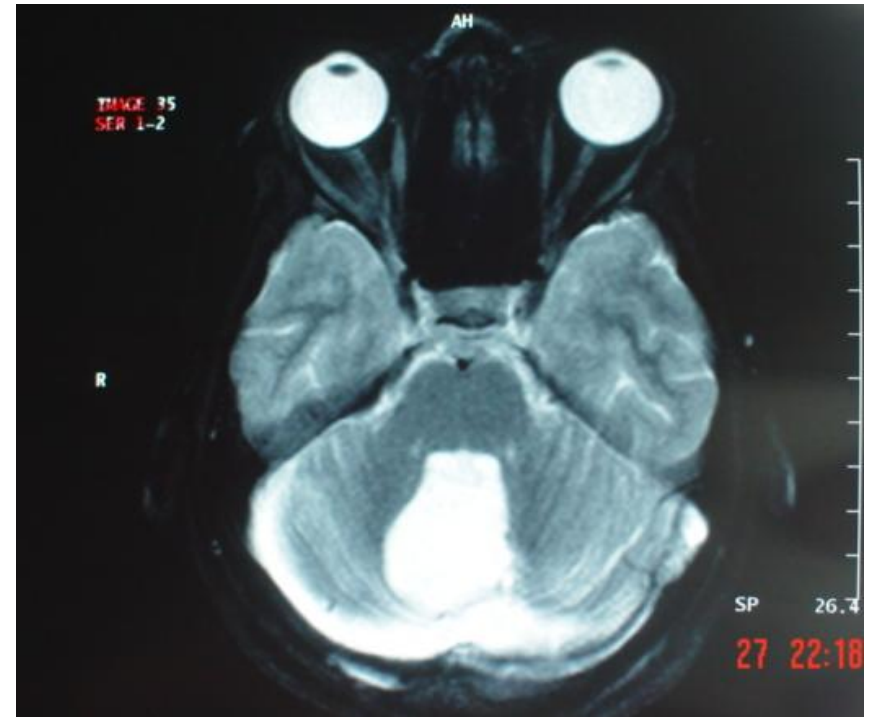
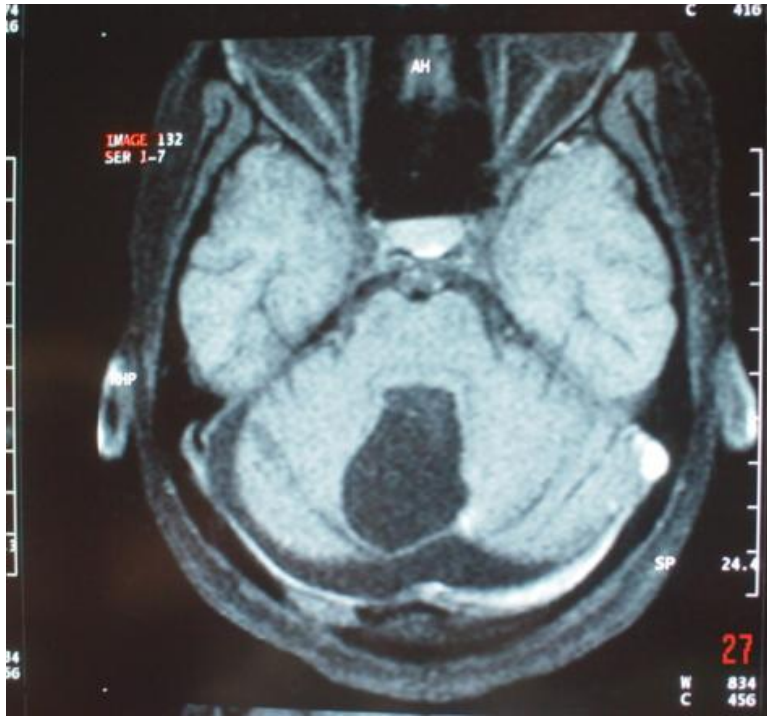
- Ms. Kavita, 20/ F, Rt handed
- Headache, diminition of vision Rt eye & ptosis,
- imbalance since May 06
- MRI 12.08.2006 – ? haemangioblastoma
- Sx 23.08.2006 – midline occipital craniectomy with total excision of cerebellar vermian lesion
- Improvement in headache & ataxia. No improvement in vision.
- HPR – JPA
- MRI 04.09.2006 – appears to have a lot of residual disease



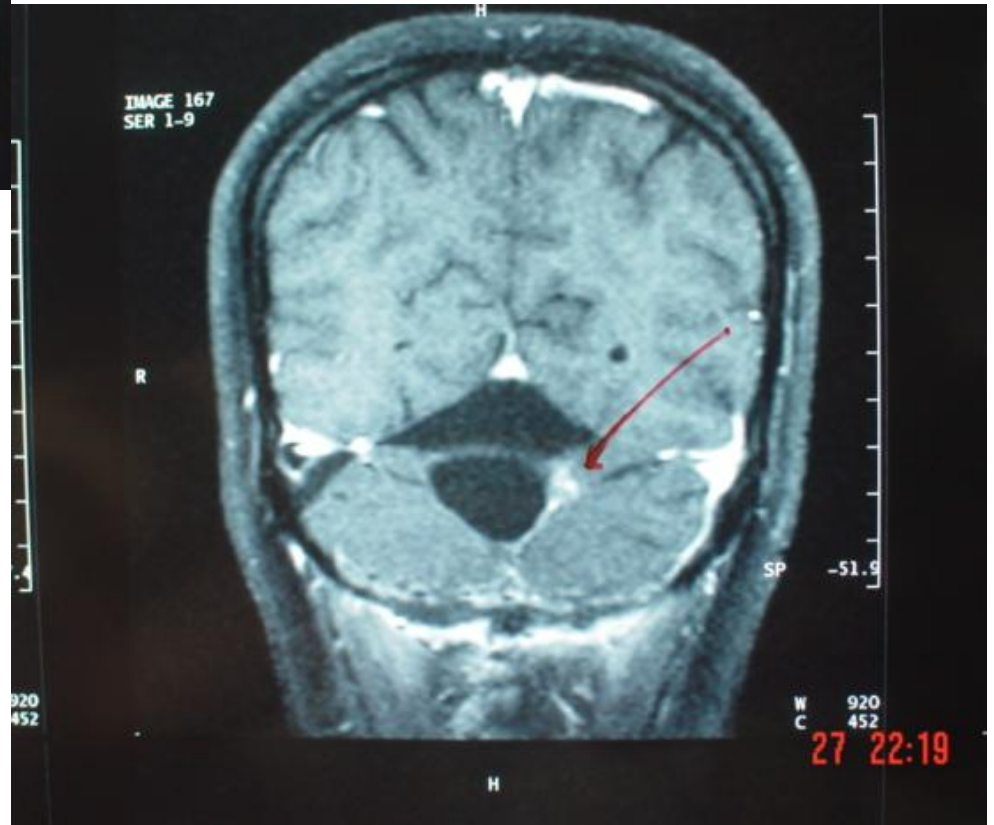
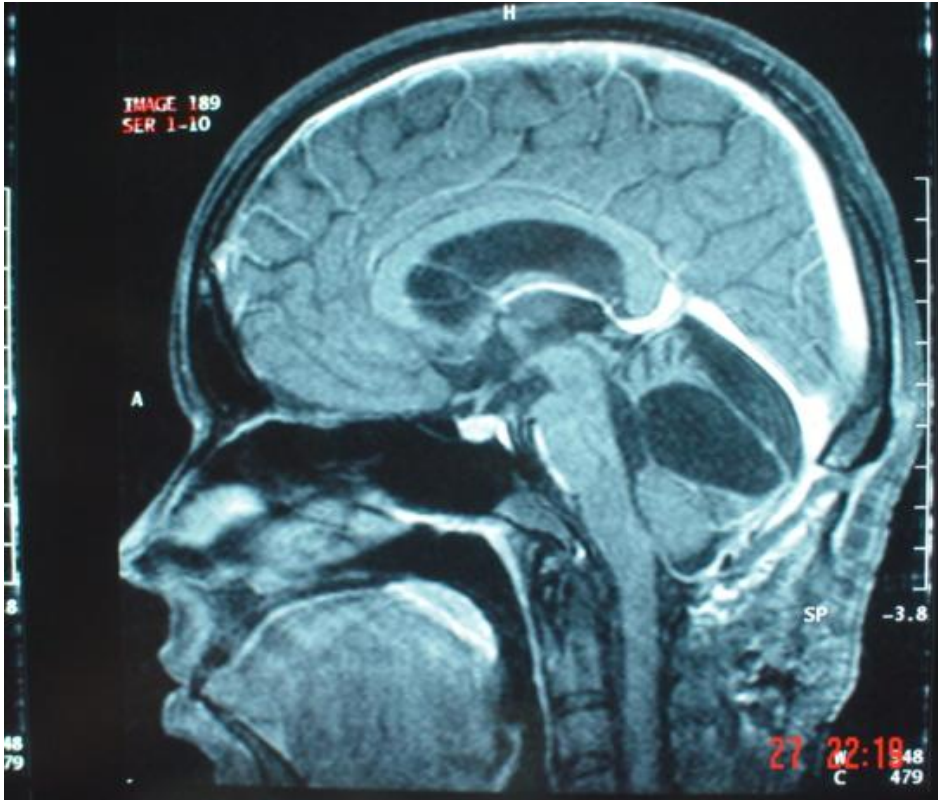
Pre op MRI –  
? haemangioblastoma







Post op



Post op